

## PennHIP Report

Referring Veterinarian: Dr Amber Herron

Email: aherronvet@gmail.com

Clinic Name: Caring Hands Veterinary Hospital (Billings, MT)

Clinic Address: 533 So. 24th St. W  
Billings, MT 59102

Phone: (406) 656-6320

Fax: (406) 652-0551

## Patient Information

Client: Mailloux-Hein, Trina

Patient Name: Wyatt

Reg. Name:

PennHIP Num: 162893

Species: Canine

Date of Birth: 15 Nov 2020

Sex: Male

Date of Study: 27 Sep 2021

Date of Report: 04 Oct 2021

Tattoo Num:

Patient ID: 44481

Registration Num:

Microchip Num:

Breed: AUSTRALIAN SHEPHERD

Age: 10 months

Weight: 52.9 lbs/24 kgs

Date Submitted: 29 Sep 2021

## Findings

Distraction Index (DI): Right DI = 0.14, Left DI = 0.13.

Osteoarthritis (OA): No radiographic evidence of OA for either hip.

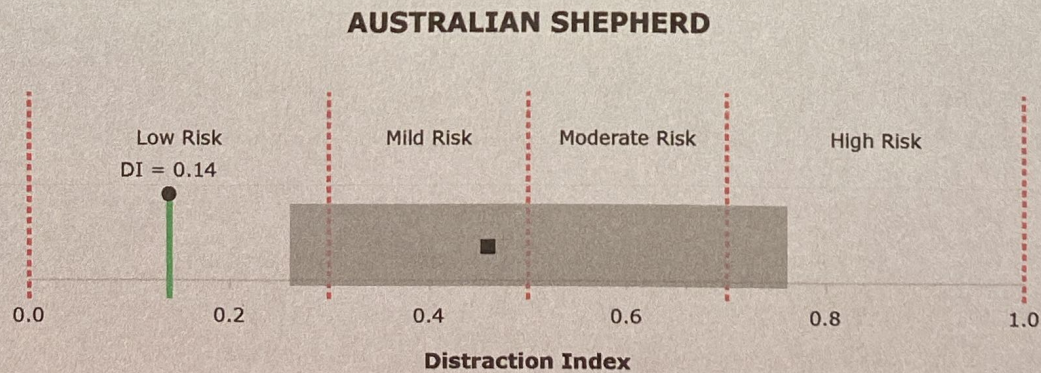
Cavitation/Other Findings: No cavitation present.

## Interpretation

Distraction Index (DI): The laxity ranking is based on the hip with the greater laxity (larger DI). In this case the DI used is 0.14.

OA Risk Category: The DI is less than or equal to 0.30. This patient is at minimal risk for hip OA.

Distraction Index Chart:



**BREED STATISTICS:** This interpretation is based on a cross-section of 1669 canine patients of the AUSTRALIAN SHEPHERD breed in the AIS PennHIP database. The gray strip represents the central 90% range of DIs (0.26 - 0.76) for the breed. The breed average DI is 0.46 (solid square). The patient DI is the solid circle (0.14).