



Osteonecrosis of the Hip

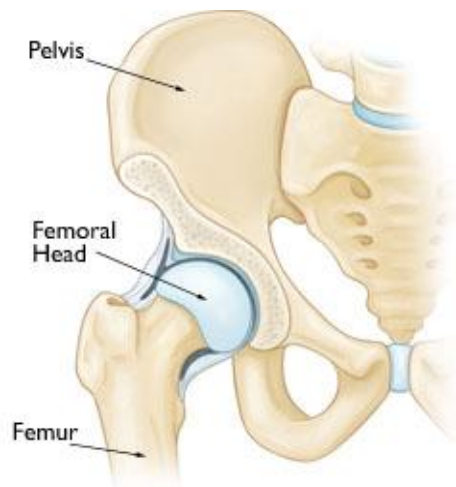
Osteonecrosis of the hip is a painful condition that occurs when the blood supply to the bone is disrupted. Because bone cells die without a blood supply, osteonecrosis can ultimately lead to destruction of the hip joint and arthritis.

Osteonecrosis is also called avascular necrosis or aseptic necrosis. Although it can occur in any bone, osteonecrosis most often affects the hip. More than 20,000 people each year enter hospitals for treatment of osteonecrosis of the hip. In many cases, both hips are affected by the disease.

Anatomy

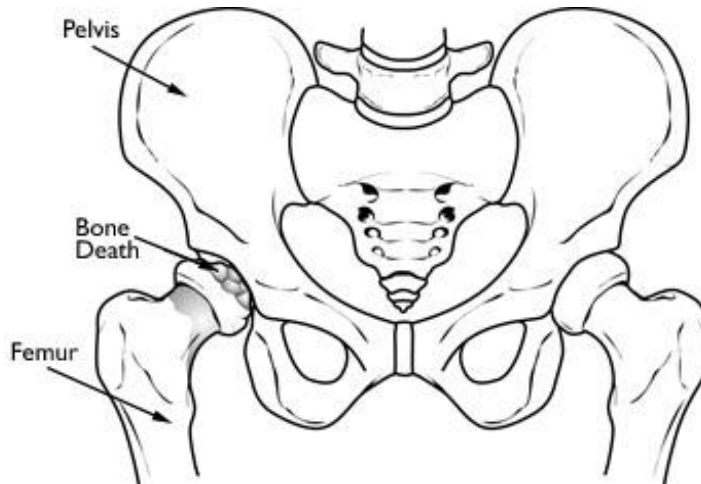
The hip is a ball-and-socket joint. The socket is formed by the acetabulum, which is part of the large pelvis bone. The ball is the femoral head, which is the upper end of the femur (thighbone).

A slippery tissue called articular cartilage covers the surface of the ball and the socket. It creates a smooth, low friction surface that helps the bones glide easily across each other.



Cause

Osteonecrosis of the hip develops when the blood supply to the femoral head is disrupted. Without adequate nourishment, the bone in the head of the femur dies and gradually collapses. As a result, the articular cartilage covering the hip bones also collapses, leading to disabling arthritis.



With osteonecrosis, the bone in the head of the femur slowly dies.

Risk Factors

Although it is not always known what causes the lack of blood supply, there are a number of risk factors that can make it more likely for someone to develop the disease:

- Injury — Hip dislocations, hip fractures, and other injuries can damage the blood vessels and impair circulation to the femoral head
- Alcoholism
- Corticosteroid medicines — Many diseases, such as asthma, rheumatoid arthritis, and systemic lupus erythematosus, are treated with steroid medications. Although it is not known exactly why these medications can lead to osteonecrosis, research shows that there is a connection between the disease and long-term steroid use.
- Other medical conditions — Osteonecrosis is associated with other diseases, including Caisson disease (diver's disease or "the bends"), sickle cell disease, myeloproliferative disorders, Gaucher's disease, systemic lupus erythematosus, Crohn's disease, arterial embolism, thrombosis, and vasculitis

Incidence

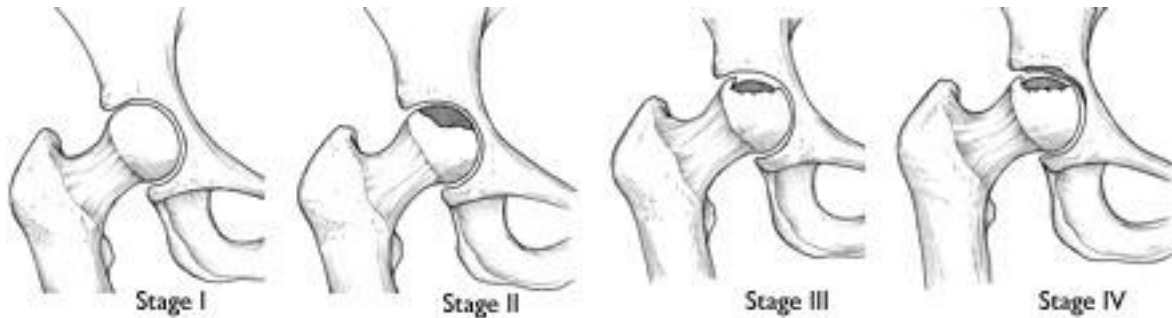
Although osteonecrosis affects people of all ages, it most commonly occurs between the ages of 40 and 65. Men develop osteonecrosis more often than women.

Symptoms

Osteonecrosis develops in stages. Hip pain is typically the first symptom. This may lead to a dull ache or throbbing pain in the groin or buttock area. As the disease progresses, it will become more difficult to stand and put weight on the affected hip, and moving the hip joint will be painful.

How long it takes for the disease to progress through these stages varies from several months to over a year. It is important to diagnose this disease early,

because some studies show that early treatment is associated with better outcomes.



Osteonecrosis can progress from a normal, healthy hip (Stage I) to the collapse of the femoral head (Stage IV).

Reproduced with permission from Beaulé PE, Amstutz, HC: Management of femoral head stage III and IV osteonecrosis of the hip. J Amer Acad Orthop Surg 2004; 12: 96-105.

Doctor Examination

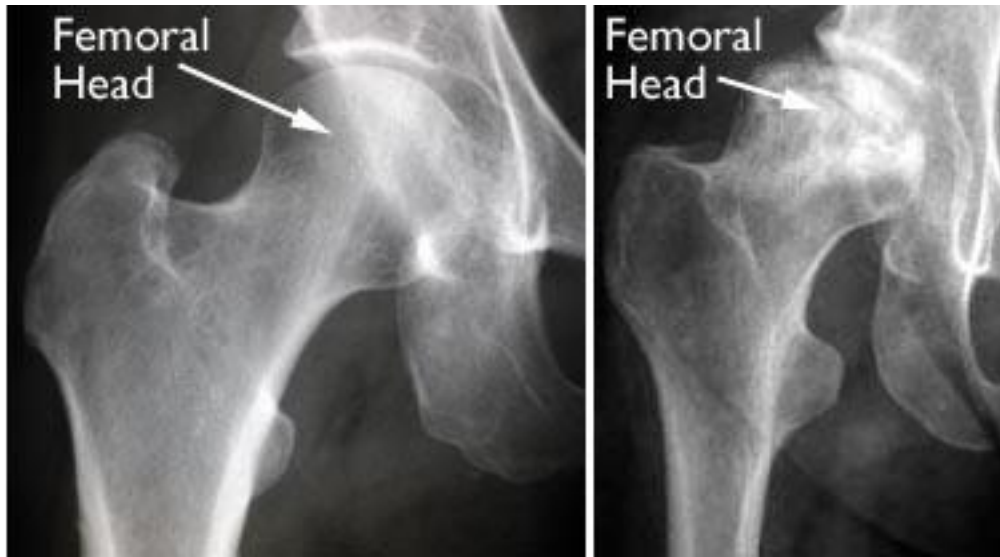
After discussing your symptoms and medical history, your doctor will examine your hip to discover what specific motions cause you pain.

Imaging Tests

Imaging tests that may help your doctor confirm a diagnosis include:

X-rays. These scans create pictures of dense structures, like bone. X-rays are used to determine whether the bone in the femoral head has collapsed and to what degree.

Magnetic resonance imaging (MRI) scans. Early changes in the bone that may not show up in an x-ray can be detected with an MRI scan. These scans are used to evaluate how much of the bone is affected by the disease. An MRI may show early osteonecrosis that has yet to cause symptoms (for example, whether osteonecrosis is developing in the opposite hip joint).



(Left) An x-ray of a healthy hip joint. **(Right)** In this x-ray, the osteonecrosis has progressed to collapse of the femoral head.

Treatment

Although nonsurgical treatment options like medications or using crutches can relieve pain and slow the progression of the disease, the most successful treatment options are surgical. Patients with osteonecrosis that is caught in the very early stages (prior to femoral head collapse) are good candidates for hip preserving procedures.

Core Decompression

This procedure involves drilling one larger hole or several smaller holes into the femoral head to relieve pressure in the bone and create channels for new blood vessels to nourish the affected areas of the hip.

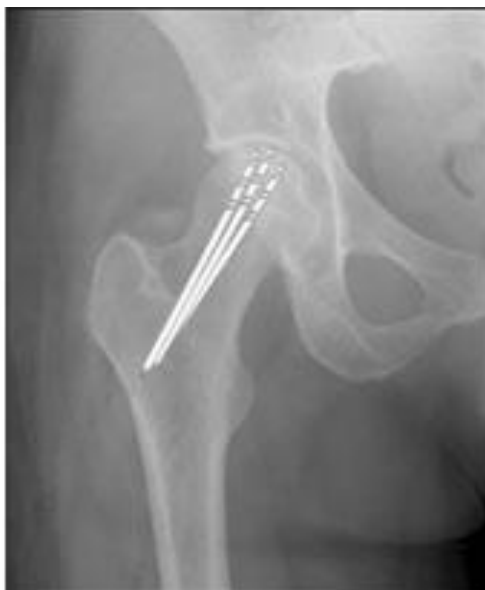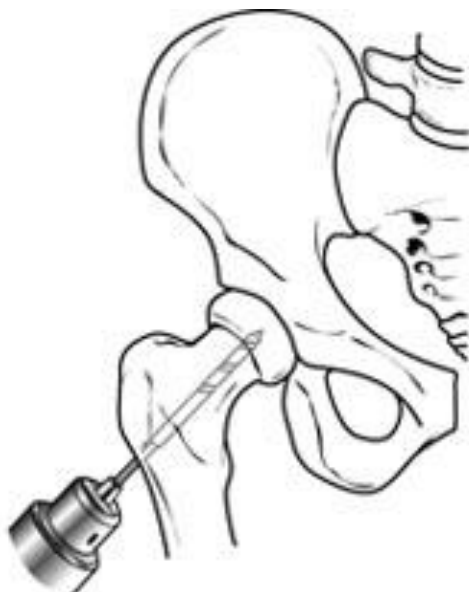When osteonecrosis of the hip is diagnosed early, core decompression is often successful in preventing collapse of the femoral head and the development of arthritis.

Core decompression is often combined with bone grafting to help regenerate healthy bone and support cartilage at the hip joint. A bone graft is healthy bone tissue that is transplanted to an area of the body where it is needed.

Many bone graft options are available today. The standard technique is to take extra bone from one part of your body (harvest) and move (graft) it to another part of your body. This type of graft is called an autograft.

Many surgeons use bone that is harvested from a donor or cadaver. This type of graft is typically acquired through a bone bank. Like other organs, bone can be donated upon death.

There are also several synthetic bone grafts available today.



(Left) Core decompression. **(Right)** In this x-ray, the drill lines show the pathway of small drill holes used in a core decompression procedure.

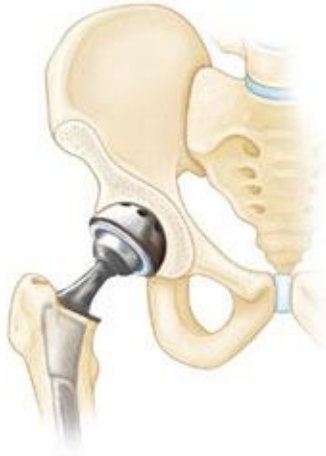Vascularized Fibula Graft

Another surgical option is a vascularized fibula graft. This is a more involved procedure in which a segment of bone is taken from the small bone in your leg (fibula) along with its blood supply (an artery and vein). This graft is transplanted into a hole created in the femoral neck and head, and the artery and vein are reattached to help heal the area of osteonecrosis.

Total Hip Replacement

If osteonecrosis has advanced to femoral head collapse, the most successful treatment is total hip replacement. This procedure involves replacing the damaged cartilage and bone with artificial implants.

Total hip replacement is successful in relieving pain and restoring function in 90 to 95 percent of patients. It is considered one of the most successful operations in all of medicine.



In a total hip replacement, both the head of the femur and the socket are replaced with an artificial device.

Outcomes

Core decompression prevents osteonecrosis from progressing to severe arthritis and the need for hip replacement in 25% to 85% of cases. This depends upon the stage and size of the osteonecrosis at the time of the procedure.

Core decompression achieves the best results when osteonecrosis is diagnosed in its early stages, before the bone collapses. In many of these cases, the bone heals and regains its blood supply after core decompression. It takes a few months for the bone to heal, and during this time, a walker or crutches will be needed to prevent putting stress on the damaged bone.

Patients with successful core decompression procedures typically return to walking unassisted in about 3 months and have complete pain relief.

When osteonecrosis is diagnosed after collapse of the bone, core decompression is not usually successful in preventing further collapse. In this situation, the patient is best treated with a total hip replacement, which relieves pain and restores function in 90% to 95% of patients.

Source: 2006-2009 Nationwide Inpatient Sample, Healthcare Cost and Utilization Project (HCUP), from the Agency for Healthcare Research and Quality (AHRQ)