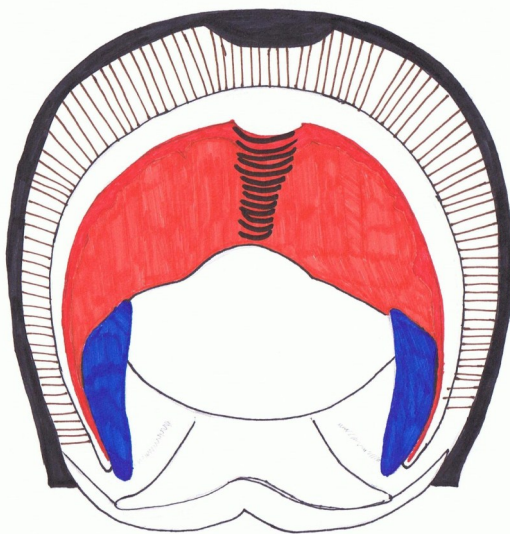
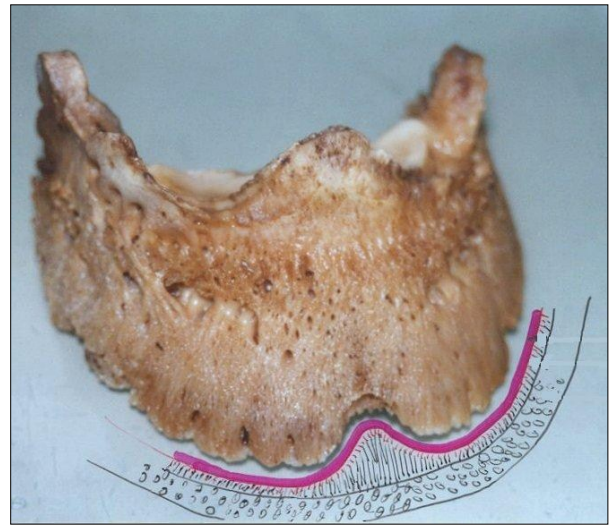




Keratoma

Sometimes you see a small semicircular area inside the white line horn at the toe. Here the coffin bone has been destroyed to some degree and the hole in the coffin bone has been lined with and filled in with laminar



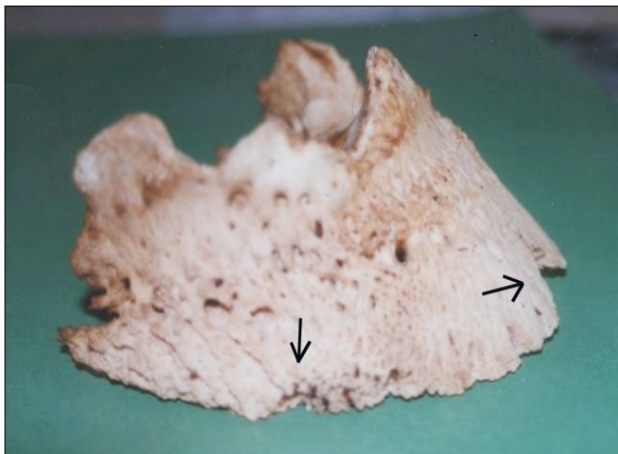
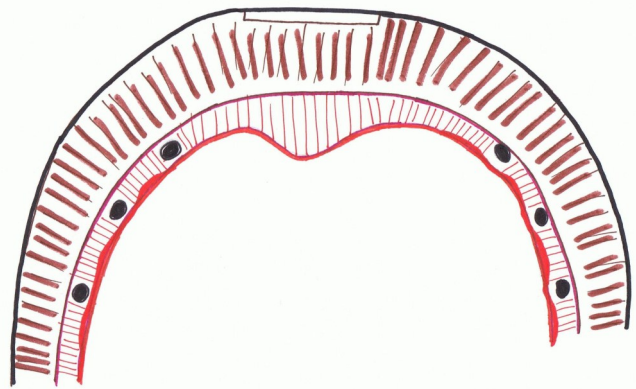
horn.

Often this laminar horn dries out quickly and crumbles away, leaving a hole in that area.

This often happens when a horse was shod with a toe clip. With every step pressure is exerted onto the frontal area of the hoof. This may also happen when you have a break in the hoof cap-

sule for a long time and the edges of the break push inwards.

Smaller keratomas may be found on the side of the hoof where the hoof has been "quicked" (nailed into the corium)



As the keratoma is highly elastic, soft laminar horn, it cannot be the cause for lameness and pain, but it is a symptom for unphysiological pressure.

Coffin bone with typical bone loss through unphysiological pressure

Pictures: Dr. Hiltrud Strasser Drawings: r.g photography

U
N
O

A
L
L
A

V
O
L
T
A
—

O
N
E

A
T

A

T
I
M
E