

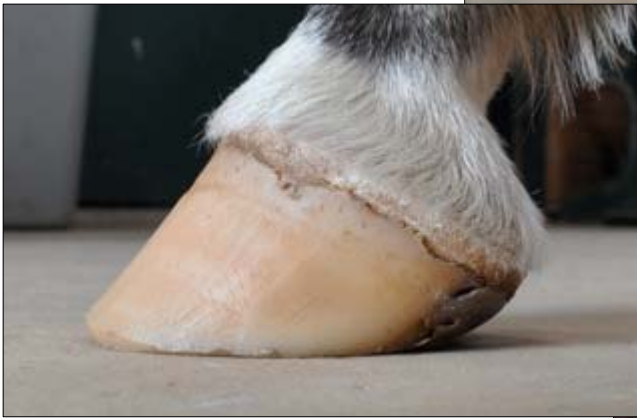
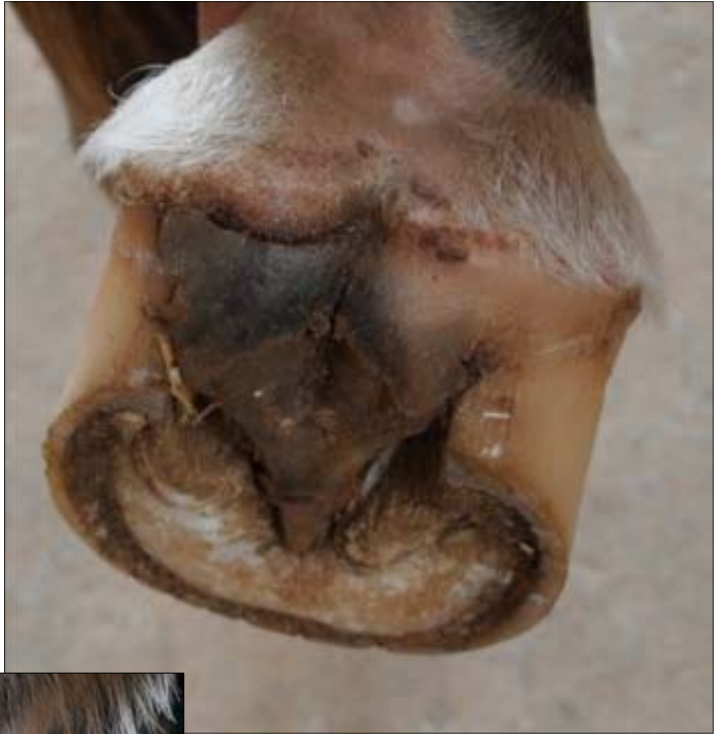
Problems with the Coronet Band

Once in a while we see things that are, well to say the least, a bit unusual. Like this one here:

The bulb seems to have a horizontal crack, maybe an abscess? Maybe the horse hit himself with the toe of the hind foot?

And then you investigate this further and you see that the coronet band looks sort of "disconnected" like in the picture below:



While this all looks a bit unusual, it may well be a reaction to changing circumstances in the horse's lifestyle. The feed, the terrain, the weather. All may



have an influence on the periople/coronet band/heel/bulb connection. An interruption in metabolism triggers the inflammation of the periople.

U
N
O

A
L
L
A

V
O
L
T
A
—

O
N
E

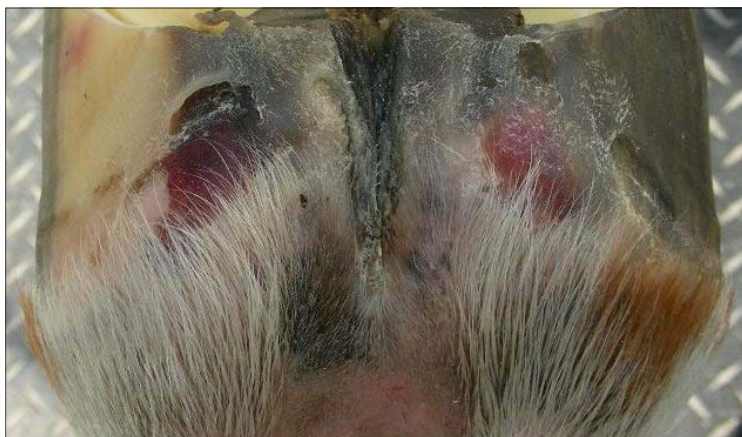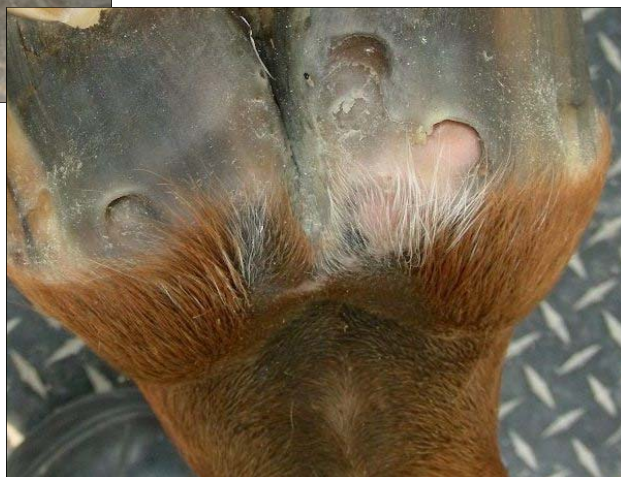
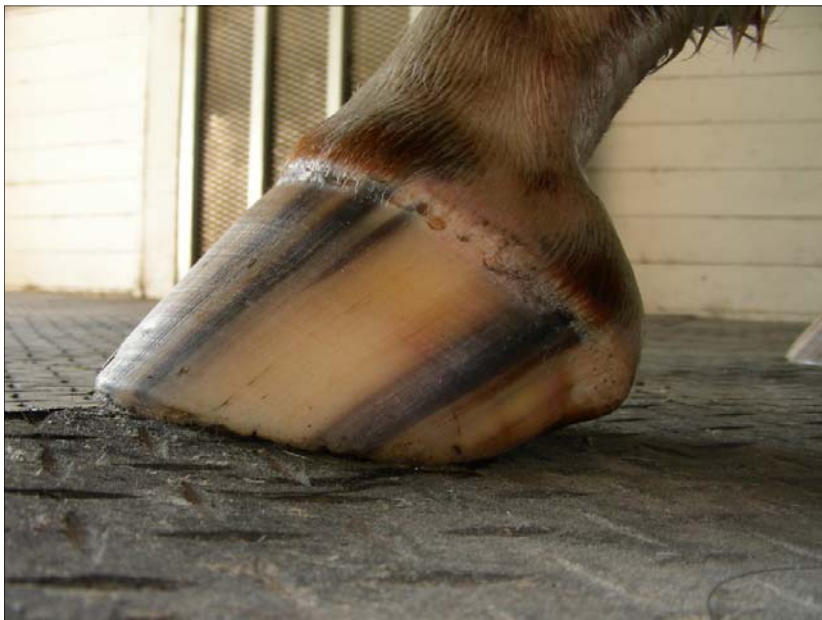A
T

A

T
I
M
E



Here is how that may have started:



It may even start like this (which you may not know about, unless you see the horse every day)

U
N
O

A
L
L
A

V
O
L
T
A
—

O
N
E

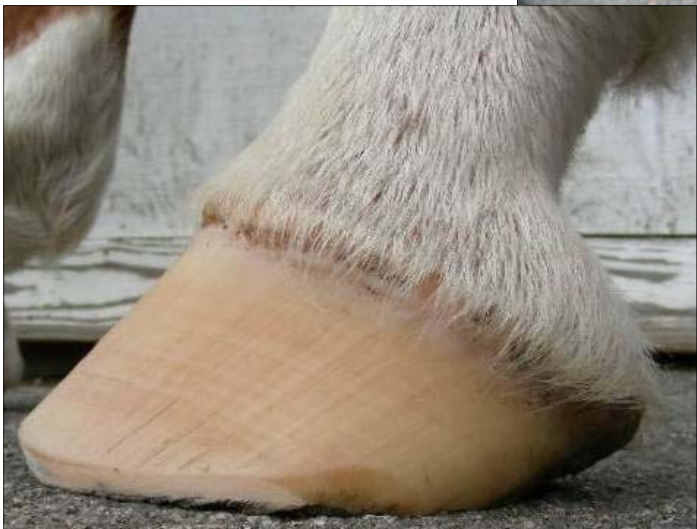A
T

A

T
I
M
E



Horse with definite metabolic problems shows the same symptom of the coronet connection.



U
N
O

A
L
L
A

V
O
L
T
A
—

O
N
E

A
T

A

T
I
M
E



Stretched periople



U
N
O

A
L
L
A

V
O
L
T
A
—

O
N
E

A
T

A

T
I
M
E