

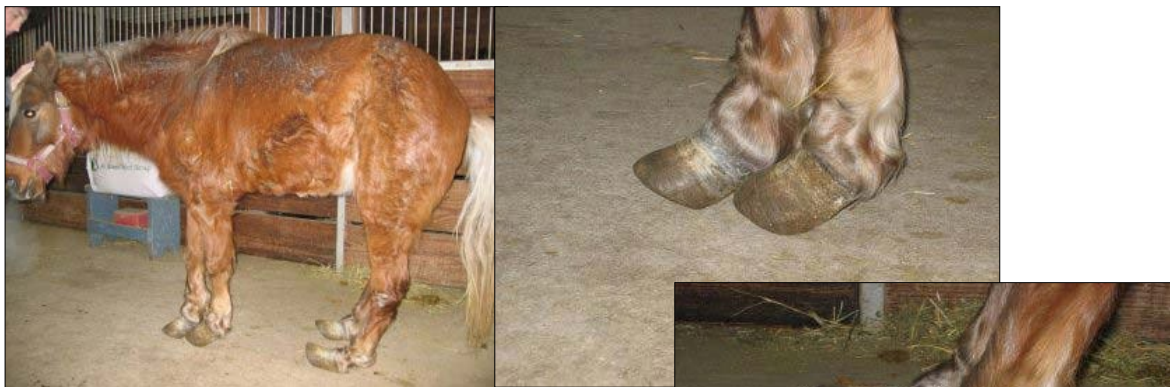

The Seemingly Impossible

Following are just two examples of rehabilitation that seemed to be impossible, there are many examples where well trained and experienced hoof trimmers perform such "miracles".

This pony had difficulty standing and walking before she was trimmed; she was severely foundered. She also had bedsores on her flanks. The before trim x-rays showed severe coffinbone destruction. Approximately 1/2 of the coffin bone was destroyed due to the chronic founder.

Case submission courtesy of Fisher Equine Lameness Foundation, Minnesota



Below: Same pony as on previous pictures, about 1 year later



U
N
O

A
L
L
A

V
O
L
T
A

—

O
N
E

A
T

A

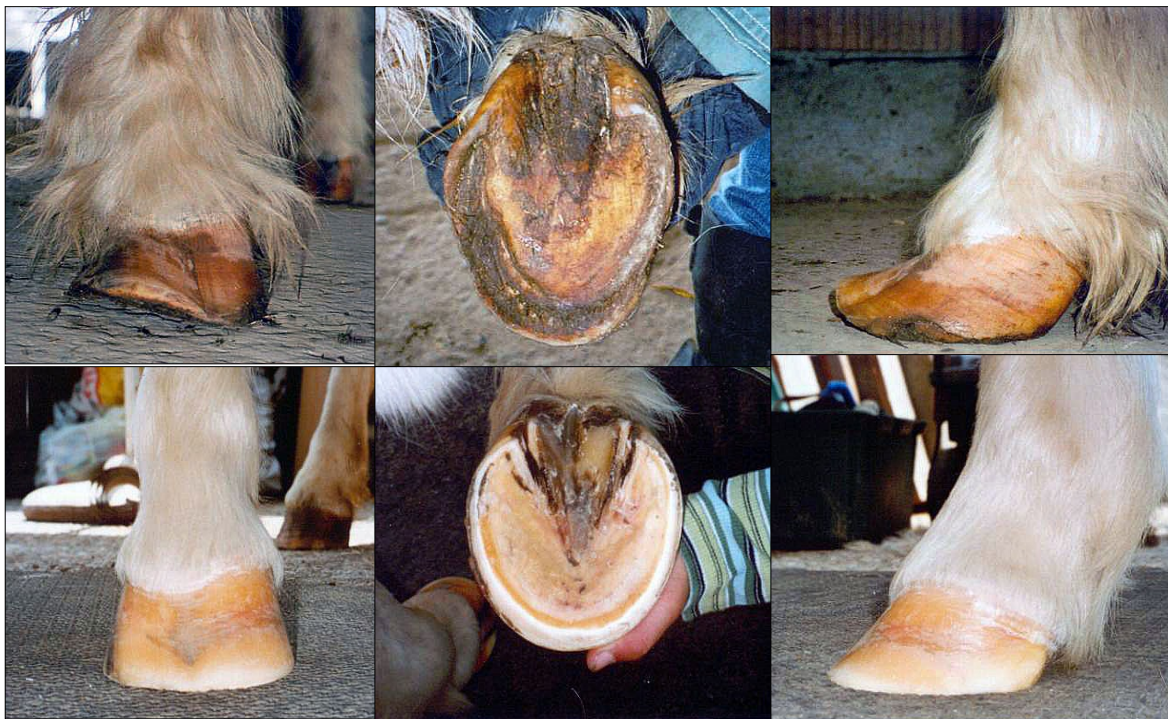
T
I
M
E



This case study was submitted by a German Association
(Deutsche Huforthopaedische Gesellschaft e.V.)
Stella, ca. 30 - 40 years old, former circus pony



Pony Stella below top row February 2005,
below bottom row August 2005



U
N
O

A
L
L
A

V
O
L
T
A
—

O
N
E

A
T
A

T
I
M
E