

## Guideline

# Stabilisation and transfer of an infant with Myelomeningocele

## 1 Scope

For use within the Paediatric and Neonatal Decision support and Retrieval service for the East of England.

## 2 Purpose

To provide safe, efficient and practical guidance for the management of neonates with Myelomeningocele during stabilisation and transfer.

## 3 Definitions and abbreviations

AFP	Alphafetoprotein
Anencephaly	absence of a major portion of the brain, skull and scalp that occurs during embryonic development when the rostral (head) end of the neural tube fails to close at or near the tail or posterior part of the body
Caudal	at or near the tail or posterior part of the body
CSF	cerebral spinal fluid
Encephalocele	a NTD characterized by sac-like protrusions of the brain and the membranes that cover it through openings in the skull
Foramen Magnum	hole in the base of the skull through which the spinal cord passes
NTD	neural tube defect
Kyphosis	excessive outward curvature of the spine
Scoliosis	abnormal lateral curvature of the spine

## 4 Introduction

The fetal nervous system starts as a single structure called the neural plate. By the 28th day after conception the neural plate should fold over and close to form the neural 'tube'. Failure of the complete closure of the neural tube results in a NTD, of which there are several types: anencephaly, spina bifida and encephalocele.

The types of spina bifida include (see figure 1):

- 1) Spina Bifida Occulta - This is a mild form of spina bifida in which the spinal cord and the surrounding structures remain inside the baby, but the lower vertebral bones fail to form normally. There may be a hairy patch, dimple, or birthmark over the area of the defect. Other times, there may be no abnormalities in the area.
- 2) Meningocele - This is a moderate form of spina bifida where the spinal cord develops normally but the meninges protrude from a spinal opening.
- 3) Spina Bifida Aperta or Myelomeningocele - This is the most serious and common form of the disease, accounting for approximately 75% of cases. With this form of spina bifida, a part of the baby's meninges, CSF, spinal cord and/ or nerve roots protrude through a defect in the vertebral arches. This appears as a flat disc or sac on the baby's back. Myelomeningocele occurs in approximately six per 10,000 births and will be the focus of this guideline.

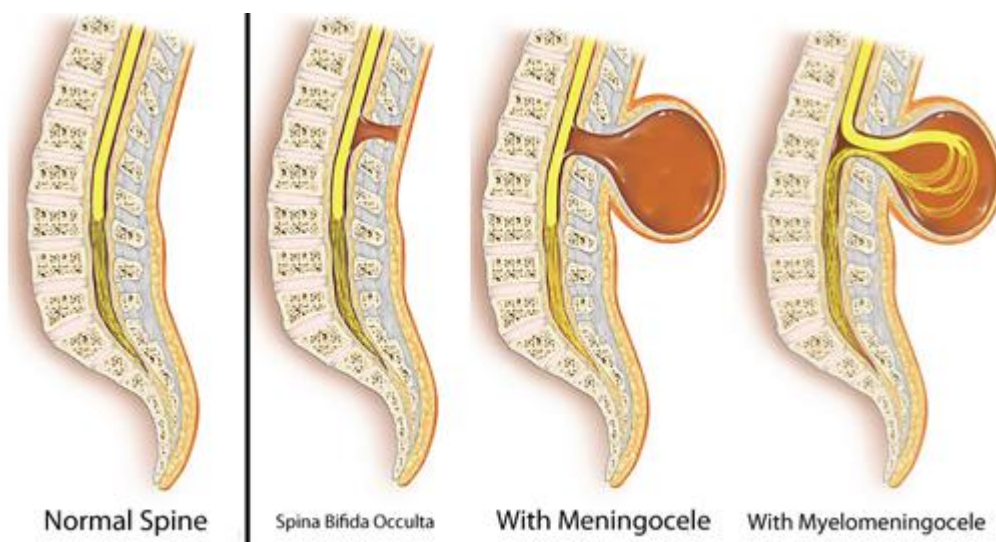


Figure 1: Classification of spina bifida

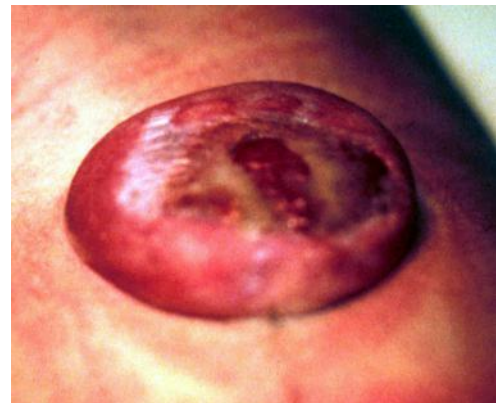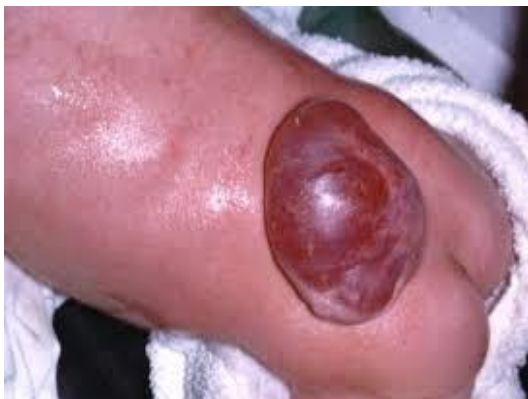Myelomeningoceles can occur anywhere along the spinal cord but are most commonly found in the lumbar and sacral areas. They cause variable paralysis and sensory loss caudal to the lesion, with secondary deformity, neurogenic bladder and bowel dysfunction.

It should be considered an emergency as without the protective covering of skin, the spinal cord may become further damaged, spinal fluid often leaks from the area and there is a very high risk of infection. Surgery is usually recommended within the first few days of life. Prognosis depends on the level of the lesion, involvement of neural tissue in the defect, ascending infection, and the presence of other structural defects.

The aetiology of neural tube defects is not fully understood but we know that maternal folic acid supplementation can reduce the risk of them occurring. Periconceptional folate supplementation reduces the incidence of first NTD by >50%. Chromosomal abnormalities including trisomy 13 & 18 and genetic mutations in the folate and homocysteine metabolism pathways have been associated.

## **5 Diagnosis**

Myelomeningoceles are usually antenatally diagnosed: Alpha-fetoprotein (AFP) is a plasma protein produced by the developing fetus. Elevated AFP from amniotic fluid is very reliable unless the defect is closed. Maternal plasma AFP is less reliable, detecting only 50-90% of open anomalies, and is falsely positive in 5%. Fetal anomaly scanning at 20 weeks will show characteristic appearances including lateral displacement of the spinal peduncles, or the myelomeningocele may be visualised. Postnatal diagnosis is usually straightforward by noting the protrusion of the sac (see photo 1 and 2).



**Photo 1 & 2: Newborn babies with myelomeningoceles**

## 6 Clinical features

At birth the infant is usually stable unless there are signs of lower brainstem dysfunction, which can lead to central apnoea. Depending on the level of the lesion, examination findings may include a distended bladder and motor/sensory disturbances.

The lesion will be noted in the midline anywhere along the spine, and may appear like a disc or sac as demonstrated in photo 1 and 2. The meningeal sac may be intact or leaking CSF.

## 7 Associated problems

The opening in the spinal cord results in loss of the fluid surrounding the nervous system. This causes the brain to be positioned further down into the upper spinal column than normal, which is called a Chiari II malformation. When this happens, the normal flow of fluid out of the brain is obstructed, causing hydrocephalus, an excess of cerebrospinal fluid within the brain.

### 7.1 Arnold chiari II malformation

This is present in almost all children with myelomeningocele. It mainly affects the lower part of the brain, but the anatomy of the whole brain is affected. Many of the nerves that control the heart, breathing and blood pressure, and help to control swallowing, sneezing and coughing can be involved.

The brainstem is elongated and displaced downwards through the foramen magnum and into the top of the spinal canal. It is often kinked. The brainstem, cranial nerves and lower portion of the cerebellum (back of the brain) may be stretched or compressed. This means that any of the functions controlled by these areas may be affected.

Many people with Arnold Chiari malformation have no obvious symptoms. In babies, the most common symptoms are a weak or absent cry, stridor (noisy breathing), arching of the neck, breathing problems, colour change, failure to thrive and feeding or swallowing difficulties.

### 7.2 Hydrocephalus

The circulation of cerebrospinal fluid (CSF) is often disturbed in children with myelomeningocele as a result of obstruction. Either at birth or in the days and weeks following surgery, fluid may start to build up within the brain leading to hydrocephalus.

If this occurs, an operation to place a shunt tube to divert the excess fluid from the brain to the abdomen is needed. This operation is needed in about 60 per cent of children with myelomeningocele.

### 7.3 Orthopaedic abnormalities

Orthopaedic abnormalities secondary to disrupted muscle innervation (eg dislocated hips and talipes) are common. There may be an associated spinal deformity – scoliosis or kyphosis.

## 8 Stabilisation and management during transfer

- Immediate care after birth involves the prevention of local infection and trauma by careful handling and positioning of the infant.
- Manage the airway, breathing and circulation as any other baby although cardio-respiratory support is not usually required.
- Nurse in the lateral or prone position avoiding direct pressure on the lesion. The lesion can then be inspected for size, location and to check for leaking.
- Handle the infant with sterile, non-latex gloves (babies with Spina Bifida are at high risk of latex allergy through repeated exposure to latex)
- Ideally ask clinical photography to take a photo with consent before a dressing is applied to minimise the need for repeated examinations.
- The sac must be kept covered and moist prior to closure so apply a sterile moist dressing to the membranous sac (gauze soaked in sterile 0.9% saline), apply a dry layer of gauze over the top and then cover with clingfilm.
- Maintain Nil by mouth, on IV fluids until a neurosurgical plan is in place.
- Avoid faecal contamination if possible.
- Full neurological examination should be performed as part of the initial assessment.
- Consider early cranial ultrasound if concerns regarding hydrocephalus.
- Assess for signs of urinary retention- palpation/ bladder scan. Infants with urinary retention will require urinary catheterisation.
- IV antibiotics should be given to infants with open lesions i.e. when there is broken skin or evidence of CSF leak. Babies with closed lesions may also require antibiotics if there are risk factors for early neonatal sepsis.

## 9 Monitoring compliance with and the effectiveness of this document

The effectiveness of the document will be monitored by review of any reported incidents via the lead nurse for risk. These incidents will be shared with the team and consideration given to adjusting the guideline if concerns are identified.

## 10 References

K Burke and S Barr January 2014- Cardiff NICU guideline

Boyd PA et al. Monitoring the prenatal detection of structural fetal congenital anomalies in England and Wales: register-based study. Journal of Medical Screening 2011; 18(1):2.

<https://london-nts.nhs.uk/wp-content/uploads/2015/01/Myelomeningocele-NTS-Guideline.pdf>

<http://www.gosh.nhs.uk/medical-information/myelomeningocele>

## Equality and diversity statement

This document complies with the Cambridge University Hospitals NHS Foundation Trust service equality and diversity statement.

## Disclaimer

It is **your** responsibility to check against the electronic library that this printed out copy is the most recent issue of this document.

## Document management

Approval:	PaNDR Consultants		
JDTC approval:	n/a		
Owning department:	PaNDR		
Author(s):	Julia Arthur		
Pharmacist:	n/a		
File name:	Stabilisation and transfer of an infant with Myelomeningocele V2 March 2022		
Supersedes:	Stabilisation and transfer of an infant with Myelomeningocele V1 August 2018		
Version number:	1	Review date:	March 2025
Local reference:		Document ID:	100899