

Exhibit 261

People Died from mRNA-Vaccine-Damaged Hearts, New Peer-Reviewed German Study Provides Direct Evidence

<https://www.zerohedge.com/covid-19/people-died-mrna-vaccine-damaged-hearts-new-peer-reviewed-german-study-provides-direct>

German Study: “Autopsy-based histopathological characterization of [myocarditis](#) after anti-SARS-CoV-2-vaccination”

<https://link.springer.com/article/10.1007/s00392-022-02129-5>

People Died From mRNA-Vaccine-Damaged Hearts, New Peer-Reviewed German Study Provides Direct Evidence

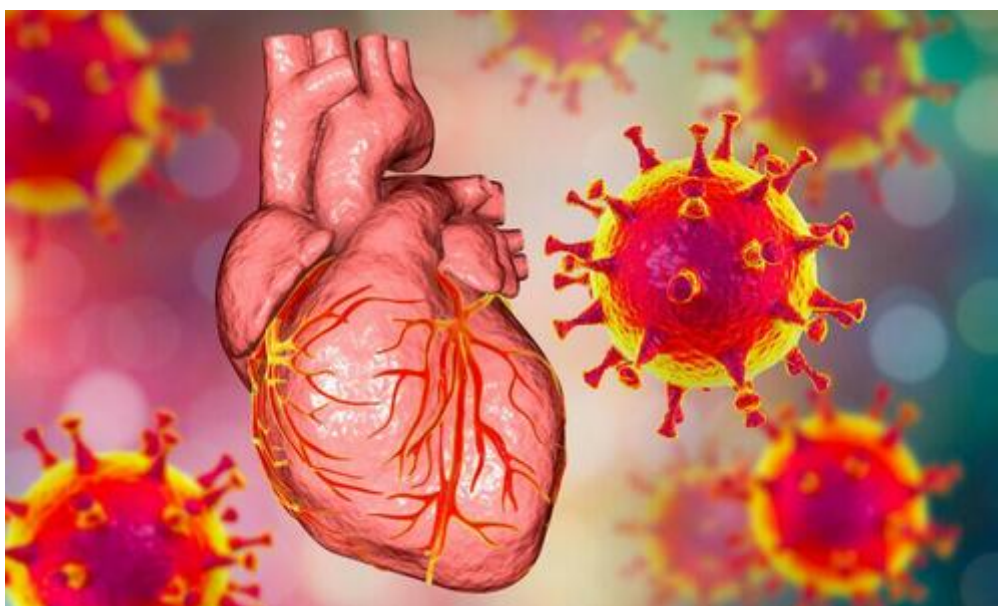


BY TYLER DURDEN

THURSDAY, DEC 15, 2022 - 12:30 AM

Authored by Jennifer Margulis and Joe Wang via [The Epoch Times](#) (emphasis ours),

Medical pathologists from Heidelberg University Hospital in Heidelberg, Germany have [published direct evidence showing how people found dead after mRNA vaccination died](#). As this team of six scientists explore in their study, **these mRNA-vaccinated patients suffered from [heart](#) damage because their hearts were attacked by their own immune cells**. This autoimmune attack on their own heart cells then leads to their damaged hearts beating so many times per second that, once the tachycardia unexpectedly started, they died in minutes.



mRNA vaccines cause myocarditis by leading your own immune cells to attack your heart, which can lead to sudden death by ventricular tachycardia or fibrillation. (Kateryna Kon/Shutterstock)

The article, “Autopsy-based histopathological characterization of [myocarditis](#) after anti-SARS-CoV-2-vaccination,” was published on Nov. 27, 2022, in the journal *Clinical Research in Cardiology*, the official journal of the German Cardiac Society. The research team autopsied 25 victims of different ages who were found dead at home within 28 days of vaccination. They looked at their heart tissue under the microscope to find out why these people died of cardiac rhythmic disruption when they had no apparent underlying heart disease.



On a long enough timeline the survival rate for everyone drops to zero.

told his audience: “This is peer-reviewed. This is proper science, and a definitive pathological diagnosis by a group of leading German pathologists.” Campbell’s video has been viewed 918,000 times. He has 2.58 million subscribers on his channel.

Died of Ventricular Tachycardia or Fibrillation

Ventricular tachycardia is when the heart begins beating so fast that it doesn’t have time to refill with blood between beats, so it is not adequately pumping blood. The problem originates from the ventricles: the chambers that push the blood out of the heart to the rest of the body.

Fibrillation is when, instead of the heart actually beating, it starts to just quiver. This problem can originate from the ventricles or the atria. The atria are the upper chambers that basically suck blood into the heart by expanding and contracting. Though more people are familiar with A-Fib (atrial fibrillation), ventricular fibrillation is much more dangerous, and usually lethal within minutes.

The deceased whose hearts were autopsied in this study were [found dead at home](#), each having died of ventricular tachycardia or fibrillation within 28 days of [mRNA vaccination](#).

Visibly Damaged Hearts

Macrophages are large cells that are part of our immune system. When the immune system is functioning properly, our bodies use macrophages to attack infectious agents and other foreign matter. Macrophages are a key part of the innate immune system, helping with normal tissue development as well as with repairing damaged tissue, [according to researchers from Northwestern University](#).

But in the case of the people who died suddenly within a month of being vaccinated, the body’s own macrophages permeated their heart muscle, chewing up the muscle and causing spots that disrupted the heart rhythm. This macrophage invasion appeared to have literally short-circuited the heart’s conduction of the electrical impulses, causing the heart to beat irregularly.

The irregular heartbeats led to a negative feedback loop, making the heart race faster and faster as it tries to right itself. When that happens, the heart is effectively pumping no blood, and the victim dies within seconds or minutes unless there is a defibrillator nearby—to deliver an electrical shock to the heart to help it get back into rhythm—and someone knows to use it immediately.

The [peer-reviewed study](#) from German researchers included microscope images showing the damage to the victims’ heart cells, the presence of lymphocytes (another kind of smaller immune cell) in the heart muscle, and invasive macrophages in the heart muscle. Both macrophages and lymphocytes called T-helper cells were found in the heart tissue. The immune cells were concentrated in spots, each of which is called a focus. Spots of [damaged](#) heart tissue like this can generate offbeat signals that disrupt the heart’s smooth rhythm.

There are thousands of cardiac cells in the heart. These cells aren’t passive, like the cells in your biceps that need separate nerves to make them move. Instead, cardiac cells generate their own electrical impulses.



On a long enough timeline the survival rate for everyone drops to zero.

Myocarditis: A Recognized Vaccine Adverse Event

The WHO and the CDC do [recognize myocarditis post-mRNA vaccination](#). Both regulatory agencies consider it a “recognized but rare complication.” Most doctors also dismiss myocarditis cases as “mild.”

But the deceased subjects of the German study, as [Campbell points out](#), also had supposedly “mild” myocarditis. The myocarditis appeared only in microscopic spots here and there. However, the electrical disruption of these spots caused rapid and dramatic deaths. In other words, [there is no mild myocarditis](#), as one parent of an [mRNA-vaccine-injured teen](#) named Aiden Ekanayake, said.

Campbell recommended that clinicians have a “high index of suspicion” that mRNA-vaccinated people might be subject to this autoimmune myocarditis so that they can diagnose and treat it while the people are still alive. Clinicians pretending that this vaccine injury is “rare and mild,” has led to [countless potentially avoidable tragedies](#).

Your Body Attacking Your Own Heart Cells

To be clear, this is not the mRNA vaccine directly damaging the heart—it is worse. The mRNA is injected into your muscle cells, turning the cell into a factory producing COVID-19 spike proteins.

As a result of the mRNA immunization, your body generates an immune response against COVID-19 spike proteins.

Since your own muscle cells were used to make the COVID-19 spike proteins and may have them on the cell surface, your newly-weaponized immune cells targeting the spike protein may start attacking your own healthy muscle cells.

This new German study shows photographic evidence that this happens and has killed people.

Correlation or Causation?

An [original investigation published earlier](#) this year in the Journal of the American Medical Association found that there were many cases of myocarditis in unexpected populations, especially in [boys and young men, following mRNA vaccination](#).

Sir Austin Bradford Hill was an English medical statistician who established a set of epidemiological guidelines in 1965, now called the [Bradford Hill criteria](#), which help prove cause and effect. If we apply the Bradford Hill criteria to this new research, it shows that the lethal myocarditis of these [patients](#) was indeed caused by mRNA vaccines. The German research demonstrated Bradford Hill’s criteria of strength (the more two things happen at the same time, the more likely one causes the other, even for rare events); consistency (the finding of [sudden death](#) from mRNA-vaccine-induced myocarditis has been [happening consistently in different places](#) and [populations](#)); specificity (for Bradford Hill, this is when a single cause produces a single effect. In this case the cause is the mRNA vaccine and the effect is myocarditis); and several more.

Read more [here...](#)



On a long enough timeline the survival rate for everyone drops to zero.

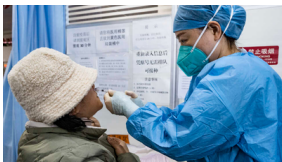MORE COVID-19 STORIES ON ZEROHEDGE



[Canadian Government Tells Kids They'll Be On Santa's 'Naughty List' Without COVID Vaccine, Masks](#)



[New Jersey School District Reinstates COVID Mask Mandate](#)



[After Loosening COVID Restrictions, China Mandates Hospitals To Take Regular Virus Samples To Monitor Mutations](#)

DISCRIMINATION NOTICE

PRIVACY POLICY

DISCLAIMER

ADVERTISE WITH ZEROHEDGE

COPYRIGHT ©2009-2022 ZEROHEDGE.COM/ABC MEDIA, LTD



Autopsy-based histopathological characterization of myocarditis after anti-SARS-CoV-2-vaccination

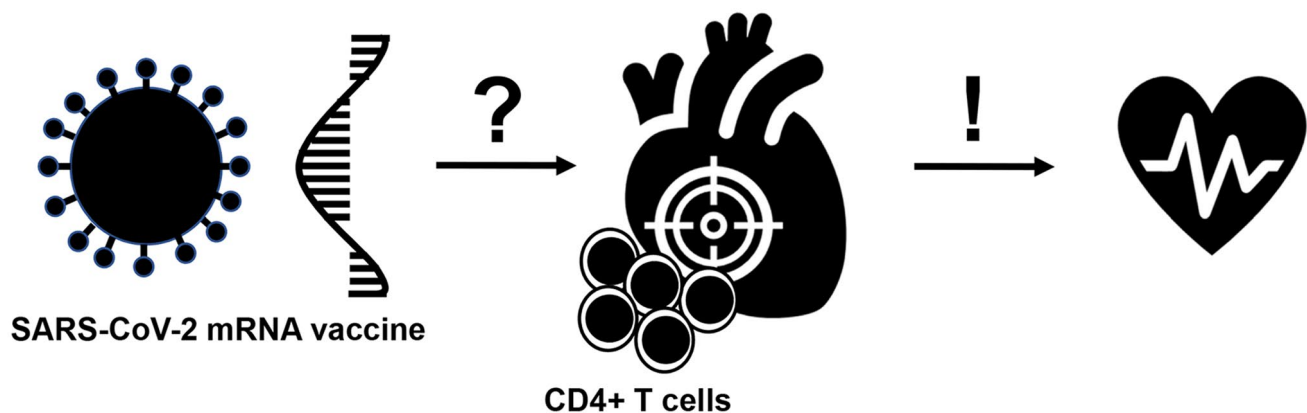
Constantin Schwab¹ · Lisa Maria Domke^{1,2} · Laura Hartmann^{1,2} · Albrecht Stenzinger¹ · Thomas Longerich¹ · Peter Schirmacher¹

Received: 22 July 2022 / Accepted: 17 November 2022
© The Author(s) 2022

Abstract

Cases of myocarditis, diagnosed clinically by laboratory tests and imaging have been described in the context of mRNA-based anti-SARS-CoV-2 vaccination. Autopsy-based description of detailed histological features of vaccine-induced myocarditis is lacking. We describe the autopsy findings and common characteristics of myocarditis in untreated persons who received anti-SARS-CoV-2 vaccination. Standardized autopsies were performed on 25 persons who had died unexpectedly and within 20 days after anti-SARS-CoV-2 vaccination. In four patients who received a mRNA vaccination, we identified acute (epi-) myocarditis without detection of another significant disease or health constellation that may have caused an unexpected death. Histology showed patchy interstitial myocardial T-lymphocytic infiltration, predominantly of the CD4 positive subset, associated with mild myocyte damage. Overall, autopsy findings indicated death due to acute arrhythmogenic cardiac failure. Thus, myocarditis can be a potentially lethal complication following mRNA-based anti-SARS-CoV-2 vaccination. Our findings may aid in adequately diagnosing unclear cases after vaccination and in establishing a timely diagnosis in vivo, thus, providing the framework for adequate monitoring and early treatment of severe clinical cases.

Graphical abstract



Keywords Autopsy · SARS · Cardiac pathology · Myocarditis · Vaccination

Thomas Longerich and Peter Schirmacher are contributed equally to this work.

✉ Peter Schirmacher
peter.schirmacher@med.uni-heidelberg.de

Extended author information available on the last page of the article

Introduction

Between December 2020 and March 2021, the European Medicines Agency approved several vaccines on the basis of randomized, blinded, controlled trials: two messenger RNA-based vaccines—Comirnaty, BNT162b2

(Pfizer–BioNTech) and Spikevax, mRNA-1273 (Moderna)—both encoding the spike protein of SARS-CoV-2 encapsulated in lipid nanoparticles as the antigen and two vaccines based on recombinant adenoviruses (Vaxzevira, ChAdOx1 nCov-19 (AstraZeneca), a recombinant chimpanzee adenoviral vector encoding the spike glycoprotein of SARS-CoV-2 and Ad26.COV2.S (Johnson & Johnson/Janssen), a recombinant adenovirus type 26 vector encoding SARS-CoV-2 spike glycoprotein. Recently, the first adapted bivalent COVID-19 booster vaccines targeting Omicron subvariants (BA.1 and BA.4-5, respectively) were authorized across the European Union (EMA/H/C/005735: Comirnaty Original/Omicron BA.1, Comirnaty Original/Omicron BA.4-5; EMA/H/C/005791: Spikevax bivalent Original/Omicron BA.1).

As vaccines may cause adverse events (AEFI), it is crucial to record them systematically and assess them for causality both at the population and at the individual level, as proposed by the World Health Organization (WHO) [1]. Detailed analyses should aim to establish or rule out a causal link between vaccination and the event in question. Autopsy is an important measure to identify severe adverse effects and to provide important mechanistic data in this setting. It may allow to identify the population at risk and may help to develop algorithms for prevention or monitoring, facilitating early diagnosis and successful treatment.

Cases of (epi-)myocarditis have previously been documented after immunization against smallpox or influenza in the vaccine adverse events reporting system [2, 3]. Recently, unusual cases of (epi-)myocarditis after vaccination with mRNA-based anti-SARS-CoV-2-vaccines have been documented [4]. These were clinically observed and diagnosed by laboratory and cardiac magnetic resonance imaging, predominantly in males under 30 years of age [5–8]. Available short-term follow-up data suggest resolution of symptoms [5–7]. However, few individuals required intensive care support or even died from acute heart failure. Information about potential long-term health outcomes is not yet available. Verma et al. reported two cases of myocarditis after mRNA vaccination, one of them fatal, revealed by endomyocardial biopsy and autopsy respectively [9]. Histology showed an inflammatory infiltrate predominantly composed of T-cells and macrophages, admixed with eosinophils, B-cells and plasma cells. By reporting similar observations based on different diagnostic techniques (e.g. cardiac magnetic resonance imaging, endomyocardial biopsy), the causality of an AEFI can be assessed at the population level [1]. However, in most of these studies comprehensive testing for infectious agents, crucial for the assessment of an AEFI at the individual level, was not reported. As a consequence, a systematic description with histopathological phenotyping as well as molecular analysis of (epi-)myocarditis after anti-SARS-CoV-2-vaccination is still lacking.

Here, we describe the cardiac autopsy findings in five persons who have died unexpectedly within seven days following anti-SARS-CoV-2-vaccination, with vaccine-induced myocardial inflammation representing the likely or possible cause of death. Our findings establish the histological phenotype of lethal vaccination-associated myocarditis.

Materials and methods

Data on autopsies of persons, who received anti-SARS-CoV-2 vaccination (up to 20 days before their death), were obtained from the COVID autopsy and biomaterial registry Baden-Württemberg. This federal state registry contains autopsy, clinical and pathological data as well as tissue samples from patients who have died in the context of a SARS-CoV-2 infection or persons who have died briefly after an anti-SARS-CoV-2 vaccination ($n = 54$). All autopsies were performed at one of the five University hospital sites (Heidelberg, Tübingen, Freiburg, Ulm, Mannheim) of Baden-Württemberg. The network cooperates with prosecution and the forensic pathology as well as with other national networks such as the German Center for Infection Research (DZIF), the German Center for Lung Research (DZL), and the national academic research network NUM (Network of University Medicine; DEFEAT PANDEMIcs); results are constantly reported to the Paul Ehrlich Institute (PEI), the German Federal Institute for Vaccines and Biomedicines. In this study, all and only autopsies performed at Heidelberg University Hospital ($n = 35$) were included to ensure that all medical documents and findings were available and that the autopsies were performed according to the standardized procedure described previously [10]. The hearts were examined macroscopically by measuring the weight and the thickness of the left, right and interventricular walls. Coronary arteries were dissected from their aortic branching to the periphery to allow for evaluation of arteriosclerosis and exclusion of thrombi. Afterwards, the inflow and outflow tracts were examined, the ventricles were cross-sectioned in short axis (transversal plane) at 1 cm intervals from the valves to the apex and the cut surfaces were examined for focal lesions (or geographic demarcations), a focussed dissection and detailed histological evaluation of the cardiac conduction system was not performed.

For histological evaluation, all tissue samples were fixed in 4% neutral-buffered formalin. At least two full-thickness blocks from the left and right ventricular wall, the interventricular septum, and the papillary muscles were taken for histological evaluation of cardiac pathologies. From formalin-fixed, paraffin-embedded (FFPE) tissue-blocks at least two sections with a thickness of 4 μm were stained with hematoxylin & eosin, periodic acid Schiff (PAS) reaction, and acid fuchsin orange G (AFOG), respectively.

Immunohistochemical stainings were performed according to standard protocols. In brief, immunohistochemistry was performed on an automated immunostainer (Ventana BenchMark Ultra, Ventana Medical Systems, Tucson, USA). Sections were cut, deparaffinized, rehydrated and pre-treated with an antigen retrieval buffer (Tris/Borat/EDTA, pH 8.4). After blocking of endogenous peroxidase, the slides were incubated with monoclonal antibodies directed against CD3 (clone 2GV6, Roche, Rotkreuz, Switzerland), CD4 (clone SP35, Roche), CD8 (clone SP57, Roche), CD20 (clone L26, Roche), GATA 3 (clone L50-823, Roche, Rotkreuz, Switzerland) and D2-40 (clone Roche, Rotkreuz, Switzerland) at the provided dilutions of the ready-to-use-kits, CD68 (clone PgM1, Agilent/Dako, Santa Clara, United States) at a dilution of 1:100, FOXP3 (clone D2W8ETM, Cell iSignaling Technology, Danvers, MA, United States) at a dilution of 1:25, and Tbet (clone 4B10, Santa Cruz Biotechnology Inc., Santa Cruz, CA, United States) at a dilution of 1:50 followed by incubation with OptiView Universal Linker and OptiView HRP Multimer. Visualization was achieved using DAB as chromogen. Before mounting, slides were counterstained with haematoxylin. Histological and immunohistological findings were analysed in synopsis with available data from the patients' medical records. Three age- and sex-matched cohorts from our autopsy files (covering the years 2005/2006, 2010/2011 and 2015/2016) were retrieved and the myocardial samples were evaluated for the presence and phenotype of inflammatory infiltrates.

Based on the Dallas criteria and the specifications according to Caforio et al. myocarditis was defined by an inflammatory infiltrate with ≥ 14 leucocytes/mm² including up to 4 monocytes/mm² with the presence of CD3 positive T-lymphocytes ≥ 7 cells/mm² and signs of myocyte degeneration and necrosis of non-ischaemic origin [11, 12]. Myocardial and epicardial infiltration was assessed semiquantitatively

by visual scoring using a four-tiered system (0–3): score 0 (no foci of inflammation), score 1 (focal, isolated foci with up to 20 leucocytes/mm²), score 2 (focal, > 20 leucocytes/mm²), and score 3 (diffuse infiltration). Regarding potential causative infectious agents, FFPE samples of all cases and fresh frozen myocardial samples of cases 1, 3, 4 and 5 were tested for viral and bacterial genomes by a diagnostic panel with (reverse transcription) PCR (Enteroviruses, parvovirus B19, human herpesvirus 6, Epstein–Barr virus, human cytomegalovirus, varicella zoster virus, herpes simplex virus type 1 and 2, human herpesvirus 7, adenoviruses, borrelia spp., Toxoplasma gondii). For each sample, 350 ng of total nucleic acid was extracted and subjected to nested (RT)-PCR using in-house techniques as described by Mahfoud et al. [13]. Glyceraldehyde-3-phosphate dehydrogenase (GAPDH) RT-PCR served as an internal control for both nucleic acid extraction and PCR amplification.

The likelihood of vaccine-induced (epi-)myocarditis was categorized according to the criteria detailed in Table 1.

Results

Among the 35 cases of the University of Heidelberg, autopsies revealed other causes of death (due to pre-existing illnesses) in 10 patients (Supplementary Table 1). Hence, these were excluded from further analysis. Cardiac autopsy findings consistent with (epi-)myocarditis were found in five cases of the remaining 25 bodies found unexpectedly dead at home within 20 days following SARS-CoV-2 vaccination. Main characteristics of the five cases are presented in Table 2, while further autopsy findings are shown in Supplementary Table 2. Three of the deceased persons were women, two men. Median age at death was 58 years (range 46–75 years). Four persons died after the first vaccine jab,

Table 1 Likelihood assessment of vaccine-induced (epi-)myocarditis

category	Criteria
No vaccine-induced myocarditis	- Absence of myocarditis OR - Myocarditis without temporal association to vaccination event OR - Myocarditis, definitely explained by other, especially infectious diseases defined by histological/microbiological/virological testing of cardiac tissue
Possible vaccine-induced myocarditis	- Presence of myocarditis with temporal association to vaccination event, but presence of mitigating factors (e.g. detection of facultatively pathogenic infectious agents) OR - Presence of pericarditis with temporal association to vaccination event, but myocardial findings insufficient to establish definite myocarditis (e.g. Dallas criteria)
Likely vaccine-induced myocarditis	- Presence of myocarditis with temporal association to vaccination event AND - Integration of histological phenotype, clinical presentation, and laboratory findings indicate no alternative differential diagnosis

Table 2 Case characteristics

Case	Gender	Age	BMI	Vaccine type	Dose	Time from vaccination to death (days)	Time from death to autopsy (days)	Comorbidity	Grading – myocarditis (0–3)	Grading – epicarditis (0–3)	PCR analysis	Assessment of causal relationship
1	male	46	31.8	Cormirmaty (BioNTech)	First	0	7	AH	2	0	Negative	Likely
2	female	50	20	Spikevax (Moderna)	First	1	3	-	1	2	Negative	Likely
3	female	62	22.5	Cormirmaty (BioNTech)	First	7	3	COPD	1	1	Negative	Possible
4	male	55	30.1	Cormirmaty (BioNTech)	Second	4	3	-	2	3	Negative	Likely
5	female	75	27.9	Cormirmaty (BioNTech)	First	1	9	AH, DM, Hashimoto's thyroiditis	2	2	HHV6	Possible

Abbreviations: AH arterial hypertension, COPD chronic obstructive pulmonary disease, DM diabetes mellitus

the remaining case after the second dose. All persons died within the first week following vaccination (mean 2.5 days, median 2 days). Clinical findings, blood tests, ECGs or imaging data were not available as deceased persons did not seek medical attention prior to death. Person 1 was found dead 12 h after the vaccination. A witness described a rattling breath shortly before discovering circulatory failure. Person 2 complained about nausea and was found dead soon thereafter. Resuscitation was started immediately but without success, respectively. The other persons were found dead at home without available information about terminal symptoms. According to the available information provided at the time of autopsies, none of the deceased persons had SARS-CoV-2 infection prior to vaccination and nasopharyngeal swabs were negative in all cases.

Histological examination showed inflammatory infiltration of the myocardium. The infiltrate was focal and interstitial in all cases. It was predominantly detected in sections taken from the right ventricular wall and interventricular septum. The histological and immunohistochemical characterization revealed that the inflammatory infiltrate was predominantly composed of lymphocytes. The number of CD3-positive T-cells by far outnumbered the few CD20-positive B-cells detected. In addition, most T-cells belonged to the CD4-positive subset, while only scattered CD8-positive T-cells were seen (Fig. 1, 2, Supplementary Fig. 1/2). The T cells were negative for Tbet as a marker for Th1 cells, GATA3 as a marker for Th2 cells, D2-40, as a marker for Th17 cells (Supplementary Fig. 2). In addition, FOXP3 positive regulatory T cells and CD21 positive follicular dendritic cells were not detected within the cardiac infiltrates, while control cases, including cases of sarcoidosis were positive (Supplementary Fig. 2/3). Immunohistochemistry for CD68 showed few interspersed histiocytes (Fig. 2, Supplementary Fig. 1). Microfocal myocyte injury was demonstrable in three cases (patient 1, 2 and 3). No granulomas were found. All cases lacked significant coronary heart disease, acute or chronic manifestations of ischaemic heart disease, manifestations of cardiomyopathy or other signs of a pre-existing, clinically relevant heart disease.

In most cases, an inflammatory infiltration of the epicardium and the subepicardial fat tissue was concomitantly found (cases 2, 3, 4 and 5; Supplementary Fig. 4) and revealed an identical immunophenotype. (T-cell dominant; CD4 >> CD8). In case 2, a prominent CD4-positive lymphocytic infiltration was also recorded at the jab site of the deltoidal muscle (Fig. 3). Analysis for potential infectious agents causing a myocarditis revealed low viral copy numbers of human herpes virus 6 (HHV6) in one case (case 5). The results of the other four cases were negative for all infectious agents tested, but demonstrated regular amplification of the GAPDH control suggesting adequate nucleic acid quality for analysis.

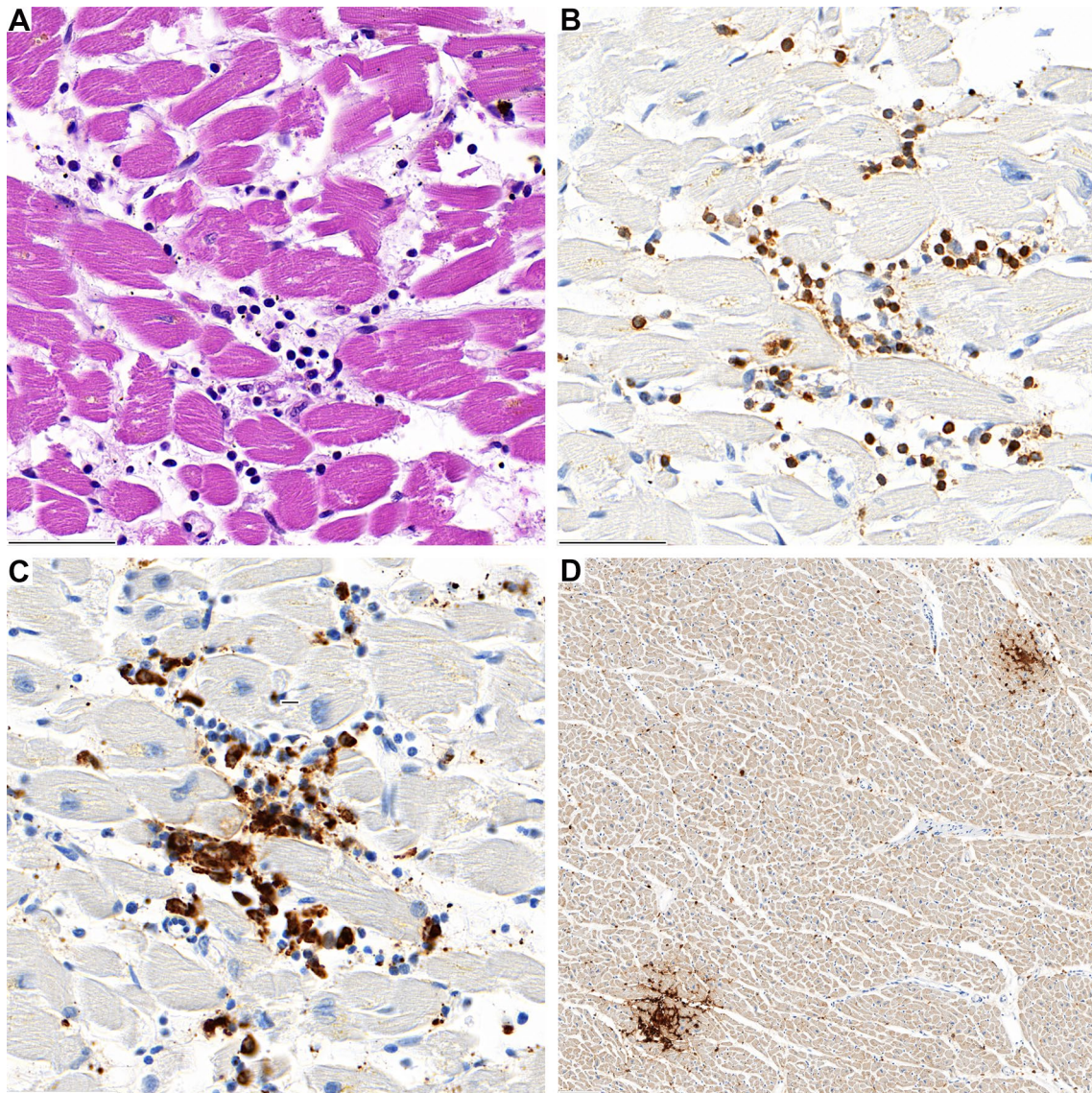


Fig. 1 **A** Lymphocytic aggregates in the interventricular septum of case 1 with associated myocardiocyte destruction. **B** The infiltrate is predominantly composed of CD3-positive T-lymphocytes and **C**

CD68-positive macrophages. **D** In lower magnification two foci of CD4-positive lymphocytes are evident (**D**)

In three cases, the overall autopsy findings, in particular presence of (epi-)myocarditis in combination with the absence of other plausible causes of death (especially pulmonary embolism, myocardial infarction, severe brain infarction or bleeding, other cardiac disease), together with the close temporal association with the vaccination event lead to the conclusion that vaccination was the likely cause of (epi-)myocarditis and that this cardiac affection was the cause of sudden death. For case 5, myocarditis was considered to be the cause of death as well, but the detection of HHV6, even in low viral copy numbers provided an alternative explanation for the presence of myocarditis. With regard to the question of a fatal AEFI, case 5 was therefore

classified as “possible”. For case 3 no other cause for the inflammatory infiltration was found, but the infiltrate was discrete and mainly observed in the pericardial fat. Thus, case 3 was categorized as possible AEFI as well. We did not find an obvious association between the infiltrates and endothelial cells (CD31, D2-40), mesothelial cells (calretinin), or neural cells (S100). During the last 20 years of autopsy service at Heidelberg University Hospital we did not observe comparable myocardial inflammatory infiltration. This was validated by histological re-evaluation of age- and sex-matched cohorts from three independent periods, which did not reveal a single case showing a comparable cardiac pathology.

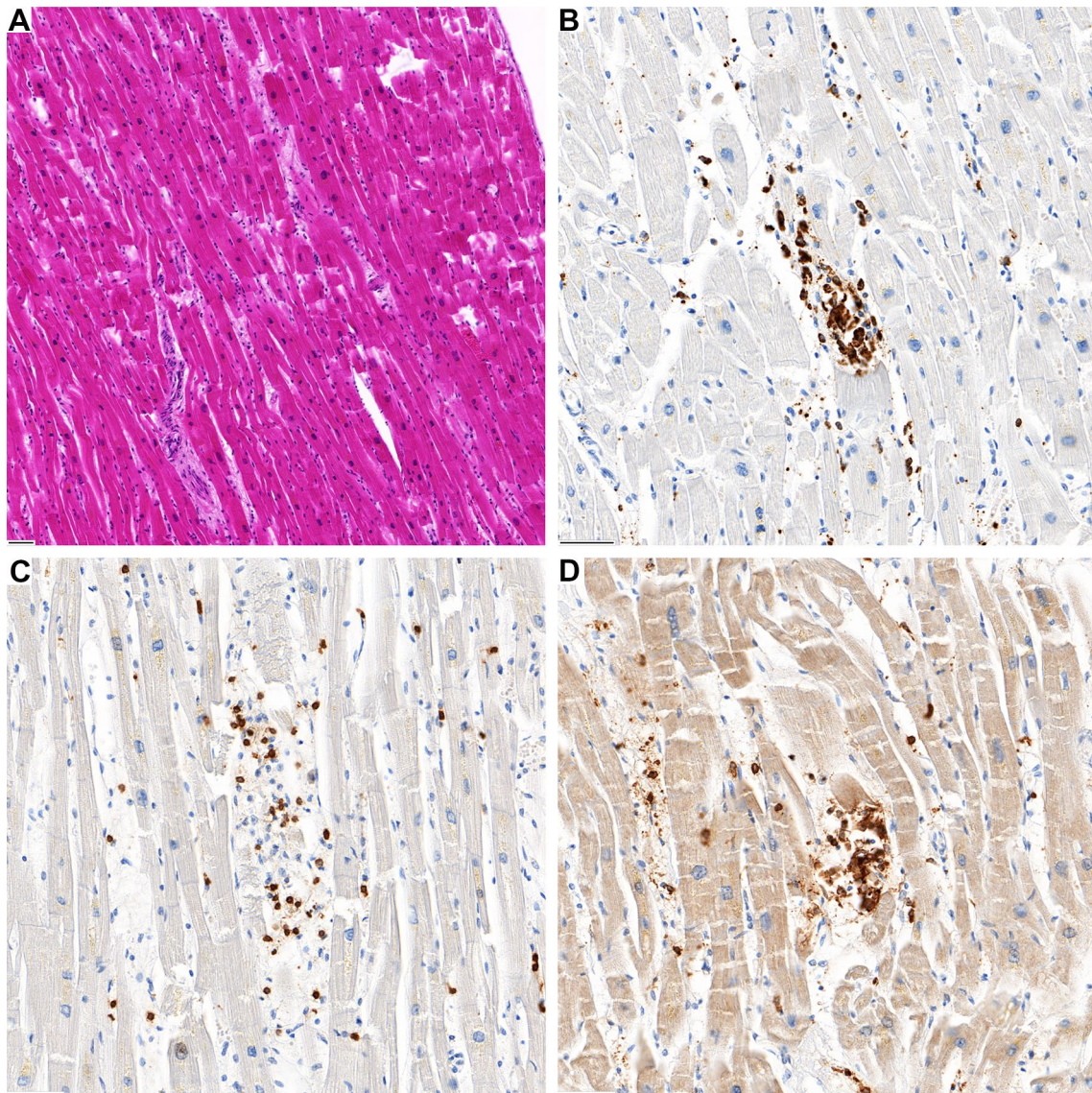


Fig. 2 **A** Inflammatory focus in the left ventricular wall of case 2. **B** The infiltrate is predominantly composed of CD68-positive macrophages and **C** CD3-positive T-lymphocytes with **(D)** co-expression of CD4

Discussion

Several cases of myocarditis following anti-SARS-CoV-2 vaccination have been published [4–6, 9, 14]. Symptoms typically occur within the first three days following the second dose of mRNA COVID-19 vaccines (Comirnaty and Spikevax, respectively) and young male patients presenting with chest pain are predominantly affected. Clinical findings like elevated troponin serum levels, abnormal ST-elevations in ECG and altered ventricle movement in echocardiogram or late enhancement in cardiac MRI suggested the development of a myocarditis. Most of the reported cases showed clinically mild courses with resolution of symptoms without treatment. However, in rare instances individuals required

intensive care support or even died from acute heart failure as described in an early report by Verma et al. [9]. These studies, with their different diagnostic modalities applied, already pointed to a link between vaccination and myocarditis, though many of these studies lack extensive testing for infectious agents. In particular studies of autopsy cohorts as well as information about potential long-term outcomes are not available yet [15–17].

Through our autopsy-based approach, we identified five cases of lymphocytic (epi-)myocarditis in persons, who were unexpectedly found dead at home within the first week following mRNA-mediated anti-SARS-CoV-2 immunization. According to the Dallas criteria four samples were classified as definitive myocarditis. In the remaining case, comparable

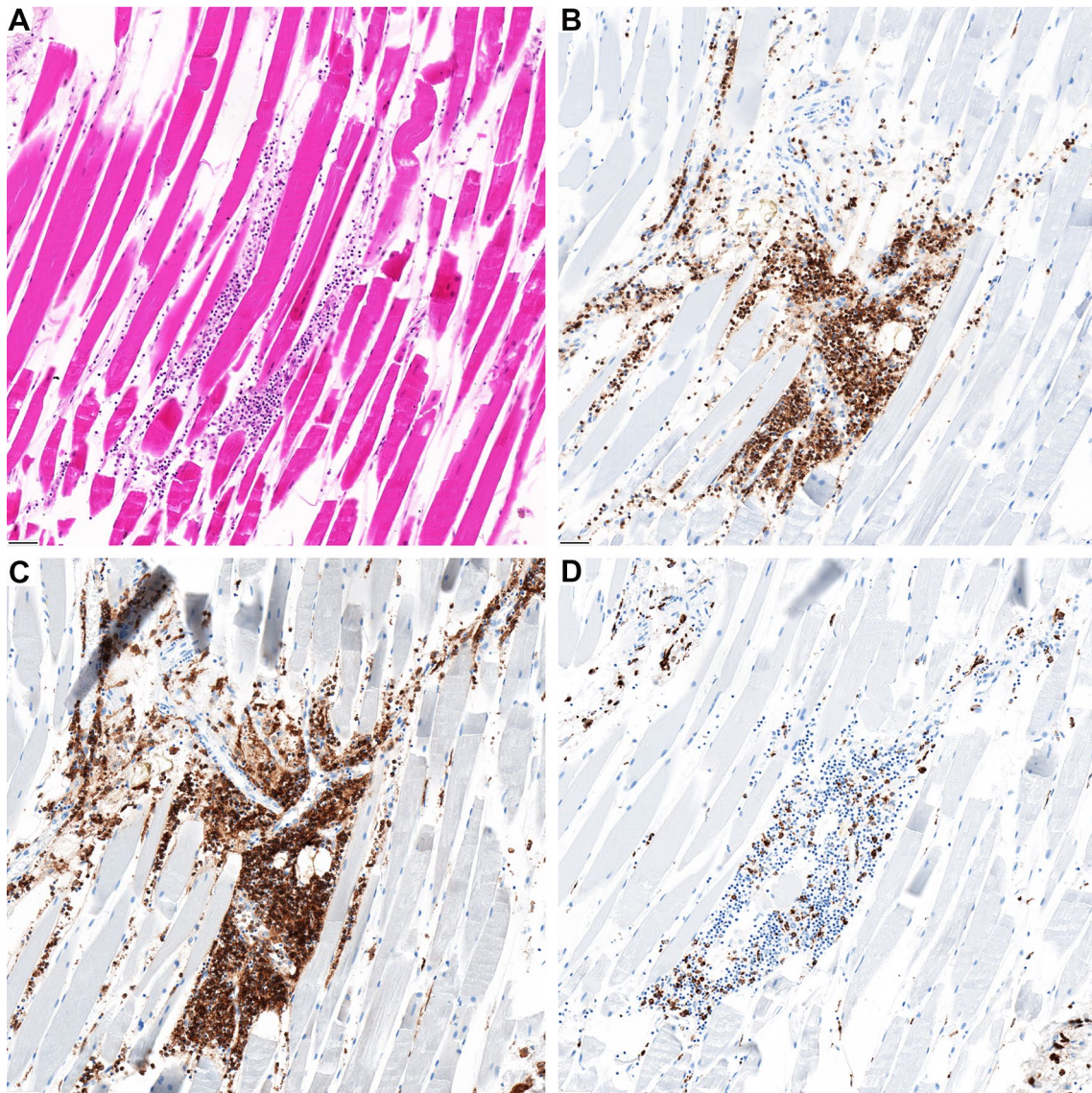


Fig. 3 **A** The jab site in the deltoid muscle reveals focal inflammation. The composition is similar to the phenotype of the myocardial infiltrates showing predominantly, **B** CD3 and **C** CD4-coexpressing lymphocytes and **D** interspersed CD68-positive macrophages

inflammatory infiltration of the epicardium, subepicardial fat and myocardium was found, but myocardial infiltration did not exceed the threshold of the Dallas criteria. All cases showed a consistent phenotype: (A) focal interstitial lymphocytic myocardial infiltration, in three cases accompanied by demonstrable microfocal myocyte destruction. (B) T-cell dominant infiltrate with CD4 positive T-cells outnumbering CD8 positive T-cells by far; (C) frequently associated with T-cell infiltration of epicardium and subepicardial fat tissue revealing a similar immune phenotype ($CD4 \gg CD8$).

As well-known from myocardial infarction, it has to be considered that microscopically visible manifestation of myocardial damage under such acute conditions may lag behind function; this may relate to aspects of infiltrate

composition, such as the relatively low macrophage content, or the histologically focal myocyte damage. Thus, functional effects may be much stronger than expected considering the histological picture. This is reflected by the fact that myocarditis is a major cause of sudden and unexpected death in infants, adolescents, and young adults with frequencies ranging from 1 to 14% among the young [18–21]. As outlined in the materials and methods section, evaluation of the likelihood of an AEFI reflects the temporal association and the autopsy findings (with exclusion of other reasons of sudden death), and negative molecular testing for potential infectious causes. Thus, case 5 with HHV6-DNA detected at low copy numbers was classified as possible. In general, a causal link between myocarditis and anti-SARS-CoV-2 vaccination

is supported by several considerations: (A) a close temporal relation to vaccination; all cases were found dead within one week after vaccination, (B) absence of any other significant pre-existing heart disease, especially ischaemic heart disease or cardiomyopathy, (C) negative testing for potential myocarditis-causing infectious agents, (D) presence of a peculiar CD4 predominant T-cell infiltrate, suggesting an immune mediated mechanism. The latter criterion is supported by demonstration of a phenotypically identical T-cell infiltrate at the deltoidal injection site in one of the cases. It has to be emphasized, that a comparable (epi-)myocardial infiltration was neither found in any of the other 20 autopsies performed on bodies found dead within 20 days following an anti-SARS-CoV-2 vaccination nor in the age- and sex-matched cohorts from three independent periods from our autopsy-files.

Based on the autopsy findings and all available data, no other cause of death except (epi-)myocarditis was identified in any of the cases presented here. Hence, myocarditis has to be considered the likely cause of death. From a functional point of view, myocardial damage in our cases is not sufficient to postulate contractile failure as terminal cause of death; thus, arrhythmic failure, either by cardiac arrest or by ventricular fibrillation, has to be assumed as the mechanism leading to the patients' death. Myocarditis-related acute cardiac arrest due to either asystole or ventricular fibrillation is a well-established pathomechanism in other causes of acute myocarditis as well [22, 23].

Regarding the potential underlying pathogenesis of (epi-)myocarditis, our findings allow some considerations. Besides pneumonia, myocarditis is another manifestation reported during SARS-CoV-2-infection [24]. It is under debate whether myocarditis in COVID-19 is primarily caused by the viral infection or whether it occurs secondary as a consequence of the host's immune response, in particular by T-lymphocyte-mediated cytotoxicity or as a consequence of the cytokine storm observed during COVID-19 [25]. Thus, it seems possible that a molecular mimicry between the spike protein of SARS-CoV-2 and self-antigens may trigger an anti-myocytic immune response in predisposed individuals. Multiple studies of mRNA-vaccines showed robust Receptor-Binding-Domain specific antibodies, T cell and cytokine responses [26]. T cells, especially CD4+ T cells, are the main drivers of heart-specific autoimmunity in myocarditis [27]. A vaccine-induced activation of the immune system in persons with otherwise peripheral tolerance due to regulatory T cells might promote CD4+ effector T cell expansion and myocarditis. Considering that (epi-)myocarditis has not been described following vector-based anti-SARS-CoV-2 immunization yet, it could also be possible that the immune response may be directed against the mRNA or other constituents of the vaccine formula. However, the

vaccine against smallpox, based on a vaccinia virus, is reported to cause (epi-)myocarditis in rare cases [2, 3]. Of note, it has been recently reported that intravenous injection of COVID-19 mRNA vaccine is able to induce an acute (epi-) myocarditis in a preclinical model [28]. Interestingly, we recorded inflammatory foci predominantly in the right heart, which may suggest a gradual blood-stream derived dilution effect and based on this finding it is at least tempting to speculate that inadvertent intravascular vaccine injection may be contributive.

Our study is limited by the relatively small cohort size and inherits the bias of an endpoint analysis. The nature of our autopsy study necessitates that the data are descriptive in quality and does not allow any epidemiological conclusions in terms of incidence or risk estimation. The reported incidence of (epi-)myocarditis after vaccination is low and the risks of hospitalization and death associated with COVID-19 are stated to be greater than the recorded risk associated with COVID-19 vaccination [29]. Importantly, infectious agents may also cause lymphocytic myocarditis with a similar immunophenotype, thus meticulous molecular analyses is required in all cases of potentially vaccination-associated myocarditis.

Regarding a potential auto-immunological mechanism explaining the myocardial damage, histological examination of lymphatic nodes might be of interest, as Röltgen et al. described altered germinal center architecture following COVID-19 vaccination [30]. This aspect could not be addressed in our analysis, as systematic lymph node sampling was not part of our standardized autopsy protocol.

Finally, we cannot provide a definitive functional proof or a direct causal link between vaccination and myocarditis. Further studies and extended registry are needed to identify persons at risk for this potentially fatal AEFI and may be aided by detailed clinical, serological, and molecular analyses which were beyond the scope of this study. Considering that this fatal adverse event may affect healthy individuals, such registry and surveillance programs may improve early diagnosis, close monitoring, and treatment.

Supplementary Information The online version contains supplementary material available at <https://doi.org/10.1007/s00392-022-02129-5>.

Acknowledgements We thank Martin Bär and his team for their support for autopsies, the biobank of the German Center for Infection Research (Deutsches Zentrum für Infektionsforschung, DZIF) for the procurement and administration of tissue samples and Annett Müller and her team for technical support in histological and immunohistological analyses. We thank K. Klingel (Institute of Pathology, Tübingen University) for performing molecular analyses for infectious agents in myocardial tissue. We thank all participants of the Baden-Württemberg COVID autopsy and biobanking registry, for this study in particular K. Yen and S. Heinze (Institute for Forensic and Traffic Medicine, Heidelberg University) for cooperation and support and the Ministry for Science, Research and Art Baden-Württemberg for financial support of the study and registry.

Author contributions Study Planning: PS, TL; Compilation and analysis of data: CS, LMD, LH; Writing of manuscript: CS, AS, TL, PS; Evaluation/contribution to manuscript: TL, PS.

Funding Open Access funding enabled and organized by Projekt DEAL. The study was funded by the Ministry of Science, Research and Art of Baden-Württemberg (Baden-Württemberg Corona Autopsy Biobank and Registry).

Data Availability Data are available upon reasonable request.

Declarations

Conflict of interest The authors have no competing interests to declare that are relevant to the content of this article.

Ethical standards S-242/2020; The study complies with all ethical standards.

Open Access This article is licensed under a Creative Commons Attribution 4.0 International License, which permits use, sharing, adaptation, distribution and reproduction in any medium or format, as long as you give appropriate credit to the original author(s) and the source, provide a link to the Creative Commons licence, and indicate if changes were made. The images or other third party material in this article are included in the article's Creative Commons licence, unless indicated otherwise in a credit line to the material. If material is not included in the article's Creative Commons licence and your intended use is not permitted by statutory regulation or exceeds the permitted use, you will need to obtain permission directly from the copyright holder. To view a copy of this licence, visit <http://creativecommons.org/licenses/by/4.0/>.

References

- World Health Organization (2019) Causality assessment of an adverse event following immunization (AEFI): user manual for the revised WHO classification second edition, 2019 update. World Health Organization, Geneva (**Licence: CC BY-NC-SA 3.0 IGO**)
- Mei R, Raschi E, Forcesi E, Diemberger I, De Ponti F, Poluzzi E (2018) Myocarditis and pericarditis after immunization: gaining insights through the Vaccine Adverse Event Reporting System. *Int J Cardiol* 273:183–186
- Nalca A, Zumbrun EE (2010) ACAM2000: the new smallpox vaccine for United States Strategic National Stockpile. *Drug Des Dev Ther* 4:71–79
- Prevention CfDca. Advisory Committee on Immunization Practices (ACIP). Coronavirus disease 2019 (COVID-19) vaccines. Accessed 2021. <https://www.cdc.gov/vaccines/acip/meetings/slides-2021-06.html>
- Larson KF, Ammirati E, Adler ED, Cooper LT Jr, Hong KN, Saponara G et al (2021) Myocarditis After BNT162b2 and mRNA-1273 Vaccination. *Circulation* 144(6):506–508
- Marshall M, Ferguson ID, Lewis P, Jaggi P, Gagliardo C, Collins JS et al (2021) Symptomatic acute myocarditis in 7 adolescents after Pfizer-BioNTech COVID-19 vaccination. *Pediatrics*. <https://doi.org/10.1542/peds.2021-052478>
- Surveillance of Myocarditis (Inflammation of the Heart Muscle) Cases Between December 2020 and May 2021 (Including). 02.06.2021 2021
- Ling RR, Ramanathan K, Tan FL, Tai BC, Somani J, Fisher D et al (2022) Myopericarditis following COVID-19 vaccination and non-COVID-19 vaccination: a systematic review and meta-analysis. *Lancet Respir Med* 10(7):679–688
- Verma AK, Lavine KJ, Lin CY (2021) Myocarditis after Covid-19 mRNA Vaccination. *N Engl J Med* 385(14):1332–1334
- Kommoss FKF, Schwab C, Tavernar L, Schreck J, Wagner WL, Merle U et al (2020) The pathology of severe COVID-19-related lung damage. *Deutsches Arzteblatt Int* 117(29–30):500–506
- Caforio AL, Pankuweit S, Arbustini E, Basso C, Gimeno-Blanes J, Felix SB et al (2013) Current state of knowledge on aetiology, diagnosis, management, and therapy of myocarditis: a position statement of the European Society of Cardiology Working Group on Myocardial and Pericardial Diseases. *Eur Heart J* 34(33):2636–2648 (**48a-48d**)
- Aretz HT, Billingham ME, Edwards WD, Factor SM, Fallon JT, Fenoglio JJ Jr et al (1987) Myocarditis. A histopathologic definition and classification. *Am J Cardiovasc Pathol* 1(1):3–14
- Mahfoud F, Gärtner B, Kindermann M, Ukena C, Gadamski K, Klingel K et al (2011) Virus serology in patients with suspected myocarditis: utility or futility? *Eur Heart J* 32(7):897–903
- Mevorach D, Anis E, Cedar N, Bromberg M, Haas EJ, Nadir E et al (2021) Myocarditis after BNT162b2 mRNA Vaccine against Covid-19 in Israel. *N Engl J Med* 385(23):2140–2149
- Administration USFD. FDA Approves First COVID-19 Vaccine 2021 [updated 23.08.2021. Available from: <https://www.fda.gov/news-events/press-announcements/fda-approves-first-covid-19-vaccine>
- Shiravi AA, Ardekani A, Sheikhbaehaei E, Heshmat-Ghahdarijani K (2022) Cardiovascular complications of SARS-CoV-2 vaccines: an overview. *Cardiology and therapy* 11(1):13–21
- Schneider J, Sottmann L, Greinacher A, Hagen M, Kasper HU, Kuhnen C et al (2021) Postmortem investigation of fatalities following vaccination with COVID-19 vaccines. *Int J Legal Med* 135(6):2335–2345
- Lyng TH, Nielsen TS, Gregers Winkel B, Tfelt-Hansen J, Banner J (2019) Sudden cardiac death caused by myocarditis in persons aged 1–49 years: a nationwide study of 14 294 deaths in Denmark. *Forensic Sci Res* 4(3):247–256
- Ali-Ahmed F, Dalgaard F, Al-Khatib SM (2020) Sudden cardiac death in patients with myocarditis: Evaluation, risk stratification, and management. *Am Heart J* 220:29–40
- Richter S, Schwab T, Berchthold-Herz M, Beyersdorf F, Schlenzak C, Bode C et al (2008) Borderline-Myokarditis als Auslöser für therapierefraktäres Kammerflimmern. *Intensivmedizin und Notfallmedizin* 45(5):287–291
- De Salvia A, De Leo D, Carturan E, Basso C (2011) Sudden cardiac death, borderline myocarditis and molecular diagnosis: evidence or assumption? *Med Sci Law* 51(1_Suppl):27–29
- Corrado D, Basso C, Thiene G (2001) Sudden cardiac death in young people with apparently normal heart. *Cardiovasc Res* 50(2):399–408
- Kragholm KH, Lindgren FL, Zaremba T, Freeman P, Andersen NH, Riahi S et al (2021) Mortality and ventricular arrhythmia after acute myocarditis: a nationwide registry-based follow-up study. *Open Heart* 8(2):e001806
- Verma V, Sondhi S, Sharma R, Mahajan K (2020) COVID-19 associated viral myocarditis: does it exist? *Monaldi archives for chest disease = Archivio Monaldi per le malattie del torace. Monaldi Arch Chest Dis*. <https://doi.org/10.4081/monaldi.2020.1382>
- Siripanthong B, Nazarian S, Muser D, Deo R, Santangeli P, Khanji MY et al (2020) Recognizing COVID-19-related myocarditis: the possible pathophysiology and proposed guideline for diagnosis and management. *Heart Rhythm* 17(9):1463–1471
- Sahin U, Muik A, Derhovanessian E, Vogler I, Kranz LM, Vormehr M et al (2020) COVID-19 vaccine BNT162b1

- elicits human antibody and TH1 T cell responses. *Nature* 586(7830):594–599
27. Chen P, Baldeviano GC, Ligons DL, Talor MV, Barin JG, Rose NR et al (2012) Susceptibility to autoimmune myocarditis is associated with intrinsic differences in CD4(+) T cells. *Clin Exp Immunol* 169(2):79–88
 28. Li C, Chen Y, Zhao Y, Lung DC, Ye Z, Song W et al (2021) Intravenous injection of Coronavirus Disease 2019 (COVID-19) mRNA vaccine can induce acute myopericarditis in mouse model. *Clin Infect Dis* 74(11):1933–1950
 29. Heymans S, Cooper LT (2022) Myocarditis after COVID-19 mRNA vaccination: clinical observations and potential mechanisms. *Nat Rev Cardiol* 19(2):75–77
 30. Röltgen K, Nielsen SCA, Silva O, Younes SF, Zaslavsky M, Costales C et al (2022) Immune imprinting, breadth of variant recognition, and germinal center response in human SARS-CoV-2 infection and vaccination. *Cell* 185(6):1025–40.e14

Authors and Affiliations

Constantin Schwab¹ · Lisa Maria Domke^{1,2} · Laura Hartmann^{1,2} · Albrecht Stenzinger¹ · Thomas Longerich¹ · Peter Schirmacher¹

¹ Institute of Pathology, Heidelberg University Hospital, Universitätsklinikum Heidelberg, Pathologisches Institut, Im Neuenheimer Feld 224, 69120 Heidelberg, Germany

² German Center for Infection Research (DZIF), partner site Heidelberg, Institute of Pathology, Heidelberg University Hospital, Heidelberg, Germany



Autopsy-based histopathological characterization of myocarditis after anti-SARS-CoV-2-vaccination

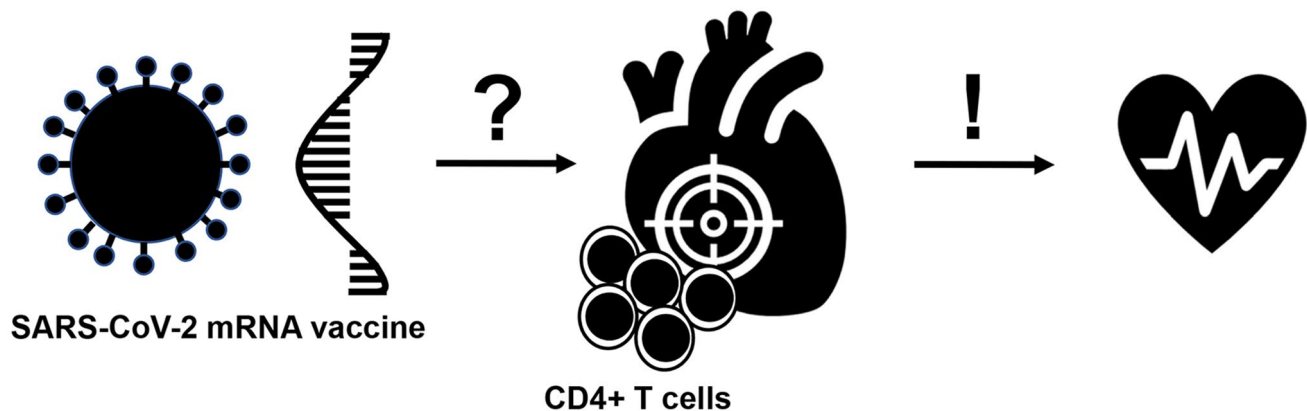
Constantin Schwab¹ · Lisa Maria Domke^{1,2} · Laura Hartmann^{1,2} · Albrecht Stenzinger¹ · Thomas Longerich¹ · Peter Schirmacher¹

Received: 22 July 2022 / Accepted: 17 November 2022
© The Author(s) 2022

Abstract

Cases of myocarditis, diagnosed clinically by laboratory tests and imaging have been described in the context of mRNA-based anti-SARS-CoV-2 vaccination. Autopsy-based description of detailed histological features of vaccine-induced myocarditis is lacking. We describe the autopsy findings and common characteristics of myocarditis in untreated persons who received anti-SARS-CoV-2 vaccination. Standardized autopsies were performed on 25 persons who had died unexpectedly and within 20 days after anti-SARS-CoV-2 vaccination. In four patients who received a mRNA vaccination, we identified acute (epi-) myocarditis without detection of another significant disease or health constellation that may have caused an unexpected death. Histology showed patchy interstitial myocardial T-lymphocytic infiltration, predominantly of the CD4 positive subset, associated with mild myocyte damage. Overall, autopsy findings indicated death due to acute arrhythmogenic cardiac failure. Thus, myocarditis can be a potentially lethal complication following mRNA-based anti-SARS-CoV-2 vaccination. Our findings may aid in adequately diagnosing unclear cases after vaccination and in establishing a timely diagnosis in vivo, thus, providing the framework for adequate monitoring and early treatment of severe clinical cases.

Graphical abstract



Keywords Autopsy · SARS · Cardiac pathology · Myocarditis · Vaccination

Thomas Longerich and Peter Schirmacher are contributed equally to this work.

✉ Peter Schirmacher
peter.schirmacher@med.uni-heidelberg.de

Extended author information available on the last page of the article

Introduction

Between December 2020 and March 2021, the European Medicines Agency approved several vaccines on the basis of randomized, blinded, controlled trials: two messenger RNA-based vaccines—Comirnaty, BNT162b2

(Pfizer–BioNTech) and Spikevax, mRNA-1273 (Moderna)—both encoding the spike protein of SARS-CoV-2 encapsulated in lipid nanoparticles as the antigen and two vaccines based on recombinant adenoviruses (Vaxzevira, ChAdOx1 nCov-19 (AstraZeneca), a recombinant chimpanzee adenoviral vector encoding the spike glycoprotein of SARS-CoV-2 and Ad26.COV2.S (Johnson & Johnson/Janssen), a recombinant adenovirus type 26 vector encoding SARS-CoV-2 spike glycoprotein. Recently, the first adapted bivalent COVID-19 booster vaccines targeting Omicron subvariants (BA.1 and BA.4-5, respectively) were authorized across the European Union (EMA/H/C/005735: Comirnaty Original/Omicron BA.1, Comirnaty Original/Omicron BA.4-5; EMA/H/C/005791: Spikevax bivalent Original/Omicron BA.1).

As vaccines may cause adverse events (AEFI), it is crucial to record them systematically and assess them for causality both at the population and at the individual level, as proposed by the World Health Organization (WHO) [1]. Detailed analyses should aim to establish or rule out a causal link between vaccination and the event in question. Autopsy is an important measure to identify severe adverse effects and to provide important mechanistic data in this setting. It may allow to identify the population at risk and may help to develop algorithms for prevention or monitoring, facilitating early diagnosis and successful treatment.

Cases of (epi-)myocarditis have previously been documented after immunization against smallpox or influenza in the vaccine adverse events reporting system [2, 3]. Recently, unusual cases of (epi-)myocarditis after vaccination with mRNA-based anti-SARS-CoV-2-vaccines have been documented [4]. These were clinically observed and diagnosed by laboratory and cardiac magnetic resonance imaging, predominantly in males under 30 years of age [5–8]. Available short-term follow-up data suggest resolution of symptoms [5–7]. However, few individuals required intensive care support or even died from acute heart failure. Information about potential long-term health outcomes is not yet available. Verma et al. reported two cases of myocarditis after mRNA vaccination, one of them fatal, revealed by endomyocardial biopsy and autopsy respectively [9]. Histology showed an inflammatory infiltrate predominantly composed of T-cells and macrophages, admixed with eosinophils, B-cells and plasma cells. By reporting similar observations based on different diagnostic techniques (e.g. cardiac magnetic resonance imaging, endomyocardial biopsy), the causality of an AEFI can be assessed at the population level [1]. However, in most of these studies comprehensive testing for infectious agents, crucial for the assessment of an AEFI at the individual level, was not reported. As a consequence, a systematic description with histopathological phenotyping as well as molecular analysis of (epi-)myocarditis after anti-SARS-CoV-2-vaccination is still lacking.

Here, we describe the cardiac autopsy findings in five persons who have died unexpectedly within seven days following anti-SARS-CoV-2-vaccination, with vaccine-induced myocardial inflammation representing the likely or possible cause of death. Our findings establish the histological phenotype of lethal vaccination-associated myocarditis.

Materials and methods

Data on autopsies of persons, who received anti-SARS-CoV-2 vaccination (up to 20 days before their death), were obtained from the COVID autopsy and biomaterial registry Baden-Württemberg. This federal state registry contains autopsy, clinical and pathological data as well as tissue samples from patients who have died in the context of a SARS-CoV-2 infection or persons who have died briefly after an anti-SARS-CoV-2 vaccination ($n = 54$). All autopsies were performed at one of the five University hospital sites (Heidelberg, Tübingen, Freiburg, Ulm, Mannheim) of Baden-Württemberg. The network cooperates with prosecution and the forensic pathology as well as with other national networks such as the German Center for Infection Research (DZIF), the German Center for Lung Research (DZL), and the national academic research network NUM (Network of University Medicine; DEFEAT PANDEMIcs); results are constantly reported to the Paul Ehrlich Institute (PEI), the German Federal Institute for Vaccines and Biomedicines. In this study, all and only autopsies performed at Heidelberg University Hospital ($n = 35$) were included to ensure that all medical documents and findings were available and that the autopsies were performed according to the standardized procedure described previously [10]. The hearts were examined macroscopically by measuring the weight and the thickness of the left, right and interventricular walls. Coronary arteries were dissected from their aortic branching to the periphery to allow for evaluation of arteriosclerosis and exclusion of thrombi. Afterwards, the inflow and outflow tracts were examined, the ventricles were cross-sectioned in short axis (transversal plane) at 1 cm intervals from the valves to the apex and the cut surfaces were examined for focal lesions (or geographic demarcations), a focussed dissection and detailed histological evaluation of the cardiac conduction system was not performed.

For histological evaluation, all tissue samples were fixed in 4% neutral-buffered formalin. At least two full-thickness blocks from the left and right ventricular wall, the interventricular septum, and the papillary muscles were taken for histological evaluation of cardiac pathologies. From formalin-fixed, paraffin-embedded (FFPE) tissue-blocks at least two sections with a thickness of 4 μm were stained with hematoxylin & eosin, periodic acid Schiff (PAS) reaction, and acid fuchsin orange G (AFOG), respectively.

Immunohistochemical stainings were performed according to standard protocols. In brief, immunohistochemistry was performed on an automated immunostainer (Ventana BenchMark Ultra, Ventana Medical Systems, Tucson, USA). Sections were cut, deparaffinized, rehydrated and pre-treated with an antigen retrieval buffer (Tris/Borat/EDTA, pH 8.4). After blocking of endogenous peroxidase, the slides were incubated with monoclonal antibodies directed against CD3 (clone 2GV6, Roche, Rotkreuz, Switzerland), CD4 (clone SP35, Roche), CD8 (clone SP57, Roche), CD20 (clone L26, Roche), GATA 3 (clone L50-823, Roche, Rotkreuz, Switzerland) and D2-40 (clone Roche, Rotkreuz, Switzerland) at the provided dilutions of the ready-to-use-kits, CD68 (clone PgM1, Agilent/Dako, Santa Clara, United States) at a dilution of 1:100, FOXP3 (clone D2W8ETM, Cell iSignaling Technology, Danvers, MA, United States) at a dilution of 1:25, and Tbet (clone 4B10, Santa Cruz Biotechnology Inc., Santa Cruz, CA, United States) at a dilution of 1:50 followed by incubation with OptiView Universal Linker and OptiView HRP Multimer. Visualization was achieved using DAB as chromogen. Before mounting, slides were counterstained with haematoxylin. Histological and immunohistological findings were analysed in synopsis with available data from the patients' medical records. Three age- and sex-matched cohorts from our autopsy files (covering the years 2005/2006, 2010/2011 and 2015/2016) were retrieved and the myocardial samples were evaluated for the presence and phenotype of inflammatory infiltrates.

Based on the Dallas criteria and the specifications according to Caforio et al. myocarditis was defined by an inflammatory infiltrate with ≥ 14 leucocytes/mm² including up to 4 monocytes/mm² with the presence of CD3 positive T-lymphocytes ≥ 7 cells/mm² and signs of myocyte degeneration and necrosis of non-ischaemic origin [11, 12]. Myocardial and epicardial infiltration was assessed semiquantitatively

by visual scoring using a four-tiered system (0–3): score 0 (no foci of inflammation), score 1 (focal, isolated foci with up to 20 leucocytes/mm²), score 2 (focal, > 20 leucocytes/mm²), and score 3 (diffuse infiltration). Regarding potential causative infectious agents, FFPE samples of all cases and fresh frozen myocardial samples of cases 1, 3, 4 and 5 were tested for viral and bacterial genomes by a diagnostic panel with (reverse transcription) PCR (Enteroviruses, parvovirus B19, human herpesvirus 6, Epstein–Barr virus, human cytomegalovirus, varicella zoster virus, herpes simplex virus type 1 and 2, human herpesvirus 7, adenoviruses, borrelia spp., Toxoplasma gondii). For each sample, 350 ng of total nucleic acid was extracted and subjected to nested (RT)-PCR using in-house techniques as described by Mahfoud et al. [13]. Glyceraldehyde-3-phosphate dehydrogenase (GAPDH) RT-PCR served as an internal control for both nucleic acid extraction and PCR amplification.

The likelihood of vaccine-induced (epi-)myocarditis was categorized according to the criteria detailed in Table 1.

Results

Among the 35 cases of the University of Heidelberg, autopsies revealed other causes of death (due to pre-existing illnesses) in 10 patients (Supplementary Table 1). Hence, these were excluded from further analysis. Cardiac autopsy findings consistent with (epi-)myocarditis were found in five cases of the remaining 25 bodies found unexpectedly dead at home within 20 days following SARS-CoV-2 vaccination. Main characteristics of the five cases are presented in Table 2, while further autopsy findings are shown in Supplementary Table 2. Three of the deceased persons were women, two men. Median age at death was 58 years (range 46–75 years). Four persons died after the first vaccine jab,

Table 1 Likelihood assessment of vaccine-induced (epi-)myocarditis

category	Criteria
No vaccine-induced myocarditis	- Absence of myocarditis OR - Myocarditis without temporal association to vaccination event OR - Myocarditis, definitely explained by other, especially infectious diseases defined by histological/microbiological/virological testing of cardiac tissue
Possible vaccine-induced myocarditis	- Presence of myocarditis with temporal association to vaccination event, but presence of mitigating factors (e.g. detection of facultatively pathogenic infectious agents) OR - Presence of pericarditis with temporal association to vaccination event, but myocardial findings insufficient to establish definite myocarditis (e.g. Dallas criteria)
Likely vaccine-induced myocarditis	- Presence of myocarditis with temporal association to vaccination event AND - Integration of histological phenotype, clinical presentation, and laboratory findings indicate no alternative differential diagnosis

Table 2 Case characteristics

Case	Gender	Age	BMI	Vaccine type	Dose	Time from vaccination to death (days)	Time from death to autopsy (days)	Comorbidity	Grading – myocarditis (0–3)	Grading – epicarditis (0–3)	PCR analysis	Assessment of causal relationship
1	male	46	31.8	Cormirnaty (BioNTech)	First	0	7	AH	2	0	Negative	Likely
2	female	50	20	Spikevax (Moderna)	First	1	3	-	1	2	Negative	Likely
3	female	62	22.5	Cormirnaty (BioNTech)	First	7	3	COPD	1	1	Negative	Possible
4	male	55	30.1	Cormirnaty (BioNTech)	Second	4	3	-	2	3	Negative	Likely
5	female	75	27.9	Cormirnaty (BioNTech)	First	1	9	AH, DM, Hashimoto's thyroiditis	2	2	HHV6	Possible

Abbreviations: AH arterial hypertension, COPD chronic obstructive pulmonary disease, DM diabetes mellitus

the remaining case after the second dose. All persons died within the first week following vaccination (mean 2.5 days, median 2 days). Clinical findings, blood tests, ECGs or imaging data were not available as deceased persons did not seek medical attention prior to death. Person 1 was found dead 12 h after the vaccination. A witness described a rattling breath shortly before discovering circulatory failure. Person 2 complained about nausea and was found dead soon thereafter. Resuscitation was started immediately but without success, respectively. The other persons were found dead at home without available information about terminal symptoms. According to the available information provided at the time of autopsies, none of the deceased persons had SARS-CoV-2 infection prior to vaccination and nasopharyngeal swabs were negative in all cases.

Histological examination showed inflammatory infiltration of the myocardium. The infiltrate was focal and interstitial in all cases. It was predominantly detected in sections taken from the right ventricular wall and interventricular septum. The histological and immunohistochemical characterization revealed that the inflammatory infiltrate was predominantly composed of lymphocytes. The number of CD3-positive T-cells by far outnumbered the few CD20-positive B-cells detected. In addition, most T-cells belonged to the CD4-positive subset, while only scattered CD8-positive T-cells were seen (Fig. 1, 2, Supplementary Fig. 1/2). The T cells were negative for Tbet as a marker for Th1 cells, GATA3 as a marker for Th2 cells, D2-40, as a marker for Th17 cells (Supplementary Fig. 2). In addition, FOXP3 positive regulatory T cells and CD21 positive follicular dendritic cells were not detected within the cardiac infiltrates, while control cases, including cases of sarcoidosis were positive (Supplementary Fig. 2/3). Immunohistochemistry for CD68 showed few interspersed histiocytes (Fig. 2, Supplementary Fig. 1). Microfocal myocyte injury was demonstrable in three cases (patient 1, 2 and 3). No granulomas were found. All cases lacked significant coronary heart disease, acute or chronic manifestations of ischaemic heart disease, manifestations of cardiomyopathy or other signs of a pre-existing, clinically relevant heart disease.

In most cases, an inflammatory infiltration of the epicardium and the subepicardial fat tissue was concomitantly found (cases 2, 3, 4 and 5; Supplementary Fig. 4) and revealed an identical immunophenotype. (T-cell dominant; CD4 >> CD8). In case 2, a prominent CD4-positive lymphocytic infiltration was also recorded at the jab site of the deltoidal muscle (Fig. 3). Analysis for potential infectious agents causing a myocarditis revealed low viral copy numbers of human herpes virus 6 (HHV6) in one case (case 5). The results of the other four cases were negative for all infectious agents tested, but demonstrated regular amplification of the GAPDH control suggesting adequate nucleic acid quality for analysis.

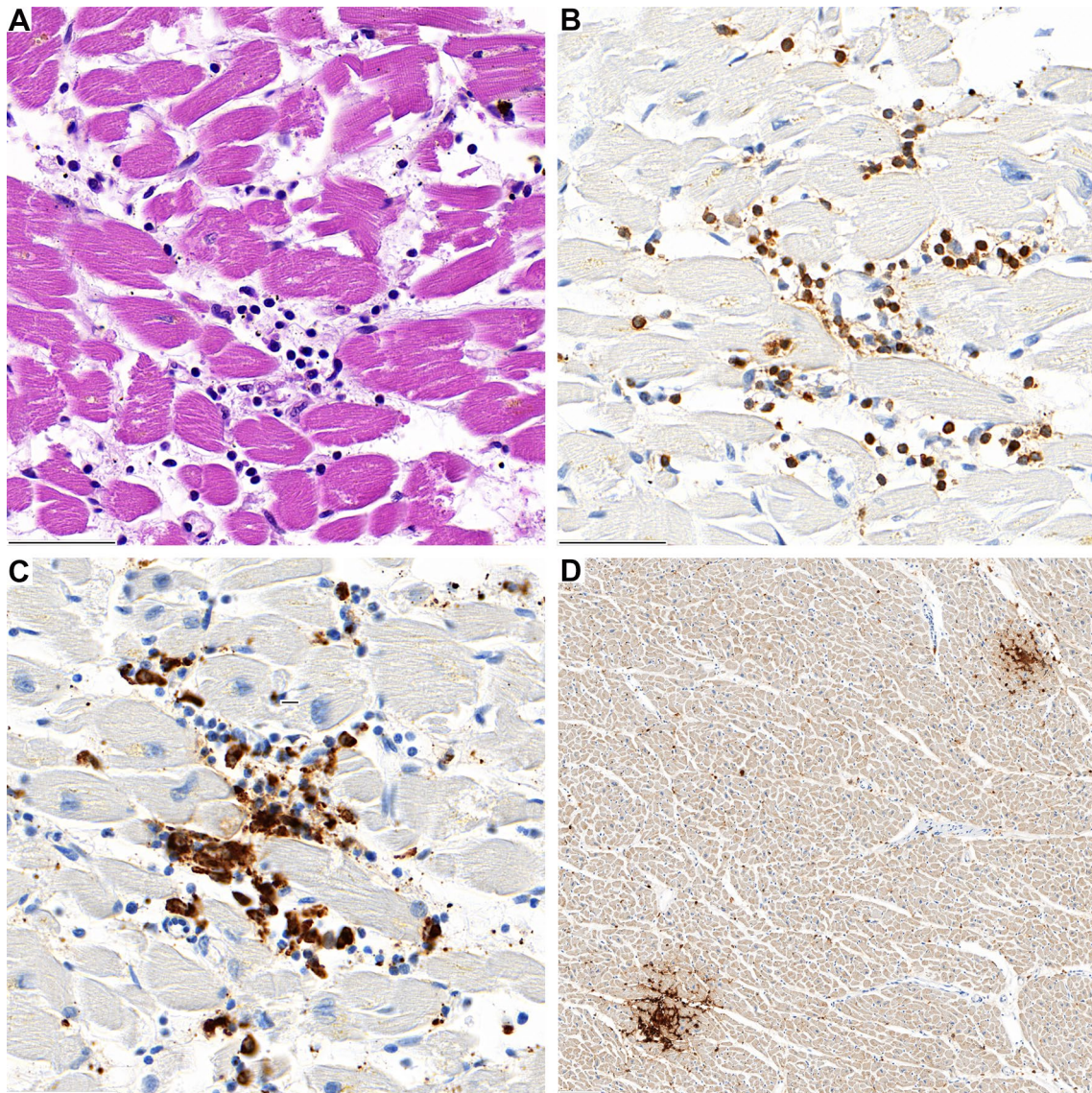


Fig. 1 **A** Lymphocytic aggregates in the interventricular septum of case 1 with associated myocardiocyte destruction. **B** The infiltrate is predominantly composed of CD3-positive T-lymphocytes and **C**

CD68-positive macrophages. **D** In lower magnification two foci of CD4-positive lymphocytes are evident (**D**)

In three cases, the overall autopsy findings, in particular presence of (epi-)myocarditis in combination with the absence of other plausible causes of death (especially pulmonary embolism, myocardial infarction, severe brain infarction or bleeding, other cardiac disease), together with the close temporal association with the vaccination event lead to the conclusion that vaccination was the likely cause of (epi-)myocarditis and that this cardiac affection was the cause of sudden death. For case 5, myocarditis was considered to be the cause of death as well, but the detection of HHV6, even in low viral copy numbers provided an alternative explanation for the presence of myocarditis. With regard to the question of a fatal AEFI, case 5 was therefore

classified as “possible”. For case 3 no other cause for the inflammatory infiltration was found, but the infiltrate was discrete and mainly observed in the pericardial fat. Thus, case 3 was categorized as possible AEFI as well. We did not find an obvious association between the infiltrates and endothelial cells (CD31, D2-40), mesothelial cells (calretinin), or neural cells (S100). During the last 20 years of autopsy service at Heidelberg University Hospital we did not observe comparable myocardial inflammatory infiltration. This was validated by histological re-evaluation of age- and sex-matched cohorts from three independent periods, which did not reveal a single case showing a comparable cardiac pathology.

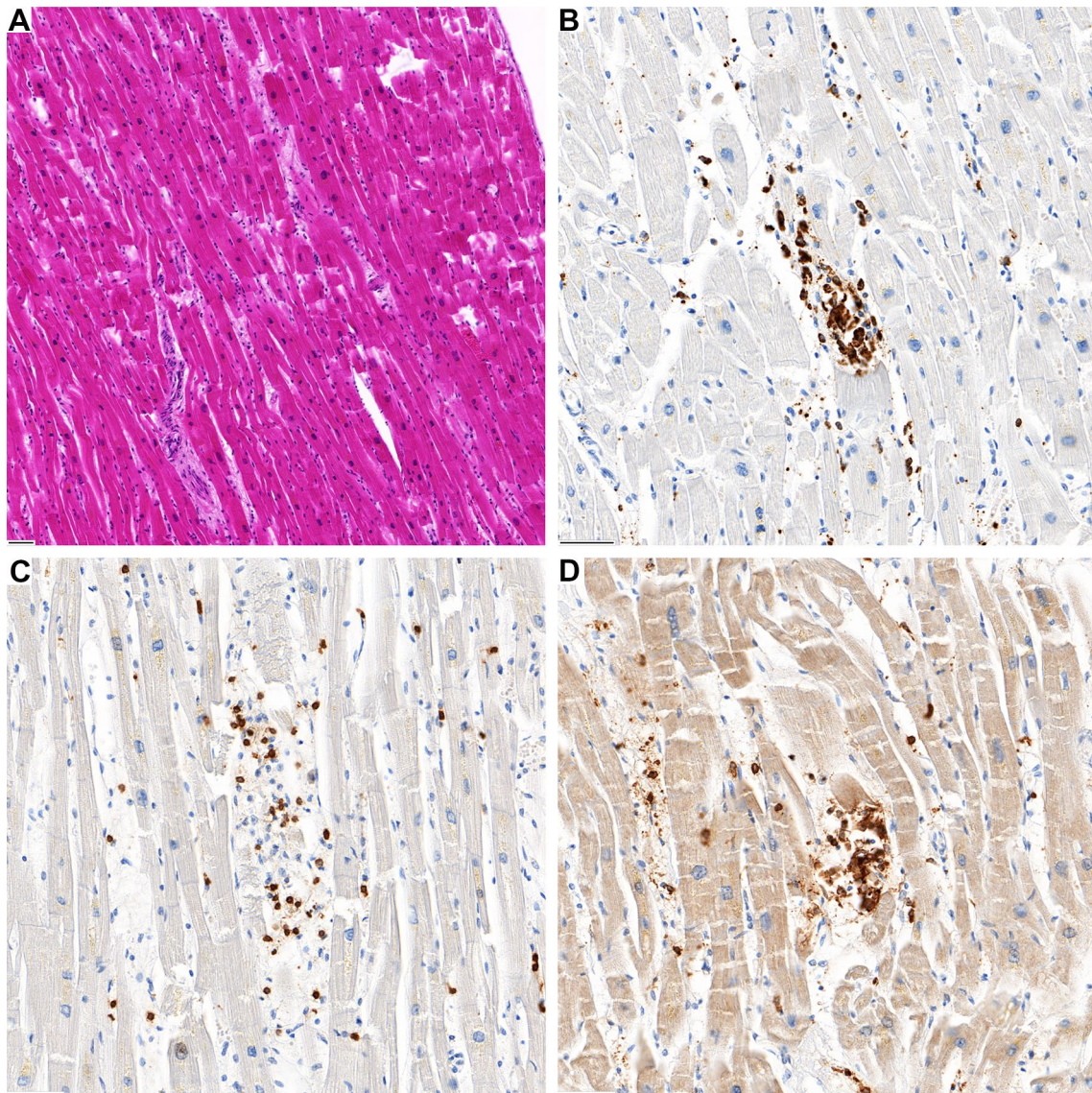


Fig. 2 **A** Inflammatory focus in the left ventricular wall of case 2. **B** The infiltrate is predominantly composed of CD68-positive macrophages and **C** CD3-positive T-lymphocytes with **(D)** co-expression of CD4

Discussion

Several cases of myocarditis following anti-SARS-CoV-2 vaccination have been published [4–6, 9, 14]. Symptoms typically occur within the first three days following the second dose of mRNA COVID-19 vaccines (Comirnaty and Spikevax, respectively) and young male patients presenting with chest pain are predominantly affected. Clinical findings like elevated troponin serum levels, abnormal ST-elevations in ECG and altered ventricle movement in echocardiogram or late enhancement in cardiac MRI suggested the development of a myocarditis. Most of the reported cases showed clinically mild courses with resolution of symptoms without treatment. However, in rare instances individuals required

intensive care support or even died from acute heart failure as described in an early report by Verma et al. [9]. These studies, with their different diagnostic modalities applied, already pointed to a link between vaccination and myocarditis, though many of these studies lack extensive testing for infectious agents. In particular studies of autopsy cohorts as well as information about potential long-term outcomes are not available yet [15–17].

Through our autopsy-based approach, we identified five cases of lymphocytic (epi-)myocarditis in persons, who were unexpectedly found dead at home within the first week following mRNA-mediated anti-SARS-CoV-2 immunization. According to the Dallas criteria four samples were classified as definitive myocarditis. In the remaining case, comparable

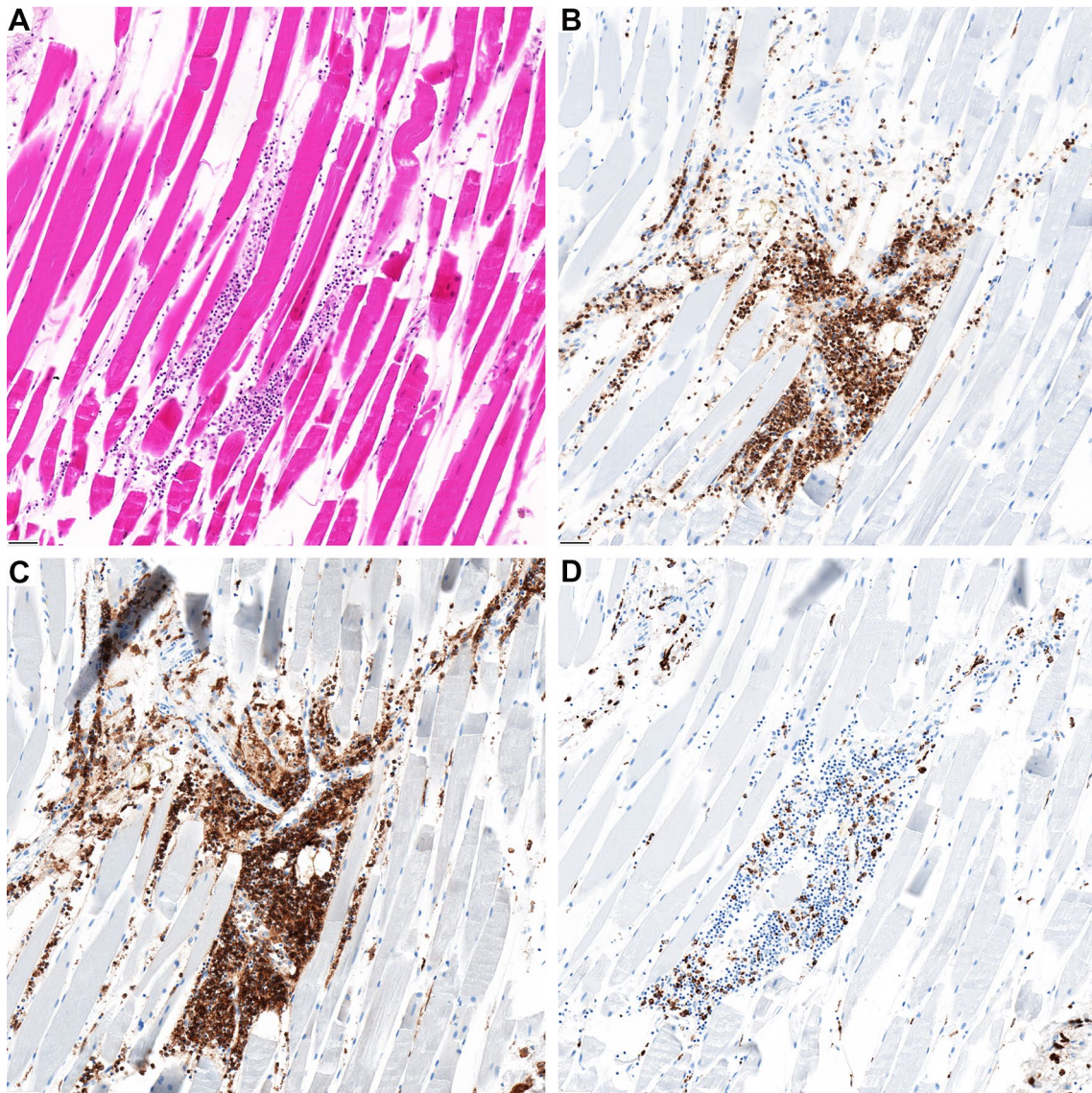


Fig. 3 **A** The jab site in the deltoid muscle reveals focal inflammation. The composition is similar to the phenotype of the myocardial infiltrates showing predominantly, **B** CD3 and **C** CD4-coexpressing lymphocytes and **D** interspersed CD68-positive macrophages

inflammatory infiltration of the epicardium, subepicardial fat and myocardium was found, but myocardial infiltration did not exceed the threshold of the Dallas criteria. All cases showed a consistent phenotype: (A) focal interstitial lymphocytic myocardial infiltration, in three cases accompanied by demonstrable microfocal myocyte destruction. (B) T-cell dominant infiltrate with CD4 positive T-cells outnumbering CD8 positive T-cells by far; (C) frequently associated with T-cell infiltration of epicardium and subepicardial fat tissue revealing a similar immune phenotype ($CD4 \gg CD8$).

As well-known from myocardial infarction, it has to be considered that microscopically visible manifestation of myocardial damage under such acute conditions may lag behind function; this may relate to aspects of infiltrate

composition, such as the relatively low macrophage content, or the histologically focal myocyte damage. Thus, functional effects may be much stronger than expected considering the histological picture. This is reflected by the fact that myocarditis is a major cause of sudden and unexpected death in infants, adolescents, and young adults with frequencies ranging from 1 to 14% among the young [18–21]. As outlined in the materials and methods section, evaluation of the likelihood of an AEFI reflects the temporal association and the autopsy findings (with exclusion of other reasons of sudden death), and negative molecular testing for potential infectious causes. Thus, case 5 with HHV6-DNA detected at low copy numbers was classified as possible. In general, a causal link between myocarditis and anti-SARS-CoV-2 vaccination

is supported by several considerations: (A) a close temporal relation to vaccination; all cases were found dead within one week after vaccination, (B) absence of any other significant pre-existing heart disease, especially ischaemic heart disease or cardiomyopathy, (C) negative testing for potential myocarditis-causing infectious agents, (D) presence of a peculiar CD4 predominant T-cell infiltrate, suggesting an immune mediated mechanism. The latter criterion is supported by demonstration of a phenotypically identical T-cell infiltrate at the deltoidal injection site in one of the cases. It has to be emphasized, that a comparable (epi-)myocardial infiltration was neither found in any of the other 20 autopsies performed on bodies found dead within 20 days following an anti-SARS-CoV-2 vaccination nor in the age- and sex-matched cohorts from three independent periods from our autopsy-files.

Based on the autopsy findings and all available data, no other cause of death except (epi-)myocarditis was identified in any of the cases presented here. Hence, myocarditis has to be considered the likely cause of death. From a functional point of view, myocardial damage in our cases is not sufficient to postulate contractile failure as terminal cause of death; thus, arrhythmic failure, either by cardiac arrest or by ventricular fibrillation, has to be assumed as the mechanism leading to the patients' death. Myocarditis-related acute cardiac arrest due to either asystole or ventricular fibrillation is a well-established pathomechanism in other causes of acute myocarditis as well [22, 23].

Regarding the potential underlying pathogenesis of (epi-)myocarditis, our findings allow some considerations. Besides pneumonia, myocarditis is another manifestation reported during SARS-CoV-2-infection [24]. It is under debate whether myocarditis in COVID-19 is primarily caused by the viral infection or whether it occurs secondary as a consequence of the host's immune response, in particular by T-lymphocyte-mediated cytotoxicity or as a consequence of the cytokine storm observed during COVID-19 [25]. Thus, it seems possible that a molecular mimicry between the spike protein of SARS-CoV-2 and self-antigens may trigger an anti-myocytic immune response in predisposed individuals. Multiple studies of mRNA-vaccines showed robust Receptor-Binding-Domain specific antibodies, T cell and cytokine responses [26]. T cells, especially CD4+ T cells, are the main drivers of heart-specific autoimmunity in myocarditis [27]. A vaccine-induced activation of the immune system in persons with otherwise peripheral tolerance due to regulatory T cells might promote CD4+ effector T cell expansion and myocarditis. Considering that (epi-)myocarditis has not been described following vector-based anti-SARS-CoV-2 immunization yet, it could also be possible that the immune response may be directed against the mRNA or other constituents of the vaccine formula. However, the

vaccine against smallpox, based on a vaccinia virus, is reported to cause (epi-)myocarditis in rare cases [2, 3]. Of note, it has been recently reported that intravenous injection of COVID-19 mRNA vaccine is able to induce an acute (epi-) myocarditis in a preclinical model [28]. Interestingly, we recorded inflammatory foci predominantly in the right heart, which may suggest a gradual blood-stream derived dilution effect and based on this finding it is at least tempting to speculate that inadvertent intravascular vaccine injection may be contributive.

Our study is limited by the relatively small cohort size and inherits the bias of an endpoint analysis. The nature of our autopsy study necessitates that the data are descriptive in quality and does not allow any epidemiological conclusions in terms of incidence or risk estimation. The reported incidence of (epi-)myocarditis after vaccination is low and the risks of hospitalization and death associated with COVID-19 are stated to be greater than the recorded risk associated with COVID-19 vaccination [29]. Importantly, infectious agents may also cause lymphocytic myocarditis with a similar immunophenotype, thus meticulous molecular analyses is required in all cases of potentially vaccination-associated myocarditis.

Regarding a potential auto-immunological mechanism explaining the myocardial damage, histological examination of lymphatic nodes might be of interest, as Röltgen et al. described altered germinal center architecture following COVID-19 vaccination [30]. This aspect could not be addressed in our analysis, as systematic lymph node sampling was not part of our standardized autopsy protocol.

Finally, we cannot provide a definitive functional proof or a direct causal link between vaccination and myocarditis. Further studies and extended registry are needed to identify persons at risk for this potentially fatal AEFI and may be aided by detailed clinical, serological, and molecular analyses which were beyond the scope of this study. Considering that this fatal adverse event may affect healthy individuals, such registry and surveillance programs may improve early diagnosis, close monitoring, and treatment.

Supplementary Information The online version contains supplementary material available at <https://doi.org/10.1007/s00392-022-02129-5>.

Acknowledgements We thank Martin Bär and his team for their support for autopsies, the biobank of the German Center for Infection Research (Deutsches Zentrum für Infektionsforschung, DZIF) for the procurement and administration of tissue samples and Annett Müller and her team for technical support in histological and immunohistological analyses. We thank K. Klingel (Institute of Pathology, Tübingen University) for performing molecular analyses for infectious agents in myocardial tissue. We thank all participants of the Baden-Württemberg COVID autopsy and biobanking registry, for this study in particular K. Yen and S. Heinze (Institute for Forensic and Traffic Medicine, Heidelberg University) for cooperation and support and the Ministry for Science, Research and Art Baden-Württemberg for financial support of the study and registry.

Author contributions Study Planning: PS, TL; Compilation and analysis of data: CS, LMD, LH; Writing of manuscript: CS, AS, TL, PS; Evaluation/contribution to manuscript: TL, PS.

Funding Open Access funding enabled and organized by Projekt DEAL. The study was funded by the Ministry of Science, Research and Art of Baden-Württemberg (Baden-Württemberg Corona Autopsy Biobank and Registry).

Data Availability Data are available upon reasonable request.

Declarations

Conflict of interest The authors have no competing interests to declare that are relevant to the content of this article.

Ethical standards S-242/2020; The study complies with all ethical standards.

Open Access This article is licensed under a Creative Commons Attribution 4.0 International License, which permits use, sharing, adaptation, distribution and reproduction in any medium or format, as long as you give appropriate credit to the original author(s) and the source, provide a link to the Creative Commons licence, and indicate if changes were made. The images or other third party material in this article are included in the article's Creative Commons licence, unless indicated otherwise in a credit line to the material. If material is not included in the article's Creative Commons licence and your intended use is not permitted by statutory regulation or exceeds the permitted use, you will need to obtain permission directly from the copyright holder. To view a copy of this licence, visit <http://creativecommons.org/licenses/by/4.0/>.

References

- World Health Organization (2019) Causality assessment of an adverse event following immunization (AEFI): user manual for the revised WHO classification second edition, 2019 update. World Health Organization, Geneva (**Licence: CC BY-NC-SA 3.0 IGO**)
- Mei R, Raschi E, Forcesi E, Diemberger I, De Ponti F, Poluzzi E (2018) Myocarditis and pericarditis after immunization: gaining insights through the Vaccine Adverse Event Reporting System. *Int J Cardiol* 273:183–186
- Nalca A, Zumbrun EE (2010) ACAM2000: the new smallpox vaccine for United States Strategic National Stockpile. *Drug Des Dev Ther* 4:71–79
- Prevention CfDCa. Advisory Committee on Immunization Practices (ACIP). Coronavirus disease 2019 (COVID-19) vaccines. Accessed 2021. <https://www.cdc.gov/vaccines/acip/meetings/slides-2021-06.html>
- Larson KF, Ammirati E, Adler ED, Cooper LT Jr, Hong KN, Saponara G et al (2021) Myocarditis After BNT162b2 and mRNA-1273 Vaccination. *Circulation* 144(6):506–508
- Marshall M, Ferguson ID, Lewis P, Jaggi P, Gagliardo C, Collins JS et al (2021) Symptomatic acute myocarditis in 7 adolescents after Pfizer-BioNTech COVID-19 vaccination. *Pediatrics*. <https://doi.org/10.1542/peds.2021-052478>
- Surveillance of Myocarditis (Inflammation of the Heart Muscle) Cases Between December 2020 and May 2021 (Including). 02.06.2021 2021
- Ling RR, Ramanathan K, Tan FL, Tai BC, Somani J, Fisher D et al (2022) Myopericarditis following COVID-19 vaccination and non-COVID-19 vaccination: a systematic review and meta-analysis. *Lancet Respir Med* 10(7):679–688
- Verma AK, Lavine KJ, Lin CY (2021) Myocarditis after Covid-19 mRNA Vaccination. *N Engl J Med* 385(14):1332–1334
- Kommoss FKF, Schwab C, Tavernar L, Schreck J, Wagner WL, Merle U et al (2020) The pathology of severe COVID-19-related lung damage. *Deutsches Arzteblatt Int* 117(29–30):500–506
- Caforio AL, Pankuweit S, Arbustini E, Basso C, Gimeno-Blanes J, Felix SB et al (2013) Current state of knowledge on aetiology, diagnosis, management, and therapy of myocarditis: a position statement of the European Society of Cardiology Working Group on Myocardial and Pericardial Diseases. *Eur Heart J* 34(33):2636–2648 (**48a-48d**)
- Aretz HT, Billingham ME, Edwards WD, Factor SM, Fallon JT, Fenoglio JJ Jr et al (1987) Myocarditis. A histopathologic definition and classification. *Am J Cardiovasc Pathol* 1(1):3–14
- Mahfoud F, Gärtner B, Kindermann M, Ukena C, Gadamski K, Klingel K et al (2011) Virus serology in patients with suspected myocarditis: utility or futility? *Eur Heart J* 32(7):897–903
- Mevorach D, Anis E, Cedar N, Bromberg M, Haas EJ, Nadir E et al (2021) Myocarditis after BNT162b2 mRNA Vaccine against Covid-19 in Israel. *N Engl J Med* 385(23):2140–2149
- Administration USFD. FDA Approves First COVID-19 Vaccine 2021 [updated 23.08.2021. Available from: <https://www.fda.gov/news-events/press-announcements/fda-approves-first-covid-19-vaccine>
- Shiravi AA, Ardekani A, Sheikhbaehaei E, Heshmat-Ghahdarijani K (2022) Cardiovascular complications of SARS-CoV-2 vaccines: an overview. *Cardiology and therapy* 11(1):13–21
- Schneider J, Sottmann L, Greinacher A, Hagen M, Kasper HU, Kuhnen C et al (2021) Postmortem investigation of fatalities following vaccination with COVID-19 vaccines. *Int J Legal Med* 135(6):2335–2345
- Lyng TH, Nielsen TS, Gregers Winkel B, Tfelt-Hansen J, Banner J (2019) Sudden cardiac death caused by myocarditis in persons aged 1–49 years: a nationwide study of 14 294 deaths in Denmark. *Forensic Sci Res* 4(3):247–256
- Ali-Ahmed F, Dalgaard F, Al-Khatib SM (2020) Sudden cardiac death in patients with myocarditis: Evaluation, risk stratification, and management. *Am Heart J* 220:29–40
- Richter S, Schwab T, Berchthold-Herz M, Beyersdorf F, Schlenzak C, Bode C et al (2008) Borderline-Myokarditis als Auslöser für therapierefraktäres Kammerflimmern. *Intensivmedizin und Notfallmedizin* 45(5):287–291
- De Salvia A, De Leo D, Carturan E, Basso C (2011) Sudden cardiac death, borderline myocarditis and molecular diagnosis: evidence or assumption? *Med Sci Law* 51(1_Suppl):27–29
- Corrado D, Basso C, Thiene G (2001) Sudden cardiac death in young people with apparently normal heart. *Cardiovasc Res* 50(2):399–408
- Kragholm KH, Lindgren FL, Zaremba T, Freeman P, Andersen NH, Riahi S et al (2021) Mortality and ventricular arrhythmia after acute myocarditis: a nationwide registry-based follow-up study. *Open Heart* 8(2):e001806
- Verma V, Sondhi S, Sharma R, Mahajan K (2020) COVID-19 associated viral myocarditis: does it exist? *Monaldi archives for chest disease = Archivio Monaldi per le malattie del torace. Monaldi Arch Chest Dis*. <https://doi.org/10.4081/monaldi.2020.1382>
- Siripanthong B, Nazarian S, Muser D, Deo R, Santangeli P, Khanji MY et al (2020) Recognizing COVID-19-related myocarditis: the possible pathophysiology and proposed guideline for diagnosis and management. *Heart Rhythm* 17(9):1463–1471
- Sahin U, Muik A, Derhovanessian E, Vogler I, Kranz LM, Vormehr M et al (2020) COVID-19 vaccine BNT162b1

- elicits human antibody and TH1 T cell responses. *Nature* 586(7830):594–599
27. Chen P, Baldeviano GC, Ligons DL, Talor MV, Barin JG, Rose NR et al (2012) Susceptibility to autoimmune myocarditis is associated with intrinsic differences in CD4(+) T cells. *Clin Exp Immunol* 169(2):79–88
 28. Li C, Chen Y, Zhao Y, Lung DC, Ye Z, Song W et al (2021) Intravenous injection of Coronavirus Disease 2019 (COVID-19) mRNA vaccine can induce acute myopericarditis in mouse model. *Clin Infect Dis* 74(11):1933–1950
 29. Heymans S, Cooper LT (2022) Myocarditis after COVID-19 mRNA vaccination: clinical observations and potential mechanisms. *Nat Rev Cardiol* 19(2):75–77
 30. Röltgen K, Nielsen SCA, Silva O, Younes SF, Zaslavsky M, Costales C et al (2022) Immune imprinting, breadth of variant recognition, and germinal center response in human SARS-CoV-2 infection and vaccination. *Cell* 185(6):1025–40.e14

Authors and Affiliations

Constantin Schwab¹ · Lisa Maria Domke^{1,2} · Laura Hartmann^{1,2} · Albrecht Stenzinger¹ · Thomas Longerich¹ · Peter Schirmacher¹

¹ Institute of Pathology, Heidelberg University Hospital, Universitätsklinikum Heidelberg, Pathologisches Institut, Im Neuenheimer Feld 224, 69120 Heidelberg, Germany

² German Center for Infection Research (DZIF), partner site Heidelberg, Institute of Pathology, Heidelberg University Hospital, Heidelberg, Germany