



GUIDELINES FROM THE WORKING GROUP

Recommendations for Performing Transoesophageal Echocardiography

F. A. Flachskampf¹, P. Decoodt², A. G. Fraser³, W. G. Daniel⁴ and J. R. T. C. Roelandt⁴ for the Subgroup on Transoesophageal Echocardiography and Valvular Heart Disease, on behalf of the Working Group on Echocardiography of the European Society of Cardiology

¹Med. Klinik II, University of Erlangen-Nürnberg, Germany; ²Department of Cardiology, Centre Hospitalier Universitaire Brugmann, Université Libre de Bruxelles, Belgium; ³University of Wales College of Medicine, Cardiff, United Kingdom; ⁴Erasmus Medical Centre Rotterdam, The Netherlands

Please see the Appendix on pages 20 and 21 for an explanation of the abbreviations used within this article.

Introduction: the Need for Guidelines

Transoesophageal echocardiography (TEE) is a diagnostic tool with widespread utilization. Due to its unique potential in improving cardiological diagnosis, the procedure is increasingly applied in small hospitals, private practice, and new settings such as the emergency room. In spite of its frequent usage, there is no generally accepted standard protocol of the examination procedure, which is distinctly different from transthoracic echocardiography. Indeed, this procedure involves patient discomfort, carries a minute risk to the patient, and hence is not easily repeated.

This paper represents an effort by the Subgroup on Transoesophageal Echocardiography and Valvular Heart Disease of the Working Group Echocardiography of the European Society of Cardiology to state succinctly the essential points of the typical TEE exam in adults. The recommendations have been worded from 'desirable' to 'mandatory' according to the individual strength that the authors felt they carry. The wealth of potential indications, pathological findings, and variations in examination technique preclude a comprehensive review, which is available in textbooks and review articles^[1–4]. Similarly, it was not the purpose to write an educational text but rather to briefly describe the minimal requirements for a complete TEE examination. Similar efforts have been undertaken for intraoperative echocardiography by the American Society of Echocardiography^[5].

Address correspondence to: F. A. Flachskampf, Östl.Stadtmauerstr.29, D-91054 Erlangen, Germany.

General Recommendations

Indications

The indications for TEE have widened continuously in recent years. It is clear that this technique is extremely valuable in many conditions, such as aortic dissection, prosthetic valve disease, the search for cardiac source of emboli, detection of endocarditic abscess, emergency care, and intra- and perioperative monitoring. In general, TEE is indicated whenever the transthoracic examination is inconclusive and the clinical question is important enough to warrant the (very small) risk and (moderate) discomfort of the procedure. This may include classic indications for transthoracic echocardiography, such as evaluation of left ventricular function, in patients who are extremely difficult to examine transthoracically (e.g. postoperative and ventilated patients). Essential points for the principal indications are given in Tables 1–5.

Competence

In most European countries TEE must be performed by physicians. Physicians performing TEE should be experienced in transthoracic echocardiography (including Doppler) and have performed at least 100 TEE examinations under the supervision of a cardiologist with extensive experience. A minimum of 50 examinations, but preferably more than 100 per year, are necessary for maintaining competence. This is in line with the requirement of 'level 2' proficiency in general echocardiography for TEE trainees stated in the guidelines of the American Society of Echocardiography^[6], the American College of Cardiology and in the unpublished report of the task force on Standardization and Education of the Working Group Echocardiography of the European Society of Cardiology. The recommended number of TEE examinations for basic training is slightly higher than in the

Tables. Principal TEE indications: essential views and structures in specific clinical conditions.

1. Source of embolism.

Left ventricular apex or aneurysm (transgastric and low transoesophageal two-chamber views).
 Aortic and mitral valve.
 Ascending and descending aorta, aortic arch.
 Left atrial appendage (including pulsed wave Doppler exam); note spontaneous contrast.
 Left atrial body including interatrial septum; note spontaneous contrast.
 Fossa ovalis/foramen ovale/atrial septal defect/atrial septal aneurysm; contrast+Valsalva.

2. Infective endocarditis.

Mitral valve in multiple cross-sections.
 Aortic valve in long- and short-axis views; para-aortic tissue (in particular, short-axis views of aortic valve and aortic root) to rule out abscess.
 Tricuspid valve in transgastric views, low oesophageal view, and right ventricular inflow-outflow view.
 Pacemaker, central intravenous lines, aortic grafts, Eustachian valve, pulmonic valve in longitudinal right atrial views and high basal short-axis view of the right heart (inflow-outflow view of the right ventricle).

3 Aortic dissection, aortic aneurysm.

Ascending aorta in long-axis and short-axis views, maximal diameter, note flap or intramural haematoma, para-aortic fluid.
 Descending aorta in long- and short-axis views, note maximal diameter, flap, intramural haematoma, para-aortic fluid.
 Aortic arch, note maximal diameter, flap, intramural haematoma, para-aortic fluid.
 Aortic valve (regurgitation, annular diameter, number of cusps).
 Relation of dissection membrane to coronary ostia.
 Pericardial effusion, pleural effusion.
 Entry/re-entry sites of dissection (use colour Doppler).
 Spontaneous contrast or thrombus formation in false lumen (use colour Doppler to characterize flow/absence of flow in false lumen).

4. Mitral regurgitation.

Mitral anatomy (transgastric basal short-axis view, multiple lower transoesophageal views). Emphasis on detection of mechanism and origin of regurgitation (detection and mapping of prolapse/flail to leaflets and scallops, papillary muscle and chordal integrity, vegetations, paraprosthetic leaks).
 Left atrial colour Doppler mapping with emphasis on jet width and proximal convergence zone.
 Left upper pulmonary, and, if eccentric jet present, also right upper pulmonary venous pulsed Doppler.

Note systolic or mean blood pressure!

5. Prosthetic valve evaluation.

Morphological and/or Doppler evidence of obstruction (reduced opening/mobility of cusps/disks/leaflets and elevated velocities by CW Doppler).
 Morphological and Doppler evidence of regurgitation, with mapping of the origin of regurgitation to specific sites (transprosthetic, paraprosthetic); presence of dehiscence.
 Presence of morphological changes in the prosthetic structure: calcification, perforation of bioprostheses, absence of occluder.
 Presence of additional paraprosthetic structures (vegetation/thrombus/pannus, suture material, strand, abscess, pseudoaneurysm, fistula).

American guidelines, which specify 25 oesophageal intubations plus 50 supervised TEEs. Since a small, but finite, risk is involved in both the TEE examination and the sedation, physicians must be familiar with resuscitation measures, for which equipment must be readily available in the laboratory. Certain settings, such as congenital heart disease or intra-operative TEE, require specialized additional training.

Patient Consent, Preparation, and Equipment

A history of swallowing problems or evidence of oesophageal disease or recent gastroesophageal surgery should be obtained. A discussion with the patient of the procedure, risks, and benefits, including implications of

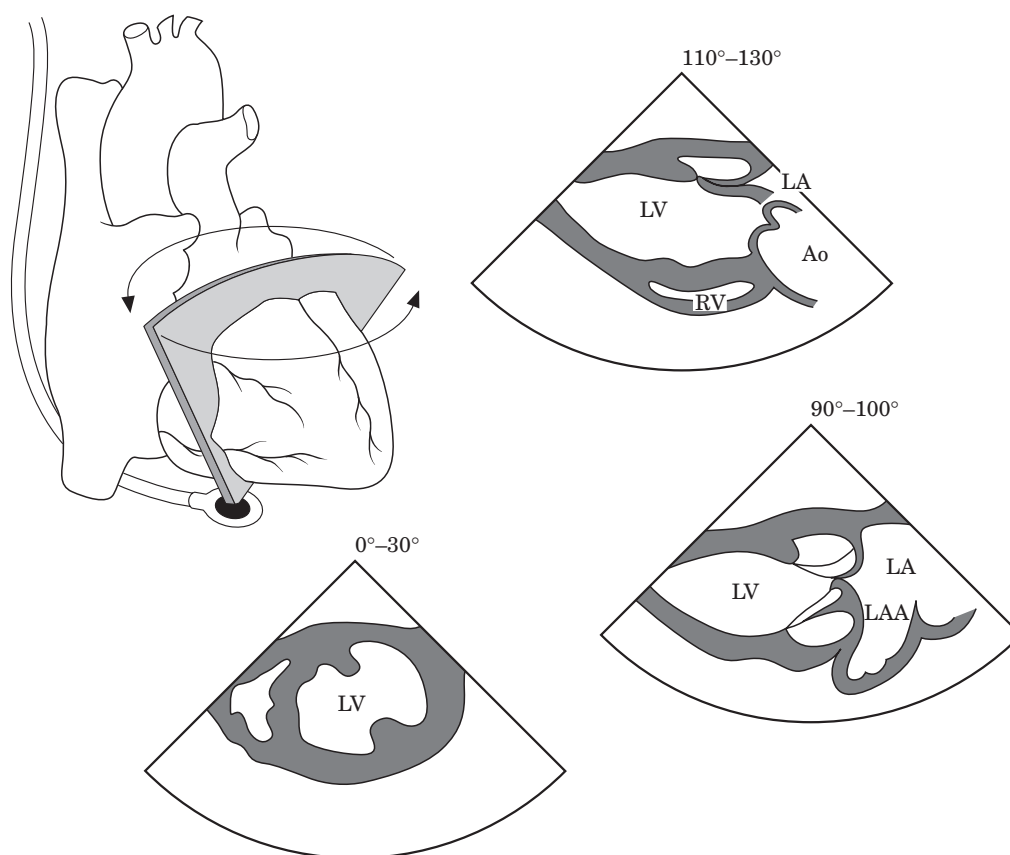


Diagram 1. Transgastric views, with exemplary cross-sections corresponding to (counter-clockwise) the transgastric short axis view at midpapillary level (Fig. 1), the transgastric two-chamber view (Fig. 2), and the transgastric long-axis view of the left ventricle (Fig. 3).

topical anesthesia (oral intake should be avoided for about 2 h after the examination) and sedation (e.g. unfitness for driving for at least 12 h), should precede the examination. Informed patient consent is mandatory in conscious patients. While ideally a written informed consent should be documented, at least a clinical note is recommended indicating that consent was sought and obtained. At least a 4-hour fast (preferably 6 h, with clear liquids allowed until 2 h prior to the examination) before TEE should be observed, except in emergency situations; the possibility of diabetic gastroparesis should be kept in mind. Use of antibiotics is optional in patients at very high risk of endocarditis, e.g. patients with a history of endocarditis. However, benefit from such prophylaxis remains unproven^[8].

Ideally, TEE should be performed with multiplane equipment. The ECG must be monitored throughout the procedure. An intravenous line should be in place both for sedation and in the event of complications, and a supply of oxygen as well as equipment for suction should be at hand. Blood pressure and oxygen saturation monitoring, including baseline values prior to the examination, are desirable.

Dental fixtures have to be removed, and a bite guard should be in place. Topical oropharyngeal anesthesia with an agent such as lidocaine is usually given. Seda-

tives should be used sparingly, if needed, especially in frail or severely compromised patients. A typical dose in a stable patient is 2–4 mg of intravenous midazolam (0.075 mg/kg), but lower doses may be sufficient; other sedatives or analgesics such as fentanyl may be used as well. Whenever sedatives are used, availability of, and experience with, resuscitation equipment is mandatory. A benzodiazepine antagonist, for example flumazenil (0.3–0.6 mg), must be available. Some centres use a drying agent, such as glycopyrrolate bromide.

The instrument tip has to be unlocked during intubation of the oesophagus. Awake patients are usually intubated in the lateral decubitus position, to facilitate drainage of saliva. In ventilated patients, use of a laryngoscope can facilitate oesophageal intubation. Any clear persistent resistance to advancing the instrument mandates termination of the examination, and endoscopy should be performed before re-examination. After each examination, probes have to be disinfected, inspected for damage, and checked for electrical safety according to manufacturer's guidelines. Rubber covers for the TEE probe in theory protect against transmission of infectious agents and provide some electrical insulation in case of a current leak, as long as no tear of the cover occurs.

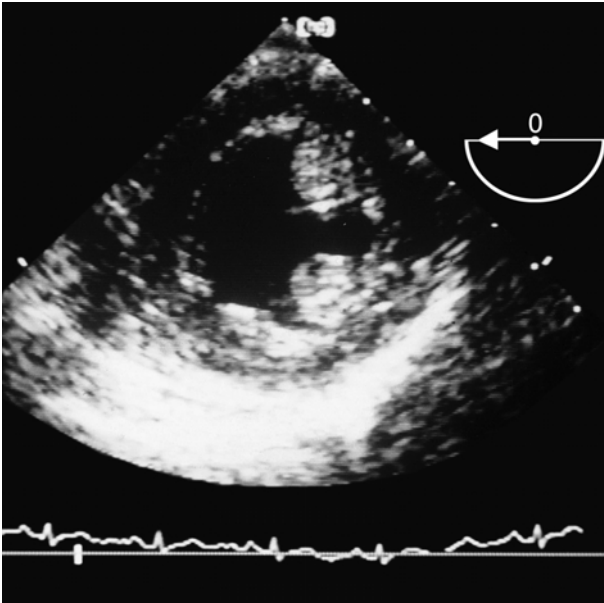


Figure 1. Transgastric short-axis view of the left ventricle at the midpapillary level.

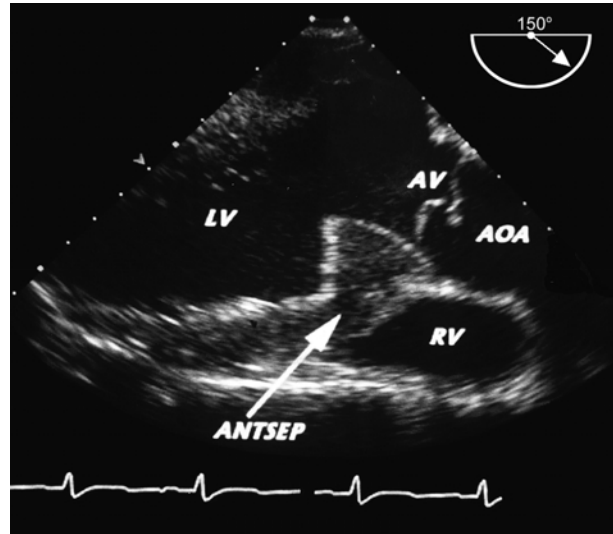


Figure 3. Transgastric long-axis view of the left ventricle.

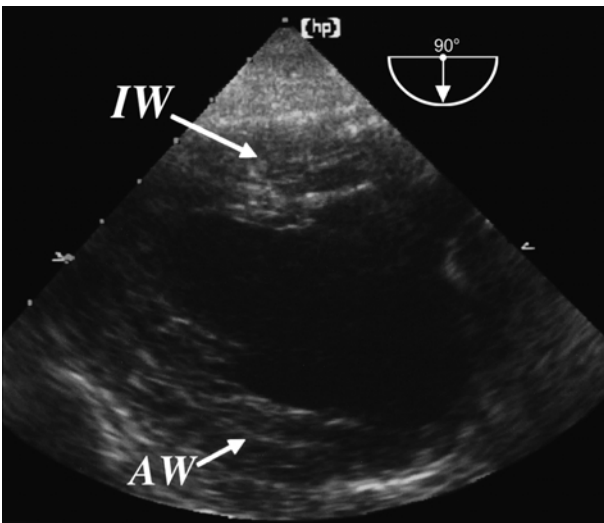


Figure 2. Transgastric two-chamber view. The apex is to the left, and the mitral valve to the right in the image.

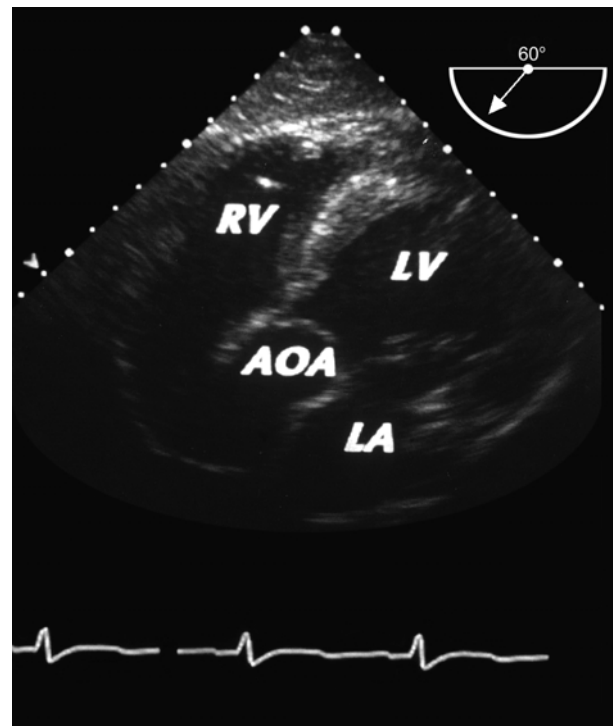


Figure 4. Deep transgastric long-axis view of the left ventricle.

Documentation

Video recording or extensive digital documentation of the examination is mandatory. A written report and a log of examinations, the use of echo contrast, adjunctive medication, and examiners must be kept. In the report it is desirable (especially with computerized report generation) to specify whether cardiac structures have or have not been studied, in order to convey the information as to whether a structure is truly normal or simply has not been (sufficiently) visualized. It is mandatory to note all side-effects and complications.

General Course of the Examination

Unlike transthoracic echocardiography, TEE is uncomfortable for the patient. Therefore the examination time is limited, and the procedure cannot be repeated as frequently as a transthoracic echo. The examiner must therefore ensure that: (i) the diagnostic goal is satisfied; (ii) preferentially the structures not well visualized by transthoracic echo are thoroughly investigated (e.g. the left atrial appendage and the aorta), and (iii) that the

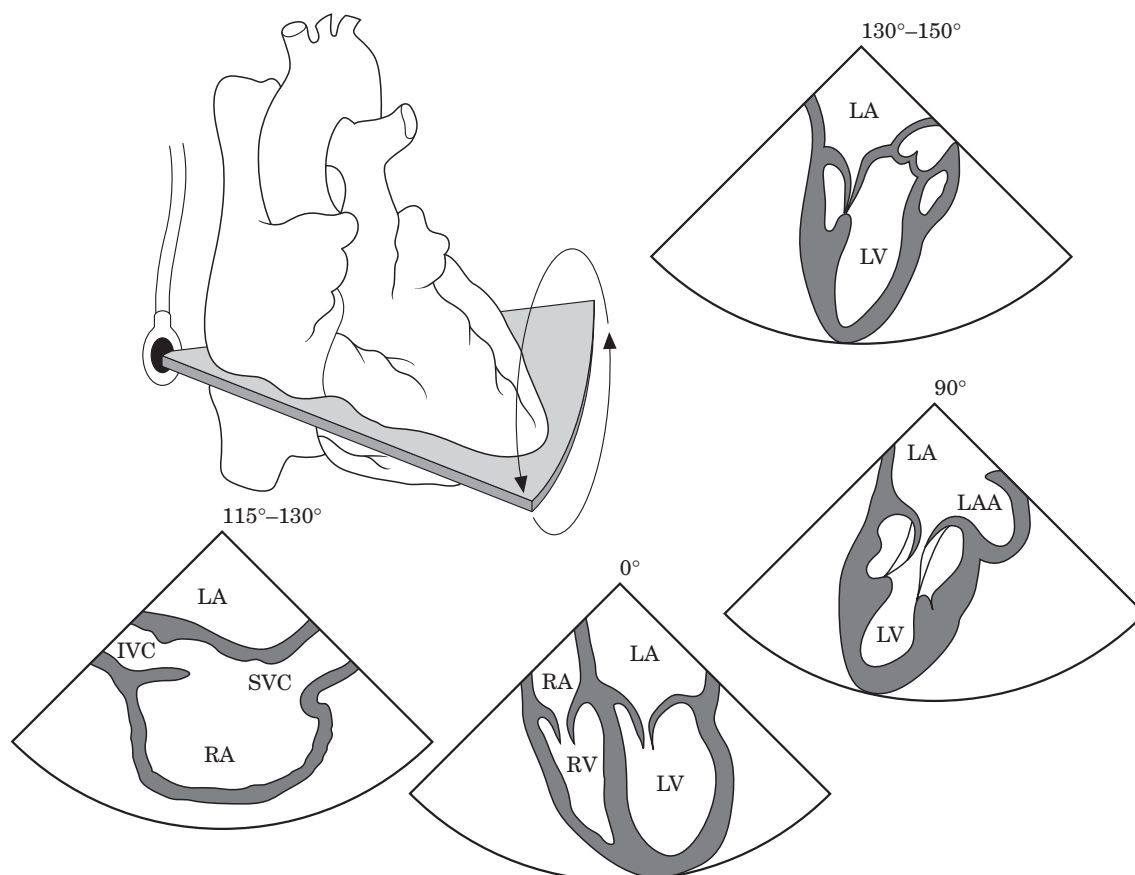


Diagram 2. Lower-middle transoesophageal views, with exemplary cross-sections corresponding to (counter-clockwise) the four-chamber view (Fig. 6), transoesophageal two-chamber view (Fig. 7), and transoesophageal long axis view of the left ventricle (cf. Fig. 8). From this transducer location, right heart structures can be visualized. A right atrial longitudinal view is visualized at 115–130 degrees (Fig. 10).

study is complete. If possible, the following protocol of the examination should be followed and the boldfaced views obtained (sometimes not all of these views are of satisfactory quality). Although any number of additional views may be necessary to better delineate pathological findings (e.g. vegetations, thrombi, etc.), and the patient's tolerance sometimes limits the available examination time, the boldfaced views are essential for a complete TEE examination, and colour Doppler, pulsed wave and continuous Doppler should be used as indicated. Analogous to transthoracic echocardiography, views are mainly defined by internal landmarks, not by specification of probe position and plane angulation. In the following, the designations of views are in analogy to the classic two-dimensional (2D) transthoracic views. For example, the term 'long-axis view of the left ventricle' denotes a view that incorporates the apex, inflow and outflow tract of the left ventricle, the mitral valve, the aortic valve, and which cuts tangentially through the right ventricle. Where degrees of viewing plane are given, 0 degrees denotes a transverse and 90 degrees a longitudinal view, with clockwise plane rotation when looking in

the direction of the ultrasound beam. Plane rotation (or switching from transverse to longitudinal in biplane probes), shaft rotation, antelexion, retroflexion, and sideward flexion of the tip, and finally probe advancement and withdrawal are the manoeuvres available to the examiner to change the position of the view. Antelexion flexes the tip mechanically upward anteriorly, thereby usually improving contact with the anterior gastric or oesophageal wall, and retroflexion flexes it upward posteriorly, thereby often deteriorating transducer contact with the gastric or oesophageal wall. Sideward flexion (to the right or left of the transducer face) can be used instead of plane rotation to fine-tune views and improve acoustic coupling, but is less important with the use of multiplane transducers. Probe shaft rotation is described as clockwise or counterclockwise as seen from the examiner's viewpoint looking down the shaft of the probe.

The following description is intended to outline a complete examination. Patient discomfort or consequences of the findings (e.g. in the presence of aortic dissection) may necessitate shortening the examination to focus on the clinical question. On the other hand,

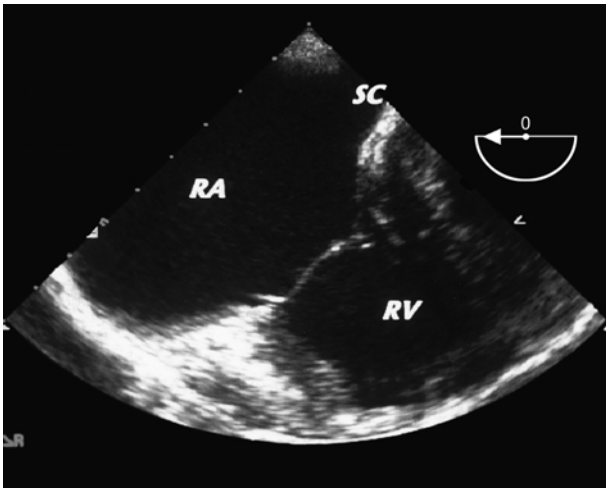


Figure 5. Diaphragmatic right ventricular inflow view.

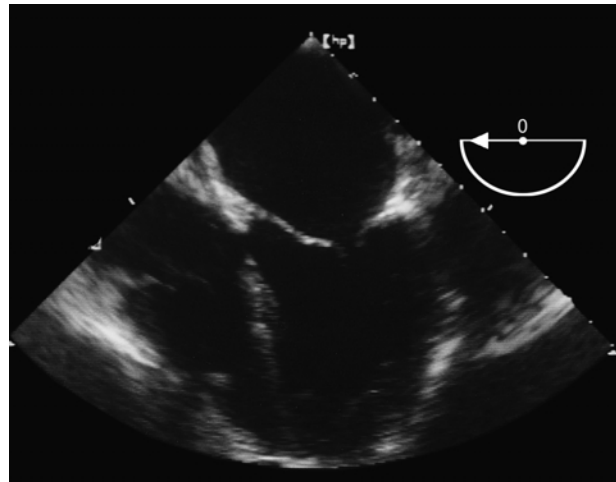


Figure 6. Transoesophageal four-chamber view.

pathological findings or special questions may necessitate a more detailed examination of particular structures, which is beyond the scope of this article.

The typical TEE examination comprises three major steps:

- the transgastric examination
- the proper transoesophageal examination, which may be conceptually divided into (i) lower oesophageal views, mainly to image the ventricles, and (ii) upper transoesophageal views, mainly to image the valves, atria, and great vessels. However, sharply defined transducer positions do not exist, since they vary individually and have to be adjusted for each view.
- the examination of the aorta.

The sequence of these elements may be chosen individually; the following is one widely used approach.

A: Transgastric Views (Diagram 1)

The transducer initially is positioned in the upper stomach, enabling **left ventricular short-axis and two-chamber views** (Figs 1 and 2). In the left ventricular short-axis view at the mid-papillary level (at 0–30 degrees), the anterolateral papillary muscle is seen at approximately 5 o'clock and the posteromedial approximately between 11 and 2 o'clock. The free wall of the right ventricle is seen on the left sector side. Counter-clockwise, the mid segments of the septal, anteroseptal, anterior (farthest from the transducer), lateral, posterior, and inferior (closest to the transducer) left ventricular walls are seen. In the left ventricular two-chamber view (at 90–100 degrees), the inferior wall is seen in the near field of the sector and the anterior wall

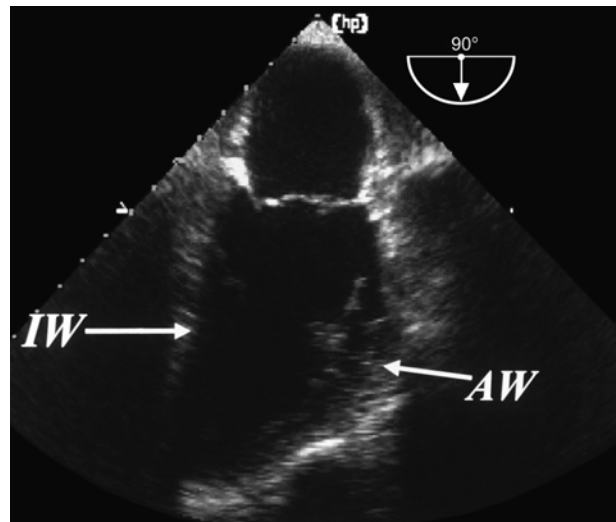


Figure 7. Transoesophageal two-chamber view.

at the bottom of the sector. The apex, which often is not well visualized, is to the left and the mitral valve to the right of the sector. Wall motion abnormalities, thrombi, and pathology of the subvalvular mitral apparatus, which is particularly well displayed in the transgastric two-chamber view, should be noted.

The **long-axis view of the left ventricle**, with assessment of left ventricular outflow tract and aortic valve, is obtained at approximately 110–130 degrees and sometimes minor clockwise shaft rotation (Fig. 3). The aortic valve is seen in the far field. Elevated or reversed flow velocities in the outflow tract or through the aortic valve should be documented. It is frequently difficult to achieve this view, and the ascending aorta is not seen well. Additionally, or alternatively in case of difficulty in obtaining the long-axis view of the left ventricle from the typical transgastric position, a **deep transgastric long-axis view or five-chamber view** (Fig. 4), including the

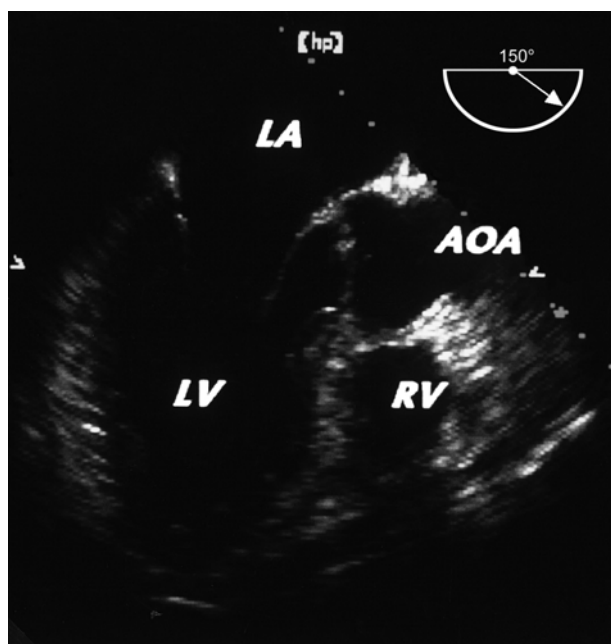


Figure 8. Transoesophageal long-axis view of the left ventricle.

aortic valve, can be obtained by advancing the probe further into the gastric fundus and using maximal ante-flexion of the probe, thus achieving an inverted transducer position. Note that this view will display cardiac structures roughly like a transthoracic apical four-chamber view, i.e. upside down compared to the transoesophageal four-chamber view. Rotation to 60–90 degrees creates a **modified transgastric apical long-axis view** of the left ventricle. These views are particularly useful for the Doppler examination of the left ventricular outflow tract and aortic valve.

A **short-axis view of the mitral valve** is obtained further basally from the mid-papillary muscle short-axis view by slightly withdrawing and ante-flexing the instrument, and sometimes adding 10–20 degrees of rotation. The origin of mitral regurgitation jets by colour Doppler, as well as flail or prolapsing portions, and systolic anterior motion of the leaflets, can be detected in this view. Although this view is often not easy to obtain, it is very helpful in assessing the origin of mitral regurgitant jets.

Additional views of the right heart, which are not routinely obtained but are important whenever right heart pathology has to be evaluated, are generated by rotating the probe from the transgastric left ventricular short-axis position to the right, positioning the right ventricle in the centre of the sector, and steering the plane angulation first to approximately 30 degrees, producing a **short-axis view of the tricuspid valve**, with the posterior leaflet to the upper left, the septal leaflet to the upper right, and the large anterior leaflet in the lower half of valve cross-section. A **right ventricular inflow view** can be obtained by further rotation. At approximately 90 degrees a long axis of the right ventricular inflow is

seen, which is analogous to the left ventricular two-chamber view in that the apex is to the left and the right atrium to the right. Further rotation discloses the right ventricular outflow tract, with the pulmonary valve located at the bottom of the sector.

B: Lower Transoesophageal Views (Diagram 2)

Withdrawal of the probe to a low transoesophageal position is usually performed with the imaging plane in the transverse (0 degrees) position. Passing the diaphragm, the **inflow tract of the right ventricle and the tricuspid valve** are visualized in a long-axis view (Fig. 5). Immediately adjacent to the septal tricuspid leaflet, the orifice of the coronary sinus is seen, which courses upward. The anterior tricuspid leaflet is seen to the left, and the septal to the right.

Reaching the lower oesophagus, a (foreshortened) **transoesophageal four-chamber view** (at approximately 0 degrees) is obtained (Fig. 6). Sometimes a low degree of rotation (10–20 degrees) is useful to exclude the aortic valve. The probe should be straightened after withdrawal from the stomach to minimize foreshortening, as long as image quality is maintained. In the transoesophageal four-chamber view the left ventricle is on the right side of the sector and the right ventricle on the left. The left atrium is on top, and septal and lateral walls of the left ventricle, as well as the right ventricular free wall, are seen. The anterior mitral leaflet is seen on the left and the posterior on the right side; the septal tricuspid leaflet is on the right side and the anterior tricuspid leaflet on the left side. From the same transducer position, the mitral valve and left ventricle can be comprehensively scanned, the left atrium always remaining on top. The **transoesophageal two-chamber view** (Fig. 7) is obtained at approximately 60–90 degrees together with a small amount of retroflexion of the tip to visualize the true apex, with the convex anterior wall to the right, the straight inferior wall to the left, and the apex in the far field. The posterior mitral leaflet is on the left side and the anterior leaflet on the right side, or, in intermediate views between four-chamber and two-chamber view, portions of the posterior mitral leaflet are seen on both sides of the anterior leaflet. Frequently the left atrial appendage is seen on the right side of the base of the left ventricle (in the sector image). Further plane rotation brings into view the **transoesophageal long-axis view** of the left ventricle (Fig. 8) at approximately 130–150 degrees, with the anterior mitral leaflet, the aortic valve and ascending aorta, and the anteroseptal left ventricular segments on the right side (from near to far field), and the posterior mitral leaflet and posterior left ventricular wall on the left side. The left atrium continues in the near field of the transducer, and the left ventricular apex in the far field. These three views of the left ventricle (four-chamber, two-chamber, and long-axis) are the essential oesophageal views for evaluating

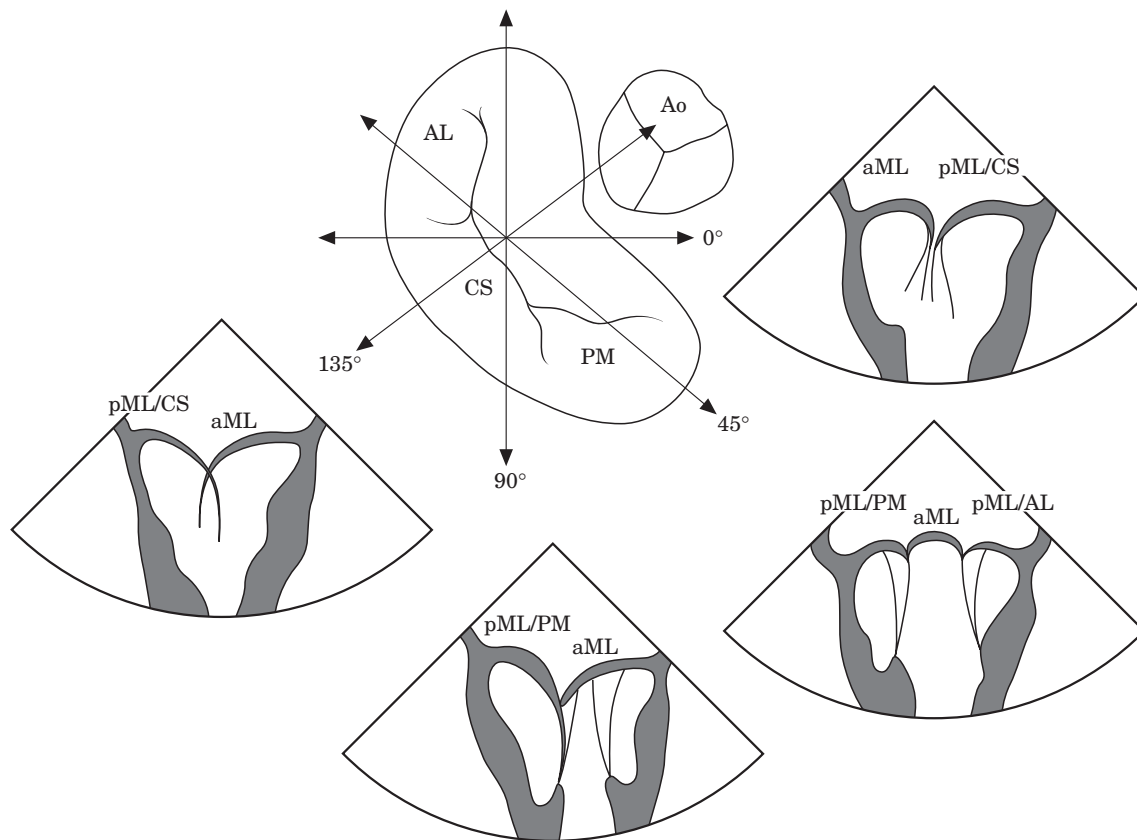


Diagram 3. Mapping of mitral pathology. Four cross-sections centred on the mitral valve and the relationship of the anterior (aML) and posterior (pML) mitral leaflets are seen in these cross-sections: at 0 degrees, corresponding to a four-chamber view (Fig. 6), at 45 degrees, representing an intermediate view, at 90 degrees, corresponding to a two-chamber view (Fig. 7), and at 135 degrees, corresponding to a long-axis view (Fig. 8) of the left ventricle. Different scallops of the pML are visualized in the different views: the central scallop (PML/CS) is seen in the four-chamber and the long-axis views, the anterolateral scallop (PML/AL) in the 45 degrees intermediate view, and the posteromedial (PML/PM) in the two-chamber and in the intermediate view.

the left ventricle, including segmental wall motion abnormalities, in a fashion that allows application of the 16 segment model^[9].

From the same probe location right heart structures can be visualized. By positioning, for example, the interatrial septum and the right atrium in the centre of the image (approximately 115–130 degrees), the fossa ovalis, inferior and superior vena cava and the Eustachian valve are visualized.

The mitral valve can be studied in detail (after appropriate depth reduction) in the same views enumerated for the left ventricle. The use of **multiple transoesophageal cross-sections of the mitral valve** (Diagram 3), especially with a multiplane transducer, including spectral Doppler of transmitral flow and colour Doppler mapping of the left atrium, allows mapping of mitral pathology and regurgitant jet origin to leaflets and leaflet segments (scallops in the posterior mitral leaflet). In the presence of more than mild mitral regurgitation, particular care should be taken to identify and localize the morphological basis of regurgitation (e.g. prolapse, flail,

restriction, annular dilatation, perforation, etc.). Pulsed Doppler tracings of pulmonary venous flow should be recorded (ideally in both the left and the right upper pulmonary veins in the presence of an eccentric jet, and at 1 cm or more distance from the orifice). If there is a mitral prosthesis, the whole circumference should be visualized by positioning the prosthesis in the centre of the sector image and rotating the cross-section systematically in small increments. If a biplane probe is used, the mitral valve and left atrium should be scanned by systematic antelexion and retroflexion of the transverse (horizontal) plane and sideward rotation of the longitudinal (vertical) plane, as well as sideward flexion of the probe tip, if necessary.

Spontaneous echo contrast ('smoke') in the left atrium and/or appendage should be noted. Since spontaneous echo contrast is somewhat gain-dependent, it should be ensured that gain levels are high enough not to miss it, and that there is a swirling motion in the left atrium which distinguishes it from pure noise at too high a gain level.

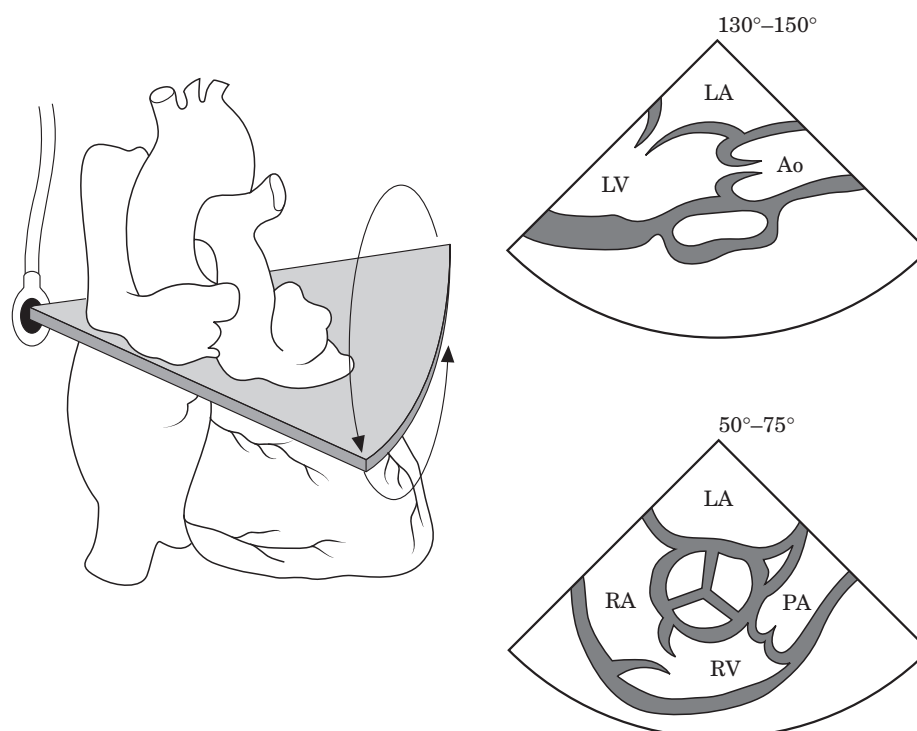


Diagram 4. Upper transoesophageal views of the aortic valve in long-axis (130–150 degrees, [Fig. 9c](#)) and short axis views (55–75 degrees, [Fig 9a,b](#)).

C: Upper Transoesophageal Views

Further withdrawal of the probe will display the aortic valve and both atria from an upper transoesophageal position. Image depth should be reduced from the setting used for the left ventricle. **Short- and long-axis views of the aortic valve** (Diagram 4, [Fig. 9](#)) should be obtained by looking for a circular aortic root in the short axis (at 50–75 degrees) views and a central closure of the two visualized aortic leaflets, as well as a maximal visualized length of the ascending aorta in the long axis view (at 130–160 degrees). The short-axis view shows the left coronary cusp in the upper right third, the non-coronary cusp in the upper left third, and the right coronary cusp in the lower third (anteriorly), while the long-axis view has the non-coronary aortic cusp on top and the right coronary cusp at the bottom (i.e. anteriorly). If the transducer is withdrawn a few millimetres from the aortic valve short-axis view, both coronary ostia can be identified, located at approximately 2 o'clock (left coronary ostium) and 6 o'clock (right coronary ostium) of the circumference of the aortic root ([Fig. 9b](#)). The right coronary ostium is frequently more easily visualized in the long-axis view of the aortic valve and the ascending aorta. Colour Doppler mapping should be performed in both aortic valve views, and in the presence of stenosis a continuous wave Doppler can be attempted, although this will yield significant underestimation because of the large angle between

ultrasound beam and flow direction; presence of high velocities will, however, indicate significant stenosis. More reliable Doppler assessment of aortic velocities is achieved in transgastric long-axis views. The maximal visualizable extent of the **ascending aorta in a long-axis view** (usually several centimetres) should be documented, which necessitates some withdrawal of the probe to display the upper part of the ascending aorta (displayed on the right sector side), with an angle between 130 and 150 degrees.

The right atrium, the tricuspid valve, inflow and outflow tract of the right ventricle, the pulmonary valve, and the main pulmonary trunk are seen in counterclockwise continuity, with the aortic valve in the centre, in the short-axis view of the aortic valve ([Fig. 9a](#)). This view (also called the **right ventricular inflow-outflow view**^[5]) resembles a parasternal aortic valve short-axis view (although upside down). Colour Doppler evaluation of the tricuspid and — less satisfactorily — the pulmonary valve can be performed. If visualization of the distal right ventricular outflow tract, the pulmonary valve, and the proximal main pulmonary artery are of particular interest, a plane rotation to a lower angle (100–130) or counterclockwise shaft rotation brings into view these structures.

From an upper transoesophageal window the interatrial septum with the fossa ovalis should be visualized in at least two planes (transverse and longitudinal view). The **transverse view of the right atrium** is usually a minor

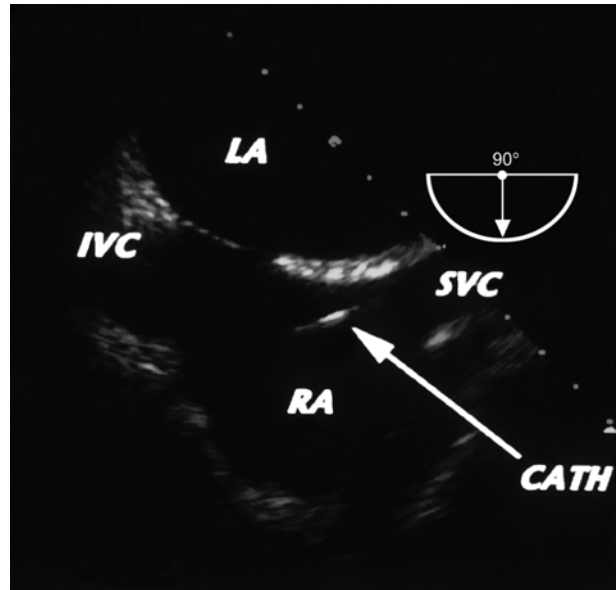
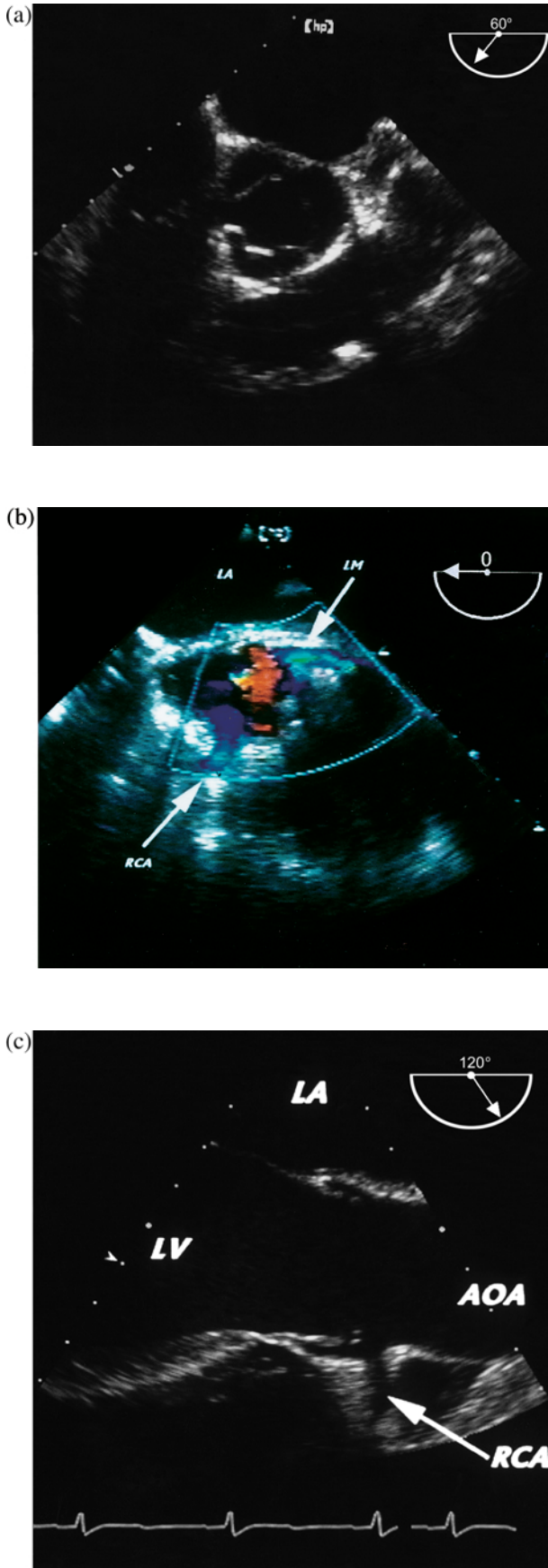


Figure 10. Interatrial septum and right atrium in longitudinal view.

modification of the transoesophageal four-chamber view with reduced depth. It shows the left atrium on top, then the interatrial septum as an approximately horizontal structure, and the tricuspid valve to the right. Neither caval vein is seen in this view. The **longitudinal view of the right atrium** (at 90 degrees, Diagram 2; also called the **bicaval view**^[5]) displays the orifices of the superior (right sector side) and inferior caval vein (left sector side) and the right atrial appendage (sector bottom) (Fig. 10); the tricuspid valve is not seen. This view particularly allows the evaluation of pacemaker leads, intravenous lines and masses attached to them. **Colour Doppler mapping of the interatrial septum** should be performed at a low pulse repetition frequency (low-velocity scale) to better recognize low-velocity jets. If patency of the foramen ovale is an important consideration (stroke, pulmonary embolism, positive end-expiratory pressure ventilation, congenital heart disease, risk assessment of decompression sickness, and other conditions), echo contrast should be applied and monitored during spontaneous breathing and, importantly, on release of a Valsalva manoeuvre. Any kind of echo contrast can be used, including agitated blood or infusion solutions, as long as it yields dense opacification of the right atrium.

Views of the cranial structures of the heart and great vessels (Diagram 5) are obtained by withdrawing and

Figure 9. (a) Aortic valve short axis (with view of right atrium at 9–11 o'clock, tricuspid valve at 9 o'clock, and right ventricle). (b) Coronary ostia immediately superior of aortic valve (short axis view of ascending aorta). (c) Aortic valve long-axis view.

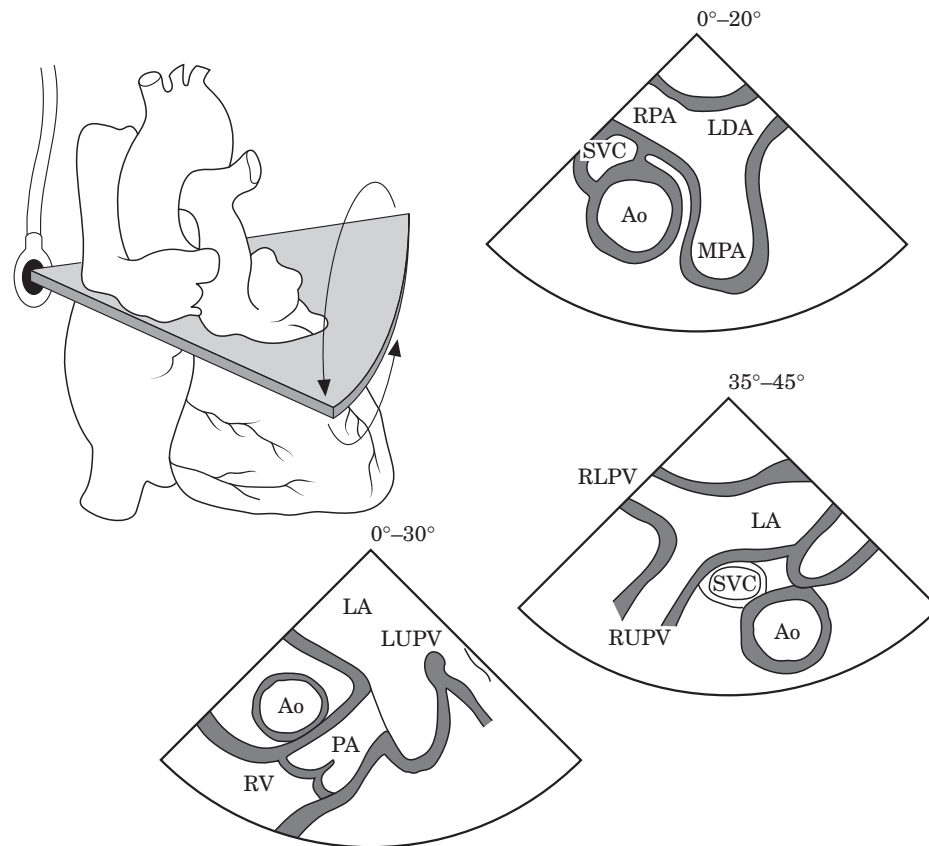


Diagram 5. Upper transoesophageal views of the great vessels and atrial appendage (counter-clockwise): the transverse view of the left atrial appendage and the left upper pulmonary vein (35–45 degrees, **Figs 11** and **12**), the intermediate view of ascending aorta, left atrium and right pulmonary veins, and with anterioflexion of the probe a transverse view of the ascending aorta, superior vena cava and main pulmonary artery with its bifurcation are obtained (0–20 degrees, **Fig. 13b**).

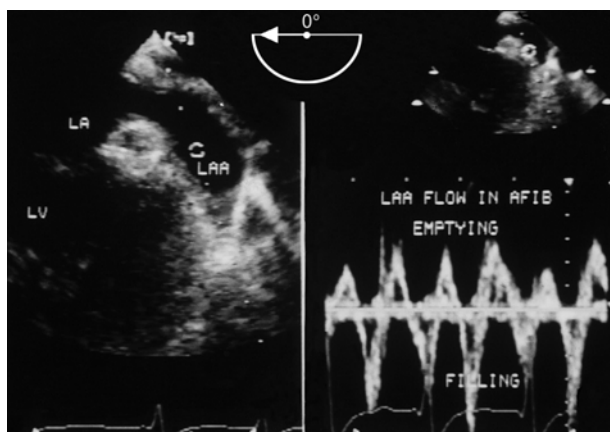


Figure 11. (Left). Left atrial appendage, with pulsed Doppler sample volume. (Right). Recording of emptying (upward) and filling (downward) velocities in atrial fibrillation.

anteflecting the probe in the transverse (0 degree) plane from a position showing the mitral valve in the centre of the sector. On the right side of the screen, the left

atrial appendage is seen (**Fig. 11**); careful study of this structure of varying size, shape and orientation may require additional plane rotation. Pulsed Doppler recording of appendage flow is useful to assess the risk of thrombus formation. Further withdrawal and ante-flexion displays the **left upper pulmonary vein** (**Fig. 12**). Clockwise shaft rotation displays the **short-axis view of the ascending aorta**, accompanied on the left side by the **superior vena cava** (**Fig. 13a**), and on the right side by the **main pulmonary artery**. The right pulmonary artery courses to the left side of the sector posteriorly of the ascending aorta (**Fig. 13b**). The left pulmonary artery is poorly seen and courses to the right side of the sector.

The **right upper pulmonary vein** is seen coursing downward and rightward at the junction of right atrium and superior vena cava and posterior to the latter, both in transverse and longitudinal views (**Fig. 13a**). This junction is the location of the transthoracically (often poorly) visualized sinus venosus atrial defects. In a longitudinal (90 degrees) view, the orifice of the right upper pulmonary vein can be located between left atrium and right pulmonary artery.

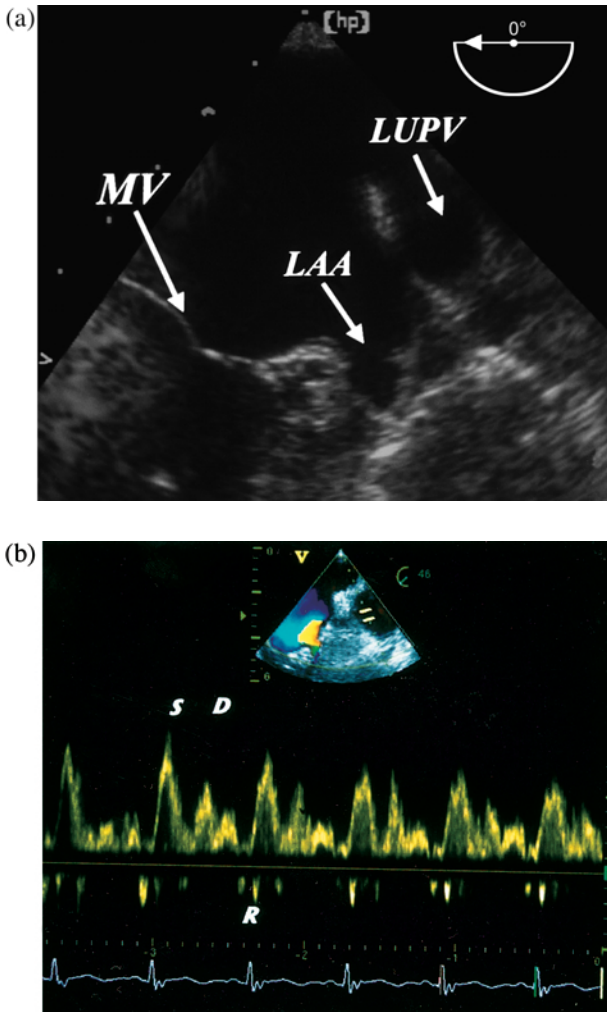


Figure 12. (a) Left atrial appendage and left upper pulmonary vein. (b) Pulsed Doppler recording of normal pulmonary venous inflow in the left upper pulmonary vein.

Aortic Views

Finally, the probe should be rotated towards the descending aorta. Especially in older patients, the complete length of the thoracic **descending aorta** (Fig. 14) should be scanned in short-axis views, supplemented by long-axis views if pathology is detected. The location of findings in the descending aorta can be described either by the distance of the probe tip to the frontal teeth, or by the cardiac structures at the same depth level. The take-off of the (left) subclavian artery can usually be seen, and often part of the distal arch and the supra-aortic branches can be visualized. Clockwise shaft rotation and slight probe withdrawal at the junction of aortic arch and descending aorta displays the **long axis of the aortic arch**, with the anterior aortic arch wall at the bottom of the sector, and partially the superior ascending aorta. At 90 degrees, a short-axis view of the aortic arch is obtained.

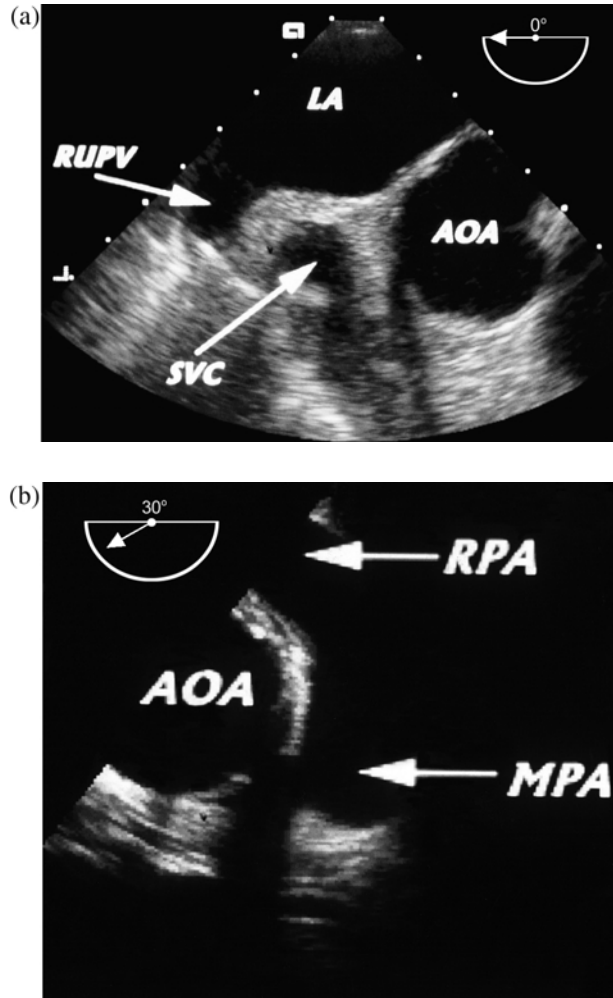


Figure 13. (a) Short-axis view of ascending aorta, superior vena cava, and right upper pulmonary vein. (b) Short-axis view of ascending aorta and main pulmonary artery, with bifurcation and origin of right pulmonary artery.

Conclusion

TEE offers unique advantages in certain clinical scenarios (Tables 1–5) and is superior to conventional transthoracic echocardiography for visualizing specific structures. For optimal use, the operator should be aware of the clinical circumstances and critical questions and follow a systematic approach for collecting the data necessary to answer the clinical question.

Acknowledgements

The authors wish to acknowledge valuable input from many members of the Working Group Echocardiography of the European Society of Cardiology, in particular Leo Baur, Leiden, The Netherlands; Raimund Erbel, Essen, Germany; Andreas Franke, Aachen, Germany; Adrian Ionescu, Cardiff, United Kingdom; Maria Lengyel, Budapest, Hungary; Petros Nihoyannopoulos, London, United Kingdom; Mauro Pepi, Milano, Italy; and William Stewart, Cleveland, U.S.A.

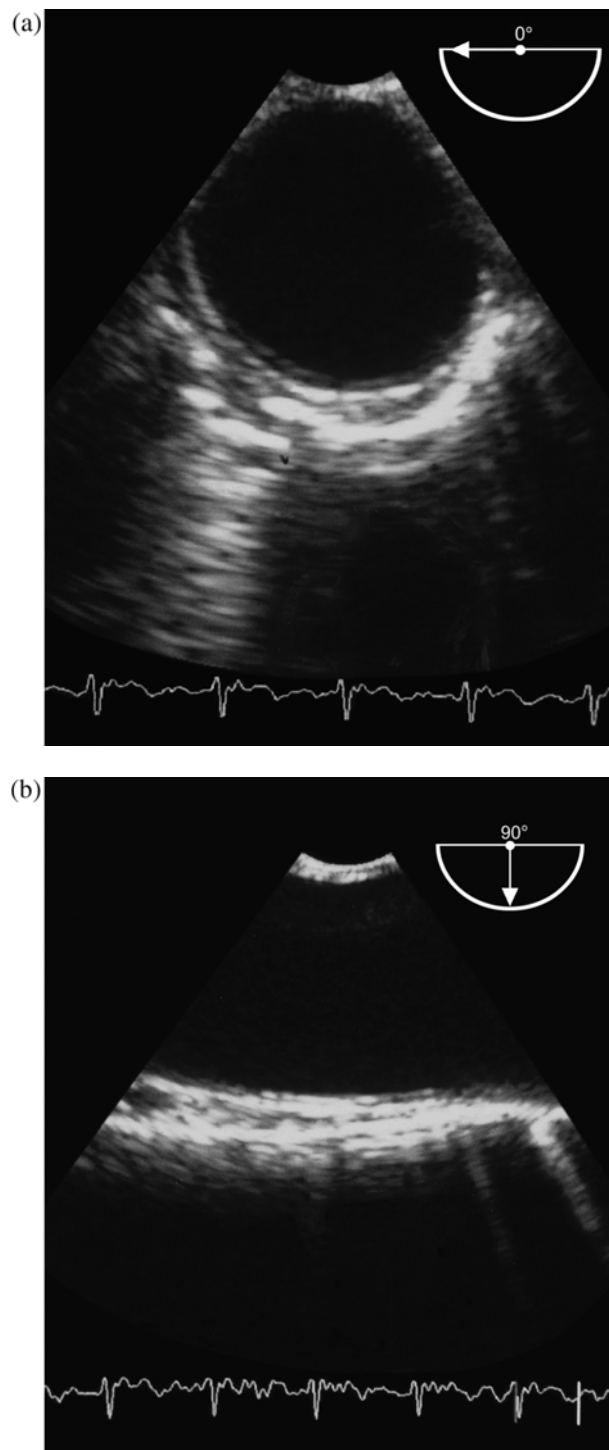


Figure 14. Descending aorta: (a) short-axis view; (b) long-axis view.

References

[1] Sutherland GR, Roelandt JRTC, Fraser AG, Anderson RA. *Transesophageal Echocardiography in Clinical Practice*. London: Gower Medical Publishing, 1991.
 [2] Roelandt JRTC, Pandian N (eds). *Multiplane Transesophageal Echocardiography*. New York: Churchill Livingstone, 1996.

[3] Freeman WK, Seward JB, Khanderia BK, Tajik AJ. *Transesophageal Echocardiography*. Boston: Little, Brown, 1994.
 [4] Daniel WG, Mügge A. Transesophageal echocardiography. *New Engl J Med* 1995; **332**: 1268–1279.
 [5] Shanewise JS, Cheung AT, Aronson S *et al.* ASE/SCA guidelines for performing a comprehensive intraoperative multiplane transesophageal echocardiography examination: recommendations of the American Society of Echocardiography Council for Intraoperative Echocardiography and the Society of Cardiovascular Anesthesiologists Task Force for Certification in Perioperative Transesophageal Echocardiography. *J Am Soc Echocardiogr* 1999; **12**: 884–900.
 [6] Stewart WJ, Aurigemma GP, Bierman FZ *et al.* Guidelines for training in adult cardiovascular medicine. Core Cardiology Training Symposium (COCATS). Task Force 4: training in echocardiography. *J Am Coll Cardiol* 1995; **25**: 16–19.
 [7] Pearlman AS, Gardin JM, Martin RP *et al.* Guidelines for physician training in transesophageal echocardiography: Recommendations of the American Society of Echocardiography Committee for Physician Training in Echocardiography. *J Am Soc Echocardiogr* 1992; **5**: 187–194.
 [8] Dajani AS, Bisno AL, Durack DT *et al.* Prevention of bacterial endocarditis. Recommendations by the American Heart Association. *JAMA* 1990; **264**: 2919–2922.
 [9] American Society of Echocardiography Committee on Standards, Subcommittee on Quantitation of Two-dimensional Echocardiograms. Recommendations for quantitation of the left ventricle by two-dimensional echocardiography. *J Am Soc Echocardiogr* 1989; **2**: 358–367.

Appendix

The following abbreviations are used in the figures:

AL	anterolateral commissure or scallop of the posterior mitral leaflet
AL-PM	anterolateral papillary muscle
AML	anterior mitral leaflet
ANT	anterior wall of aortic arch
ANTSEP	anteroseptal wall of left ventricle
AOA	ascending aorta
AV	aortic valve
AW	anterior wall of left ventricle
CS	central scallop
D	diastolic inflow wave of pulmonary venous flow velocity
IVC	inferior vena cava
IW	inferior wall of left ventricle
LA	left atrium
LAA	left atrial appendage
LM	left main coronary artery
LPA	left pulmonary artery
LUPV	left upper pulmonary vein
LV	left ventricle
MPA	main pulmonary artery
PM	posteromedial commissure or scallop of the posterior mitral leaflet
PML	posterior mitral leaflet
PM-PM	posteromedial papillary muscle
POST	posterior wall of aortic arch
R	reverse end-diastolic flow wave of pulmonary venous flow velocity
RCA	right coronary artery

RPA	right pulmonary artery	S	systolic inflow wave of pulmonary venous
RV	right ventricle		flow velocity
RUPV	right upper pulmonary vein	SC	coronary sinus
RLPV	right lower pulmonary vein	SVC	superior vena cava