

GUIDELINES AND RECOMMENDATIONS

A minimum dataset for a standard transoesophageal echocardiogram: a guideline protocol from the British Society of Echocardiography

Richard Wheeler^{1,†}, Richard Steeds^{2,‡}, Bushra Rana³, Gill Wharton⁴, Nicola Smith², Jane Allen⁴, John Chambers⁵, Richard Jones⁶, Guy Lloyd⁷, Kevin O’Gallagher⁸ and Vishal Sharma⁹

¹University Hospital of Wales, Cardiff, UK

²Queen Elizabeth Hospital, University Hospital Birmingham NHS Foundation Trust, Birmingham, UK

³Papworth Hospital, Cambridge, UK

⁴York Teaching Hospital NHS Foundation Trust, York, UK

⁵Guy’s and St Thomas’ NHS Foundation Trust, London, UK

⁶Portsmouth Hospitals NHS Trust, Portsmouth, UK

⁷Barts Heart Centre, Barts Health NHS Trust, London, UK

⁸King’s College Hospital NHS Foundation Trust, London, UK

⁹Royal Liverpool and Broadgreen University Hospitals, Liverpool, UK

[†]R Wheeler is the lead author

[‡]R Steeds is the Guidelines Chair

Correspondence should be addressed to V Sharma
Email
vishal.sharma@rlbuht.nhs.uk

Abstract

A systematic approach to transoesophageal echocardiography (TOE) is essential to ensure that no pathology is missed during a study. In addition, a standardised approach facilitates the education and training of operators and is helpful when reviewing studies performed in other departments or by different operators. This document produced by the British Society of Echocardiography aims to provide a framework for a standard TOE study. In addition to a minimum dataset, the layout proposes a recommended sequence in which to perform a comprehensive study. It is recommended that this standardised approach is followed when performing TOE in all clinical settings, including intraoperative TOE to ensure important pathology is not missed. Consequently, this document has been prepared with the direct involvement of the Association of Cardiothoracic Anaesthetists (ACTA).

Key Words

- ▶ trans-oesophageal echocardiography
- ▶ 2D echocardiography
- ▶ guidelines

1. Introduction

- This document aims to provide a framework for performing an adult transoesophageal echocardiography (TOE) in a variety of clinical settings such as cardiology outpatients, cardiac theatre, and intensive care. The layout is not only a minimum dataset but also proposes a recommended sequence in which to perform a comprehensive study. This is supported by text that gives a brief

description of important issues at each view (Tables 1 and 2, Fig. 1, Tables 3, 4, 5, 6, 7, 8, 9 and 10).

- This will hopefully promote a systematic approach to TOE, which is critical not only for education and training, but also when reviewing studies performed by different operators or in different hospital sites.
- It is recognised that not all views may be possible in patients and in particular there are certain views that are sometimes poorly tolerated e.g. deep transgastric, upper

oesophageal. The decision to omit various views must therefore be made by the operator taking into account the balance between the risks of inadequate data vs patient safety and comfort.

2. Patient safety

- TOE is semi-invasive with the potential for serious albeit rare complications. The indications, risks, and precautions for TOE have been described previously (1, 2). It is mandatory to have a routine checklist for certain conditions and problems that may either contraindicate the study or be a cause for concern; e.g., oesophageal stricture, previous gastro-oesophageal surgery, and loose teeth/dentures. This checklist should be documented, preferably in a specific transoesophageal document/care-plan within the medical notes. The British Society of Echocardiography (BSE) and the Association of Cardiothoracic Anaesthetists (ACTA) have produced a checklist that may be used for this purpose (3).
- Conscious sedation is used in many units as a routine to facilitate TOE. Only individuals trained in the use of such techniques should administer sedative drugs. Continuous monitoring of oxygen saturations during and after the procedure is mandatory with full resuscitation equipment being readily available. The BSE has produced guidance for the safe use of sedation (10).
- Echo labs should have written protocols for the decontamination of probes and sterility of the procedure room. These protocols can be based on the BSE guidance for probe decontamination but should be agreed by the local trust and infection control departments (11).

3. Identifying information

- Patient name.
- A second unique identifier such as hospital number or date of birth.
- Identification of the operator; e.g., initials.

4. Electrocardiogram

- An electrocardiogram should be attached ensuring good tracings to facilitate the acquisition of complete digital loops.

5. Intraoperative TOE

- Intraoperative TOE is now a well-established procedure that may involve cardiologists, cardiothoracic

anaesthetists or cardiac physiologists. It is strongly recommended that such studies follow precisely the same format as a TOE performed in different settings; e.g., a diagnostic study in cardiology outpatients. This approach has a sound medico-legal justification and minimises the risk of missing important diagnoses that may not be apparent on the preoperative transthoracic echocardiogram (TTE). With this in mind, this document has been prepared with the direct involvement of the ACTA and its representatives Justiaan Swanevelder, David Duthie, Donna Greenhalgh, Niall O'Keeffe, and Nick Fletcher.

- To that end, intraoperative TOE needs to be well coordinated in order to allow time for a complete study. It is desirable to obtain most of the data before the chest/pericardium is open as this may affect the images; e.g., dimensions of the tricuspid annulus.
- The clinician must be aware that the physiology of the patient may be significantly different during intraoperative TOE due to the effects of general anaesthesia, fluid status, or vasoactive drugs. This is an important principle in deciding whether the TOE data should be obtained before the patient is listed for surgery. The most widely quoted example is in the assessment of the severity of mitral regurgitation, which may be misinterpreted depending on the physiology at the time of the study.

6. Duration

- It is recommended that 45–60 min is allowed for each TOE. This includes preparation of the patient, e.g., cannulation, consent etc., and may also include a pre-procedure TTE. This should be done in accordance with the BSE guidelines for TTE (4). However it is recognised that certain clinical circumstances may necessitate a more focused approach to the image acquisition but this is a clinical judgement.

7. Reporting

- All studies should be completed by issuing a formal report that is documented within the patient's medical records. Ideally this should be in the form of a standardised computerised report available on all contemporary echo systems. The TOE images should be stored in a format that is reliable and easy to access for review. It is recommended that this take the form of digital storage with regular server back up.

8. Measurements

- This document indicates several measurements that can be made during a routine TOE. However, it is expected that the vast majority of patients will have already have had TTE. There is a more extensive evidence base for TTE measurements and therefore these should be used where possible.
- Some TOE measurements are difficult to perform due to proximity of the transducer; e.g., left atrial (LA) dimensions. Some measurements may be prone to error if off-axis images have been obtained, e.g., left ventricular dimensions.
- However, certain measurements, e.g. annular dimensions or aortic root size, are usually more precise on TOE.

Table 1 Assessment of the left ventricle.

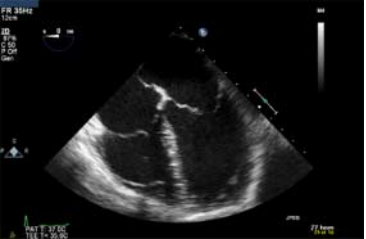
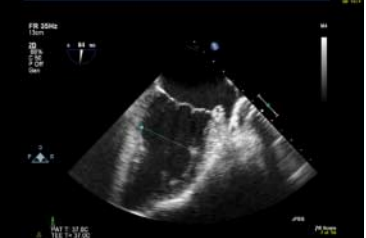
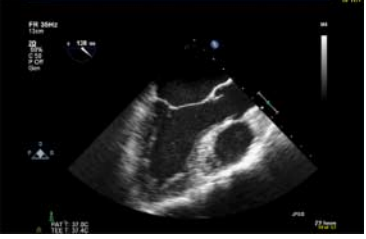
View (modality)	Measurement	Explanatory note	Image
Mid oesophageal Four-chamber, 0–20° (2D)		Assessment of LV function: inferoseptum and anterolateral walls May require extension of probe to bring apex in to view Focus can be moved towards the apex to improve quality of image Careful assessment for apical thrombus/masses	
Mid oesophageal Two-chamber, 80–100° (2D)	LVDd/s	Assessment of LV function: inferior and anterior walls Measurements can be made with 2D calipers for LV dimensions at the junction of the basal and middle thirds of the LV (8)	
Mid oesophageal long axis, 120–150° (2D)		Assessment of LV function: inferolateral and anteroseptal walls	

Table 2 Assessment of the mitral valve.


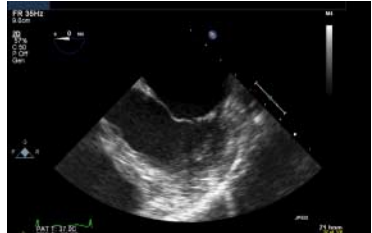

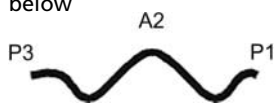



View (modality)	Measurement	Explanatory note	Image
Mid oesophageal Four-chamber, 0–20° (2D)		Assessment of MV: several sections of the MV can be imaged in this view (see Fig. 1 for a full explanation) Particular attention to the mitral annulus, leaflet morphology, leaflet motion, and the sub-valvular apparatus	
Mid oesophageal Four-chamber, 0–20° (2D)		Assessment of MV: A1/P1 Flexion or withdrawal of the probe slightly will bring A1/P1 into view The anterolateral commissure can be assessed	
Mid oesophageal Bi-commissural view, 60–70° (2D)	Commissure to commissure annular dimension (end diastole and end systole)	Assessment of MV: P3/A2/P1 The imaging plane now brings both commissures into view This is an appropriate anatomical plane to measure the annular dimension (see Fig. 1) From left to right, the scallops seen in this view are P3/A2/P1 as shown below	
			
Mid oesophageal Two-chamber, 90° (2D)		Assessment of MV: P3/A1	
Mid oesophageal Posteromedial commissure, 90° (2D)		Assessment of MV: P3/A3 The posteromedial commissure can be seen by turning the probe towards the aorta and then coming back to the MV	

Table 2 Continued.

View (modality)	Measurement	Explanatory note	Image
Mid oesophageal Long axis, 120–150° (2D)	Anterior to posterior annulus dimension (end diastole and end systole)	Assessment of MV: P2/A2 This is the second anatomical plane which allows the mitral annulus to be measured (see Fig. 1)	

All of these views should be reassessed with colour flow Doppler over the mitral valve. PW and CW should be used in either the four-chamber or long-axis views

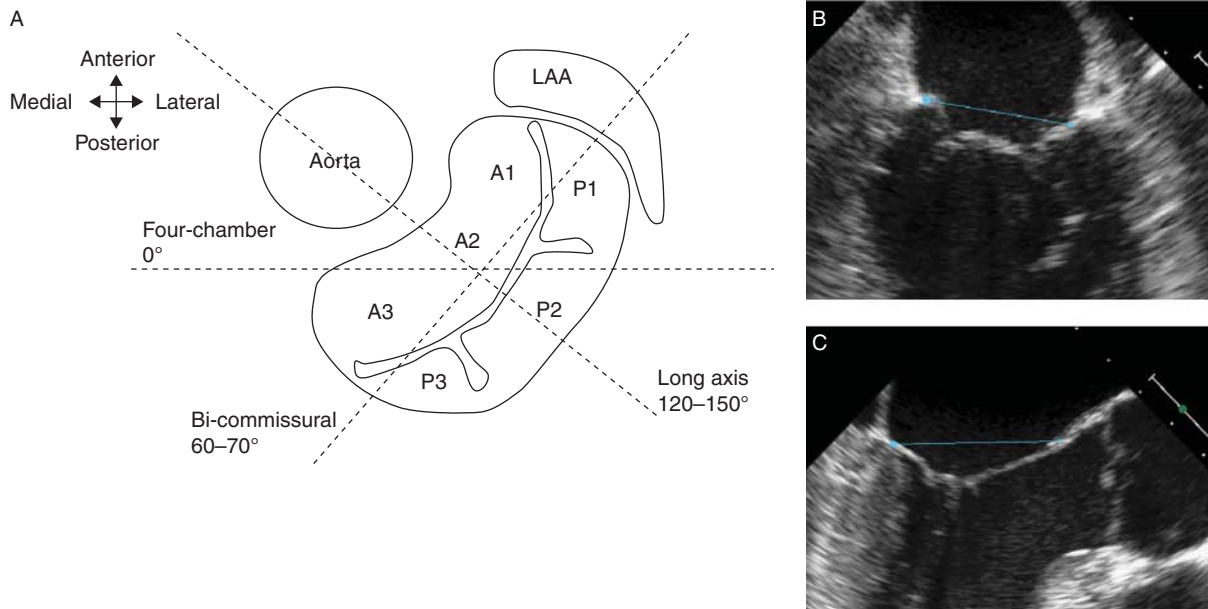
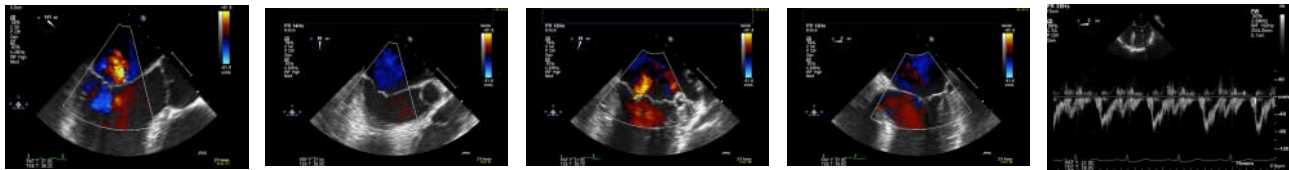
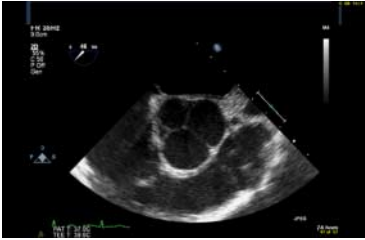

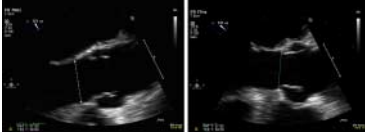


Figure 1

(A) This figure depicts the different sections of the MV that are visualised in the standard mid oesophageal imaging planes. The four-chamber view at 0° is an oblique cut through the MV and will visualise different parts of the valve according to the depth of probe insertion, the degree of flexion/extension and also the anatomical lie of the heart which may vary between patients. This means that A3/A2/A1 extending to P2/P1 may be in

view at any one time. It is not usually possible to image A3/P3 at 0°. (B and C) These panels illustrate the correct anatomical planes for annular dimensions – the bi-commissural view (B, major axis) and the long axis view (C, minor axis) (5). These measurements in end diastole and end systole provide useful data for the cardiac surgeon in the setting of mitral repair. There is a paucity of data for normal ranges indexed for body surface area.

Table 3 Assessment of the aortic valve.

View (modality)	Measurement	Explanatory note	Image
Mid oesophageal Short axis, 40–60° (2D)		Assessment of the AV. Flexion/ extension or insertion and withdrawal of the probe will allow imaging above and below the valve making sure to image at the leaflet tips to assess opening The coronary ostia can be seen above the valve	
Mid oesophageal Long axis, 120–150° (2D)	LVOT/aortic annulus	The NCC is seen in the near field with the RCC in the far field Movement of the probe from left to right is essential in this view to image the extremities of the valve	
Mid oesophageal Long axis, 120–150° (2D)	LVOT/aortic annulus	The LVOT dimension is measured in mid-systole from the septal endocardium to the anterior mitral valve leaflet ~0.5–1 cm from the valve orifice (6) The aortic 'annulus' is measured from the hinge points of the AV in mid-systole	

These views should be repeated with colour flow Doppler. Alignment is not possible for spectral Doppler. The four-chamber mid-oesophageal view can also be used with slight flexion or withdrawal of the probe in order to assess the ventricular aspect of the AV and also to image aortic regurgitation.

Table 4 Assessment of the left atrium and left atrial appendage.

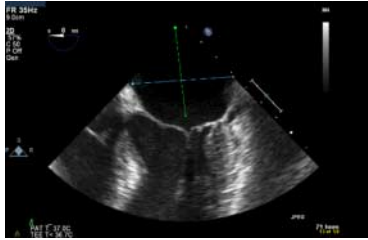


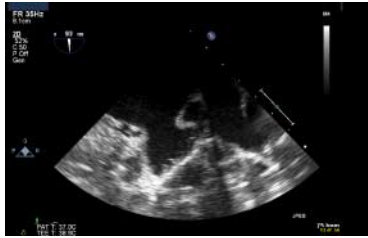
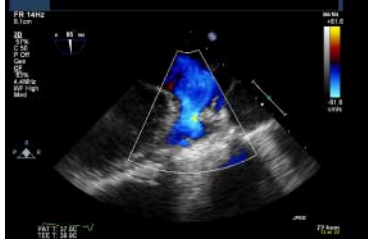
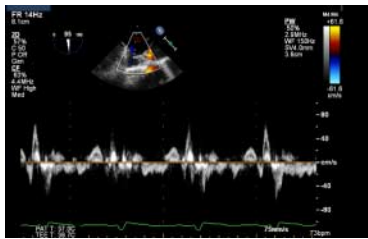


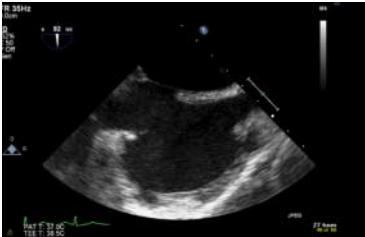
View (modality)	Measurement	Explanatory note	Image
Mid oesophageal Four-chamber, 0–20° (2D)	LA dimension in two axes	The probe needs to be moved from left to right to image all parts of the LA completely The LA area/volume can be difficult to obtain from TOE due to the proximity to the transducer. Dimensions in two axes can be measured in this view (semi-quantitative)	
Mid oesophageal Two-chamber, 90° (2D)		As above, movement of the probe from left to right will maximise the chance of imaging all corners of the LA	
Mid oesophageal Four-chamber, 0–20° (2D)		The LAA can be imaged often helped by flexion or withdrawal of the probe slightly Careful attention should be made to distinguish pectinate muscles from thrombus The depth and focus can be adjusted to maximise the quality	
Mid oesophageal LAA view, 60–130° (2D)		It is essential to image the LAA in at least two planes. One or more lobes can be seen when the multiplane is turned beyond 90° Movement of the probe to the left can keep the LAA in view Look out for spontaneous echo contrast	
Mid oesophageal LAA view, 0–130° (CFM)		Colour Doppler can help assess the extent of the LAA cavity	
Mid oesophageal LAA view, 0–130° (PW)	Emptying velocities	PW Doppler can be placed within the mouth of the LAA (not more than 1 cm) in order to quantify emptying velocities	

Table 5 Assessment of the inter-atrial septum.

View (modality)	Measurement	Explanatory note	Image
Mid oesophageal IAS, 0–20° (2D)		The interatrial septum is well seen on TOE due to its close proximity to the transducer Lipomatous hypertrophy is frequently seen in this view	
Mid oesophageal IAS, 40–80° (2D)		The presence of a patent foramen ovale can be assessed in this view. Note the insertion of the Eustachian valve near the inferior vena cava in the right atrium	
Mid oesophageal Bicaval, 80–120° (2D)		It is essential to image the IAS in multiple views to exclude ASD/PFO. Sinus venosus defects can be easily missed by incomplete imaging of the IAS near the insertion of the IVC and SVC	

All of these views should be repeated with colour flow Doppler to look for ASD/PFO. Reducing the Nyquist limit may help to visualise low velocity flow across the septum. Always remember to reset the Nyquist limit for the rest of the study.

Table 6 Assessment of the pulmonary veins.

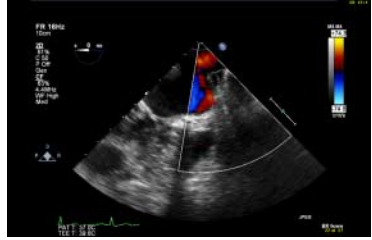

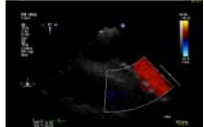

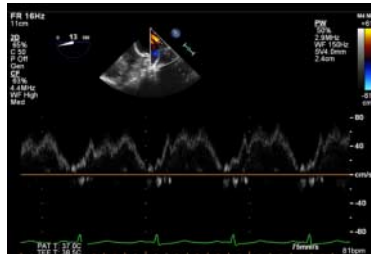
View (modality)	Measurement	Explanatory note	Image
Mid oesophageal Four-chamber, 0–20° (CFM)		The upper pulmonary veins tend to insert more vertically into the LA. Flexion or withdrawal of the probe can bring into view Note the close relationship of the LUPV to the LAA	
Mid oesophageal Four-chamber, 0–20° (CFM)		The lower pulmonary veins tend to insert more horizontally into the LA. Inserting the probe further and turning further to the left can help image the LLPV	
Mid oesophageal Four-chamber, 0–20° (CFM)		After turning the probe to the right, flexion or withdrawal of the probe can help image the RUPV	
Mid oesophageal Modified bicaval view, 90–110° (CFM)		The RUPV can often be easier to image by starting with the bicaval view to visualise the SVC and then turning the probe further to the right whilst keeping the colour Doppler in position	 SVC  RUPV
Mid oesophageal Four-chamber, 0–20° (CFM)		Inserting the probe further and turning the probe to the right can bring in the RLPV	
Mid oesophageal Four-chamber, 0–20° (PW)		The PW cursor is placed 1 cm into the mouth of any pulmonary vein but usually the LUPV is the best aligned Two pulmonary veins should be analysed in each patient	

Table 7 Assessment of right heart.






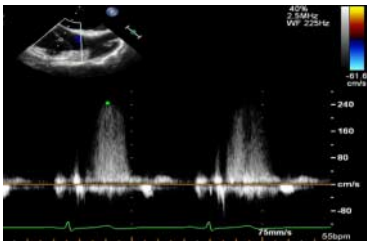

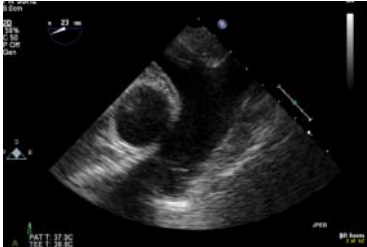
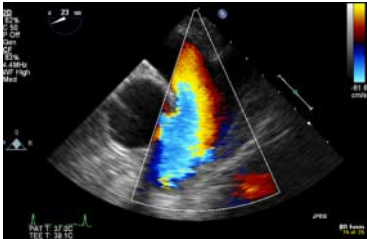
View (modality)	Measurement	Explanatory note	Image
Mid oesophageal Four-chamber, 0–20° (2D)		The right ventricle can be assessed in more detail for regional and global function The septal leaflet is on the right with the anterior or posterior leaflet on the left depending on how far the probe is inserted (7)	
Mid oesophageal Four-chamber, 0–20° (2D)	RV size Tricuspid annulus	RV size can be assessed at the base and the mid point in end diastole (8) The tricuspid annulus can be measured at end systole and end systole from hinge point to hinge point ^a	
Mid oesophageal RV inflow/outflow, 60–80° (2D)		Regional and global RV function can be further assessed The posterior leaflet is on the left with the anterior leaflet to the right The pulmonary valve can also be seen in this view	
Mid oesophageal modified RV inflow, 110–130° (2D)		The tricuspid valve can also be imaged at this multiplane angle aided by turning the probe to the right	
Mid oesophageal modified RV inflow, 110–130° (CFM)		This view often allows TR to be assessed using CW Doppler due to the vertical alignment	
Mid oesophageal modified RV inflow, 110–130° (CW)	TR Vmax	Doppler estimate of RVSP may be performed	

Table 7 Continued.

View (modality)	Measurement	Explanatory note	Image
Mid oesophageal RV outflow, 60–80° (2D)	Pulmonary valve annulus	The pulmonary valve is often better imaged by using the zoom	
Mid oesophageal Main PA, 0° (2D)	Main pulmonary artery	The main pulmonary artery can be imaged by withdrawing the probe slightly at 0°. The pulmonary artery bifurcation is well seen with the right main pulmonary artery heading behind the ascending aorta	
Mid oesophageal Main PA, 0° (CFM)		Colour Doppler will demonstrate flow towards the transducer in systole	

All of these views should be repeated with colour flow Doppler to assess the tricuspid and pulmonary valves. PW/CW can be used to assess flow through the pulmonary valve in the mid oesophageal view at 0°.

^aTricuspid annular dimensions in the four-chamber view provide useful data for the cardiac surgeon in the setting of tricuspid repair. There is a paucity of data regarding normal ranges indexed for body surface area.

Table 8 Transgastric views – assessment of the left ventricle.

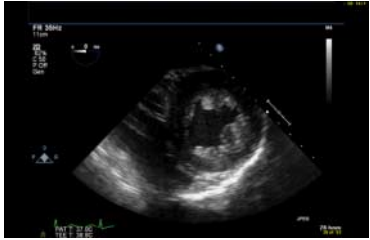
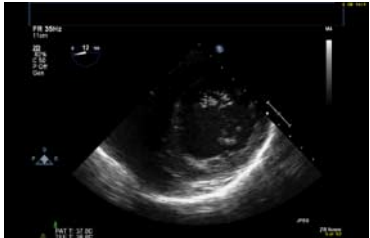
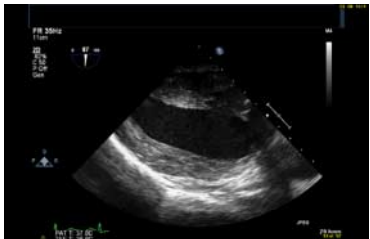
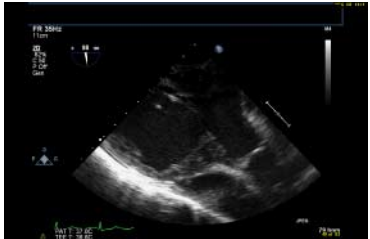
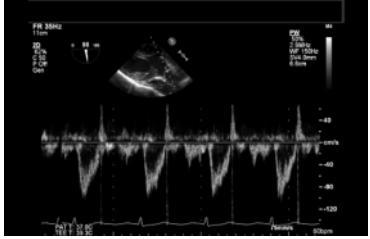
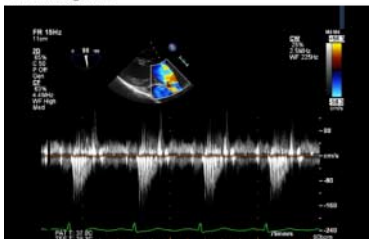
View (modality)	Measurement	Explanatory note	Image
Transgastric mid LV short axis, 0–20° (2D)	IVSd LVDD/s	After insertion of the probe into the stomach, flexion will bring this image into view Regional and global LV systolic function can be assessed Chamber dimensions can be measured either with 2D calipers or M-mode placed vertically within the sector (8)	
Transgastric Basal LV short axis, 0–20° (2D)		Withdrawing the probe slightly will image the base of the LV with the MV enface This is a good view for assessing the mitral commissures and imaging the site of MR with colour Doppler	
Transgastric Two-chamber, 80–100° (2D)	LVDD/s	The inferior wall is seen within the near field with the anterior wall in the far field LV dimensions may be obtained by 2D callipers or M-mode as for the short axis views (8) This view is the best for assessing chordal pathology and length	
Transgastric long axis 90–120° (2D, CFM, PW, CW)		Turning the probe slightly to the right may help image the AV	
Transgastric long axis, 90–120° (PW, CW)	PW LVOT CW AVmax	Colour Doppler guides the alignment of PW in the LVOT and CW through the AV	<p>PW LVOT:</p>  <p>CW through AV:</p> 
		The mid oesophageal views do not allow spectral doppler analysis of the AV	

Table 8 Continued.

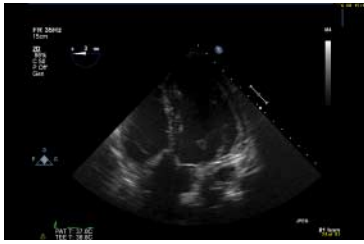
View (modality)	Measurement	Explanatory note	Image
Deep transgastric, 0° (2D, CFM, PW, CW)	PW LVOT CW AVmax	The probe is inserted further in to the stomach with flexion in order to obtain this image which is similar to a transthoracic apical five-chamber view Colour Doppler can guide the use of PW in the LVOT and CW through the AV	

Table 9 Transgastric assessment of the right heart.

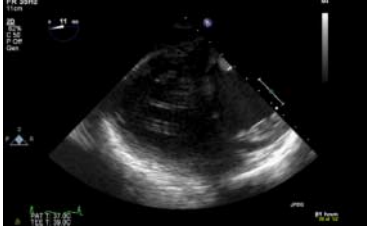
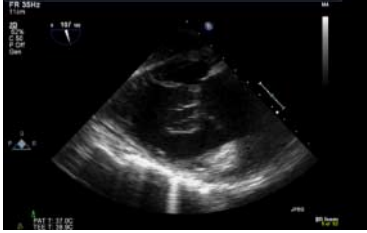
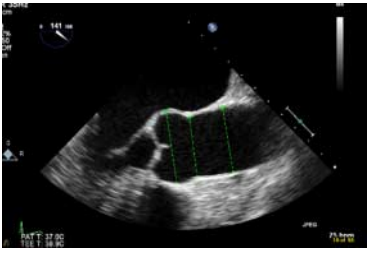





View (modality)	Measurement	Explanatory note	Image
Transgastric Short axis RV, 0–20° (2D)		All three leaflets of the tricuspid valve can be seen in this view. RV regional and global function can be assessed	
Transgastric RV inflow, 80–100° (2D)		The tricuspid leaflets and the sub-valvular apparatus are well seen. This is also an excellent view for assessment of pacing wires in the RV	

Table 10 Assessment of the aorta.

View (modality)	Measurement	Explanatory note	Image
Mid oesophageal Long axis aortic root, 120–150° (2D)	Sinuses of Valsalva, sinotubular junction, and ascending aorta	Internal dimensions can be measured in mid diastole (8) Measurements at the level of the sinuses of Valsalva should be indexed for body surface area (9)	
Mid oesophageal Long axis Ascending aorta, 100–120° (2D)	Ascending aorta	The upper ascending aorta can be imaged by withdrawing the probe slightly and reducing the multiplane angle The right pulmonary artery is in the near field	
Mid oesophageal Short axis Ascending aorta, 0° (2D)		Withdrawal of the probe will image the ascending aorta in short axis above the leaflets of the AV The main pulmonary artery is on the right	
Mid oesophageal Descending thoracic aorta, 0° (2D)	Descending thoracic aorta	The entire thoracic aorta can be assessed by withdrawing the probe. Abnormalities can be annotated at a level corresponding with the distance from the incisors as marked on the probe	
Mid oesophageal Descending thoracic aorta, 90° (2D)	Descending thoracic aorta	Atheromatous plaque is often well seen in the long axis view	
Upper oesophagus Aortic arch, 0° (2D)		The upper oesophageal views are often poorly tolerated by the patient. The probe is turned to the right to keep the aorta in view. The proximal arch is to the left with the distal arch to the right	

Abbreviations

2D	Two-dimensional
A1, A2, A3	Scallops of anterior mitral valve leaflet
ASD	Atrial septal defect
AV	Aortic valve
CFM	Colour flow Doppler
CW	Continuous wave Doppler
ECG	Electrocardiogram
IAS	Interatrial septum
IVC	Inferior vena cava
IVSd/s	Inter ventricular septal dimension in diastole and systole
LA	Left atrium
LAA	Left atrial appendage
LLPV	Left lower pulmonary vein
LUPV	Left upper pulmonary vein
LV	Left ventricle
LVDd/s	Left ventricular diameter in diastole and systole
LVOT	Left ventricular outflow tract
MR	Mitral regurgitation
NCC	Non coronary cusp
P1, P2, P3	Scallops of posterior mitral valve leaflet
PA	Pulmonary artery
PFO	Patent foramen ovale
PW	Pulse wave Doppler
RA	Right atrium
RCC	Right coronary cusp
RLPV	Right lower pulmonary vein
RUPV	Right upper pulmonary vein
RV	Right ventricle
RVd	Right ventricular cavity diameter in diastole
RVSP	Right ventricular systolic pressure
SVC	Superior vena cava
TOE	Transoesophageal echocardiography
TR	Tricuspid regurgitation
TTE	Transthoracic echocardiogram

Declaration of interest

This manuscript was prepared by the British Society of Echocardiography Education Committee. The authors declare that there is no conflict of interest that could be perceived as prejudicing the impartiality of this guideline.

Funding

This guideline did not receive any specific grant from any funding agency in the public, commercial or not-for-profit sector.

References

1 Hahn RT, Abraham T, Adams MS, Bruce CJ, Glas KE, Lang RM, Reeves ST, Shanewise JS, Siu SC, Stewart W *et al.* 2013 Guidelines for performing

a comprehensive transesophageal echocardiographic examination: recommendations from the American Society of Echocardiography and the Society of Cardiovascular Anesthesiologists. *Journal of the American Society of Echocardiography* **26** 921–964. (doi:10.1016/j.echo.2013.07.009)

2 Flachskampf FA, Badano L, Daniel WG, Feneck RO, Fox KF, Fraser AG, Pasquet A, Pepi M, de Isla P & Zamorano JL 2010 Recommendations for transoesophageal echocardiography: update 2010. *European Journal of Echocardiography* **11** 557–576. (doi:10.1093/ejehocard/jeq057)

3 Sharma V, Alderton S, McNamara H, Steeds R, Bradlow W, Chenzbraun A, Oxborough D, Matthew T, Jones R, Wheeler R *et al* 2015 A safety checklist for transoesophageal echocardiography from the British Society of Echocardiography and the Association of Cardiothoracic Anaesthetists. *Echo Research and Practice* **2** G25–G27. (doi:10.1530/ERP-15-0035)

4 Wharton G, Steeds R, Allen J, Phillips H, Jones R, Kanagala P, Lloyd G, Masani N, Mathew T, Oxborough D *et al.* 2015 A minimum data set for a standard transthoracic echocardiogram: a guideline protocol from the British Society of Echocardiography. *Echo Research and Practice* **2** G9–G24. (doi:10.1530/ERP-14-0079)

5 Foster GP, Dunn AK, Abraham S, Ahmadi N & Sarraf G 2009 Accurate measurement of mitral annular dimensions by echocardiography: importance of correctly aligned imaging planes and anatomic landmarks. *Journal of the American Society of Echocardiography* **22** 458–463. (doi:10.1016/j.echo.2009.02.008)

6 Baumgartner H, Hung J, Bermejo J, Chambers JB, Evangelista A, Griffin BP, Bernard I, Otto CM, Pellikka PA & Quinones M 2009 Echocardiographic assessment of valve stenosis: EAE/ASE recommendations for clinical practice. *European Journal of Echocardiography* **10** 1–25. (doi:10.1093/ejehocard/jen303)

7 Ho SY & Nihoyannopoulos P 2006 Anatomy, echocardiography, and normal right ventricular dimensions. *Heart* **92** (Suppl 1) i2–i13. (doi:10.1136/hrt.2005.077875)

8 Lang RM, Bierig M, Devereux RB, Flachskampf FA, Foster E, Pellikka PA, Picard MH, Roman MJ, Seward J, Shanewise JS *et al.* 2005 Recommendations for chamber quantification: a report from the American Society of Echocardiography's Guidelines and Standards Committee and the Chamber Quantification Writing Group, developed in conjunction with the European Association of Echocardiography, a branch of the European Society of Cardiology, Chamber Quantification Writing Group; American Society of Echocardiography's Guidelines and Standards Committee; European Association of Echocardiography. *Journal of the American Society of Echocardiography* **18** 1440–1463. (doi:10.1016/j.echo.2005.10.005)

9 Masani N, Wharton G, Allen J, Chambers J, Graham J, Jones R, Rana B, Steeds R & The British Society of Echocardiography Education Committee 2011 Echocardiography: guidelines for chamber quantification; http://www.bsecho.org/media/40506/chamber-final-2011_2_.pdf.

10 Wheeler R, Steeds RP, Wharton G, Rana B, Smith N, Oxborough D, Brewerton H, Allen J, Chambers J, Sandoval J, *et al.* 2011 Recommendations for safe practice in sedation during transoesophageal echocardiography: a report from the education committee of the British Society of Echocardiography; http://www.bsecho.org/media/55310/recommendations_for_safe_practice_in_toe.pdf.

11 Kanagala P, Bradley C, Hoffman P, Steeds RP, Rana B, Oxborough D, Wheeler R, Wharton G, Brewerton H, Chambers J, *et al.* 2011 Guidelines for transoesophageal echocardiography probe cleaning and disinfection from the British Society of Echocardiography; http://www.bsecho.org/media/36337/toe_decontamination.pdf.

Received in final form 3 November 2015

Accepted 25 November 2015