

## LUMPS & BUMPS: A PRACTICAL GUIDE TO EVALUATION & TECHNIQUE REMOVAL

Nate Lighthizer, O.D., F.A.A.O.

### Overview

- ☐ Eyelid anatomy review
- ☐ Eyelid lesions
  - Review
  - Benign vs. Precursors vs. Cancer
  - How it relates to the anatomy
- ☐ Eyelid surgery clinical tips
- ☐ Lesion removal techniques/terms
- ☐ Radiofrequency surgery (Ellman Unit)
  - Indications
  - Contraindications
  - Techniques for removal of lesions
  - Videos
- ☐ Chalazion management

### Keep in mind...

- ☐ Most eyelid lesions are benign
- ☐ Benign lesions originate in the skin (epidermis) and grow outward
- ☐ The skin of the eyelid is ideally suited for office surgery

### Unique Features of the Eyelid Skin

- ☐ Very thin (4 - 5 cell layers thick)
- ☐ Uniform depth
- ☐ Fastest turnover (5 - 7 days)
- ☐ *No dermal papilla present (absent rete ridges & rete pegs)*
- ☐ *Potential space between epidermis & dermis accommodates local anesthetic well*

### Eyelid Surgery: Clinical Tips...

- ☐ Lid Margin: Stay 2 mm from margin if possible
- ☐ Eyelid proper: Skin is only 4 - 5 cell layers thick
- ☐ Inner canthus: Beware lacrimal apparatus, angular vein, etc...
- ☐ Outer Canthus: Beware moving outer canthus up or down as this significantly changes individual's appearance
- ☐ Lid Crease: Can be altered
- ☐ Brow: Stay 2 mm below the brow if possible.

### Common eyelid lesions

- ☐ Benign
  - Hyperkeratoses: eg, squamous papilloma
  - Pseudoepitheliomas: eg, seborrheic keratosis
  - Cysts: eg, chalazion
  - Nevi: eg, Clark nevus
- ☐ The Gray Zone (pre-malignant): eg, actinic keratosis
- ☐ Malignant: eg, squamous cell carcinoma

## Lid Lesion Overview

- ☐ Benign Lid Lesions
  - Chalazion
  - Skin tag/papilloma
  - Verrucae
  - Seborrheic Keratosis
  - Cyst of Moll & Zeiss
  - Sebaceous Cyst
  - Freckle/nevus
- ☐ Precursors To Cancer
  - Actinic Keratosis
  - Keratoacanthoma
- ☐ Cancer
  - Basal Cell Carcinoma
  - Squamous Cell Carcinoma
  - Malignant Melanoma
  - Sebaceous Gland Carcinoma

## Ask yourself: Is it Benign???

- ✓ **H:** loss of hair bearing structures?
- ☐ **A:** asymmetrical?
- ☐ **A:** abnormal blood vessels (telangectasia's)?
- ☐ **B:** borders irregular?
- ✓ **B:** bleeding reported?
- ☐ **C:** multicolored?
- ✓ **C:** change in the size or color of the lesion?
- ✓ **D:** overall diameter > 5 mm?

## Lid Lesions

- ☐ Lesion work-up
  - How long has that been there?
  - Is it changing/enlarging?
  - Is it bothersome?
  - Is it bleeding?
  - Personal history of cancer?
- Is it ulcerated?
- Is there hair loss?
- Is there destruction of tissue?

## Benign Lid Lesions – Squamous Cell Papilloma

- ☐ AKA papilloma or Skin Tag
- ☐ Squamous papillomas are the most common benign neoplasms of the eyelid and conj\*\*
- ☐ Usually not bothersome to patient other than cosmetic concerns
- ☐ Often been there for many years
- ☐ More likely seen in overweight people

## Benign Lid Lesions – Squamous Cell Papilloma

- ☐ Signs:
  - Flesh-colored, avascular pedunculated lesion
  - Often seen at areas of skin rubbing
  - May be one or several
- ☐ DDX:
  - Verruca vulgaris
  - Seborrheic keratosis
  - Intradermal nevus
- ☐ Tx:
  - Simple excision at the base of the lesion

## Benign Lid Lesions – Veruca Vulgaris

- ☐ AKA Viral Warts or Common Warts
- ☐ Caused by epidermal infection with the HPV
  - Spread by direct contact and fomites
  - Contagious\*\*\*
- ☐ More common in children and young adults
- ☐ May occur anywhere on the skin
  - Occasionally on the eyelids

### Benign Lid Lesions – Veruca Vulgaris

- ☐ Signs:
  - Single or multiple elevated flesh-colored lesions with an irregular, hyperkeratotic papillomatous surface
  - If on lid margin can shed viral particles into the tear film -> mild viral conjunctivitis
- ☐ DDx:
  - Skin tags
- ☐ Treatment:
  - Observation
  - Simple excision

### Benign Lid Lesions – Seborrheic Keratosis

- ☐ AKA Basal cell papilloma
- ☐ Common, slow growing benign epithelial neoplasm most often found on the face, trunk, and extremities of older individuals
- ☐ Signs:
  - Single or multiple discrete, greasy brown plaque with a “stuck on” appearance

### Benign Lid Lesions – Seborrheic Keratosis

- ☐ DDx:
  - Pigmented basal cell carcinoma
  - Skin nevus
  - Malignant melanoma
  - Verruca vulgaris
  - Skin tag
- ☐ Tx:
  - Shave excision of flat lesions
  - Excision of pedunculated lesions

Elman unit Seborrheic keratosis removal

### Benign Lid Lesions – Cyst of Zeis

- ☐ Small, non-translucent cyst on the anterior lid margin arising from obstructed sebaceous glands associated with the eyelash follicle
- ☐ Only problem may be a cosmetic concern for pt
- ☐ Basically is a type of sebaceous cyst
- ☐ Tx:
  - Surgical excision/drainage
  - Pt ed they may recur
  -

### Benign Lid Lesions – Cyst of Moll

- ☐ Cyst of Moll (AKA apocrine hydrocystoma) = small retention cyst of the lid margin apocrine glands.
- ☐ Appears as a round, non-tender, translucent fluid-filled lesion on the anterior lid margin.
- ☐ Only problem may be a cosmetic concern for pt
- ☐ Tx:
  - Surgical excision/drainage
  - Pt ed they may recur

### Benign Lid Lesions – Sebaceous Cyst

- ☐ Benign cyst filled with cheesy sebum from a sebaceous gland in the skin
- ☐ Caused by a blocked sebaceous gland/follicle
- ☐ May be found on the eyelid or ocular adnexa
- ☐ Only problem may be a cosmetic concern for pt
- ☐ Tx:
  - Surgical excision/drainage
  - Pt ed they can recur

## Epidermal Inclusion Cyst

- 2<sup>nd</sup> most common benign lesion after the epithelial hyperplasias
- develop from epidermal cells trapped within the hair follicle, allowing keratin to accumulate beneath the cutaneous surface

## Benign Lid Lesions - Freckle & Nevus

- ▣ Freckle = brown macule due to increased melanin in the epidermal basal layer, usually in sunlight exposed areas
- ▣ Nevus = sharply demarcated lesion of the skin
  - AKA birthmarks or moles
  - Benign by definition
  - Correct term is melanocytic nevus for most lesions
  - 4 main types:
    - Junctional nevus
    - Compound nevus
    - Intradermal nevus
    - Dysplastic nevus

## Benign Lid Lesions - Freckle & Nevus

- ▣ Junctional nevus - occurs more often in young individuals. Usually brown macule. Nevus cells are located at the junction of the epidermis and dermis and have low potential for malignant transformation (although higher than the next 2).
- ▣ Compound nevus - occurs more often in middle aged individuals. Usually light tan-dark brown slightly raised papular lesion. Nevus cells extend from the epidermis into the dermis. It has low malignant potential.
- ▣ Intradermal nevus - most common nevus. Typically occurs in old age. Usually papillomatous lesion and flesh-colored (not pigmented). Nevus cells are confined to the dermis. No malignancy potential.
- ▣ Dysplastic nevus - usually a compound nevus with cellular and architectural dysplasia. Can be flat or raised. Typically larger than normal nevi and tend to have irregular borders and coloration. More likely to transform into melanoma.

## Benign Lid Lesions - Freckle & Nevus

- ▣ Signs:
  - Usually pigmented, flat or slightly elevated skin lesion
  - Located anywhere on the body
    - Frequently at the lid margin
- ▣ DDX:
  - Melanoma
- ▣ Diagnosis:
  - A
  - B
  - C
  - D
  - E

## Benign Lid Lesions - Nevus

- ▣ Tx:
  - Photodocument q3-6 months for any changes
  - Biopsy if suspicious\*\*\*
  - If you cut on a melanoma in OK = malpractice\*\*\*
  - Be darn sure that is not a melanoma\*\*\*

## Benign Lid Lesions - Capillary Hemangioma

- ▣ AKA strawberry hemangioma or nevus
- ▣ One of the most common tumors of infancy
  - Usually present shortly after birth
- ▣ Female: male ratio is 3:1
- ▣ May present as a small isolated lesion of minimal clinical significance or as a large disfiguring mass that can cause visual impairment and systemic complications

### Benign Lid Lesions – Capillary Hemangioma

- ▣ Signs:
  - Unilateral, raised bright red lesion which blanches with pressure
    - May appear dark blue or purple if below the skin
  - Large lesion may cause a mechanical ptosis
  - Large orbital tumors may give rise to proptosis
  - Biggest ocular concern????

### Benign Lid Lesions – Capillary Hemangioma

- ▣ Tx:
  - Usually just leave it alone and it will go away
    - 30% of lesions resolve by 3 years of age
    - 70% of lesions resolve by 7 years of age
  - Steroid injections – primary treatment
  - Surgical excision/resection
  - Refer to a PCP for any treatment

### Benign Lid Lesions – Pyogenic Granuloma

- ▣ Most common acquired vascular lesion to involve the eyelids/conj
- ▣ Usually occurs after surgery or trauma to area
- ▣ Symptoms:
  - Asymptomatic
  - Cosmetic concerns
- ▣ Signs:
  - Fast growing, fleshy, pinkish red mass
- ▣ Treatment:
  - Steroid QID X 1-2 weeks
  - Surgical excision

### Precursors to Cancer – Actinic Keratosis

- ▣ AKA Solar Keratosis
- ▣ Most common pre-cancerous lesion\*\*
  - 60% of predisposed people over the age of 40 will have one of these in their lifetime
- ▣ Elderly, fair-skinned individuals with excessive sunlight exposure
- ▣ Most often seen on the forehead, face, and backs of the hands
- ▣ Low potential for conversion to SCC\*\*\*
  - 1 in 1000

### Precursors to Cancer – Actinic Keratosis

- ▣ Signs:
  - Hyperkeratotic plaque with distinct borders and a scaly surface
  - Dry, rough area when running your fingers over it
  - Usually minimally elevated
- ▣ DDx:
  - SCC
  - Seborrheic keratosis

### Precursors to Cancer – Actinic Keratosis

- ▣ Tx:
  - Precancerous so referral to dermatologist
  - Biopsy & excision
  - Cryotherapy – liquid N2 to freeze of the AK
  - 5-FU – chemotherapy agent which causes the area to become red and inflamed and the lesion will then fall off
  - PDT – injecting dye into the bloodstream which makes AK more sensitive to light therapy

### Precursors to Cancer - Keratoacanthoma

- ☐ Rare tumor usually occurring in fair skinned individuals
- ☐ Often a history of chronic sun exposure
- ☐ More likely seen on the face, neck, hands/forearms
- ☐ Histopathologically, it is regarded as part of the spectrum of SCC
- ☐ Symptoms:
  - Lesion that comes about fairly rapidly (within weeks to months)

### Precursors to Cancer - Keratoacanthoma

- ☐ Signs: (in order)
  - Pink, rapidly growing hyperkeratotic lesion, often on the lower lid
  - May double or triple in size in weeks
  - Growth ceases for 2-3 months, after which spontaneous involution occurs
  - During the period of regression, a keratin-filled crater may develop
  - Resolution may take up to a year and often leaves a nasty scar

### Precursors to Cancer - Keratoacanthoma

- ☐ DDX:
  - SCC\*\*
- ☐ Tx:
  - Derm consult
  - Complete surgical excision/biopsy
    - Removal with RFP
    - Cryotherapy
  - Topical or intralesional 5-FU

### Lid Lesion Overview

- |  |  |
|--|--|
| <ul style="list-style-type: none"> <li>☐ Benign Lid Lesions               <ul style="list-style-type: none"> <li>▪ Chalazion</li> <li>▪ Skin tag/papilloma</li> <li>▪ Verrucae</li> <li>▪ Seborrheic Keratosis</li> <li>▪ Cyst of Moll &amp; Zeiss</li> <li>▪ Sebaceous Cyst</li> <li>▪ Freckle/nevus</li> </ul> </li> </ul> | <ul style="list-style-type: none"> <li>☐ Precursors To Cancer               <ul style="list-style-type: none"> <li>▪ Actinic Keratosis</li> <li>▪ Keratoacanthoma</li> </ul> </li> <li>☐ Cancer               <ul style="list-style-type: none"> <li>▪ Basal Cell Carcinoma</li> <li>▪ Squamous Cell Carcinoma</li> <li>▪ Malignant Melanoma</li> <li>▪ Sebaceous Gland Carcinoma</li> </ul> </li> </ul> |
|--|--|

### Lesion Work-up

- ☐ Lesion work-up
  - How long has that been there?
  - Is it changing/enlarging?
  - Is it bothersome?
  - Is it bleeding?
  - Personal history of cancer?
  
  - Is it ulcerated?
  - Is there hair loss?
  - Is there destruction of tissue?

### Cancer - Basal Cell Carcinoma

- ☐ Slow-growing, locally invasive, non-metastatic tumor
- ☐ Most common malignant lid tumor\*\*\*
  - 90% of cases
- ☐ 90% of cases occur on the head and neck
  - 10% of these are on the eyelid
- ☐ Risk factors:
  - Fair skin
  - Chronic exposure to UV sunlight
  - Age

## Cancer – Basal Cell Carcinoma

- ▣ Signs:
  - Most common location is the lower eyelid
    - Medial canthus > upper eyelid > lateral canthus
  - Pearly, raised, rolled edges of a raised or ulcerated firm lesion
  - Rolled, raised, pearly border/margins\*\*\*
  - Usually not pigmented
  - Often small dilated feeder bv's on its surface

## Cancer – Basal Cell Carcinoma

- ▣ Signs:
  - Nodular BCC – most common – grows slowly and it may take 1-2 years to reach 0.5 cm in size
  - Noduloulcerative BCC (rodent ulcer) – central ulceration, pearly raised rolled edges and dilated irregular bv's over its lateral margins
  - Sclerosing BCC – less common and harder to diagnose since it infiltrates laterally beneath the epidermis as an indurated plaque

## Cancer – Basal Cell Carcinoma

- ▣ DDx:
  - SCC
  - Melanoma
- ▣ Tx:
  - Derm/oculoplastics consult
  - Biopsy/excision
  - Chemotherapy cream (5-FU)
  - PDT

## Cancer – Squamous Cell Carcinoma

- ▣ Much less common, but more aggressive tumor than BCC
  - Metastasis to regional lymph nodes in ≈ 20% of cases
- ▣ 5-10% of eyelid malignancies
- ▣ May arise de novo or from pre-existing actinic keratosis, keratoacanthoma, or carcinoma in situ
- ▣ Risk factors:
  - Fair skin
  - Chronic sun exposure
  - Age

## Cancer – Squamous Cell Carcinoma

- ▣ Signs:
  - No pathognomonic characteristics
  - Has a predilection for the lower lid, lid margin, and medial canthus
  - May be indistinguishable from BCC
    - Surface vascularization is usually absent
    - Growth tends to be more rapid
    - Hyperkeratosis is more often present

## Cancer – Squamous Cell Carcinoma

- ▣ Signs:
  - Nodular SCC – hyperkeratotic nodule which may develop crusting erosions
  - Ulcerating SCC – reddish, sharply defined raised or ulcerated scaly plaque
    - Scaler, reddish, dryer look to it\*\*\*
  - Cutaneous horn – rarest form and has underlying SCC beneath it

## Cancer – Squamous Cell Carcinoma

- ▣ DDx:
  - BCC
  - Actinic keratosis
  - Keratoacanthoma
- ▣ Tx:
  - Derm/oculoplastics consult
  - Biopsy/excision
  - Chemotherapy cream (5-FU)
  - PDT
  - Much more rare than BCC.... but neglected cases are more likely to metastasize

## Cancer – Malignant Melanoma

- ▣ Malignant tumor of melanocytes
- ▣ Much less common than other skin cancers
  - But causes 75% of deaths related to skin cancer
- ▣ More often develops in sun-damaged skin
  - Face, head, neck, hands/forearms in older pts
  - But can develop anywhere
    - Iris, choroid, retina, inside of mouth
    - Rarely on the eyelids, but is potentially lethal
- ▣ Pigmentation is a hallmark of malignant melanomas...but
  - ½ of lid melanomas are non-pigmented

## Cancer – Malignant Melanoma

- ▣ Features suggestive of melanoma:
  - Recent onset of pigmented lesion
  - Change in an existing pigmented lesion
  - Irregular margins
  - Asymmetric shape
  - Color change or presence of multiple colors
  - Diameter greater than 6 mm

## Cancer – Malignant Melanoma

- ▣ DDx:
  - Nevus
  - Lentigo maligna
  - Seborrhic keratosis
- ▣ Tx:
  - Refer for biopsy/wide excision\*\*\*
    - May include local lymph node removal
  - If you cut on a melanoma that is malpractice\*\*\*

## Lid Lesion Overview

- |   |  |
|---|--|
| <ul style="list-style-type: none"> <li>▣ Benign Lid Lesions               <ul style="list-style-type: none"> <li>▪ Chalazion</li> <li>▪ Skin tag/papilloma</li> <li>▪ Verrucae</li> <li>▪ Seborrhic Keratosis</li> <li>▪ Cyst of Moll &amp; Zeiss</li> <li>▪ Sebaceous Cyst</li> <li>▪ Freckle/nevus</li> </ul> </li> </ul> | <ul style="list-style-type: none"> <li>▣ Precursors To Cancer               <ul style="list-style-type: none"> <li>▪ Actinic Keratosis</li> <li>▪ Keratoacanthoma</li> </ul> </li> <li>▣ Cancer               <ul style="list-style-type: none"> <li>▪ Basal Cell Carcinoma</li> <li>▪ Squamous Cell Carcinoma</li> <li>▪ Malignant Melanoma</li> <li>▪ Sebaceous Gland Carcinoma</li> </ul> </li> </ul> |
|---|--|

## #1 Recommendation

- ▣ A Radiofrequency Surgical Device
  - RF surface ablation
  - Incisions
  - Excisions
  - Hemostasis/cautery
  - RF Epilation
  - RF punctal occlusion
  - Telangiectasias



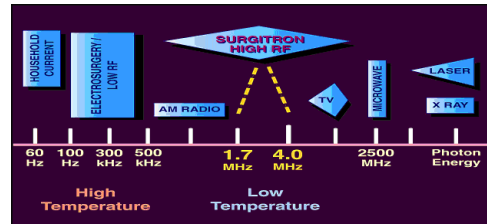


## Radiofrequency Surgery - Overview

- ❑ History of Electrosurgery
- ❑ What is Radiofrequency (RF) Surgery
- ❑ Advantages of RF surgery
- ❑ Indications
- ❑ Contraindications
- ❑ Equipment
- ❑ Surgical Technique
  - Specific approaches for various lesions
- ❑ Risks/Complications
- ❑ Post-procedure patient care
- ❑ CPT/Billing Codes

## What is Radio Surgery?

- ❑ Electro surgery at radiofrequency
- ❑ Why radio surgery?



- ❑ Radio Surgery vs. Electrocautery vs. Hyfrecaction

## HISTORY OF ELECTROSURGERY

- ❑ Origins in electrocautery
- ❑ Albucasis (980BC) used hot iron to stop bleeding
- ❑ Of course, this also caused third degree burns and poor cosmesis
- ❑ In 1893, Arsenne d' Arsonval was experimenting with passing high frequency electrical current through tissues and discovered that electric currents >100KHz do not cause muscle spasm.....this is known as the FARADIC EFFECT


## HISTORY OF ELECTROSURGERY


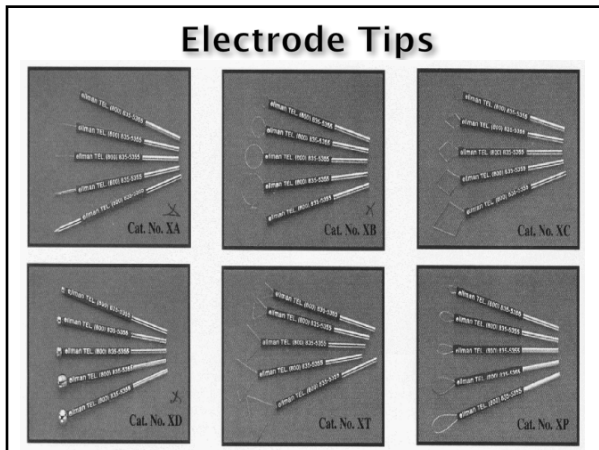
- ❑ In 1975, Dr Irving Ellman designed, patented, and produced a relatively small, lightweight, solid state radiosurgery instrument which produced a 3.9 MHz frequency signal
- ❑ In 1978, Manness published a study showing that fully filtered 3.8 MHz waves were optimal for cutting soft tissue

## What is Radiofrequency (RF) Surgery?

- ❑ Radiosurgery is the passage of high frequency radiowaves through soft tissue to cut, coagulate, and/or remove the target tissue
- ❑ Resistance of the tissue to the radiowaves causes water in the cells to heat and the cell vaporizes
- ❑ Radio-surgical unit consists of
  - Active electrode
  - Antennae (passive electrode)
  - Transformer
- ❑ Ideal frequency = 3.8 - 4.0 MHz

## Electrode Tips





## What is Radiofrequency (RF) Surgery?

- ❑ Radiosurgery is the passage of high frequency radiowaves through soft tissue to cut, coagulate, and/or remove the target tissue
- ❑ Resistance of the tissue to the radiowaves causes water in the cells to heat and the cell vaporizes
- ❑ Radio-surgical unit consists of
  - Active electrode
  - Antennae (passive electrode)
  - Transformer
- ❑ Ideal frequency = 3.8 - 4.0 MHz

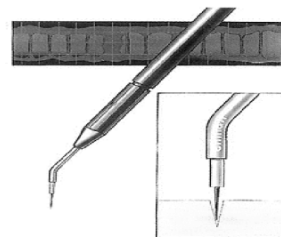


## Advantages of Radiosurgery

- ❑ Cuts and coagulates at the same time
- ❑ Nearly bloodless field
- ❑ Minimal biopsy artifact damage\*
- ❑ Quick and easy (to do and to learn)
  - Pressureless & bacteria-free incisions
- ❑ Minimal lateral heat
- ❑ Minimal Post-op pain
- ❑ Rapid healing
- ❑ Fine control with variety of tips
- ❑ No muscle contractions or nerve stimulation from radiowaves (Faradic effects)

### Setting 1 Filtered Fully Rectified Wave Form - Pure Cutting Action

Power  $\approx$  3.0 (old unit) or 20 (newer unit)



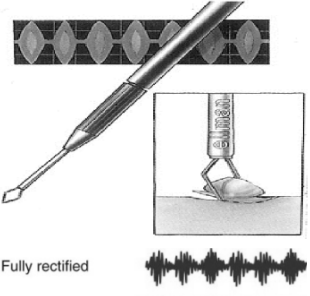
Fully filtered and fully rectified



- ❑ 90% Cutting
- ❑ 10% Coagulation
- ❑ Cutting current: high frequency sine wave that is not dampened.
- ❑ Produces very focused heat buildup that ruptures tissue through either molecular activity or through production of steam microbubbles
- ❑ Minimal lateral heat
- ❑ Use for biopsy, incisions, chalazion

**Setting 2**  
**Rectified Waveform (blended)**  
**Cut and Coag**

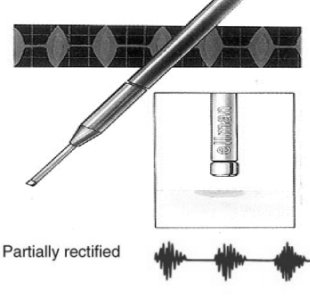
Power  $\approx$  3.0 (old unit) or 20 (newer unit)



- ☐ 50% Cutting
- ☐ 50% Coagulation
- ☐ When don't need biopsy
- ☐ Helps greatly with bleeding during procedure
- ☐ Very useful in vascular regions
- ☐ Great for excising
  - Skin tags, verruca
- ☐ Waveform we use the most

**Setting 3**  
**Partially Rectified Waveform**  
**Coagulation/Hemostasis**

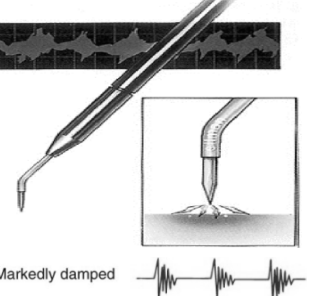
Power  $\approx$  2.5 (old unit) or 20 (newer unit)



- ☐ 90% Coagulation
- ☐ 10% Cutting
- ☐ Coagulating current: high frequency but dampened (rectified) sine wave.
- ☐ Produces oscillation of molecules leading to generation of intracellular heat that ultimately causes tissue dehydration/coagulation (hemostasis)
- ☐ Epilation, punctal occlusion

**Setting 4**  
**Fulguration - Coagulation and Destruction**

Power  $\approx$  8 (old unit) or 80 (newer unit)



- ☐ Spark gap fulgurating current (hyfrecation) for superficial cautery
- ☐ Doesn't penetrate deeply - superficial treatment
- ☐ Electrodesiccation (papilloma bed)
- ☐ Destruction of cyst remnants
- ☐ Intentional destruction of diseased tissue
  - BCC
  - SCC

**Advantages of Radiosurgery**

- ☐ Cuts and coagulates at the same time
- ☐ Nearly bloodless field
- ☐ Minimal biopsy artifact damage\*
- ☐ Quick and easy (to do and to learn)
  - Pressureless & bacteria-free incisions
- ☐ Minimal lateral heat
- ☐ Minimal Post-op pain
- ☐ Rapid healing
- ☐ Fine control with variety of tips
- ☐ No muscle contractions or nerve stimulation from radiowaves (Faradic effects)

**Lateral Heat**

**Lateral heat =  $\frac{\text{time} \times \text{waveform} \times \text{power} \times \text{electrode size}}{\text{frequency}}$**

**Factors Affecting Lateral Heat**

- ☐ Electrode contact time: slow passage = increased heat
- ☐ Excessive power can lead to sparking (too little power leads to tissue drag)
- ☐ Larger electrode head sizes lead to greater power/heat generation
- ☐ Different waveforms are associated with different levels of heat:
  - Fulguration > COAG > CUT/COAG > CUT
- ☐ Higher frequency associated with less lateral heat

**Advantages of Radiosurgery**

- ☐ Cuts and coagulates at the same time
- ☐ Nearly bloodless field
- ☐ Minimal biopsy artifact damage\*
- ☐ Quick and easy (to do and to learn)
  - Pressureless & bacteria-free incisions
- ☐ Minimal lateral heat
- ☐ Minimal Post-op pain
- ☐ Rapid healing
- ☐ Fine control with variety of tips
- ☐ No muscle contractions or nerve stimulation from radiowaves (Faradic effects)

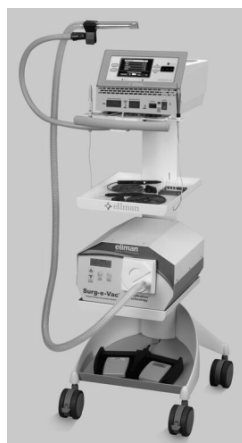
## Hazards/Contraindications

- ❑ Excess lateral tissue damage
- ❑ Smoke hazard/unpleasant smells in office
- ❑ Don't use in presence of flammable fumes/liquids
- ❑ Pacemaker
  - "Do not work near the heart and place the antenna (or grounding) plate well away from the heart. Use the least power possible. Activate the handpiece intermittently rather than continuously. The cutting mode is the most risky, so avoid it if possible. Use another form of treatment if it is an option. The pacers are purportedly "shielded" and the current in the ESUs should not affect them, but all things are not perfect! Therefore caution is needed. Asystole and tachycardia are potential adverse outcomes."
- Pfenninger and Fowler's Procedures for Primary Care, 3rd Edition. John L. Pfenninger, MD, FAAFP and Grant C. Fowler, MD

## Radiofrequency Units

- ❑ ELLMAN
  - <http://www.ellman.com/radiosurgery/medical>
- ❑ COOPER SURGICAL LEEP
  - <http://www.coopersurgical.com>
- ❑ Valley Lab Force II
  - <http://www.valleylab.com/main.html>
- ❑ Wallach Surgical Devices
  - <http://www.wallachsurgical.com>
- ❑ Circon (Cryomedics)
  - <http://www.circoncorp.com>

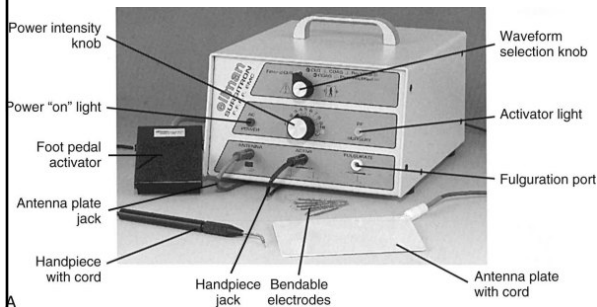
Pelleve S5



Dual 120




Ellman Unit



Elmann Unit - older model



## Ellman Unit Vacuum



## Radiofrequency (RF) Surgery Indications

- ▣ Skin papillomas/skin tags
- ▣ Seborrheic keratoses
- ▣ Verruca
- ▣ Sebaceous cysts
- ▣ Benign Nevi
- ▣ Pyogenic Granulomas
- ▣ Incision into chalazion
- ▣ Trichiasis
  
- ▣ Xanthelasma
- ▣ Blepharoplasty incisions
- ▣ Biopsies of suspicious lesions (BCC, SCC, melanoma)

## Hazards/Contraindications

- ▣ Do NOT perform shave excision on pigmented lesion unless certain is not melanoma!!!
- ▣ Don't use in presence of flammable fumes/liquids
- ▣ Pacemaker
  - "Do not work near the heart and place the antenna (or grounding) plate well away from the heart. Use the least power possible. Activate the handpiece intermittently rather than continuously. The cutting mode is the most risky, so avoid it if possible. Use another form of treatment if it is an option. The pacers are purportedly "shielded" and the current in the ESUs should not affect them, but all things are not perfect! Therefore caution is needed. Asystole and tachycardia are potential adverse outcomes."
  - Pfenninger and Fowler's Procedures for Primary Care, 3rd Edition. John L. Pfenninger, MD, FAAFP and Grant C. Fowler, MD

## Procedure Technique

- ▣ Pre-op (photos, consent, BP and Pulse, VA)
- ▣ Pacemaker? Allergies?
- ▣ Clean area, drape if needed
  - Betadine needs 3 mins on skin!
- ▣ Anesthetize (infiltrative usually)
- ▣ Turn on Ellman unit: warm up for at least 30 seconds
- ▣ Choose appropriate waveform
- ▣ Choose initial power setting (will often need to adjust depending on tissue response to energy level chosen)

## Procedure Technique

- ▣ Have assistant turn on/position vacuum unit - USE vacuum and masks!
  - Have isolated HPV and HIV in smoke
- ▣ Place yourself in comfortable/stable position to do procedure
- ▣ Brace your handpiece wrist on patient for stability

## Procedure Technique

- ☐ Electrode tip should be applied perpendicularly to allow even distribution of energy
- ☐ Press footplate activator when ready to begin procedure
- ☐ Move in expeditious but controlled fashion: always keep electrode moving when contacting tissue

## Procedure Technique

- ☐ Keep the tissue around the lesion taut
- ☐ Keep surgical site moist (saline gauze) to avoid tissue drag
  - Removes debris on surgical field
- ☐ Also wipe energized tip to remove tissue stuck to it
- ☐ When feathering down a lesion with a loop, keep perpendicular---remove until healthy tissue seen
- ☐ Can use forceps closed tips to touch end of area of bleeding, touch electrode to forceps to transfer energy to area to stop bleeding

## Post-procedure Technique

- ☐ Clean area of betadine
- ☐ Apply antibiotic ung
  - Pt ed about moist healing
- ☐ Don't let patient jump and run as you sit them up!
- ☐ Blood pressure and pulse post-op
- ☐ Write op report in chart along with patient instructions on wound care and follow-up schedule

## Radiofrequency (RF) Surgery Indications

- ☐ Skin papillomas/skin tags
- ☐ Seborrheic keratoses
- ☐ Verruca
- ☐ Sebaceous cysts
- ☐ Benign Nevi
- ☐ Pyogenic Granulomas
- ☐ Incision into chalazion
- ☐ Trichiasis
  
- ☐ Xanthelasma
- ☐ Blepharoplasty incisions

## Trichiasis Procedure Technique

- ☐ Cut offending lashes
  - ☐ Anesthetize???
  - ☐ Grab lash with forcep
  - ☐ Use microinsulated needle
  - ☐ Put needle beside lash shaft into follicle until cannot go further
  - ☐ Lowest power setting, Coag
  - ☐ Touch and let off immediately of footplate
  - ☐ Gently tug lash - if comes out smooth are done
  - ☐ If not treat quickly again
- Power  $\approx$  0.1-0.2 (old unit) or 1-2 (newer unit)