







# Comprehensive comparison of upper and lower endoscopic small intestinal biopsy in cats with chronic enteropathy

Betty Chow<sup>1,2</sup>  | Steve L. Hill<sup>1,3</sup> | Keith P. Richter<sup>1</sup> | Sina Marsilio<sup>4,5</sup>  |  
 Mark R. Ackermann<sup>6</sup> | Jonathan A. Lidbury<sup>5</sup>  | Jan S. Suchodolski<sup>5</sup>  |  
 Sarah Cocker<sup>1</sup>  | Jörg M. Steiner<sup>5</sup> 

<sup>1</sup>Veterinary Specialty Hospital by Ethos Veterinary Health, San Diego, California

<sup>2</sup>VCA Animal Specialty & Emergency Center, Los Angeles, California

<sup>3</sup>Flagstaff Veterinary Internal Medicine Consulting, Flagstaff, Arizona

<sup>4</sup>Department of Medicine and Epidemiology, University of California, School of Veterinary Medicine, Davis, California

<sup>5</sup>Gastrointestinal Laboratory, Texas A&M University, College Station, Texas

<sup>6</sup>Department of Biomedical Sciences and Oregon Veterinary Diagnostic Laboratory, Carlson College of Veterinary Medicine, Oregon State University, Corvallis, Oregon

## Correspondence

Betty Chow, VCA Animal Specialty & Emergency Center, 1535 S Sepulveda Boulevard, Los Angeles, CA 90025.  
 Email: betty.chow@vca.com

## Abstract

**Background:** Integrating immunohistochemistry (IHC) and clonality testing with histopathology may improve the ability to differentiate inflammatory bowel disease (IBD) and alimentary small cell lymphoma (LSA) in cats.

**Hypothesis/Objectives:** To evaluate the utility of histopathology, IHC, and clonality testing to differentiate between IBD and LSA and agreement of diagnostic results for endoscopic biopsy (EB) samples from the upper (USI) and lower small intestine (LSI).

**Animals:** Fifty-seven cats with IBD or LSA.

**Methods:** All cases were categorized as definitive IBD (DefIBD), possible LSA (PossLSA), probable LSA (ProbLSA), or definitive LSA (DefLSA) based on histopathology alone. Results from IHC and clonality testing were integrated.

**Results:** Based on histopathology alone, 24/57 (42.1%), 15/57 (26.3%), and 18/57 (31.6%) cats were diagnosed with DefIBD, PossLSA or ProbLSA, and DefLSA, respectively. After integrating IHC and clonality testing, 11/24 cases (45.8%) and 15/15 cases (100%) previously categorized as DefIBD and PossLSA or ProbLSA, respectively, were reclassified as LSA. A final diagnosis of IBD and LSA was reported in 13/57 (22.8%) and 44/57 (77.2%) cats, respectively. Agreement between USI and LSI samples was moderate based on histopathology alone ( $\kappa = 0.66$ ) and after integrating

**Abbreviations:** CE, chronic enteropathy; DefIBD, "definitive IBD"; DefLSA, "definitive LSA" (DefLSA); EB, endoscopic biopsy; FFPE, formalin-fixed and paraffin-embedded; GI, gastrointestinal; GrB, granzyme B; H&E, hematoxylin and eosin; IBD, inflammatory bowel disease; IEL, intraepithelial lymphocytes; IHC, immunohistochemistry; LGE, lower gastrointestinal endoscopy; LGL, large granular lymphocytic; LSA, lymphoma; LSI, lower small intestine; PARR, polymerase chain reaction for antigen receptor rearrangements; PossLSA, "possible lymphoma"; ProbLSA, "probable lymphoma"; UGE, upper gastrointestinal endoscopy; USI, upper small intestine; VSH, Veterinary Specialty Hospital; WSAVA, World Small Animal Veterinary Association;  $\kappa$ , Cohen's kappa coefficient.

This is an open access article under the terms of the Creative Commons Attribution-NonCommercial License, which permits use, distribution and reproduction in any medium, provided the original work is properly cited and is not used for commercial purposes.

© 2020 The Authors. *Journal of Veterinary Internal Medicine* published by Wiley Periodicals LLC, on behalf of the American College of Veterinary Internal Medicine.

IHC and clonality testing ( $\kappa = 0.70$ ). However, only 1/44 (2.3%) of the LSA cases was diagnosed based on LSI biopsy alone.

**Conclusions and Clinical Importance:** Integrating IHC and clonality testing increased the number of cases diagnosed with LSA, but the consequence for patient outcome is unclear. There was moderate agreement between USI and LSI samples. Samples from the LSI rarely changed the diagnosis.

#### KEYWORDS

clonality, feline chronic enteropathy, immunohistochemistry, inflammatory bowel disease, PARR, small cell lymphoma

## 1 | INTRODUCTION

I idiopathic inflammatory bowel disease (IBD) and alimentary small cell, low-grade lymphoma (LSA) are common gastrointestinal (GI) diseases of cats. Both diseases result in similar clinical signs, including weight loss, decreased appetite, vomiting, diarrhea, or some combination of these.<sup>1</sup> Differentiating IBD and LSA can be challenging. Immunohistochemistry (IHC) and clonality testing by polymerase chain reaction for antigen receptor rearrangements (PARR) in conjunction with histopathological assessment may improve the diagnostic accuracy of endoscopic biopsy (EB) samples when differentiating IBD from LSA.<sup>2-7</sup> Based on several studies, 15.6% to 26% of cases initially diagnosed as IBD based on histopathology subsequently were reclassified as LSA, or vice versa, after considering IHC.<sup>3,4,8,9</sup> In addition, 4% to 53% cases initially diagnosed as IBD based on histopathology subsequently were reclassified as LSA, or vice versa, after considering clonality testing with or without IHC.<sup>4,9</sup> However, a recent study in clinically healthy cats suggested that, similar to results in humans, PARR may lack specificity. Thus, reclassification of cases based on PARR may not be appropriate.<sup>10</sup>

A previous study found poor agreement between duodenal and ileal EBs based largely on histopathology, with 44% of LSA cases being diagnosed only by evaluation of ileal but not duodenal biopsies. Results suggested that for accurate diagnosis, duodenal and ileal biopsy samples should be collected from cats with clinical signs of chronic GI disease. However, IHC and clonality testing were not performed in all cases.<sup>11</sup> Performing both lower (LGE) and upper gastrointestinal endoscopy (UGE) increases anesthesia time, patient risk, and procedure costs.

Our aim was to reevaluate the diagnostic utility of procuring both upper small intestine (USI) and lower small intestine (LSI) biopsy samples when results of histopathology are integrated with IHC and clonality testing for the diagnosis of IBD and LSA in cats.

## 2 | METHODS

### 2.1 | Cases

Our study consisted of prospective and retrospective arms and was conducted at the Veterinary Specialty Hospital (VSH) in San Diego,

California. The study protocol was approved by the VSH Research Advisory Committee, and written owner informed consent was obtained for each cat before enrollment into the prospective arm.

For the prospective arm of the study, cats presented to the VSH between September 2015 and August 2017 for UGE and LGE and biopsy collection as part of their diagnostic evaluation for clinical signs of chronic enteropathy (CE) were eligible for enrollment. Chronic enteropathy was defined as the presence of clinical signs of GI disease (ie, hyporexia, polyphagia, weight loss, vomiting, and diarrhea) for at least 3 weeks. All cats underwent routine diagnostic evaluation for CE including CBC, serum biochemistry profile, serum total T4 concentration, and urinalysis. All cats with diarrhea were tested for endoparasites by fecal flotation, antigen immunoassays, PCR testing, or some combination of these at the clinician's discretion. Polymerase chain reaction testing included testing for *Campylobacter* species, *Salmonella* species, *Tritrichomonas foetus*, feline coronavirus, panleukopenia virus, or some combination of these. Serum feline trypsin-like immunoreactivity concentration was normal in all 35 cats in which it was measured. Serum cobalamin, folate, and pancreatic lipase immunoreactivity concentrations were measured in 60, 59, and 61 cases, respectively. Cases with intestinal parasites or extra-GI disease (eg, advanced chronic kidney disease, uncontrolled hyperthyroidism) were excluded. For the retrospective analysis, medical records of cats that had undergone UGE and LGE at the VSH between April 2012 and August 2015 were reviewed. Cases matching the abovementioned criteria were eligible for enrollment. For both study arms, cats treated with corticosteroids within 2 weeks before endoscopy were excluded. In addition, cases were excluded if abdominal ultrasound examination was not performed, histopathologic changes were not consistent with either IBD or LSA, or EB specimens were inadequate in quantity or quality.

### 2.2 | Sample collection and processing

Endoscopy was performed using a 103 cm endoscope with a 5.9 mm outside diameter and a 2.0 mm instrument channel (GIF-XP160, Olympus, Center Valley, Pennsylvania). Biopsy samples from the LSI were obtained either by cannulation of the ileocolic valve (direct visualization), or by passing a reusable or disposable 1.8 mm ellipsoid cup

biopsy forceps, with or without spike, blindly through the ileocolic valve into the LSI for sample collection (blind technique). Histopathologic examinations of hematoxylin and eosin (H&E)-stained formalin-fixed and paraffin-embedded (FFPE) tissue sections were reviewed by a single board-certified pathologist with a special interest in GI pathology (M.R. Ackermann) in all cases. The pathologist had access to information regarding history, clinical signs, and endoscopic findings. Biopsy samples were evaluated for quantity and quality. The findings were reported descriptively and numerically scored according to the World Small Animal Veterinary Association (WSAVA) histopathologic scoring system.<sup>5,12</sup> Briefly, morphological features (eg, surface epithelial injury, crypt hyperplasia, crypt dilatation or distortion, and fibrosis or atrophy) and inflammatory changes (eg, lamina propria lymphocytes, plasma cells, eosinophils, neutrophils, and macrophages) were assessed histologically and assigned a score (normal = 0, mild = 1, moderate = 2, or marked = 3).

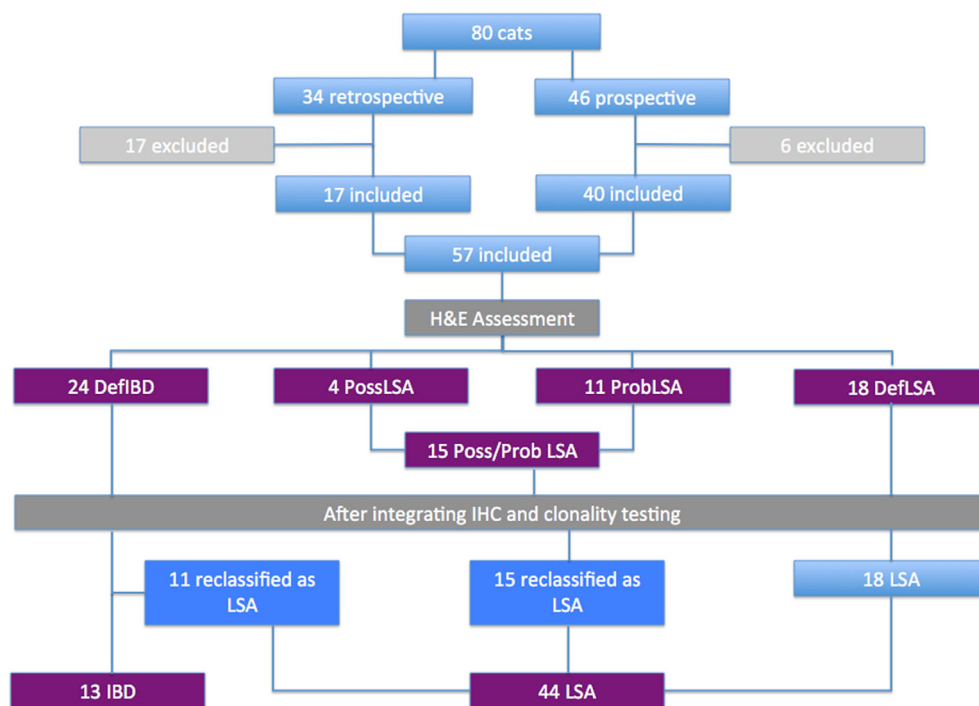
Cases were categorized based on the histopathologic diagnosis as “definitive IBD” (DefIBD, the pathologist made a definitive diagnosis of IBD); “possible lymphoma” (PossLSA, the pathologist reported findings where LSA could not be ruled out but was deemed unlikely); “probable lymphoma” (ProbLSA, the pathologist was concerned about the presence of LSA and recommended IHC, clonality testing, or both for further evaluation); or “definitive LSA” (DefLSA, the pathologist made a definitive diagnosis of LSA). In cats with discordant results between USI and LSI, the diagnosis of LSA was determined when LSA was reported in either site. Association between morphological features and clinical features and diagnosis were evaluated.

Sections of FFPE tissue were sent to a single external laboratory for IHC and clonality testing (Leukocyte Antigen Biology Laboratory, University of California Davis, on a fee-for-service basis). The

pathologist at the external laboratory was blinded to the H&E diagnosis. Sections were assessed by H&E staining, IHC, and clonality testing using a stepwise approach. Staining for T-, B-, and natural killer cell markers (ie, CD3, CD79a, granzyme B [GrB], respectively) were performed at the pathologist's discretion and based on histopathology results (ie, size and distribution of mucosal lymphocytes). Clonality testing was conducted on at least 2 FFPE tissue sections (each 25  $\mu$ m in thickness) using PARR analysis. Total DNA content was measured before the procedure to ensure that sufficient tissue was present for accurate PARR testing. Results from the H&E-based histopathology, IHC, and clonality analysis were integrated and reported by the external pathologist.

## 2.3 | Statistical analysis

All datasets were tested for normality using the Anderson-Darling test. Normally distributed numerical data were analyzed using the Student's *t* test and presented as means and standard deviations. Non-normally distributed continuous data were analyzed using the Wilcoxon signed rank test and presented as medians and range. Categorical data were analyzed using the Fisher's exact test or Wilcoxon rank-sum test. If a discrepancy was found between the USI and LSI diagnosis in a cat, the more malignant diagnosis category was used for statistical analysis. Agreement between diagnoses by intestinal location and by type of diagnostic testing (H&E staining alone, H&E with IHC and clonality testing) was assessed by calculating Cohen's kappa coefficient ( $\kappa$ ). Kappa values 0-0.40 were characterized as poor, 0.41-0.75 as fair to good, and >0.75 as excellent agreement.<sup>13</sup>



**FIGURE 1** Summary of case numbers and diagnoses. DefIBD, “definitive IBD”; DefLSA, “definitive LSA”; H&E, hematoxylin and eosin; IBD, inflammatory bowel disease; IHC, immunohistochemistry; LSA, lymphoma; PossLSA, “possible LSA”; ProbLSA, “probable LSA”

Commercial software (Stata version 14.2) was used for statistical analysis. Statistical significance was set at  $P < .05$ .

### 3 | RESULTS

#### 3.1 | Patient population

Eighty cats that had undergone both UGE and LGE, with EBs obtained from the USI and LSI, between 2012 and 2017 were reviewed. Seventeen retrospective cases were excluded because of inadequate sample for IHC and clonality analysis ( $n = 4$ ), poor sample quality ( $n = 6$ ), insufficient DNA amplification from samples ( $n = 3$ ), abdominal ultrasound examination was not performed ( $n = 1$ ), diagnosis of gastric LSA with a normal small intestine on H&E ( $n = 1$ ), diagnosis of feline GI

eosinophilic sclerosing fibroplasia ( $n = 1$ ), or diagnosis of histoplasmosis ( $n = 1$ ). Six prospective cases were excluded because of inadequate sample for analysis ( $n = 2$ ), poor sample quality ( $n = 3$ ), or a diagnosis of gastric LSA with a normal small intestine on H&E ( $n = 1$ ). Fifty-seven cases (17 retrospective and 40 prospective) were available for analyses (Figure 1).

Demographic characteristics and clinical signs are shown in Table 1. Mean age was significantly higher for LSA (mean, 11.7 years; SD, 2.4) than IBD (mean, 7.6 years; SD, 3.6;  $P < .001$ ) cats. No significant associations were found between the diagnosis based on H&E or after integrating IHC and clonality testing and clinical signs or patient weight, nor between WSAVA score and clinical signs or patient weight ( $P > .05$ ).

#### 3.2 | Biopsy sample method, numbers, and quality

Biopsy sample numbers were reported as adequate for all cases, with exact numbers recorded in 37/57 cases, and a median of 11 USI biopsy samples (range, 6-20) and 5 LSI biopsy samples (range, 3-12) per case. Biopsy sample quality was commented on for all cases. For USI biopsies, 57/57 cases (100%) had samples of adequate quality. For LSI biopsies, 52/57 cases (91.2%) had samples of adequate quality and 5/57 cases (8.8%) had samples of marginal quality. In 37 cases where both biopsy sample numbers and quality were available, USI biopsy samples were of adequate quality in all cases; whereas LSI biopsy samples were of adequate quality in 34/37 (91.9%) cases, and of marginal quality in 3/37 (8.1%) cases. Increased LSI biopsy sample number was associated with superior sample quality ( $P < .05$ ). All USI biopsy samples were obtained by direct visualization. Except for 1 case where the LSI biopsy method was not recorded, samples were obtained by direct visualization in 44/56 (78.6%) cases and by blind technique in 12/56 (21.4%) cases. The number of LSI samples obtained by direct visualization or by blind technique ranged from 3 to 12 and 1 to 6 samples, respectively. In 56 cases where biopsy quality and technique information were available for both segments (detailed data not shown), biopsy sample quality in LSI biopsy samples obtained by direct visualization was adequate in

**TABLE 1** Demographic data

Number of cats	57
Demographic information	
Mean age in years (SD)	10.7 ( $\pm 3.2$ )
Median body weight in kg (range)	4.4 (2.2-8.6)
Sex	28 MN, 29 FS
Breeds	41 DSH, 3 Siamese, 3 mixed-breed, 2 Maine Coon, 2 Persian, 2 Bengal, 1 DLH, 1 Cornish Rex, 1 Ragdoll, 1 Norwegian Forest Cat
Clinical signs	
	Weight loss (49/57, 86.0%)
	Vomiting (46/57, 80.7%)
	Hyporexia (23/57, 40.4%)
	Diarrhea (19/57, 33.3%)
	Lethargy (9/57, 15.8%)
	Polyphagia (5/57, 8.8%)
	Dysuria (2/57, 3.5%)

Abbreviations: DLH: domestic longhair; DSH: domestic shorthair; FS: female spayed; MN: male neutered.

**TABLE 2** Histopathological assessments of 57 cases by H&E alone

		LSI H&E				Total
		Definitive IBD	Possible LSA	Probable LSA	Definitive LSA	
USI H&E	Definitive IBD	24 (42.1%)	1 (1.8%)	3 (5.3%)	1 (1.8%)	29 (50.9%)
	Possible LSA	1 (1.8%)	2 (3.5%)	0 (0.0%)	1 (1.8%)	4 (7.0%)
	Probable LSA	2 (3.5%)	0 (0.0%)	6 (10.5%)	0 (0.0%)	8 (14.0%)
	Definitive LSA	1 (1.8%)	1 (1.8%)	1 (1.8%)	13 (22.8%)	16 (28.1%)
	Total	28 (49.1%)	4 (7.0%)	10 (17.5%)	15 (26.3%)	57 (100%)
Diagnosis		n (%)				
IBD		24 (42.1)				
Possible/probable LSA		15 (26.3%)				
LSA		18 (31.5%)				

Abbreviations: H&E: hematoxylin and eosin; IBD: inflammatory bowel disease; LSA: lymphoma; LSI: lower small intestine; n: number; USI: upper small intestine.

40/44 cases (90.9%) and marginal in 4/44 cases (9.1%); whereas biopsy quality in LSI biopsy obtained blindly was judged to be adequate in 11/12 cases (91.7%) and marginal in 1 case (8.3%). Blind LSI biopsy technique was significantly associated with a decreased number of biopsy samples ( $P = .001$ ), but was not associated with inferior biopsy sample quality ( $P = 1.00$ ).

### 3.3 | Histopathologic results

Based on H&E assessment alone (Figure 1; Table 2), cats were categorized as DefIBD (24 cats, 42.1%), PossLSA (4 cats, 7.0%), ProbLSA (11 cats, 19.3%), and DefLSA (18 cats, 31.6%). Of the 31 biopsy sections diagnosed as DefLSA (16 USI, 15 LSI), 28/31 (90.3%) sections had a monomorphic population of lymphocytes in the lamina propria that fully effaced the normal architecture, whereas 3/31 (9.7%) had relatively uniform homogenous populations of lymphocytes, with (1/31) or without (2/31) marked intraepithelial lymphocytes (IEL) that were suggestive of LSA but had not fully effaced and replaced the normal mucosal architecture. The H&E assessment led to 24 cats being diagnosed with IBD (42.1%), 15 cats with PossLSA or ProbLSA (26.3%) and 18 cats with LSA (31.5%).

### 3.4 | Immunohistochemistry and clonality testing

As previously stated, IHC was performed using a stepwise approach, starting with the T-cell marker CD3+, but additional stains were pursued

**TABLE 3** Clonality assessments by polymerase chain reaction for antigen receptor rearrangements (PARR)

		LSI clonality		Total
		Polyclonal	Clonal	
USI clonality	Polyclonal	13 (22.8%)	1 (1.8%)	14 (24.6%)
	Clonal	7 (12.3%)	36 (63.2%)	43 (75.4%)
	Total	20 (35.9%)	37 (64.9%)	57 (100%)

Abbreviations: H&E: hematoxylin and eosin; IBD: inflammatory bowel disease; IHC: immunohistochemistry; LSA: lymphoma; LSI: lower small intestine; n: number; USI: upper small intestine.

		LSI H&E + IHC + clonality		
		IBD	LSA	Total
USI H&E + IHC + clonality	IBD	13 (22.8%)	1 (1.8%)	14 (24.6%)
	LSA	6 (10.5%)	37 (64.9%)	43 (75.4%)
	Total	19 (33.3%)	38 (66.7%)	57 (100%)
Diagnosis		n (%)		
IBD		13 (22.8)		
LSA		44 (77.2)		

Abbreviations: H&E: hematoxylin and eosin; IBD: inflammatory bowel disease; IHC: immunohistochemistry; LSA: lymphoma; LSI: lower small intestine; n: number; USI: upper small intestine.

if deemed necessary. All sections were positive for CD3+. Based on PARR testing (Table 3), both USI and LSI sections were polyclonal in 13 (22.8%) cases, and both USI and LSI sections were clonal in 36 (62.3%) cases. The remaining 8 cases had discordant results between USI and LSI sections. In 2 cases, the pathologist suggested additional IHC staining because of concern for large granular lymphocytic (LGL) LSA. In total, 3 biopsy sections (1 USI and 2 LSI) were GrB positive (GrB+), which is considered consistent with LGL-LSA. In 1 cat, both USI and LSI sections were GrB+ and were clonal. In another cat, the USI section was GrB- and clonal in a polyclonal background, and the LSI section was GrB+ and polyclonal, reported as LSA in the USI and LGL-LSA in the LSI.

### 3.5 | Reclassification of cases based on integrated interpretation of H&E staining, IHC, and clonality testing

Results from histopathological assessment of H&E stains, IHC, and clonality testing were integrated by the external pathologist and reported as an overall case interpretation, with IBD in 13/57 cats (22.8%) and LSA in 44/57 cats (77.2%; Figure 1; Table 4).

Eleven of 24 (45.8%) cases initially categorized as DefIBD, and 15/15 (100%) cases initially categorized as PossLSA or ProbLSA were reclassified as LSA after consideration of IHC and clonality testing. In total, 26/39 (66.7%) cases of DefIBD/PossLSA/ProbLSA were reclassified as LSA. No DefLSA case was reclassified as IBD. Among the 44 cases of LSA, 80 biopsy sections showed clonal rearrangements. Of those 80 biopsy sections, 26 sections had clonal rearrangement in a polyclonal background, including 10/18 (55.6%), 4/7 (5.7%), 5/19 (26.3%), and 7/36 (19.4%) sections that initially were diagnosed as DefIBD, PossLSA, ProbLSA, and DefLSA on histopathology, respectively. In 11 LSA cases, the pattern of T-cell receptor rearrangement differed or was not clonally related between USI and LSI sections, although some identical clonal peaks were present in both sections in 1 case.

### 3.6 | Additional histopathological features

The most common features were increased IEL, lamina propria lymphocytes or plasma cells, crypt dilatation or distortion, and mucosal or

**TABLE 4** Assessments by H&E, IHC, and clonality testing

		LSI H&E + IHC + clonality		
		IBD	LSA	Total
USI H&E + IHC + clonality	IBD	13 (22.8%)	1 (1.8%)	14 (24.6%)
	LSA	6 (10.5%)	37 (64.9%)	43 (75.4%)
	Total	19 (33.3%)	38 (66.7%)	57 (100%)
Diagnosis		n (%)		
IBD		13 (22.8)		
LSA		44 (77.2)		

Abbreviations: H&E: hematoxylin and eosin; IBD: inflammatory bowel disease; IHC: immunohistochemistry; LSA: lymphoma; LSI: lower small intestine; n: number; USI: upper small intestine.

lamina propria fibrosis. A positive association was found between the severity of IEL scores (ie, minimal or mild vs moderate or marked) and a diagnosis of DefIBD, Poss/ProbLSA or DefLSA based on H&E alone ( $P < .001$ ) or a diagnosis of IBD or LSA after integrating IHC and clonality testing ( $P = .003$ ). A positive association was found between severity of lamina propria lymphocytes and plasma cells scores (ie, minimal or mild vs moderate or marked) and a diagnosis of DefIBD, Poss/ProbLSA, or DefLSA on H&E ( $P < .001$ ) and after integration of IHC and clonality testing ( $P < .01$ ).

### 3.7 | Agreement between USI and LSI

Agreement between USI and LSI samples was moderate based on H&E assessment alone ( $\kappa = 0.66$ ) and after integrating IHC and clonality testing ( $\kappa = 0.70$ ). Based on H&E alone, LSA was diagnosed in 3/18 (16.7%) cases from USI samples alone and in 2/18 (11.1%) cases diagnosed from LSI samples alone. After IHC and clonality, LSA was diagnosed in 6/44 cases (13.6%) from USI samples alone, but only in 1/44 cases (2.3%) from LSI samples alone.

## 4 | DISCUSSION

We evaluated the diagnostic utility of procuring both USI and LSI when results of histopathology are integrated with IHC and clonality testing for the diagnosis of IBD or LSA in cats. Results showed that integration of IHC and PARR with histopathology increased the frequency of a diagnosis of LSA. The mean age of our population was 10.7 years, comparable to other studies where CE usually occurred in middle-aged to older cats.<sup>1,4,6-9,11,13</sup> Consistent with previous reports, cats with LSA were significantly older compared to cats with a final diagnosis of IBD.<sup>6,7,9,14,13</sup> Clinical signs were not associated with diagnosis, reaffirming reports by others that clinical signs cannot differentiate the 2 conditions.<sup>1,6,7,9,14</sup>

After integrating IHC and clonality testing results, 67% of DefIBD/PossLSA/ProbLSA cases were reclassified as LSA, including 46% of the DefIBD cases (43.9% of sections) and 100% of the PossLSA/ProbLSA cases (96.2% of sections). The only PossLSA section not reclassified as LSA was interpreted as possible emerging LSA because of oligoclonality (markedly decreased TCRG repertoire diversity in a chronic inflammatory background) or multiple neoplastic clones. Emerging LSA was reported as the likely reason for oligoclonality in a lesion that is morphologically consistent with LSA in GI biopsy samples from cats.<sup>15</sup> This situation can be difficult to prove without serial biopsies, but in this case, LSA was diagnosed in the USI. The large number of cases reclassified to LSA is comparable to what was observed in a previous study.<sup>4</sup> One study evaluating 53 cats with alimentary LSA and IBD reported that 24.0% of H&E only-diagnosed IBD cases were reclassified to LSA after integration of IHC.<sup>3</sup> Another study evaluating 77 cats reported that 18.0% of H&E only-diagnosed IBD cases were reclassified as LSA after IHC integration, and 26.9% cases of the IHC-diagnosed IBD cases were reclassified as LSA after integration of clonality testing.<sup>9</sup>

In contrast, a study evaluating 63 cats reported only 26.0% of H&E only-diagnosed IBD cases were reclassified as LSA after integration of IHC, but this number doubled to 53% after also integrating clonality testing, which is similar to our results.<sup>4</sup>

Most sections diagnosed as DefLSA (90%) had a monomorphic population of lymphocytes effacing the lamina propria, and some had uniform homogenous populations of lymphocytes that had not fully effaced the normal mucosal architecture, which is a common finding in alimentary small cell LSA in cats.<sup>4,6,7,9-11,14,15</sup> In 1 study, dense monomorphic lymphoid infiltrates of small to intermediate-sized cells that effaced the lamina propria or the entire mucosa were readily recognized as mucosal T-cell LSA, although these architectural alterations only were observed in advanced mucosal T-cell LSA.<sup>15</sup> Less advanced LSA cases may have had less severe histological changes that were less likely to be interpreted as DefLSA, and may explain the large proportion of IBD cases that were reclassified as LSA in our study and a previous study.<sup>4</sup>

In contrast to the high rate of reclassification of IBD cases to LSA, none of our cases diagnosed with LSA were reclassified as IBD. This finding is in contrast to previous reports where up to 15.6%,<sup>8</sup> 12.5%,<sup>9</sup> and 8.1%<sup>4</sup> of cases with an initial diagnosis of LSA were reclassified as IBD based on IHC or clonality testing or both. The discrepancies might be a result of high interobserver variability for the histopathologic assessment of biopsy samples,<sup>16</sup> different biopsy sampling techniques, and variabilities in conduction, performance, and interpretation of clonality testing.<sup>17</sup> Although the sensitivity of PCR-based clonality assays performed on FFPE tissue generally is considered to be high (>90%), a study in humans with lymphoproliferative disease identified specificities as low as 54.3% in patients with reactive lesions, despite the use of standardized clonality assays. Currently, there are no standards for conducting or interpreting clonality assays in veterinary medicine.<sup>17,18</sup> Only H&E staining and IHC were performed in a previous study,<sup>8</sup> and LSA cases were reclassified based on the presence of mixed CD3+/CD79a+ lymphocytes. However, alimentary LSA in cats often coexists with inflammatory lesions, and a background of mixed infiltrates does not necessarily rule out LSA. We found that 18/44 cases with clonal sections had a polyclonal background, consistent with a diagnosis of LSA with concurrent inflammation. A possible progression of IBD to LSA over months to years has been hypothesized.<sup>15,19</sup> In 1 study, 60% cats with alimentary LSA had a prior clinical history indicative of IBD, and IBD was identified in intestinal segments proximal or distal to those with LSA in cats where tissue was available.<sup>19</sup>

A stepwise approach of histopathology, followed by immunophenotyping, and finally testing to determine the clonality of infiltrating T- and B-cells generally is recommended.<sup>4,17,20</sup> Immunohistochemistry and clonality results were considered separately rather than in conjunction in another study.<sup>9</sup>

T-cell receptor rearrangement pattern differed between USI and LSI sections in 11 LSA cases. Identical neoplastic T-cell clones in different GI segments is more common, although the occurrence of 2 unrelated clones in topologically distinct sites in a single cat has been reported.<sup>15,19</sup>

Epitheliotropism, present in 38% of feline alimentary LSA cases, is an important diagnostic feature, and the presence of clusters of IELs in villous or crypt epithelium is readily recognizable.<sup>15</sup> Higher inter-observer variability however occurs in diffuse villous epitheliotropism, which may be under-recognized in H&E-stained sections although it appears more abundant on IHC.<sup>15,21</sup> This variability may have contributed to the 46% DefIBD cases that were reclassified to LSA after integration of IHC and clonality.

Moderate agreement was found between USI and LSI sections. In cases where LSA was present in only 1 of the sections, 3/18 (17%) were only diagnosed in the USI compared with 2/18 (11%) in only the LSI on H&E assessment alone. After integration of IHC and clonality testing, only 1 case of LSA was diagnosed in the LSI alone. In contrast, a previous study reported poor agreement between the USI and LSI, with 17% having LSA in both sections, 39% LSA only in the USI, and 44% only in the LSI.<sup>11</sup> However, LSI samples in that study were significantly more likely to be classified as “marginal” in quality (16%) compared to USI (3%) samples. This difference may be related to biopsy technique, because most of their LSI samples were obtained by blind biopsy. Only 21% of our cases had blind LSI biopsies performed, with 9% of LSI samples classified as marginal in quality, compared to 100% of USI samples classified as adequate quality. Decreased LSI biopsy number was associated with decreased sample quality, and blind LSI biopsy technique was associated with fewer biopsy samples. Although blind technique itself was not associated with inferior biopsy sample quality, our study may have been underpowered to detect such an association because there was only 1 case with marginal quality that was obtained by blind technique. Furthermore, fewer prospective cases were excluded because of sample issues (5/46, 10.9%) than were retrospective cases (13/34, 38.2%), because more samples had been acquired during the prospective portion of the study. Higher quality samples would decrease the number of biopsy samples needed to establish a diagnosis, improve the pathologist's ability to arrive at an accurate diagnosis on H&E staining and IHC, and also potentially increase the target DNA for clonality testing.<sup>5</sup> It has been reported previously that approximately 6 marginal or adequate samples from the stomach or duodenum are sufficient to diagnose mild or moderate cellular infiltration in cats.<sup>5</sup> Our median biopsy sample numbers were 11 and 5 per case for USI and LSI, respectively. Biopsy sample numbers were not reported in a previous study, and may have led to greater discrepancy in diagnoses between USI and LSI samples in that study.<sup>11</sup> Alimentary LSA in cats is most prevalent in the jejunum<sup>15,19</sup> or duodenum.<sup>21</sup> The duodenum and ileum in the cat are short, with median lengths of 9.2 and 2.5 cm, respectively.<sup>22</sup> In almost all cases, a 103 cm gastroscope can go well beyond this distance. Therefore, it is likely that most of our USI and many of our LSI samples also contained jejunum. Our results are consistent with our clinical experience, where the diagnosis arrived at by evaluating biopsy samples from the USI or LSI often were in agreement, and rarely did LSI samples change the diagnosis. This is clinically important because it suggests that if USI biopsy samples are collected, procuring LSI samples may not be necessary in most cases.

Clonality assays have become the gold standard for the diagnosis and differentiation of intestinal T-cell LSA in cats since their

introduction in 2005.<sup>4,15,19,23</sup> Evaluation of TCRG rearrangement on FFPE tissue is up to 91% sensitive for the detection of GI LSA in cats.<sup>15</sup> The high sensitivity may explain the large proportion of cases (69%) that were reclassified as LSA in our study and a previous study (53%).<sup>4</sup> Some reclassified LSA cases may have had neoplastic infiltrates elsewhere in the GI tract, and a phenomenon known as lymphocyte trafficking may have led to clonal TCRG rearrangements despite a lack of apparent histopathological changes.<sup>24</sup> Indolent lymphocyte clones were a possibility in our study cats, although this occurrence would be difficult to prove without long-term follow-up by serial biopsies.

The specificity of standardized T-cell clonality assays in a study of lymphoproliferative disease in humans was shown to be as low as 54%.<sup>25</sup> In a recent study, many middle-aged to older, clinically healthy cats were diagnosed with intestinal LSA based on histopathology and IHC and clonality testing.<sup>10</sup> A study of CE in cats found clonality assays to have a poor specificity of 33%.<sup>26</sup> Poor specificity of clonality testing also may explain our high reclassification rate. False-positive clonality results can occur because of benign clones, canonical rearrangements, or pseudoclonality.<sup>17</sup> Therefore, results of clonality assays should be interpreted along with clinical, histopathology, and IHC data,<sup>4</sup> and performed in the same laboratory, preferably by the same pathologist.<sup>17,20</sup> Unfortunately, not all veterinary laboratories follow this recommendation.<sup>17,18</sup> Meanwhile, false-negative results also can be a problem, mainly because of insufficient primer coverage.<sup>17,20</sup> Identification of all TCRG gene segments only will be possible when the feline genome is assembled.<sup>15</sup> Further evaluation of the specificity of clonality assays in veterinary medicine is warranted.

Our study had several limitations. Most of the cats had some form of dietary trial while being managed by the referring veterinarian, but we cannot verify this possibility for all cats nor can we verify which diets they were fed and if these diets were fed exclusively. Some of our cases were retrospective and approximately one-third of retrospective cases were excluded because of sample issues, often related to fewer numbers of samples obtained at the time. All tissue samples were from EBs. Although mucosal effacement and transmural lymphocytic invasion determined from full-thickness biopsy samples may help to diagnose LSA, alimentary small cell LSA manifests in the intestinal mucosa long before transmural progression.<sup>15,21,27</sup> This feature is supported by a previous study where the mucosal T-cell LSA group largely consisted of the small-cell type, whereas the transmural T-cell LSA group was mostly of the large-cell type, with a higher mortality rate in the transmural and large-cell groups, likely because of advanced disease.<sup>15</sup> In addition, given the limited number of full-thickness biopsy samples generally obtained, the diagnostically available mucosal surface can be substantially decreased compared to many EBs obtained over a larger anatomic area, and EBs may allow for early detection and treatment of alimentary small cell LSA (Marsilio et al. 2020, unpublished data). Although H&E assessment performed by 1 pathologist and the lack of a blinded review may introduce bias,<sup>16,28</sup> submitting samples to a single pathologist with relevant clinical information provided mimics what is done clinically, and using a pathologist with special interest in GI pathology may minimize interpretation variability. In 16 cases, histopathology was reviewed by >1 pathologist (10 retrospective and 6 prospective cases because of

pathologist availability or owner requests). Diagnoses either remained the same (11/16), were reported as more likely to be LSA (4/16; all subsequently were classified as LSA on IHC and clonality), or an initial report of PossLSA was reported as IBD (1/16; reclassified as LSA on IHC and clonality). A study with H&E assessments by multiple pathologists would allow for assessment of the degree of interobserver variability and the impact on the proportion of cases that become reclassified after applying IHC and clonality testing. Finally, exact biopsy sample numbers were available for only 65% of cases, which may or may not alter the association between sample number and quality.

## 5 | CONCLUSIONS

Our results show that the addition of IHC and clonality testing to H&E assessment increases the number of cases diagnosed with LSA. Although the sensitivity of clonality testing is considered to be high, further assessment of its specificity is warranted. Further research to determine if a change in diagnosis correlates with patient outcome is in progress. Additionally, moderate agreement was found for the diagnosis of IBD and LSA between samples collected from the USI or LSI upon histopathology alone or when integrating IHC and clonality testing. Importantly, in our study, samples from the LSI rarely led to a diagnosis of LSA that would otherwise have been diagnosed as IBD on USI samples alone.

## ACKNOWLEDGMENTS

No funding was received for this study. Portions of these data were presented at the 2018 American College of Veterinary Internal Medicine Forum in Seattle, WA. The authors thank Dr Peter F. Moore, Dr William Vernau, and Kristy L. Harmon from the Leukocyte Antigen Biology Laboratory at the University of California Davis, California, for their support of this study and consultation on the results. The authors also thank Gary Clark for his help with the statistical analysis.

## CONFLICT OF INTEREST DECLARATION

At the time of the study, authors Marsilio, Lidbury, Suchodolski, and Steiner are or were employed by the Gastrointestinal Laboratory at Texas A&M University, which offers laboratory tests, including histopathology services, on a fee-for-service basis. The author Ackermann is affiliated with Gastrointestinal Laboratory at Texas A&M University. The authors Chow, Hill, Richter, and Cocker have nothing to disclose.

## OFF-LABEL ANTIMICROBIAL DECLARATION

Authors declare no off-label use of antimicrobials.

## INSTITUTIONAL ANIMAL CARE AND USE COMMITTEE (IACUC) OR OTHER APPROVAL DECLARATION

The study protocol was approved by the Veterinary Specialty Hospital Research Advisory Committee, and written owner informed consent was obtained for each cat before enrollment into the prospective arm.

## ORCID

Betty Chow  <https://orcid.org/0000-0002-7775-3719>

Sina Marsilio  <https://orcid.org/0000-0002-0693-0669>

Jonathan A. Lidbury  <https://orcid.org/0000-0001-5107-4577>

Jan S. Suchodolski  <https://orcid.org/0000-0002-2176-6932>

Sarah Cocker  <https://orcid.org/0000-0002-8110-8894>

Jörg M. Steiner  <https://orcid.org/0000-0003-3336-2086>

## REFERENCES

- Barrs VR, Beatty JA. Feline alimentary lymphoma: 1. Classification, risk factors, clinical signs and non-invasive diagnostics. *J Feline Med Surg.* 2012;14:182-190.
- Barrs VR, Beatty JA. Feline alimentary lymphoma: 2. Further diagnostics, therapy and prognosis. *J Feline Med Surg.* 2012;14:191-201.
- Briscoe KA, Krockenberger M, Beatty JA, et al. Histopathological and immunohistochemical evaluation of 53 cases of feline lymphoplasmacytic enteritis and low-grade alimentary lymphoma. *J Comp Pathol.* 2011;145:187-198.
- Kiupel M, Smedley RC, Pfent C, et al. Diagnostic algorithm to differentiate lymphoma from inflammation in feline small intestinal biopsy samples. *Vet Pathol.* 2011;48:212-222.
- Washabau RJ, Day MJ, Willard MD, et al. Endoscopic, biopsy, and histopathologic guidelines for the evaluation of gastrointestinal inflammation in companion animals. *J Vet Intern Med.* 2010;24:10-26.
- Norsworthy GD, Scot Estep J, Kiupel M, Olson JC, Gassler LN. Diagnosis of chronic small bowel disease in cats: 100 cases (2008-2012). *J Am Vet Med Assoc.* 2013;243:1455-1461.
- Norsworthy GD, Estep JS, Hollinger C, et al. Prevalence and underlying causes of histologic abnormalities in cats suspected to have chronic small bowel disease: 300 cases (2008-2013). *J Am Vet Med Assoc.* 2015;247:629-635.
- Waly NE, Gruffydd-Jones TJ, Stokes CR, et al. Immunohistochemical diagnosis of alimentary lymphomas and severe intestinal inflammation in cats. *J Comp Pathol.* 2005;133:253-260.
- Sabattini S, Bottero E, Turba ME, Vicchi F, Bo S, Bettini G. Differentiating feline inflammatory bowel disease from alimentary lymphoma in duodenal endoscopic biopsies. *J Small Anim Pract.* 2016;57:396-401.
- Marsilio S, Ackermann MR, Lidbury JA, Suchodolski JS, Steiner JM. Results of histopathology, immunohistochemistry, and molecular clonality testing of small intestinal biopsy specimens from clinically healthy client-owned cats. *J Vet Intern Med.* 2019;33:551-558.
- Scott KD, Zoran DL, Mansell J, Norby B, Willard MD. Utility of endoscopic biopsies of the duodenum and ileum for diagnosis of inflammatory bowel disease and small cell lymphoma in cats. *J Vet Intern Med.* 2011;25:1253-1257.
- Day MJ, Bilzer T, Mansell J, et al. Histopathological standards for the diagnosis of gastrointestinal inflammation in endoscopic biopsy samples from the dog and cat: a report from the World Small Animal Veterinary Association Gastrointestinal Standardization Group. *J Comp Pathol.* 2008;138(Suppl 1):S1-S43.
- Fleiss JL, Levin B, Paik MC. The measurement of interrater agreement. *Statistical Methods for Rates and Proportions.* Hoboken, NJ: John Wiley & Sons; 2004:598-626.
- Evans SE, Bonczynski JJ, Broussard JD, Han E, Baer KE. Comparison of endoscopic and full-thickness biopsy specimens for diagnosis of inflammatory bowel disease and alimentary tract lymphoma in cats. *J Am Vet Med Assoc.* 2006;229:1447-1450.
- Moore PF, Rodriguez-Bertos A, Kass PH. Feline gastrointestinal lymphoma: mucosal architecture, immunophenotype, and molecular clonality. *Vet Pathol.* 2012;49:658-668.
- Willard MD, Jergens AE, Duncan RB, et al. Interobserver variation among histopathologic evaluations of intestinal tissues from dogs and cats. *J Am Vet Med Assoc.* 2002;220:1177-1182.



17. Keller SM, Vernau W, Moore PF. Clonality testing in veterinary medicine: a review with diagnostic guidelines. *Vet Pathol.* 2016;53:711-725.
18. Langerak AW. Toward standardization of clonality testing in veterinary medicine. *Vet Pathol.* 2016;53:705-706.
19. Moore PF, Woo JC, Vernau W, Kosten S, Graham PS. Characterization of feline T cell receptor gamma (TCRG) variable region genes for the molecular diagnosis of feline intestinal T cell lymphoma. *Vet Immunol Immunopathol.* 2005;106:167-178.
20. Langerak AW, Groenen P, Brüggemann M, et al. EuroClonality/BIOMED-2 guidelines for interpretation and reporting of Ig/TCR clonality testing in suspected lymphoproliferations. *Leukemia.* 2012;26:2159-2171.
21. Carreras JK, Goldschmidt M, Lamb M, McLearn R, Drobatz KJ, Sørensen KU. Feline epitheliotropic intestinal malignant lymphoma: 10 cases (1997-2000). *J Vet Intern Med.* 2003;17:326-331.
22. Santos ALQ, Menezes LT, Kaminishi APS, et al. Partial and total intestinal length of domestic cats *Felis catus domesticus* - (Linnaeus, 1758). *PUBVET.* 2011;5:14.
23. Hammer SE, Groiss S, Fuchs-Baumgartinger A, et al. Characterization of a PCR-based lymphocyte clonality assay as a complementary tool for the diagnosis of feline lymphoma. *Vet Comp Oncol.* 2017;15:1354-1369.
24. Habtezion A, Nguyen LP, Hadeiba H, Butcher EC. Leukocyte trafficking to the small intestine and colon. *Gastroenterology.* 2016;150:340-354.
25. Kokovic I, Novakovic BJ, Cerkovnik P, et al. Clonality analysis of lymphoid proliferations using the BIOMED-2 clonality assays: a single institution experience. *Radiol Oncol.* 2014;48:155-162.
26. Marsilio S, Newman SJ, Estep JS, et al. Differentiation of lymphocytic-plasmacytic enteropathy and small cell lymphoma in cats using histology-guided mass spectrometry. *J Vet Intern Med.* 2020;34:669-677.
27. Fondacaro JV, Richter KP, Carpenter JL, et al. Feline gastrointestinal lymphoma: 67 cases (1988-1996). *Eur J Comp Gastroenterol.* 1999;4:5-11.
28. Willard MD, Moore GE, Denton BD, et al. Effect of tissue processing on assessment of endoscopic intestinal biopsies in dogs and cats. *J Vet Intern Med.* 2010;24:84-89.

**How to cite this article:** Chow B, Hill SL, Richter KP, et al. Comprehensive comparison of upper and lower endoscopic small intestinal biopsy in cats with chronic enteropathy. *J Vet Intern Med.* 2021;35:190-198. <https://doi.org/10.1111/jvim.16000>