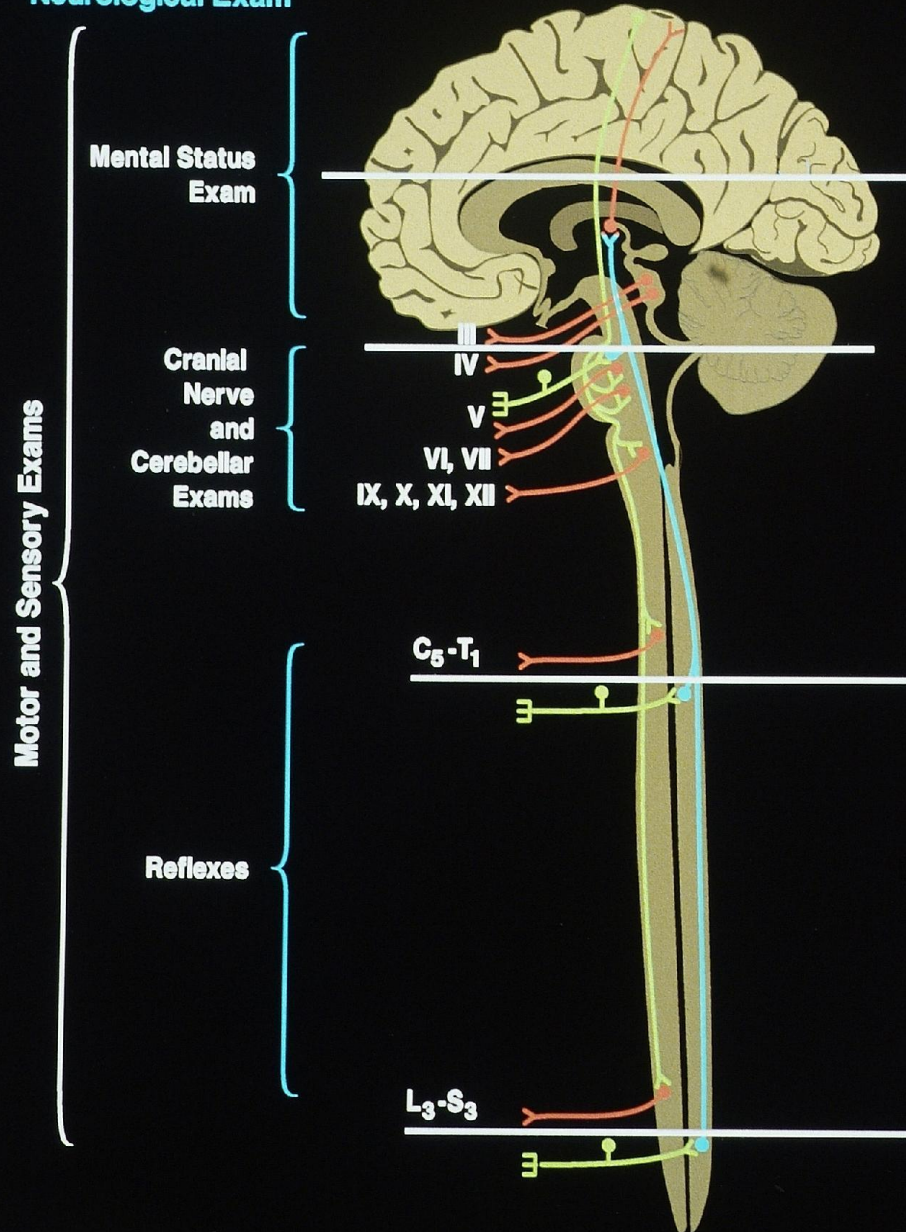
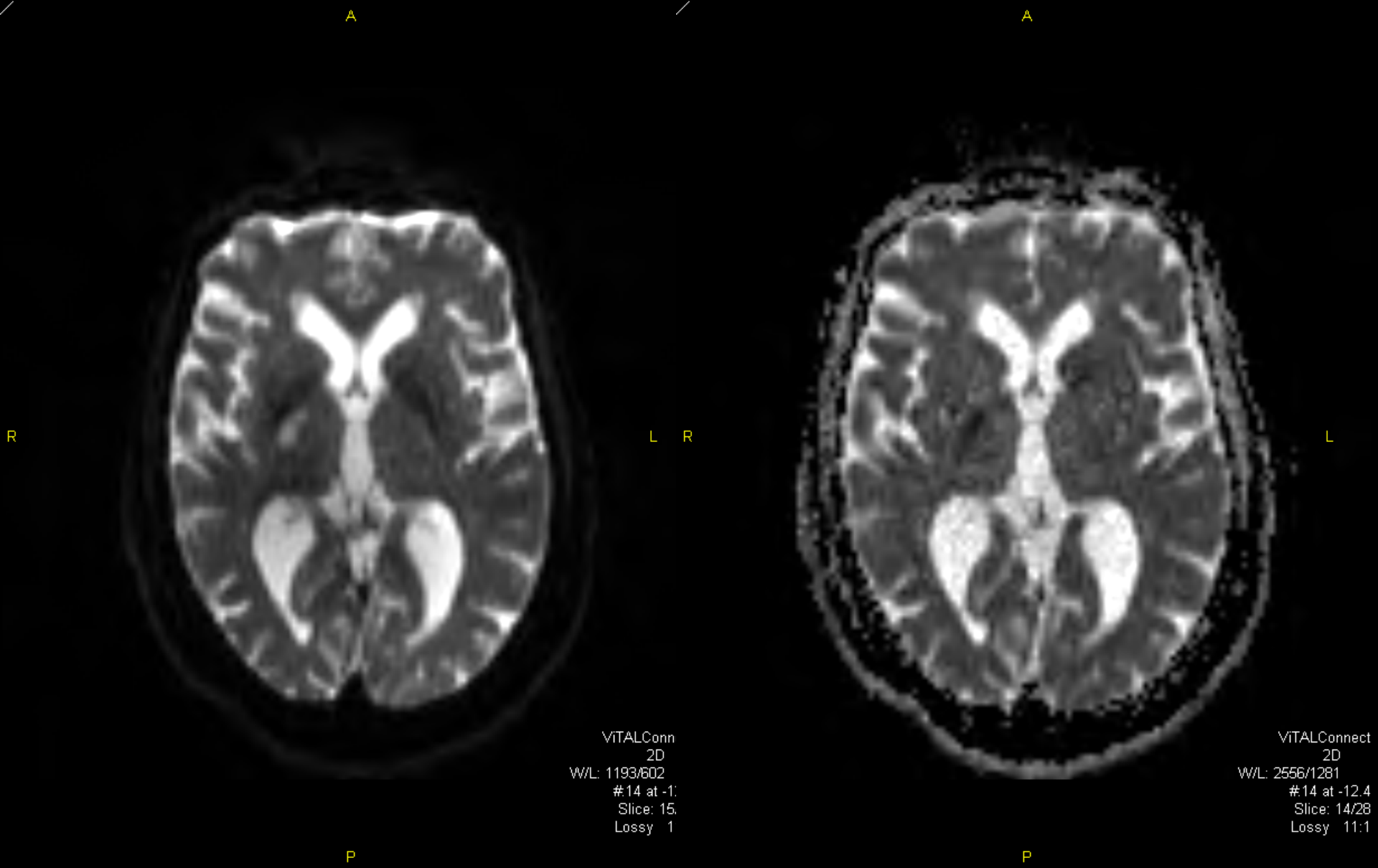


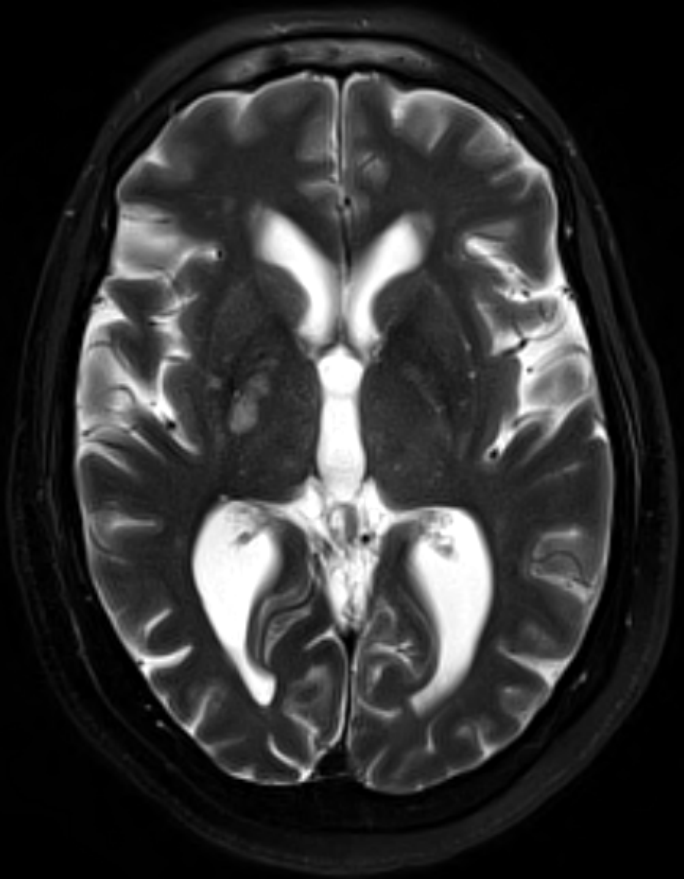
# Lesion Localization in Neurologic Disease

## Neurological Exam

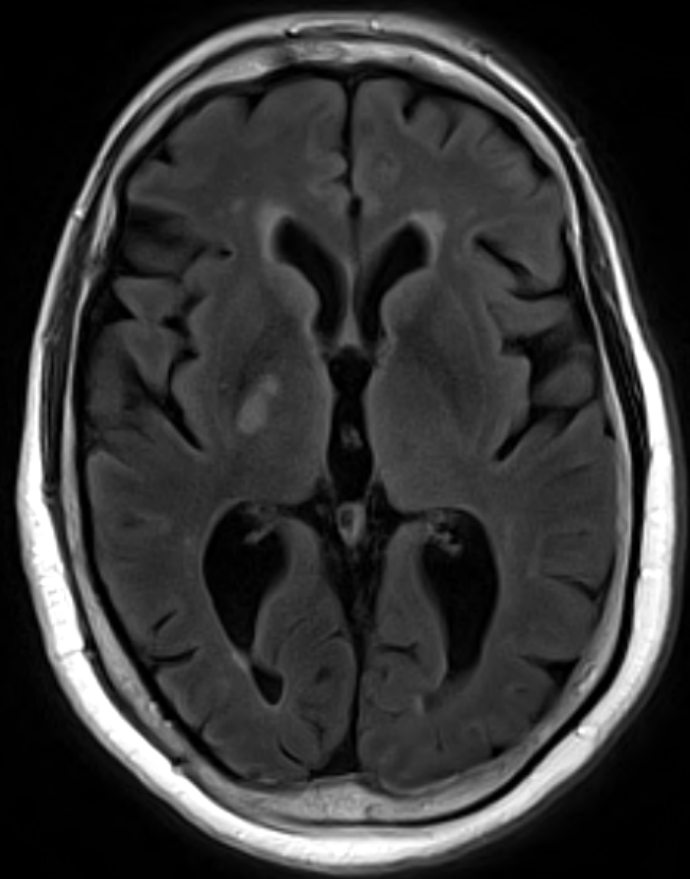




Horizontal DWI [left] & ADC [right] MRI Scan



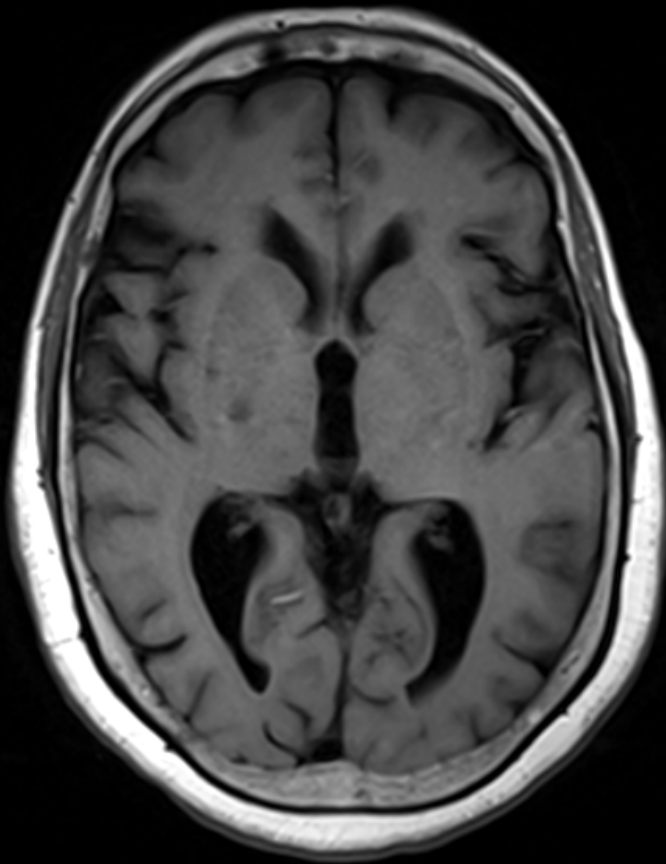
VITALConnect  
2D  
W/L: 1580/794  
#14 at -12.4  
Slice: 14/28  
Lossy 10:1



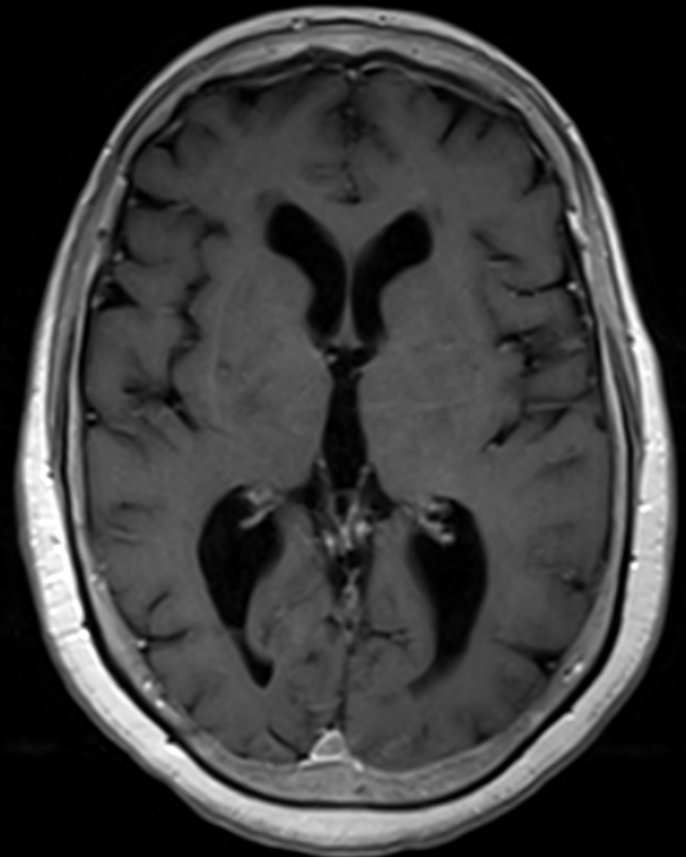
VITALConnect  
2D  
W/L: 1170/587  
#14 at -12.4  
Slice: 14/28  
Lossy 10:1

Horizontal T2W [left] & FLAIR [right] MRI Scan

12/29/09



VITALConnect  
2D  
W/L: 1452/728  
#14 at -12.4  
Slice: 14/28  
Lossy 10:1



VITALConnect  
2D  
W/L: 1809/908  
#14 at -12.4  
Slice: 14/28  
Lossy 10:1

Horizontal T1W [left] & T1W w Gd [right] MRI Scan

12/29/09

