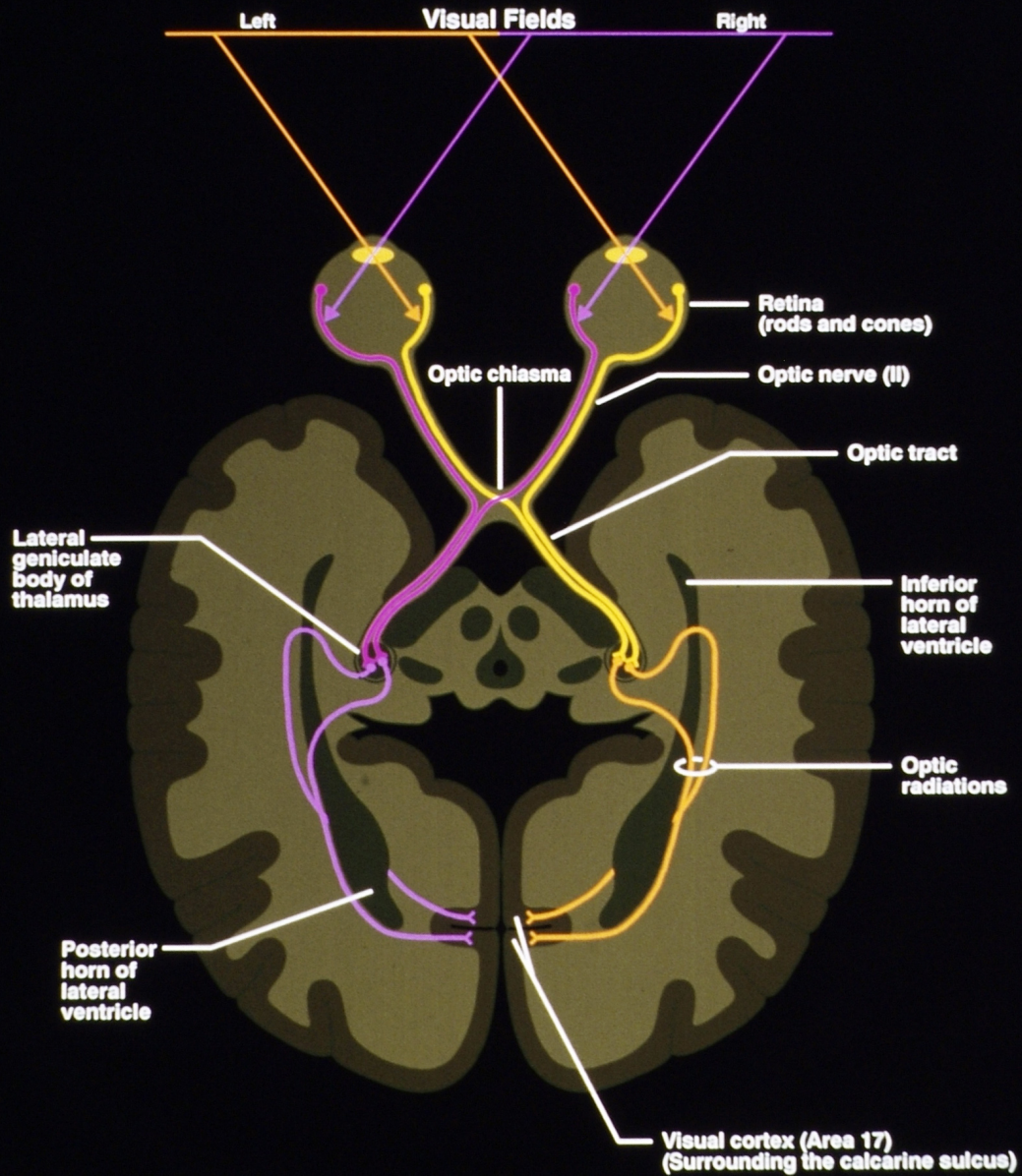
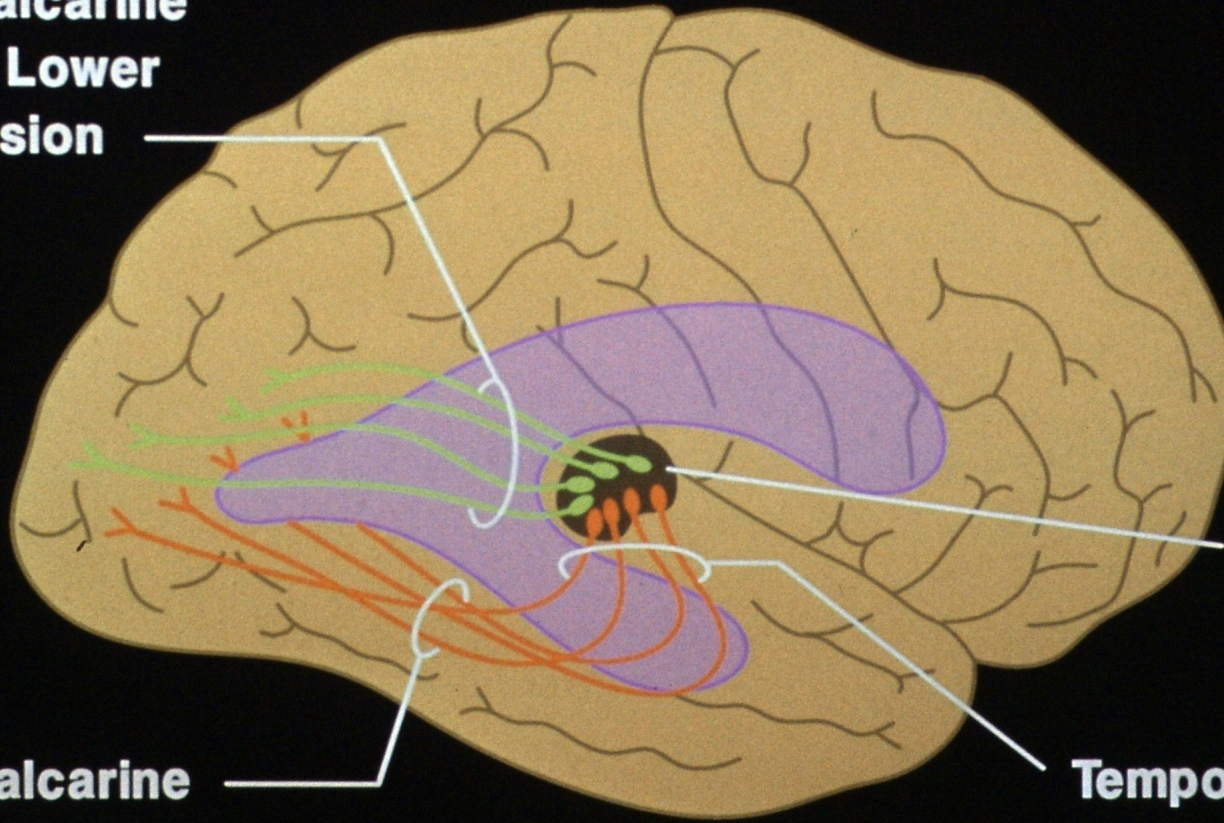


Visual Pathways



Optic Radiations

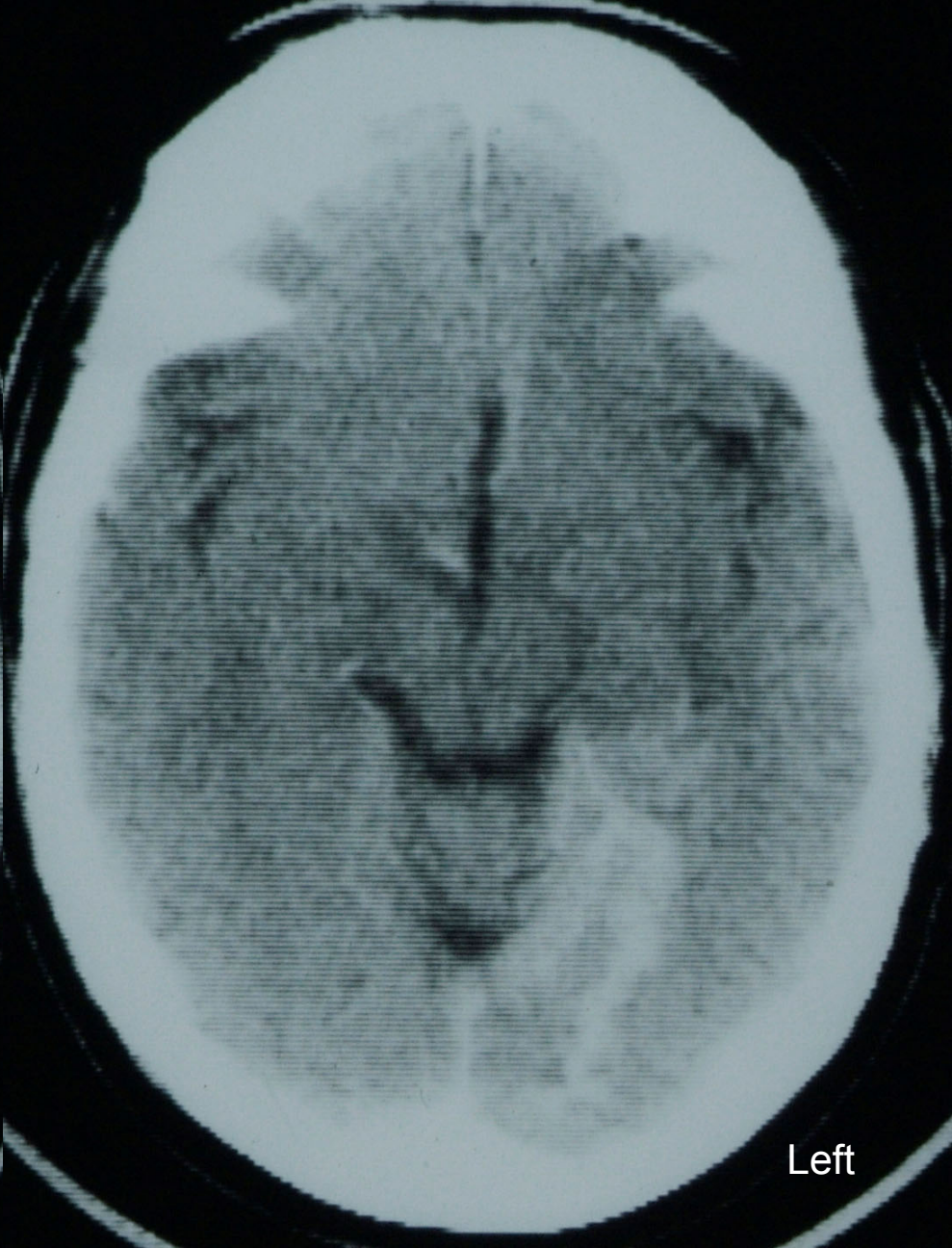
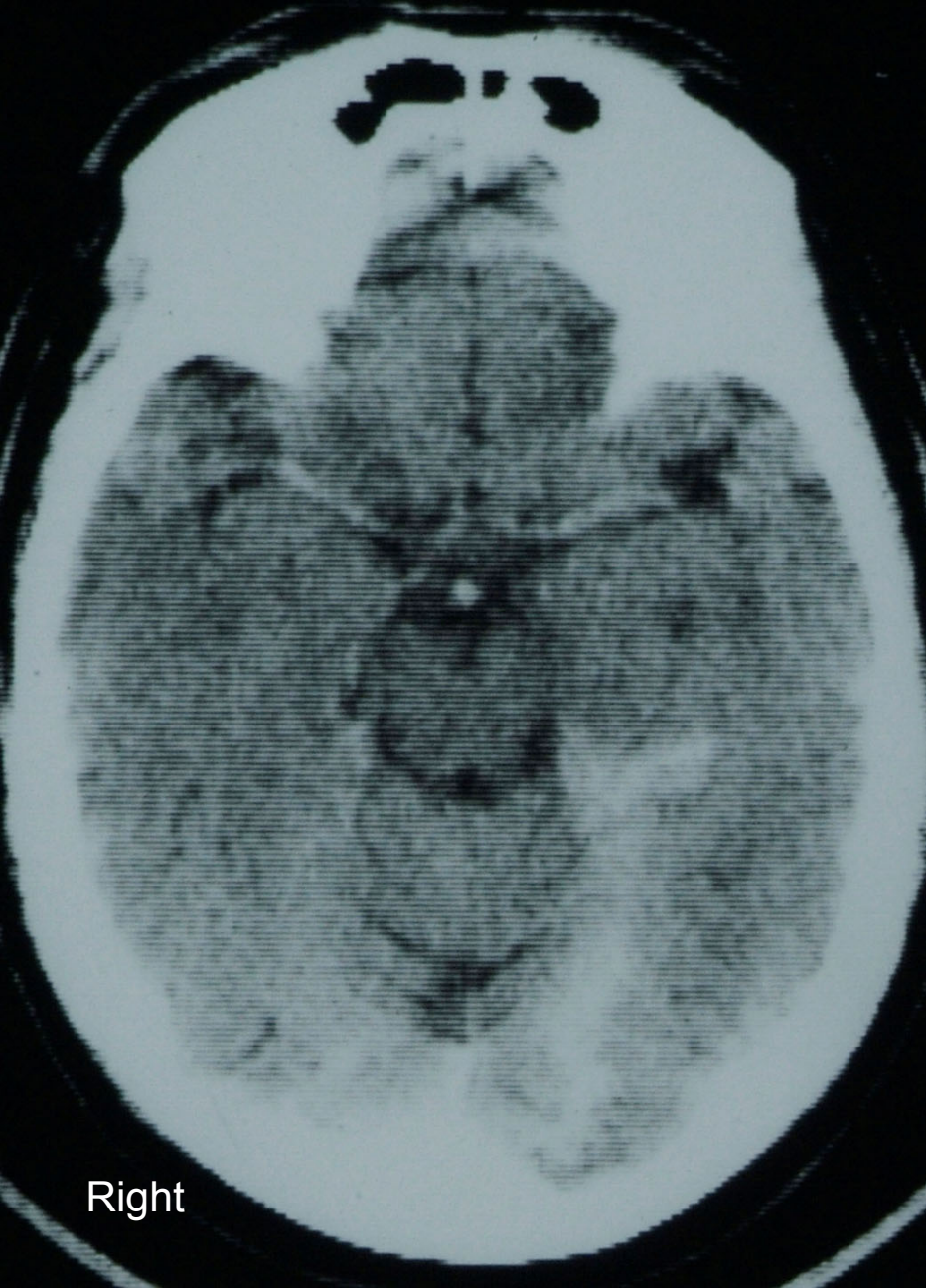
**Geniculocalcarine
Fibers for Lower
Field of Vision**



**Lateral
Geniculate
Body**

**Temporal
Loop**

**Geniculocalcarine
Fibers for Upper
Field of Vision**

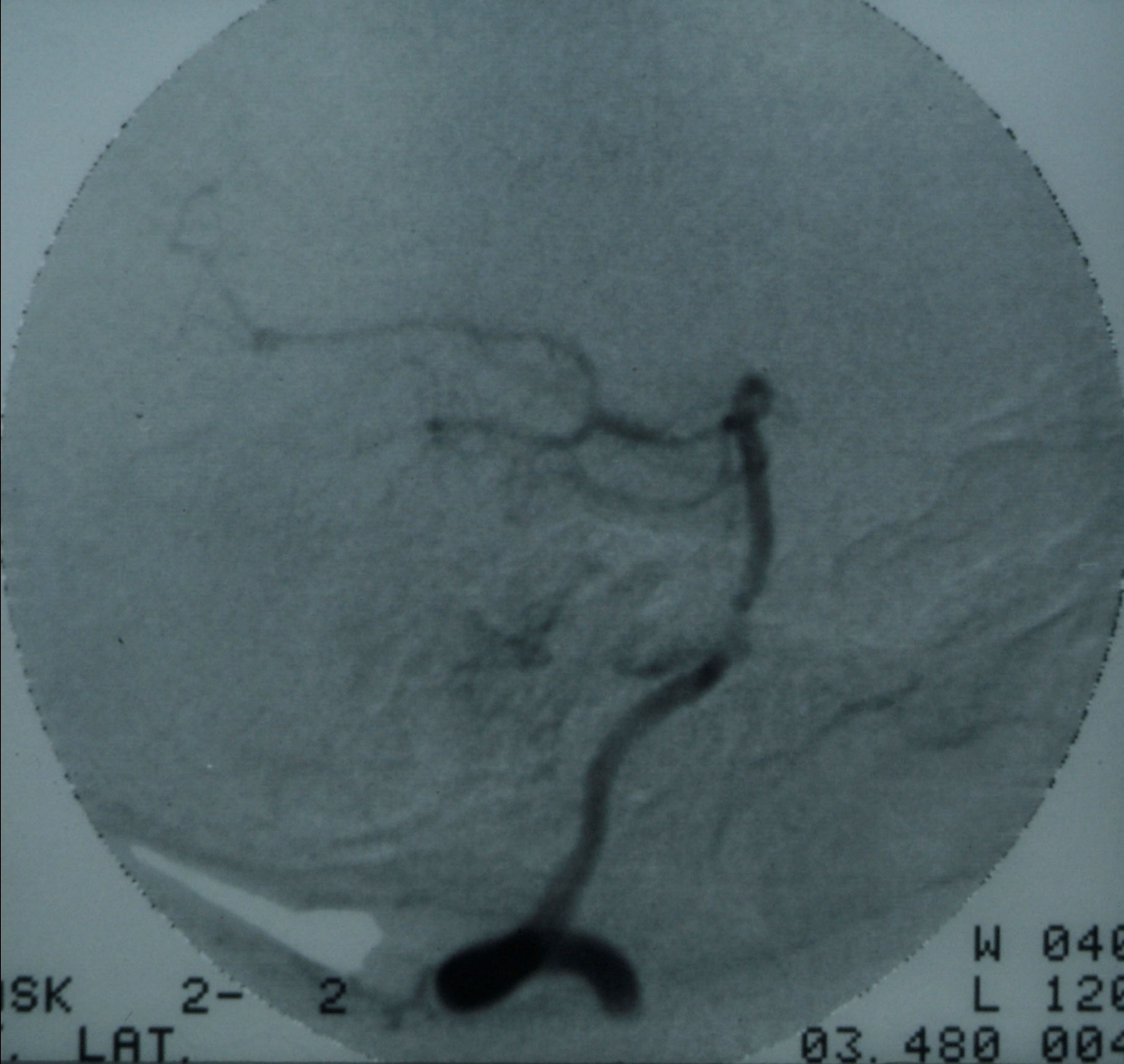

Right

Left

Horizontal CT Scan with contrast

1/10/84



Posterior

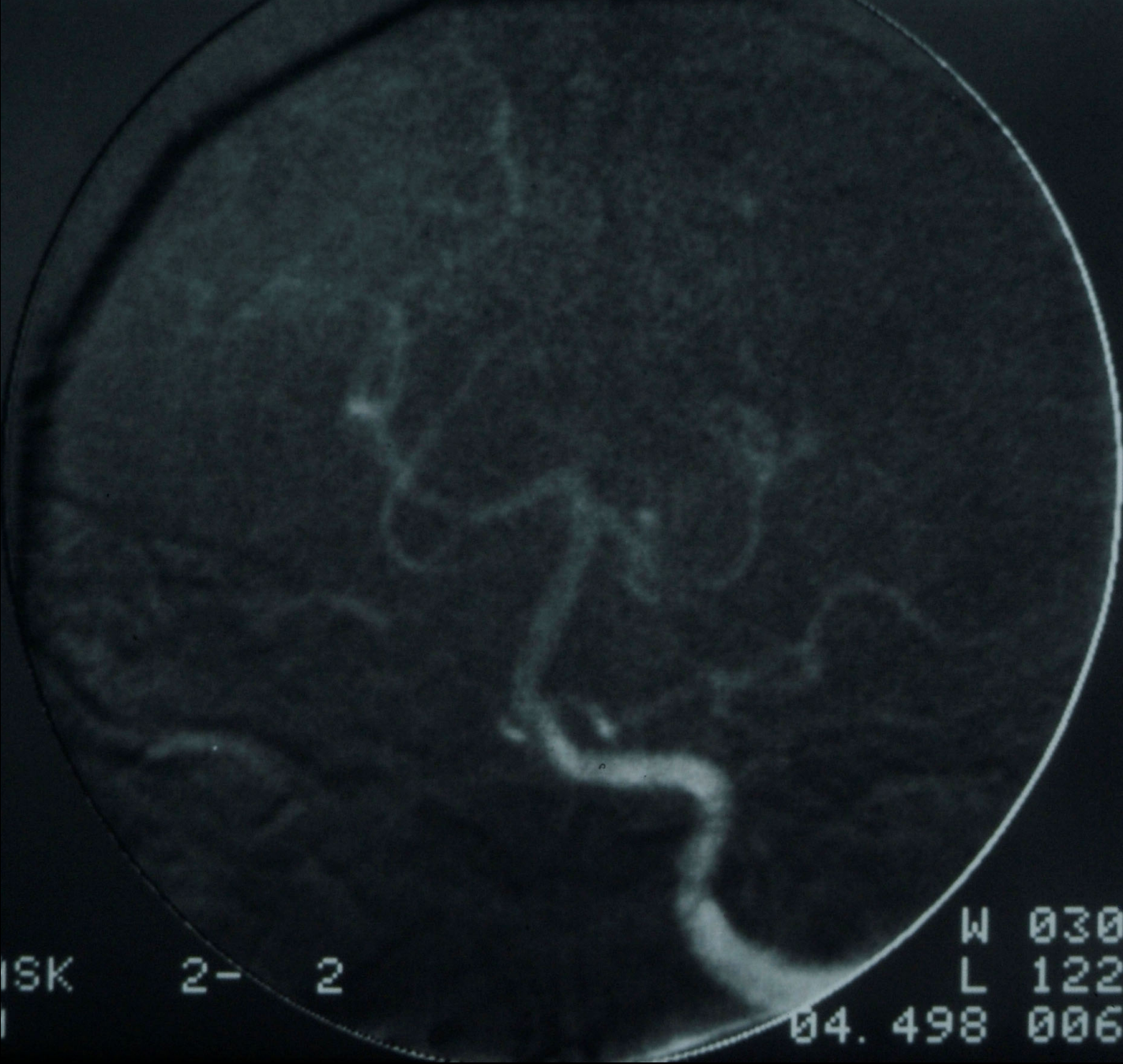
Anterior

SK 2- 2
LAT.

W 040
L 120
03. 480 004

Left Vertebral A. Arteriogram (Lateral View)

1/11/84



Right

Left

Left Vertebral A. Arteriogram (P-A View)

1/11/84