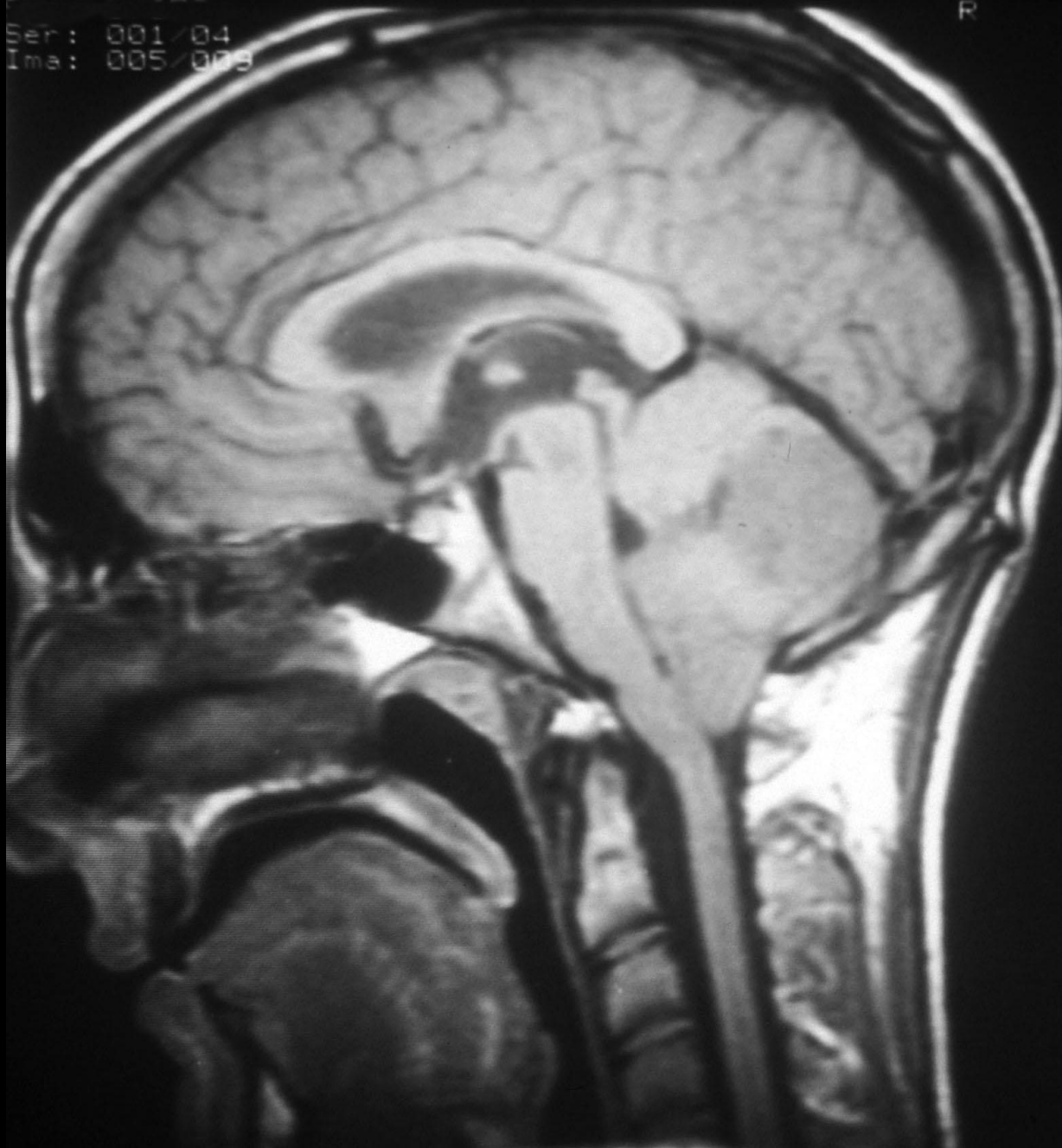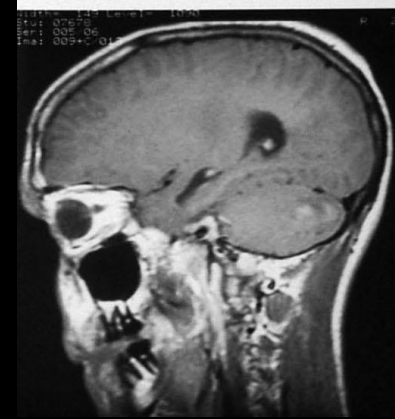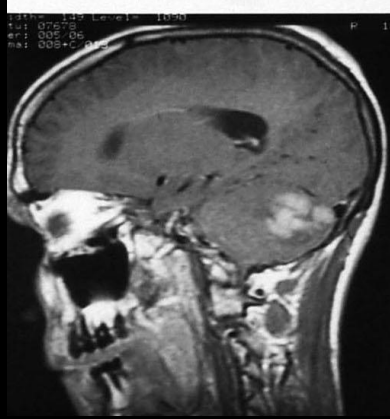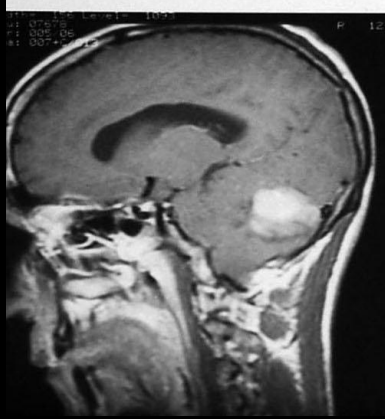
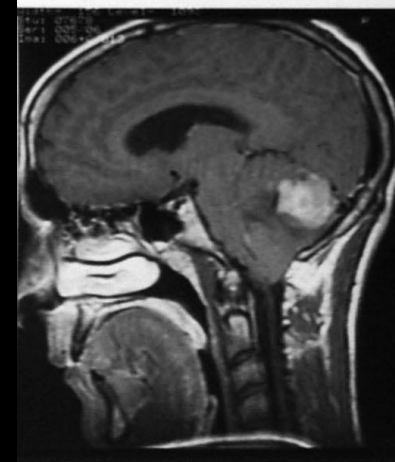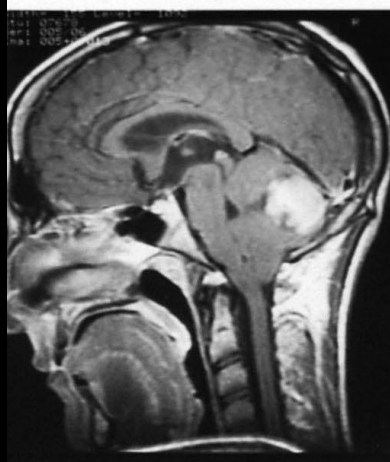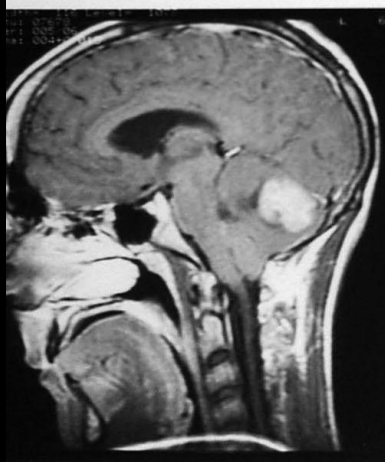
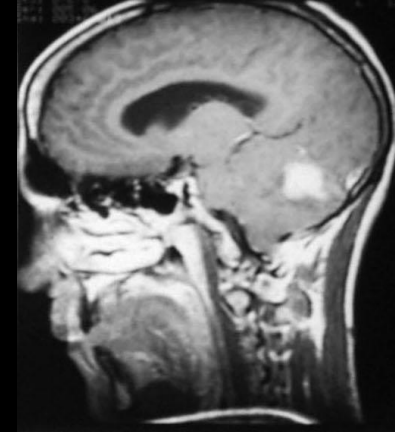
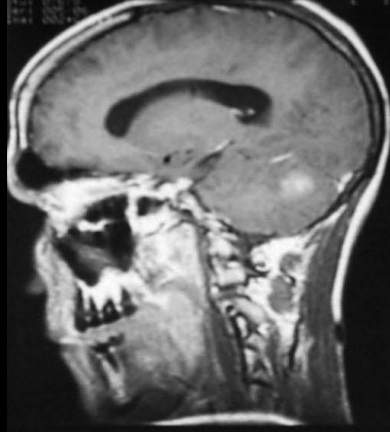
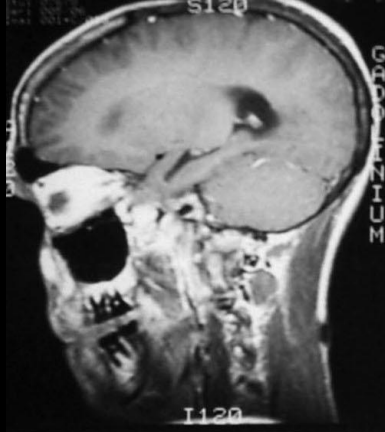
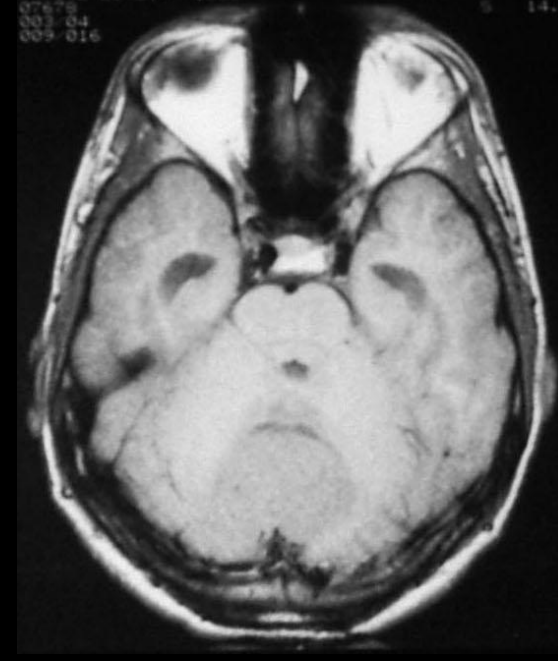
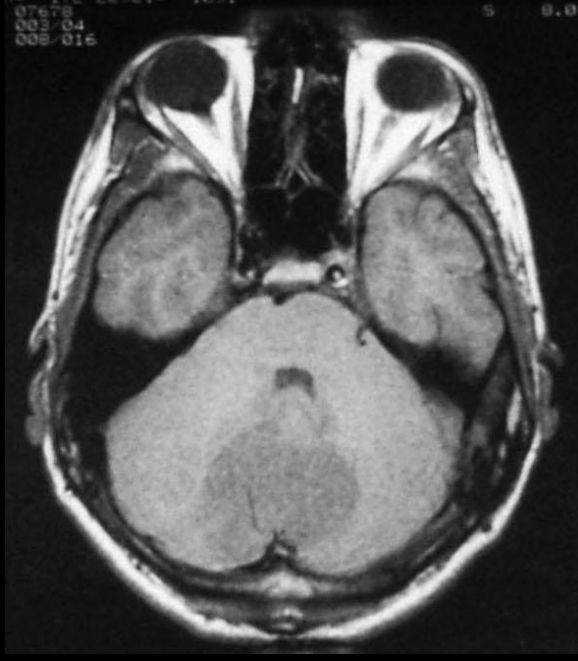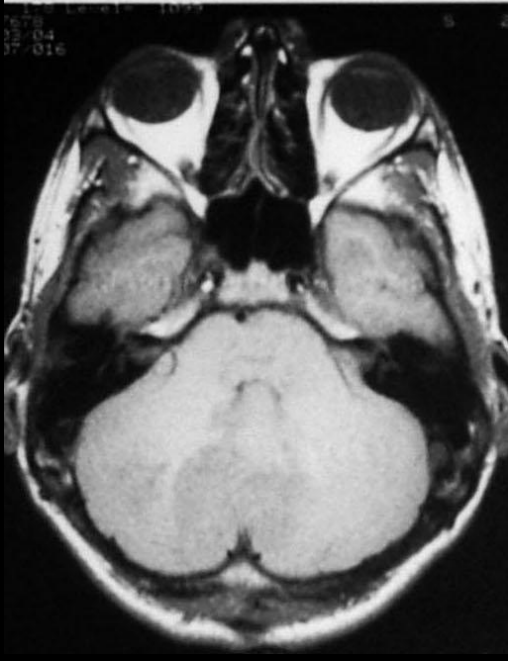
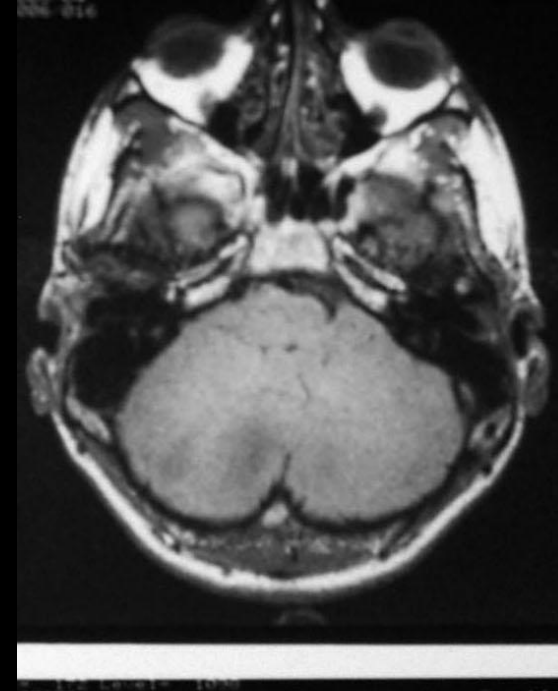
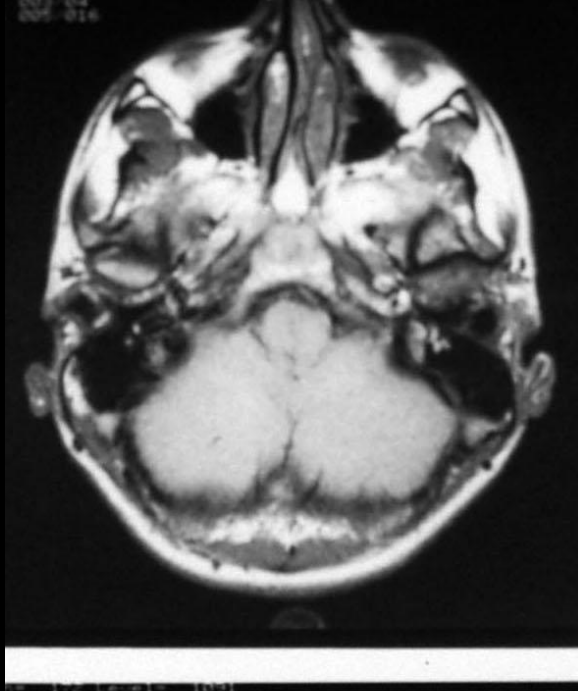
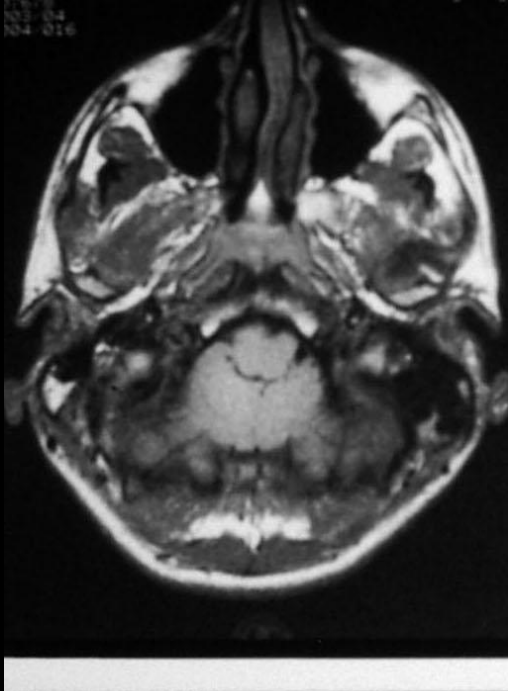




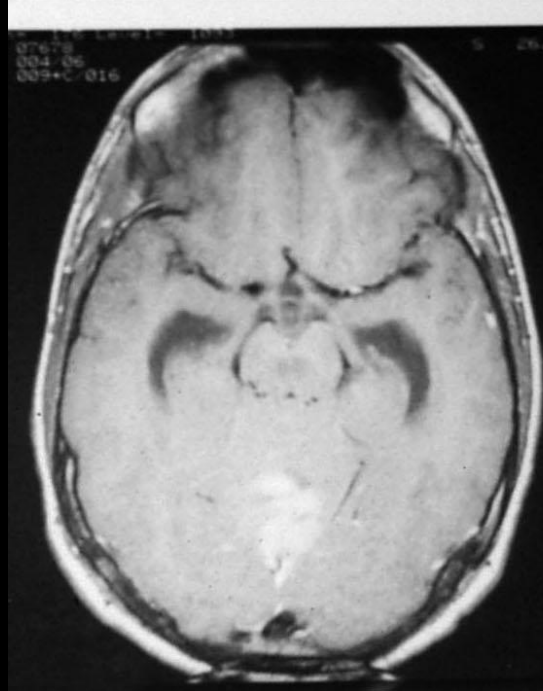
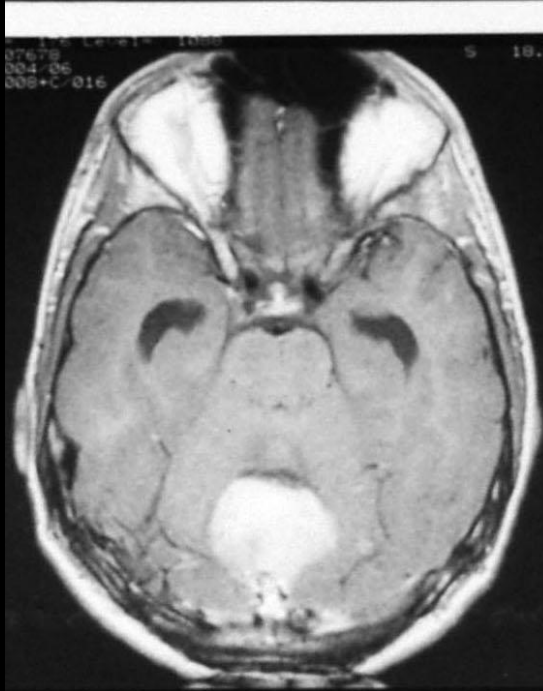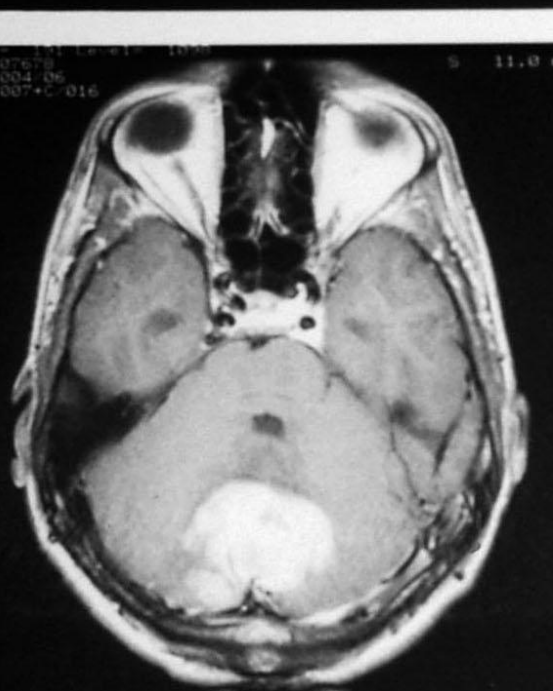
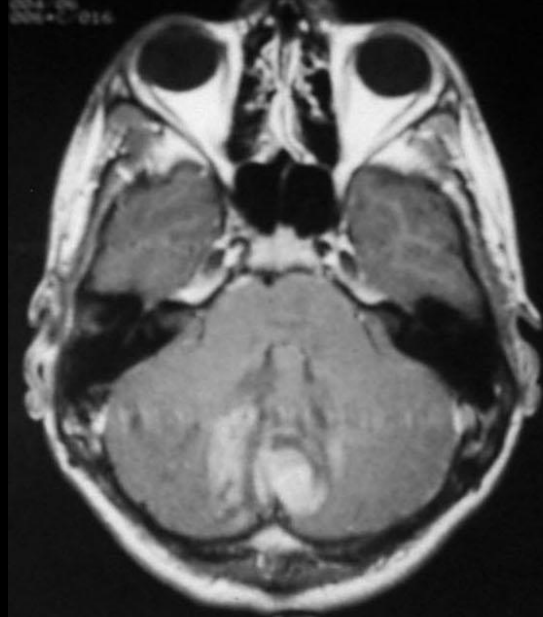
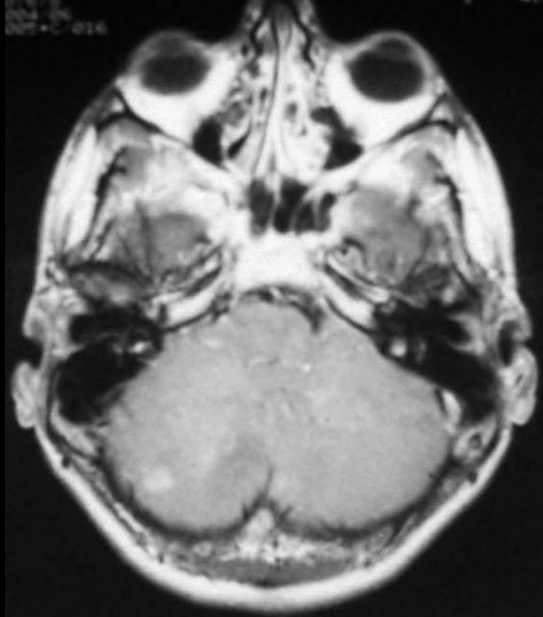
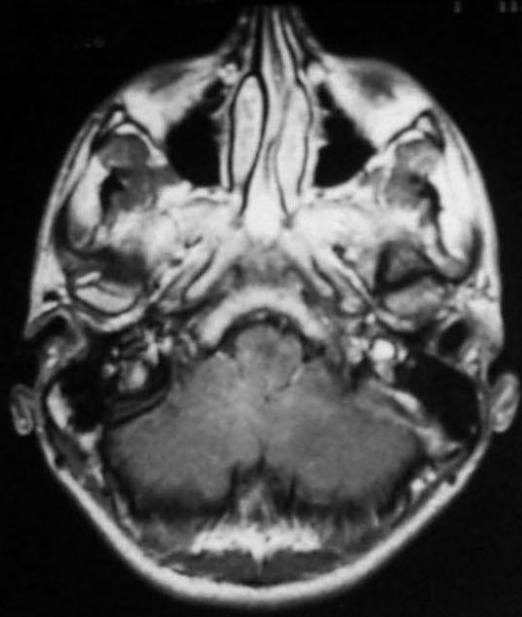
Sagittal T1W MRI Scan without GAD



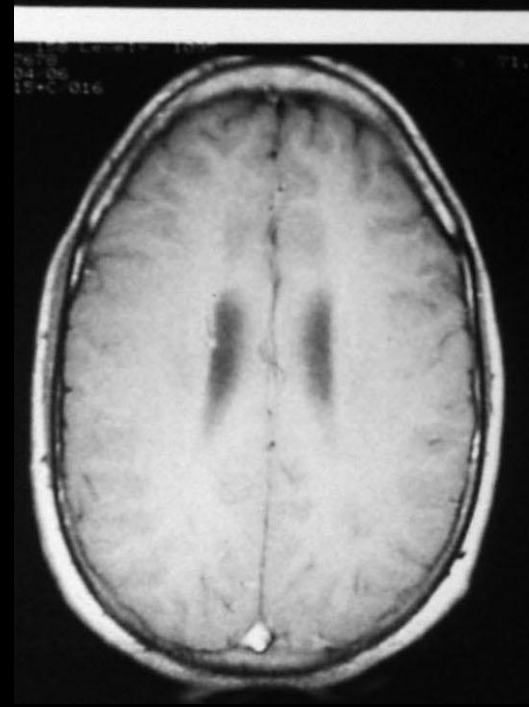
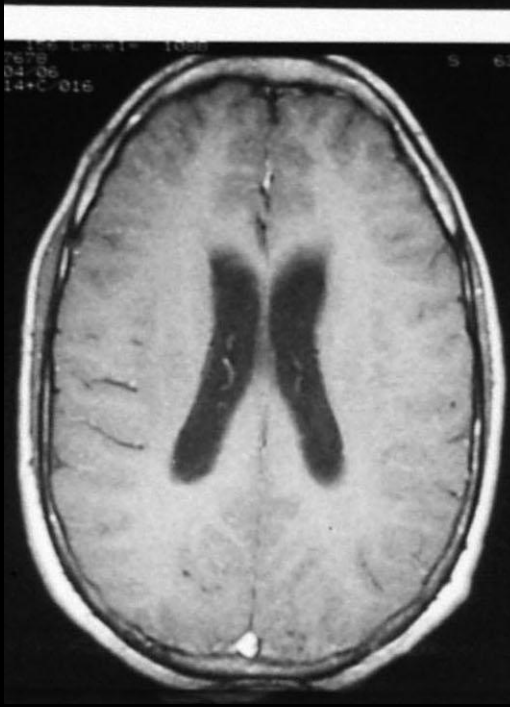
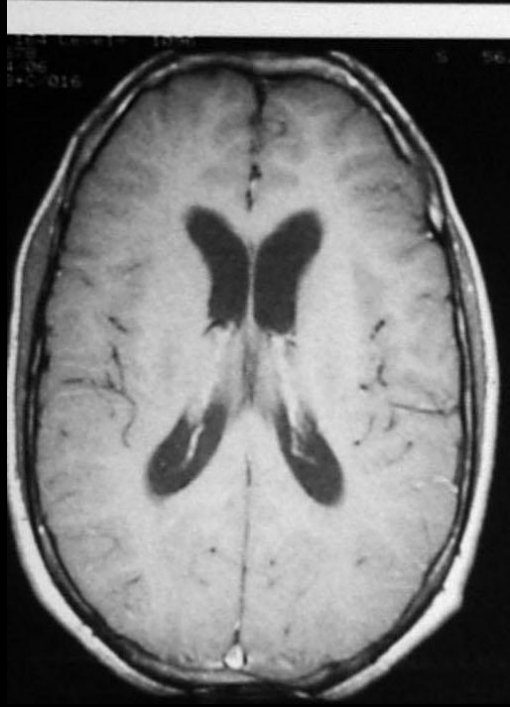
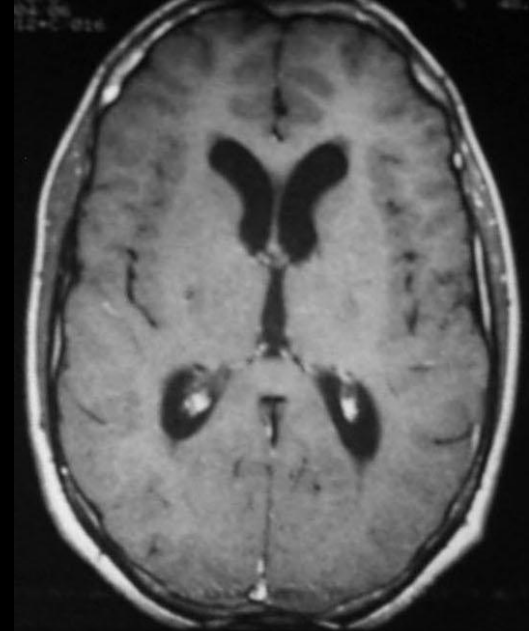
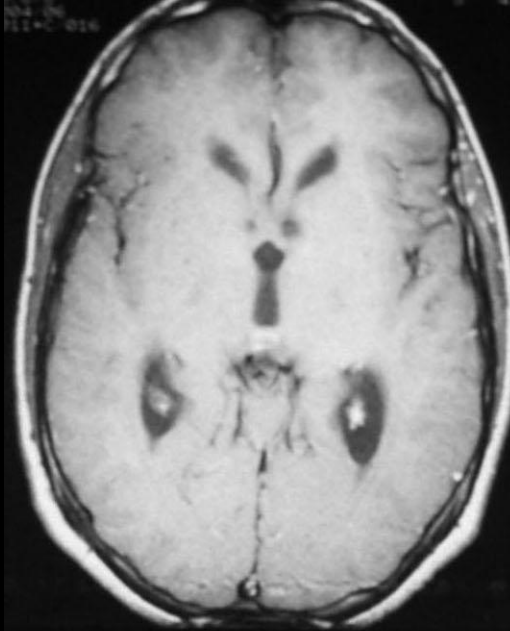
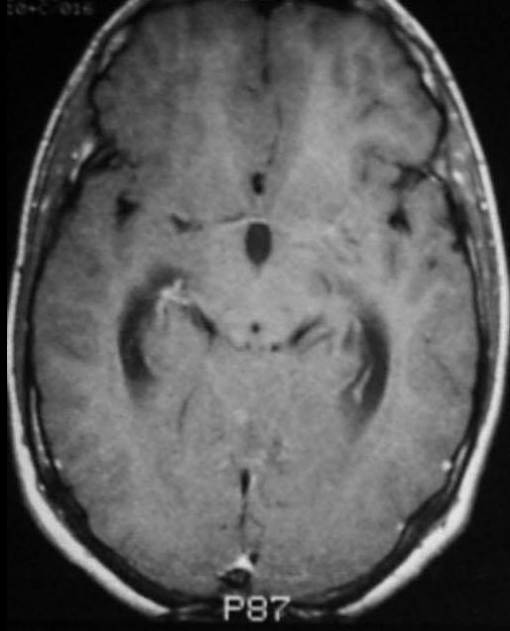
Sagittal T1W MRI Scan with GAD



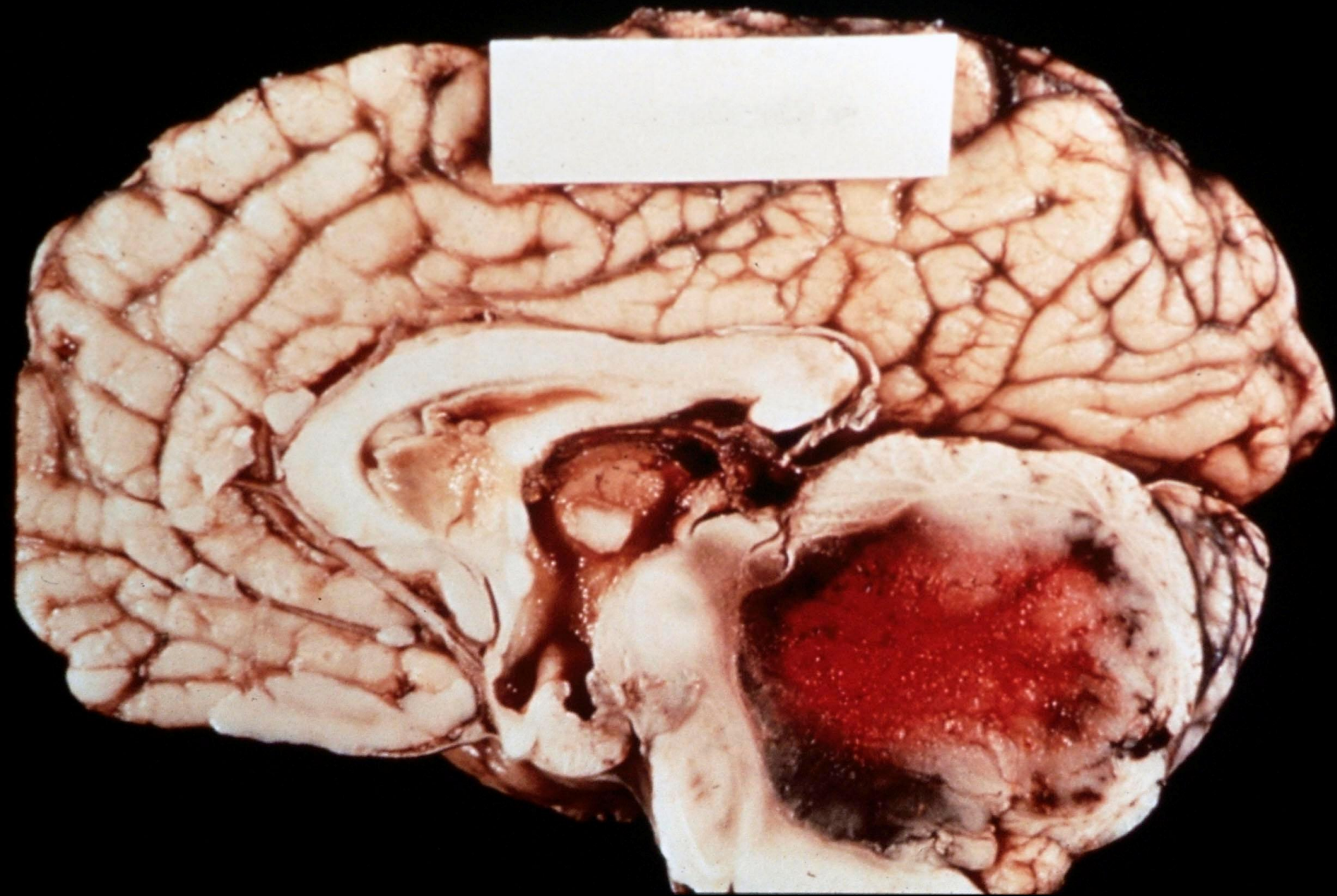
Horizontal T1W MRI Scan without GAD



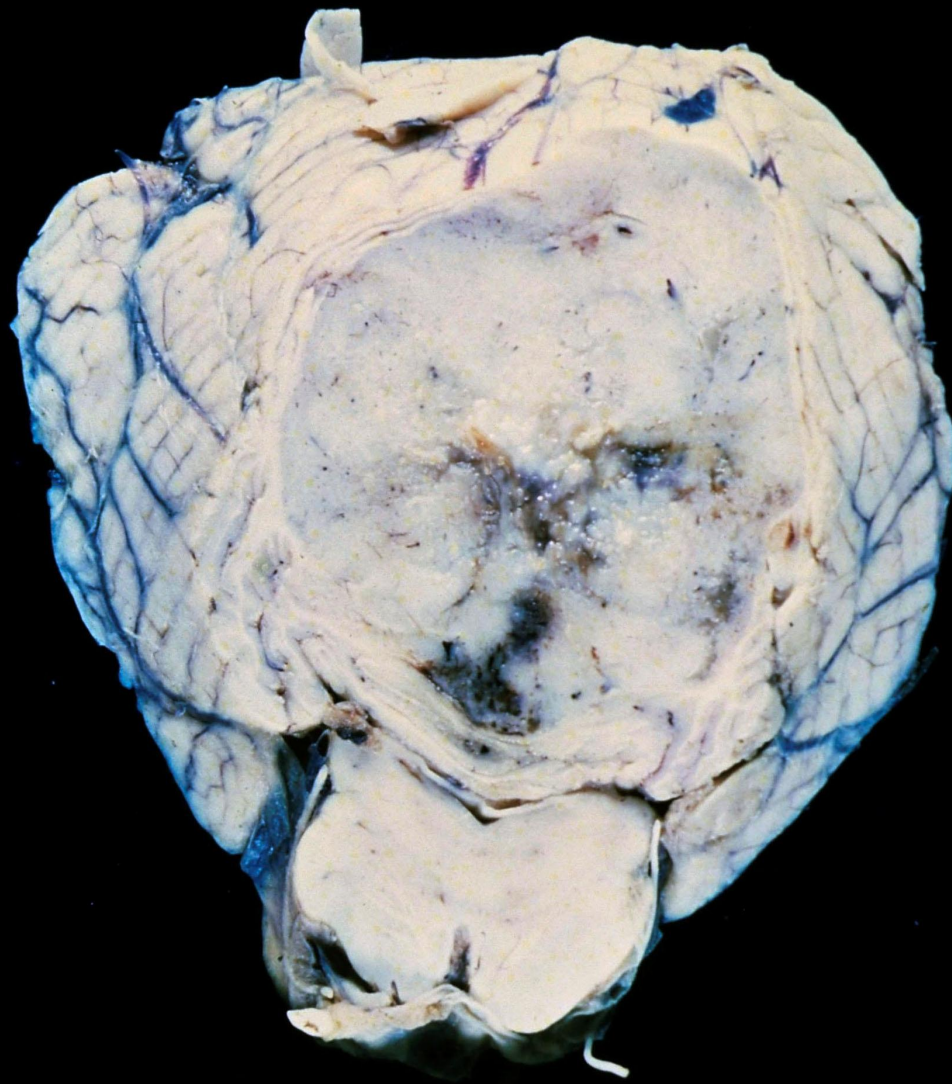
Horizontal T1W MRI Scan with GAD



Horizontal T1W MRI Scan with GAD showing Hydrocephalus



Medulloblastoma



Medulloblastoma