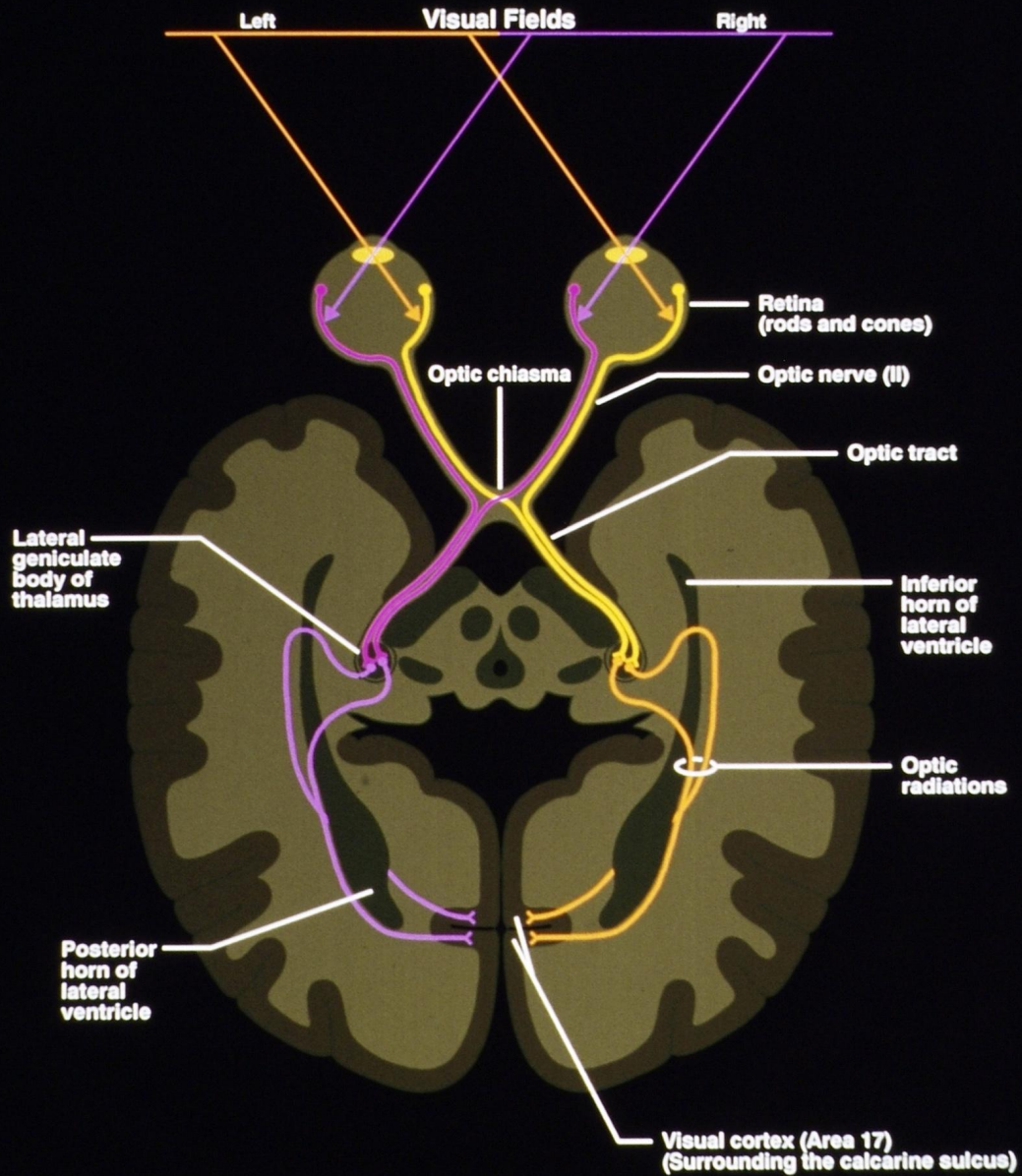
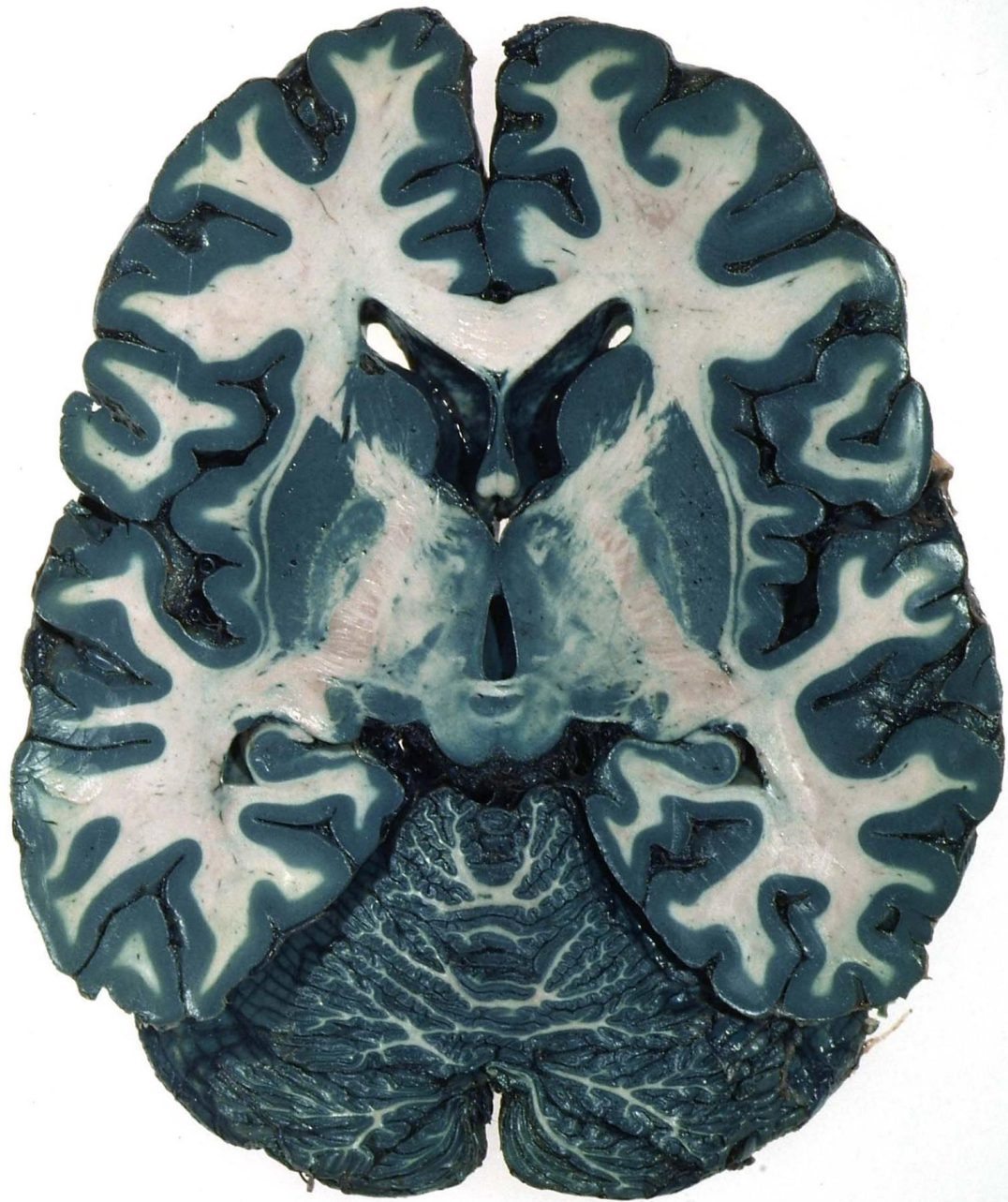
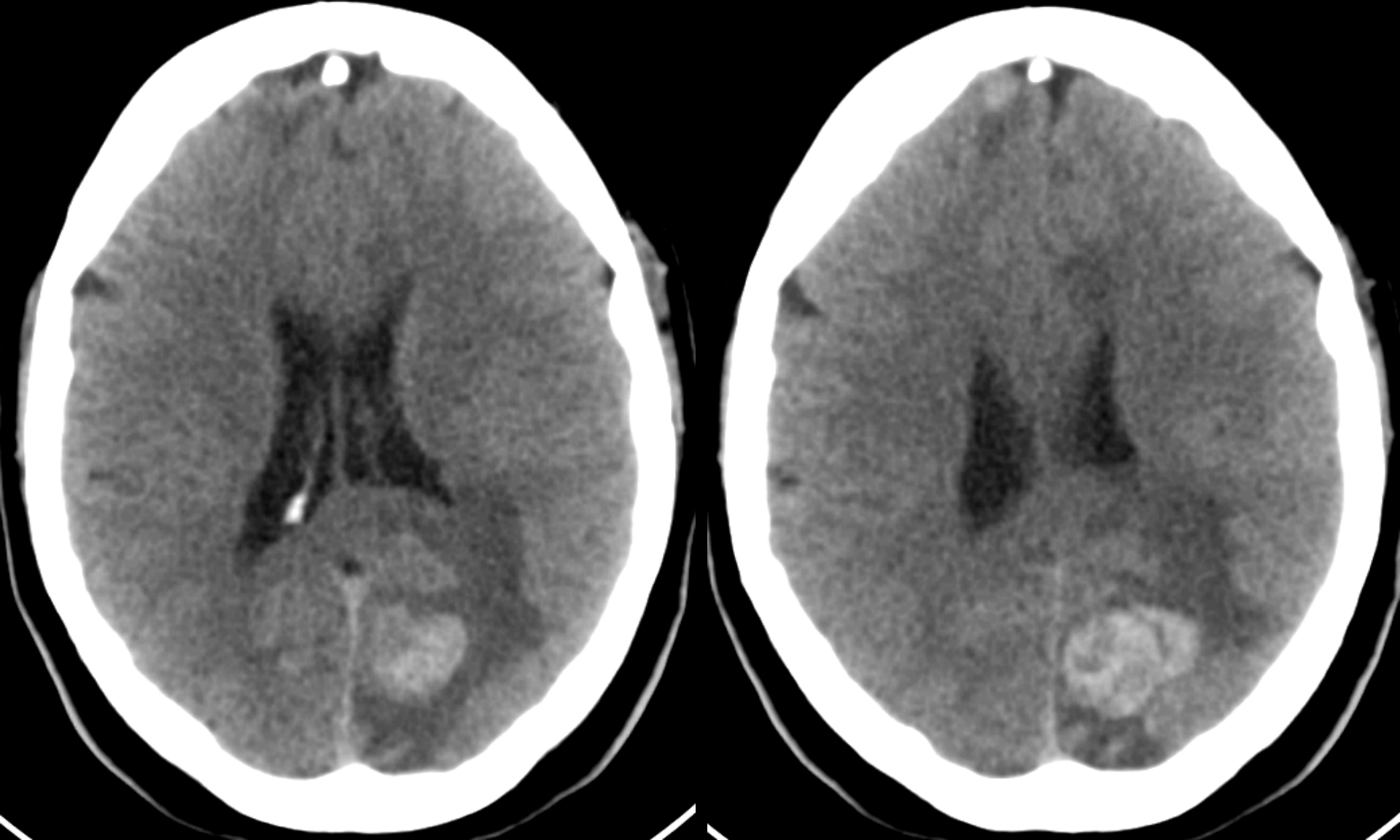


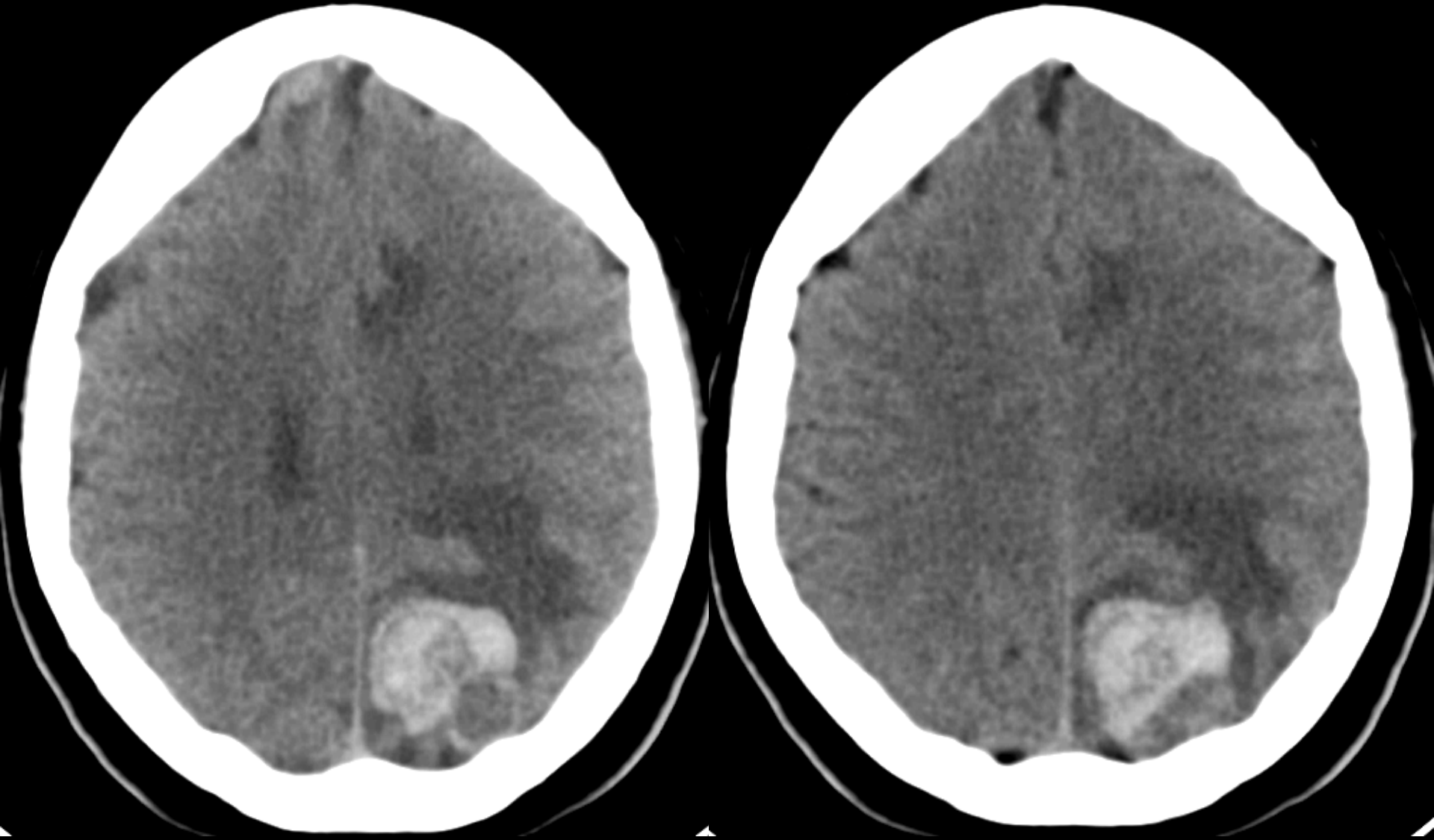
Visual Pathways



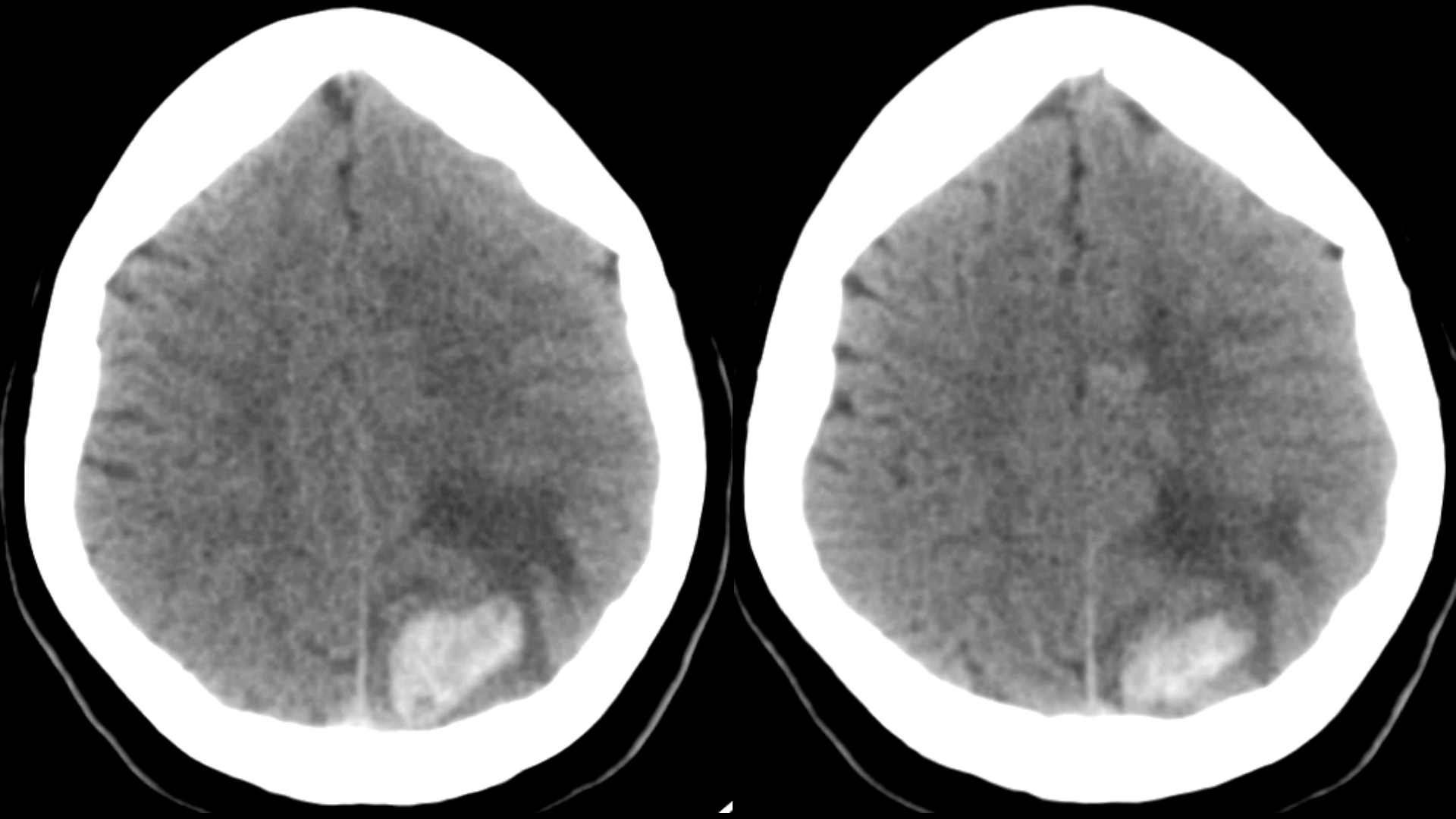




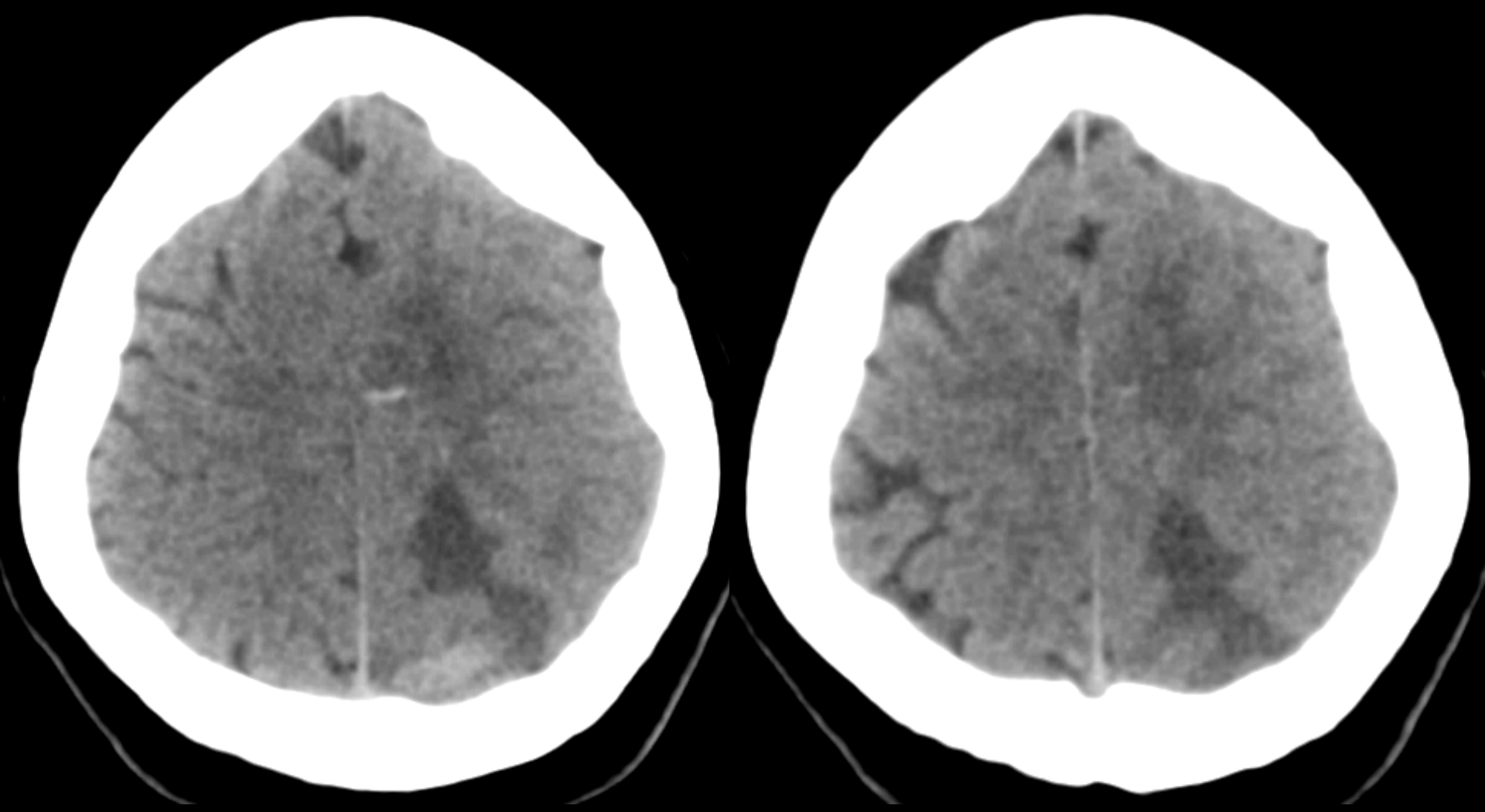
Horizontal CT Scan without Contrast



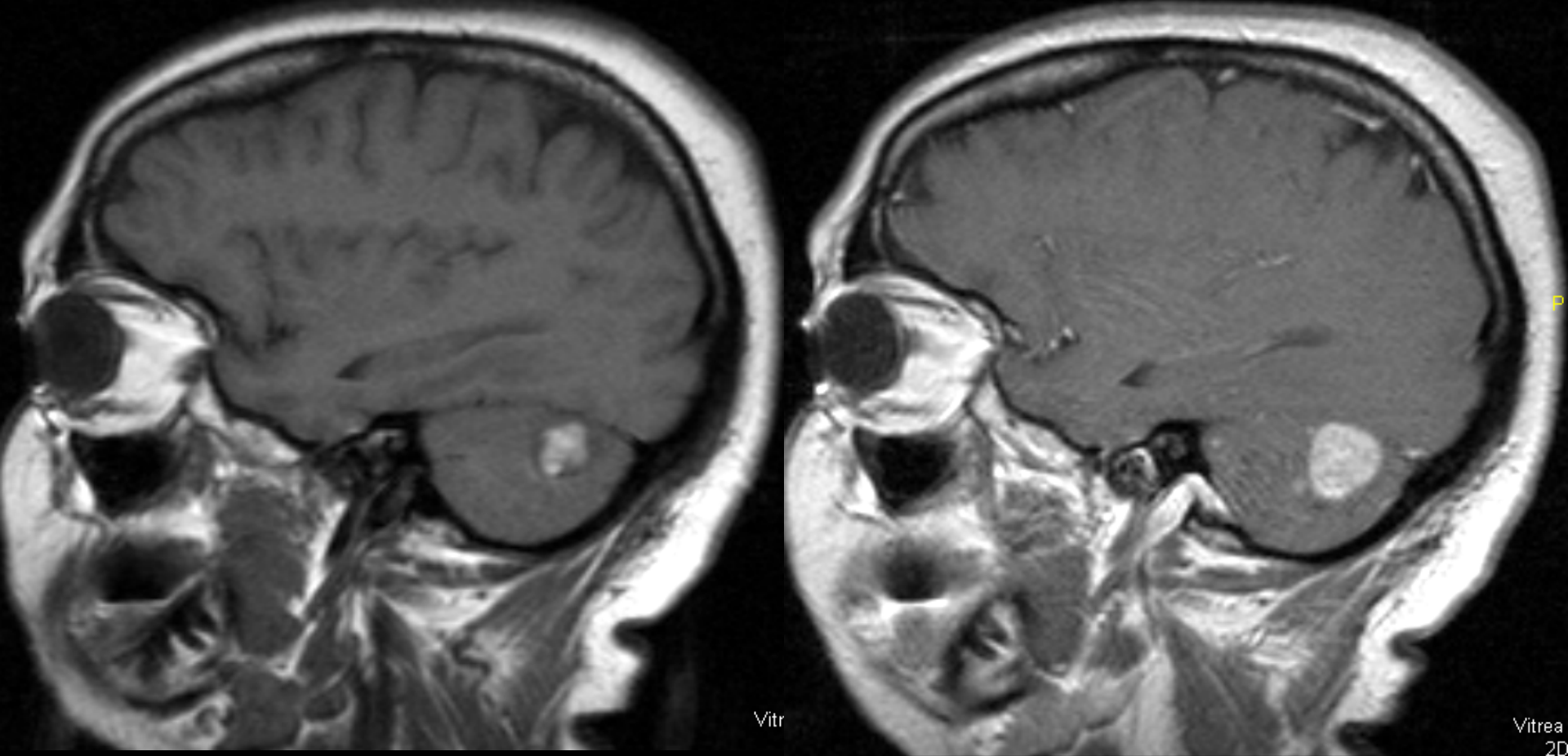
Horizontal CT Scan without Contrast



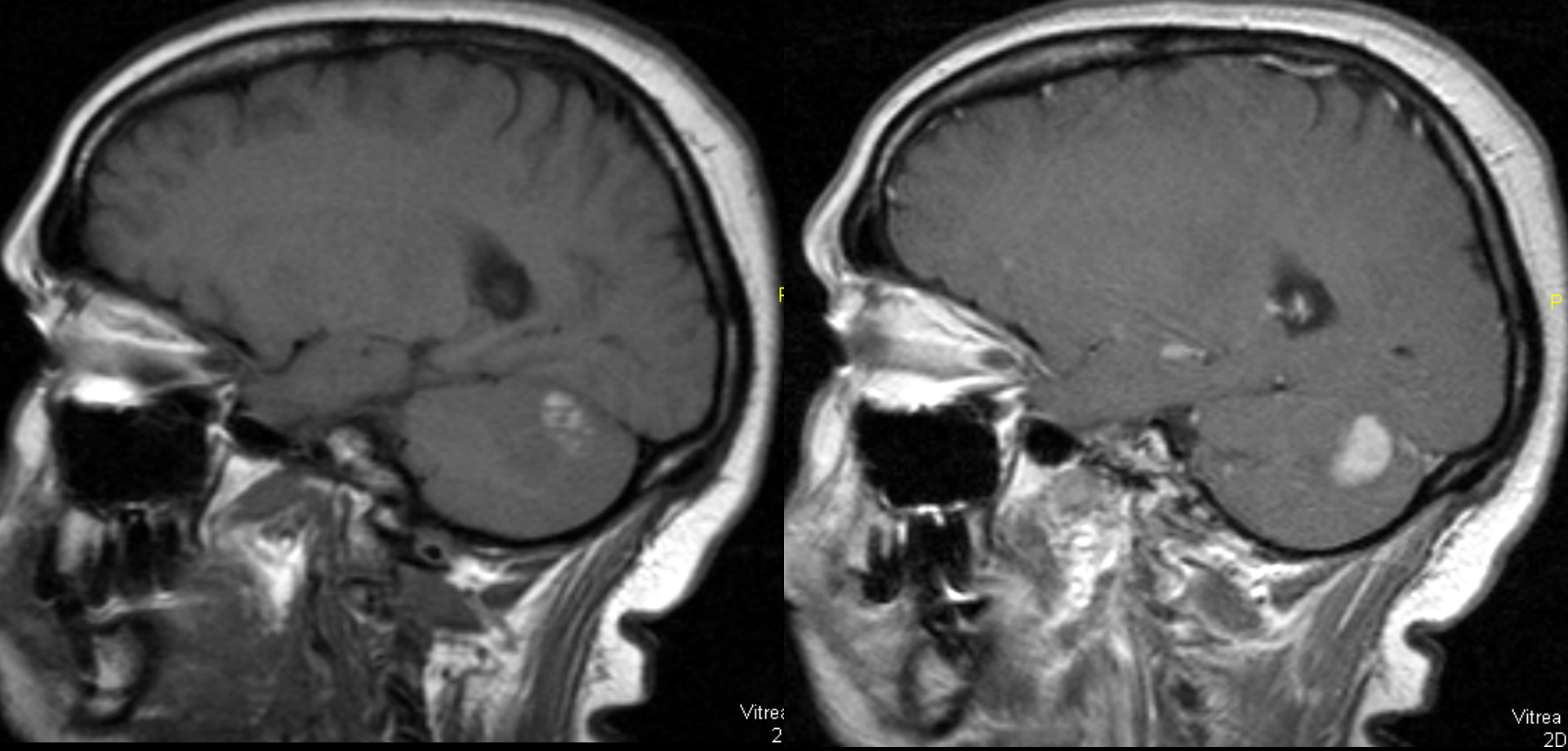
Horizontal CT Scan without Contrast



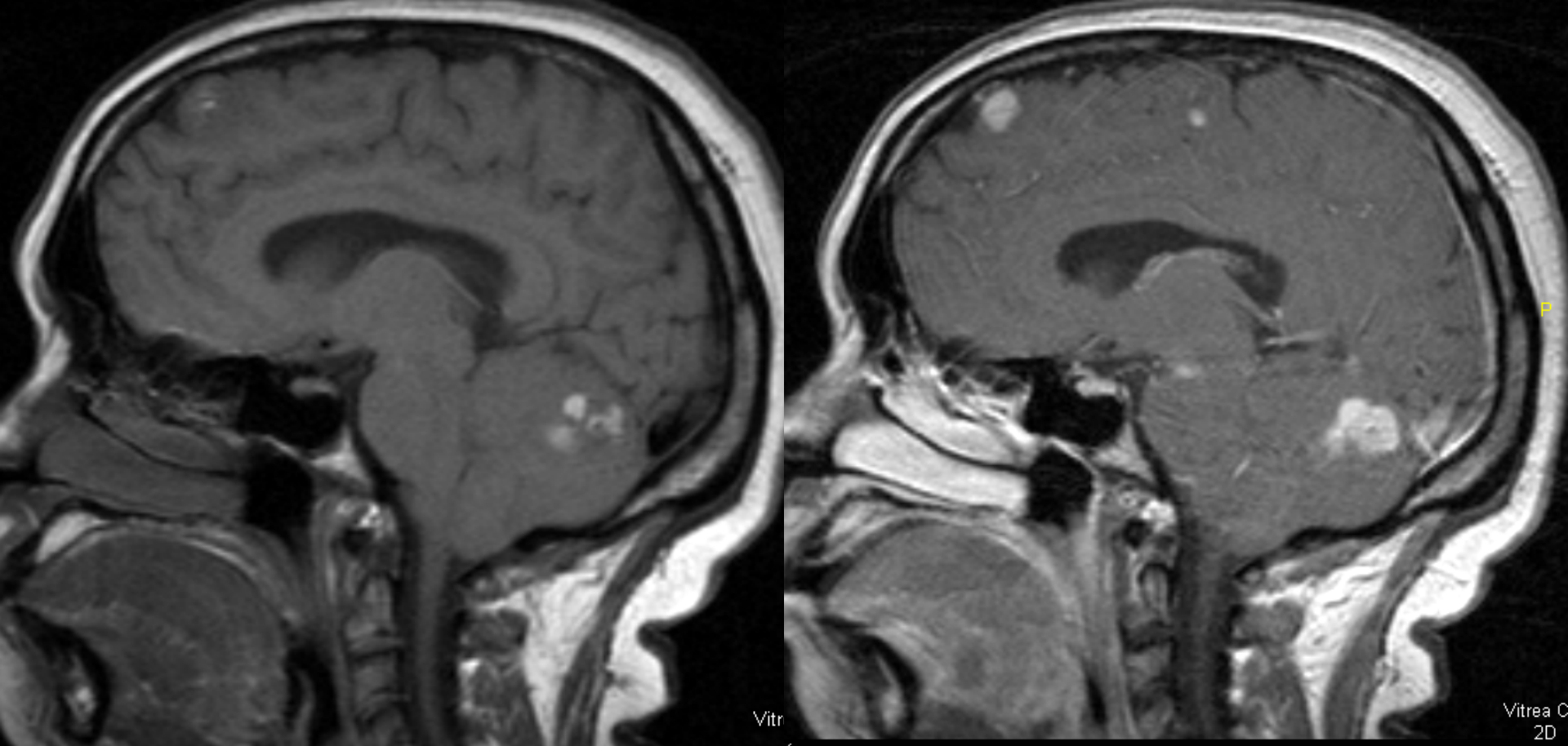
Horizontal CT Scan without Contrast



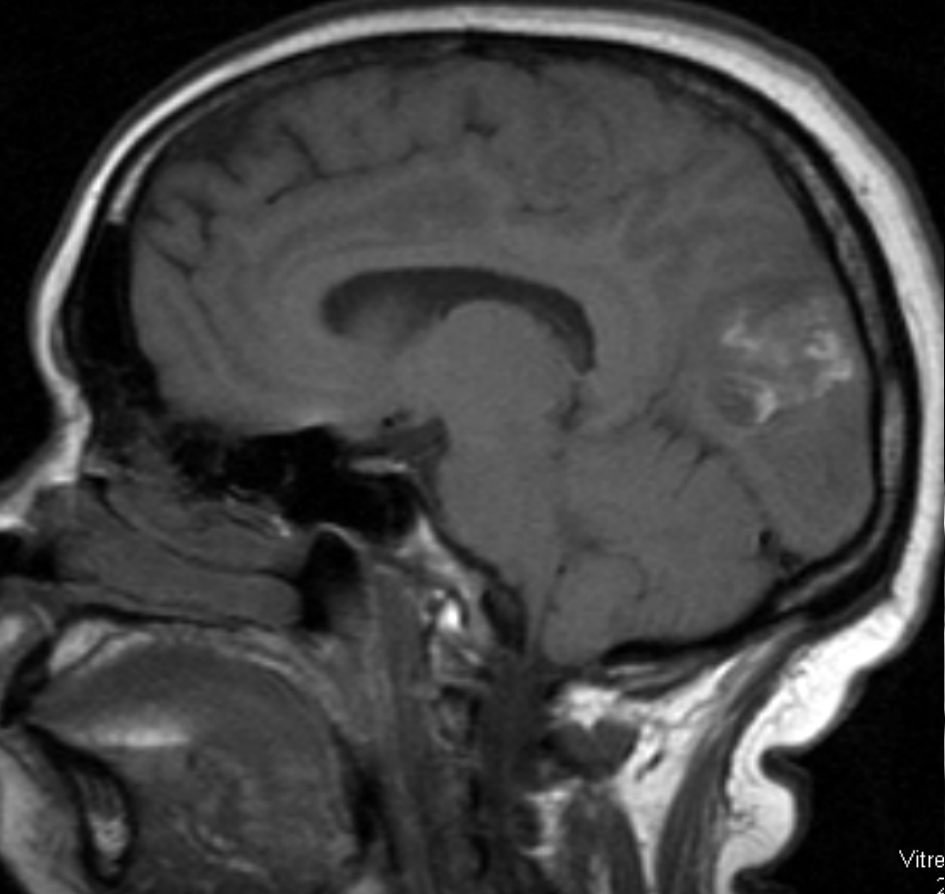
Sagittal T1W MRI Scan wo (left) and with (right) Gd



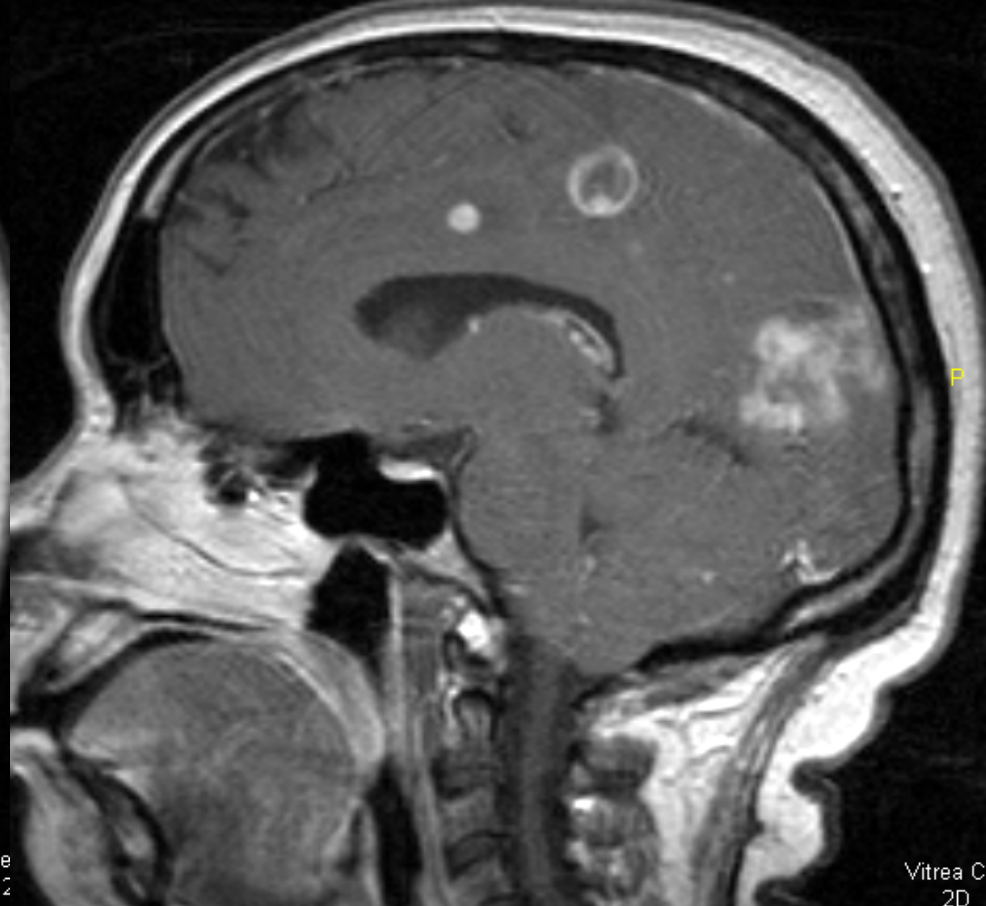
Sagittal T1W MRI Scan wo (left) and with (right) Gd



Sagittal T1W MRI Scan wo (left) and with (right) Gd

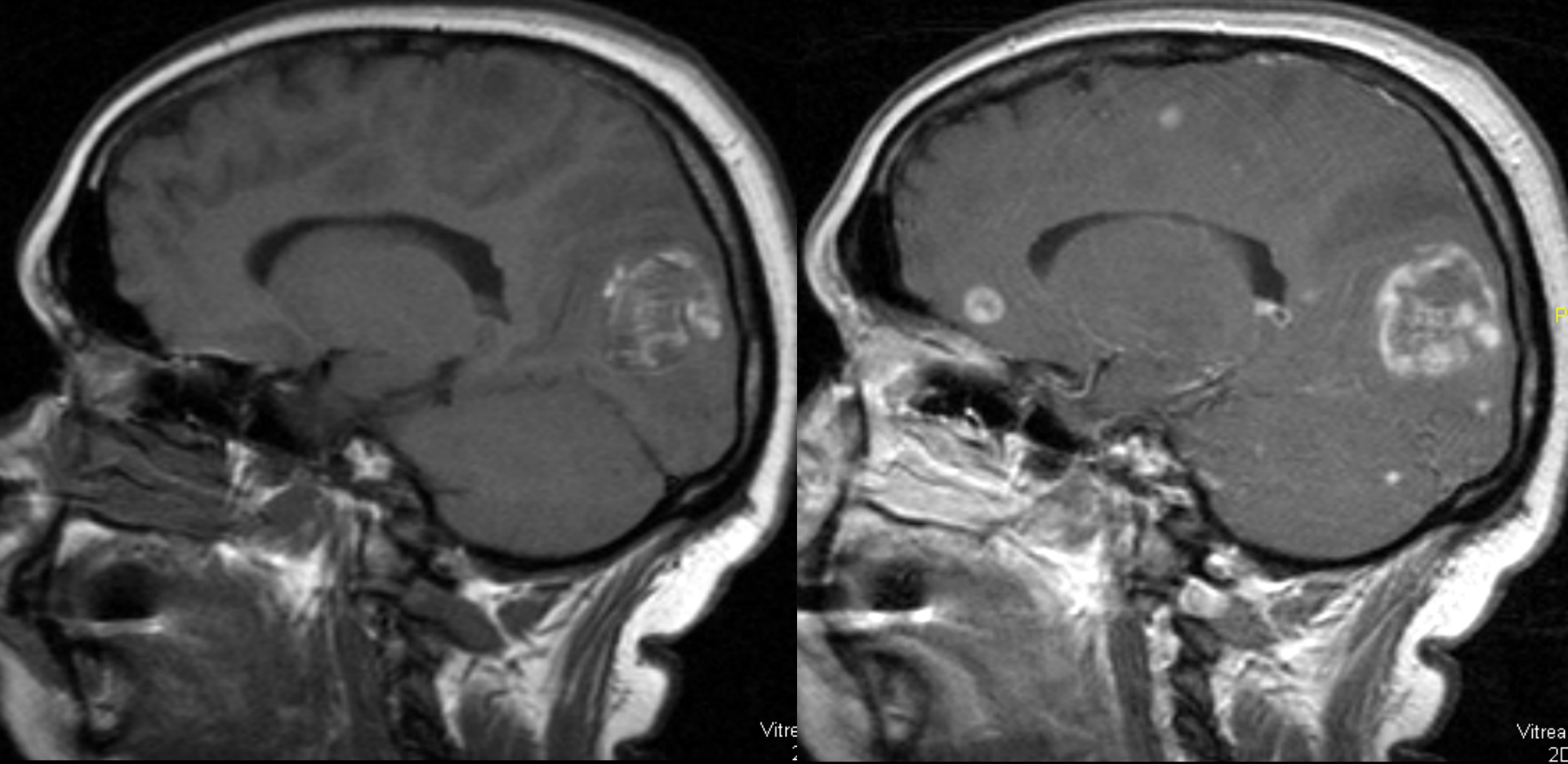


Vitre
2

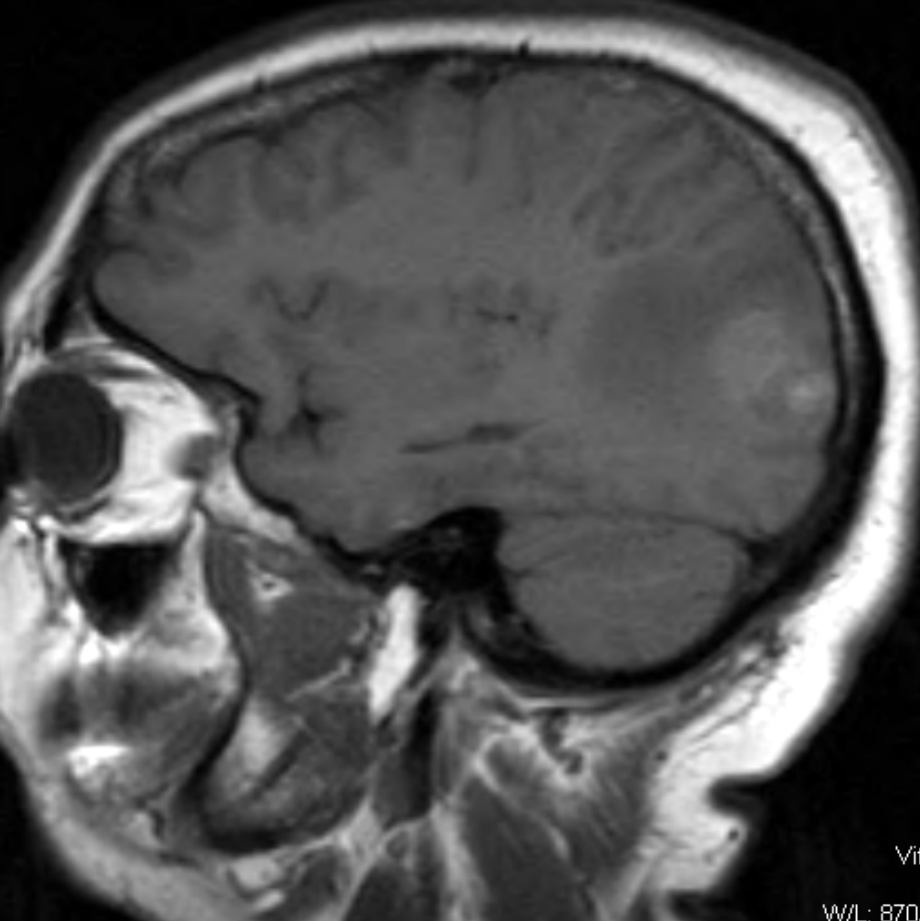


Vitre C
2D

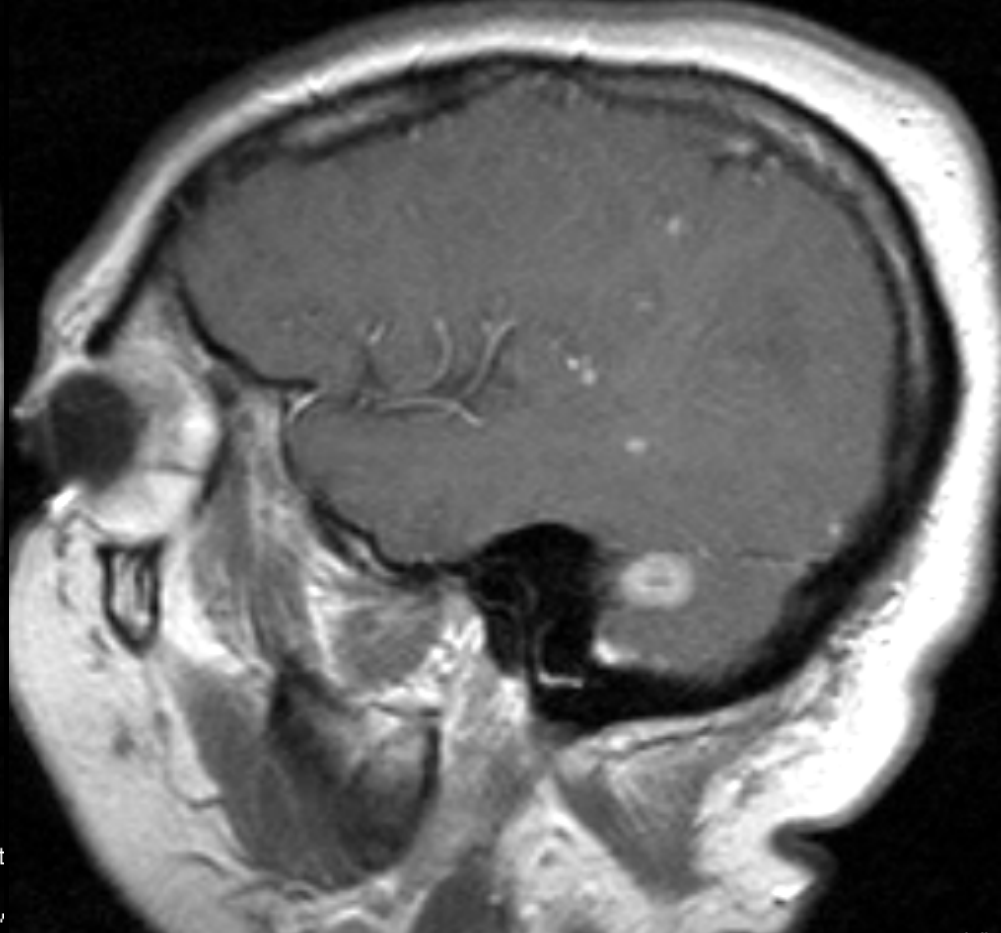
Sagittal T1W MRI Scan wo (left) and with (right) Gd



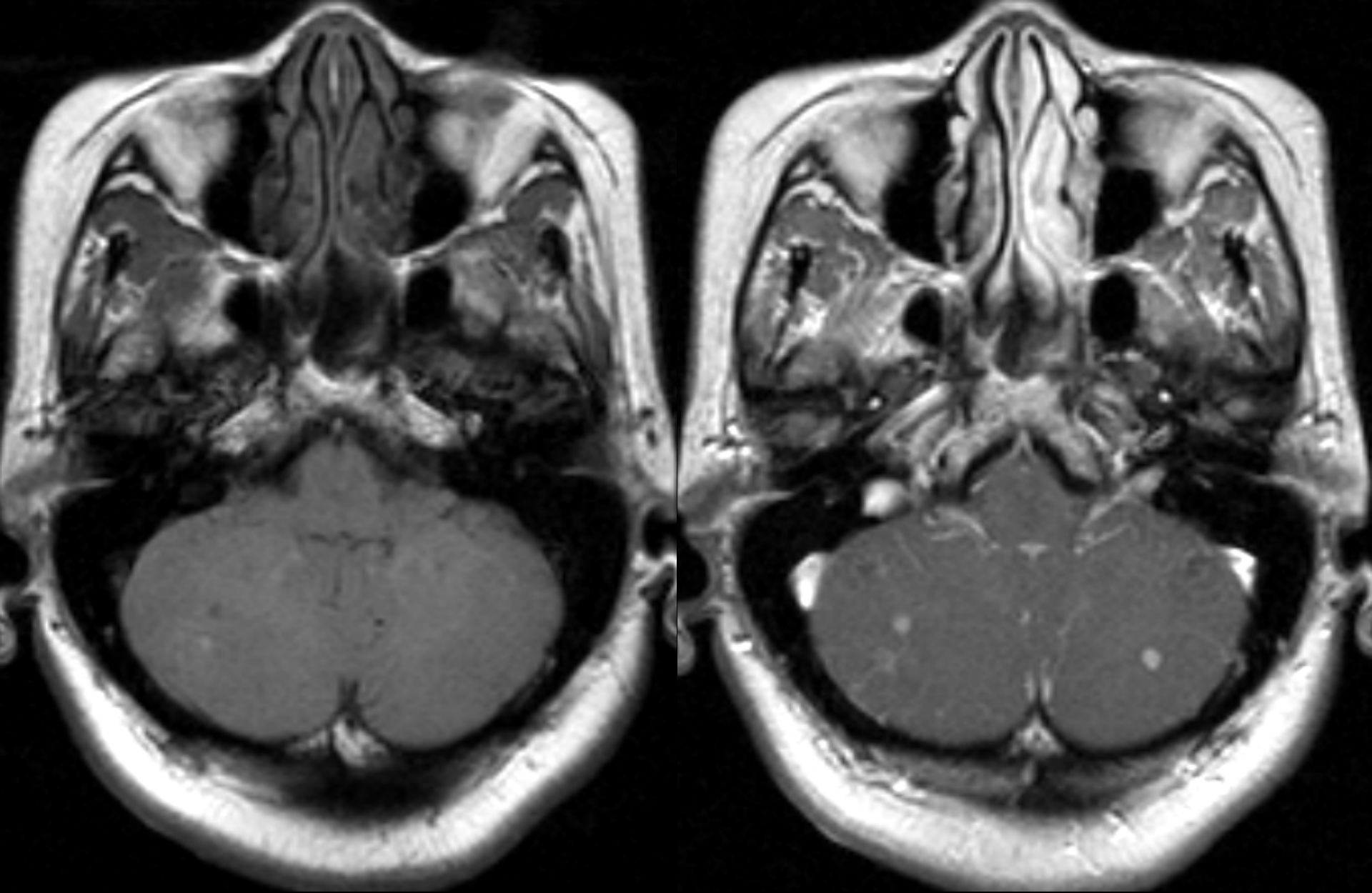
Sagittal T1W MRI Scan wo (left) and with (right) Gd



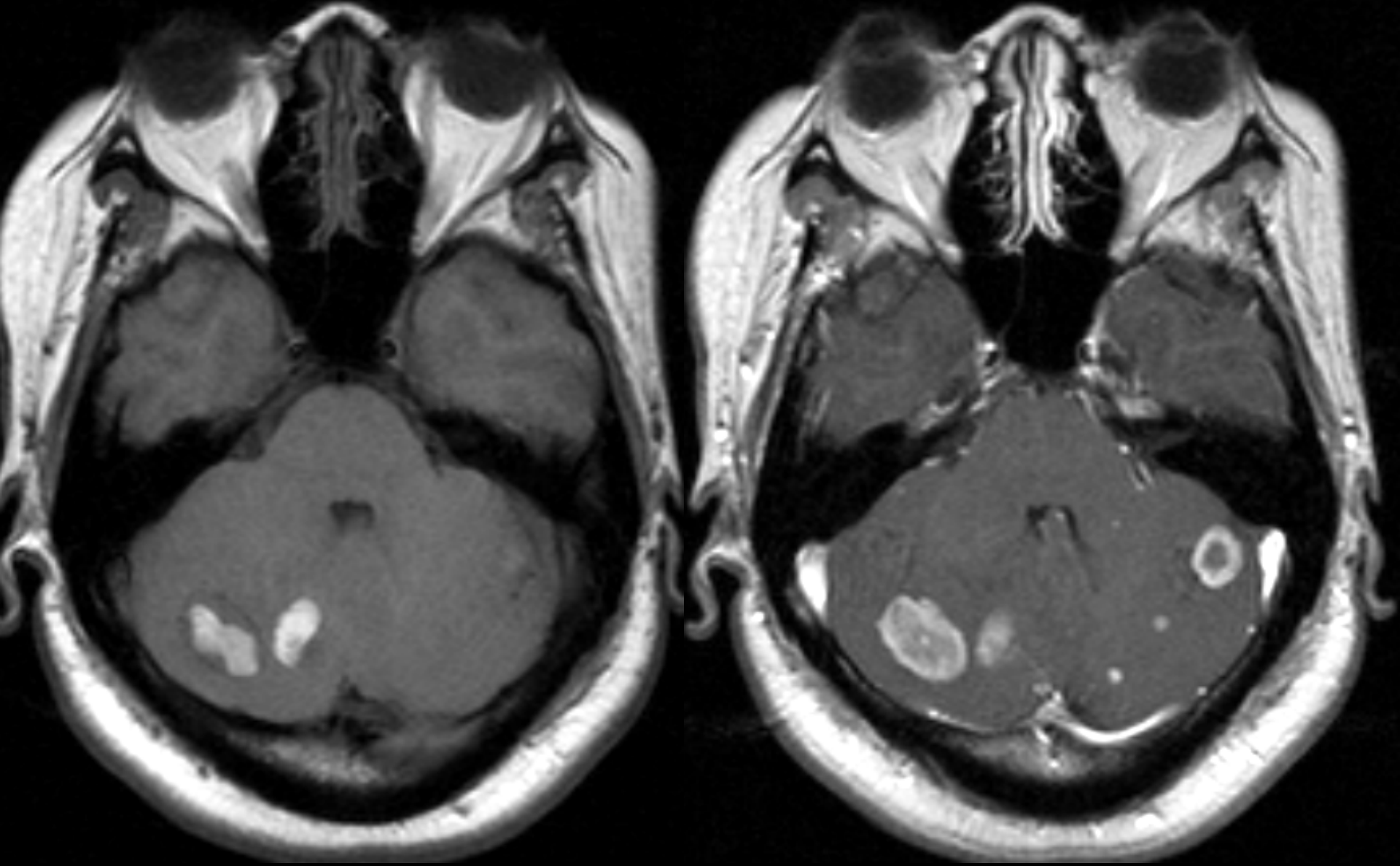
Vit
W/L: 870,



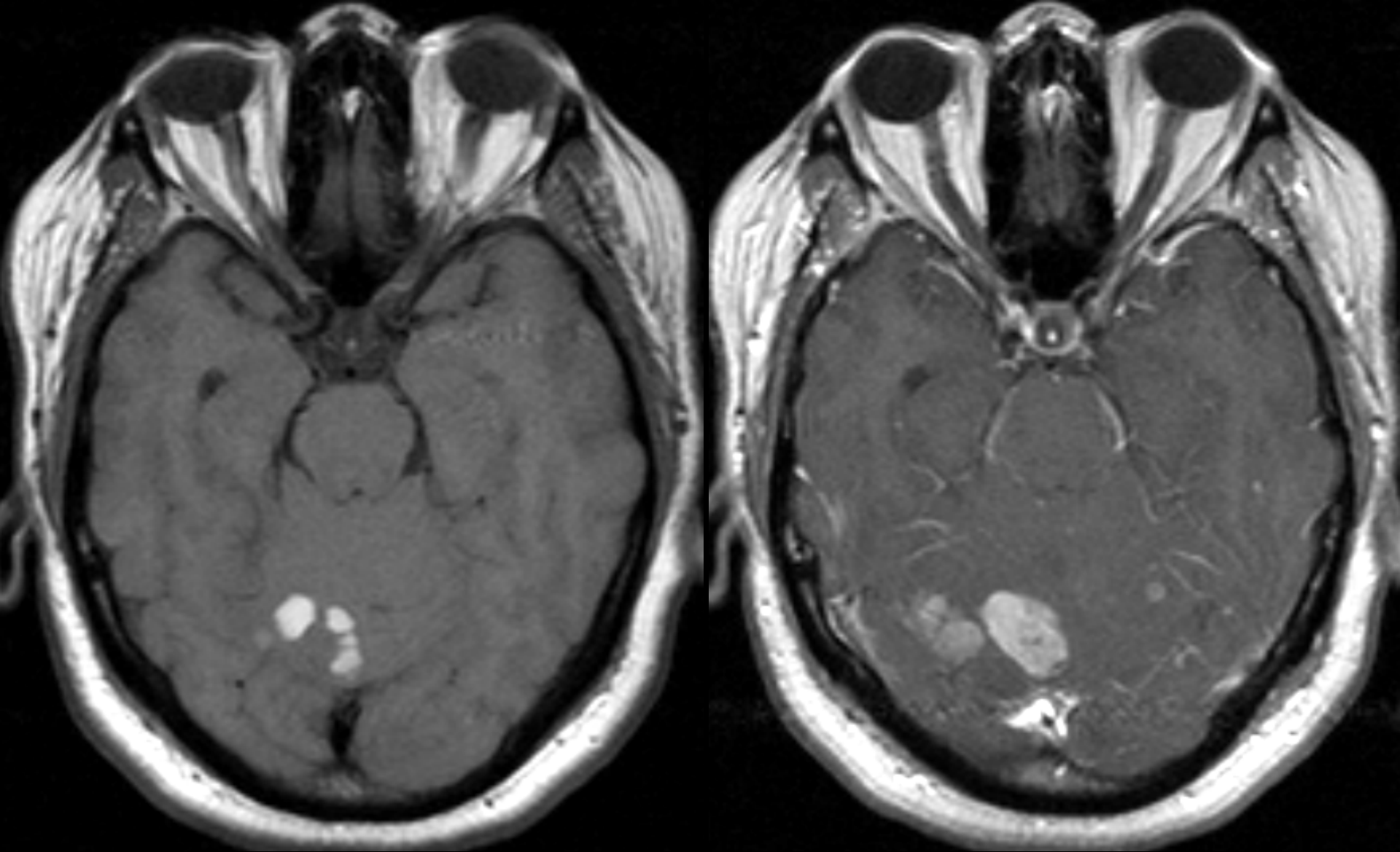
Sagittal T1W MRI Scan wo (left) and with (right) Gd



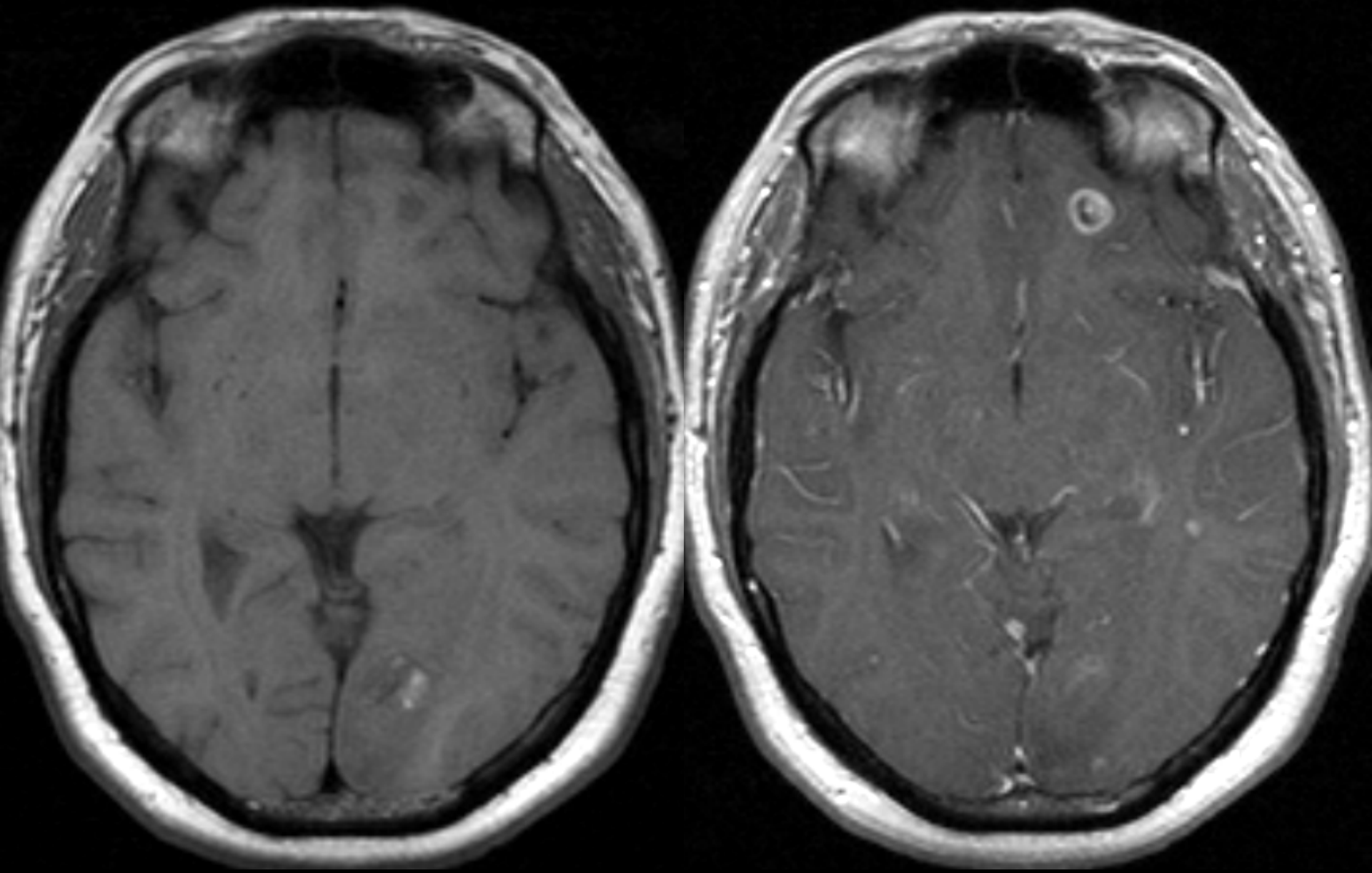
Horizontal T1W MRI Scan wo (left) and with (right) Gd



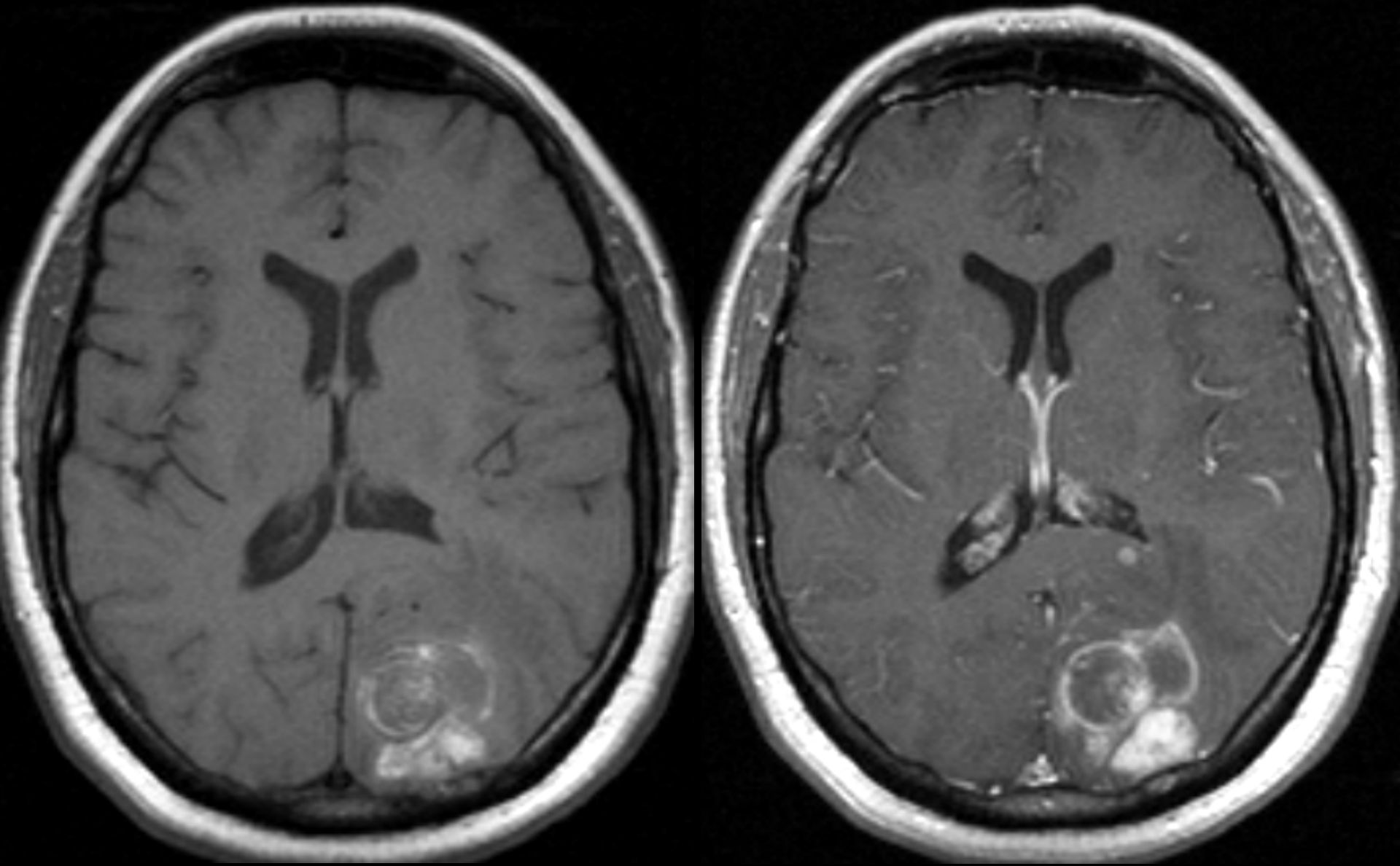
Horizontal T1W MRI Scan wo (left) and with (right) Gd



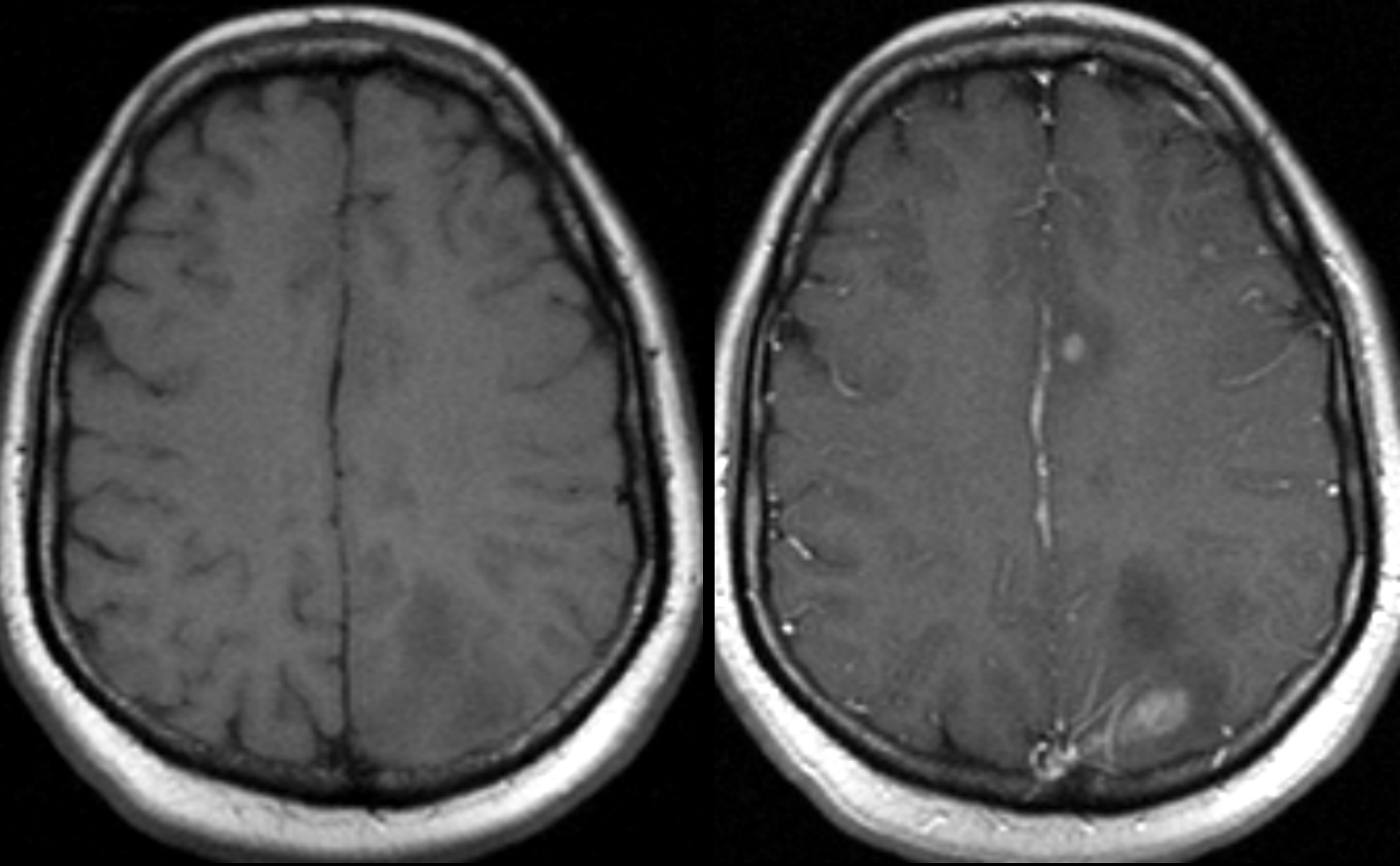
Horizontal T1W MRI Scan wo (left) and with (right) Gd



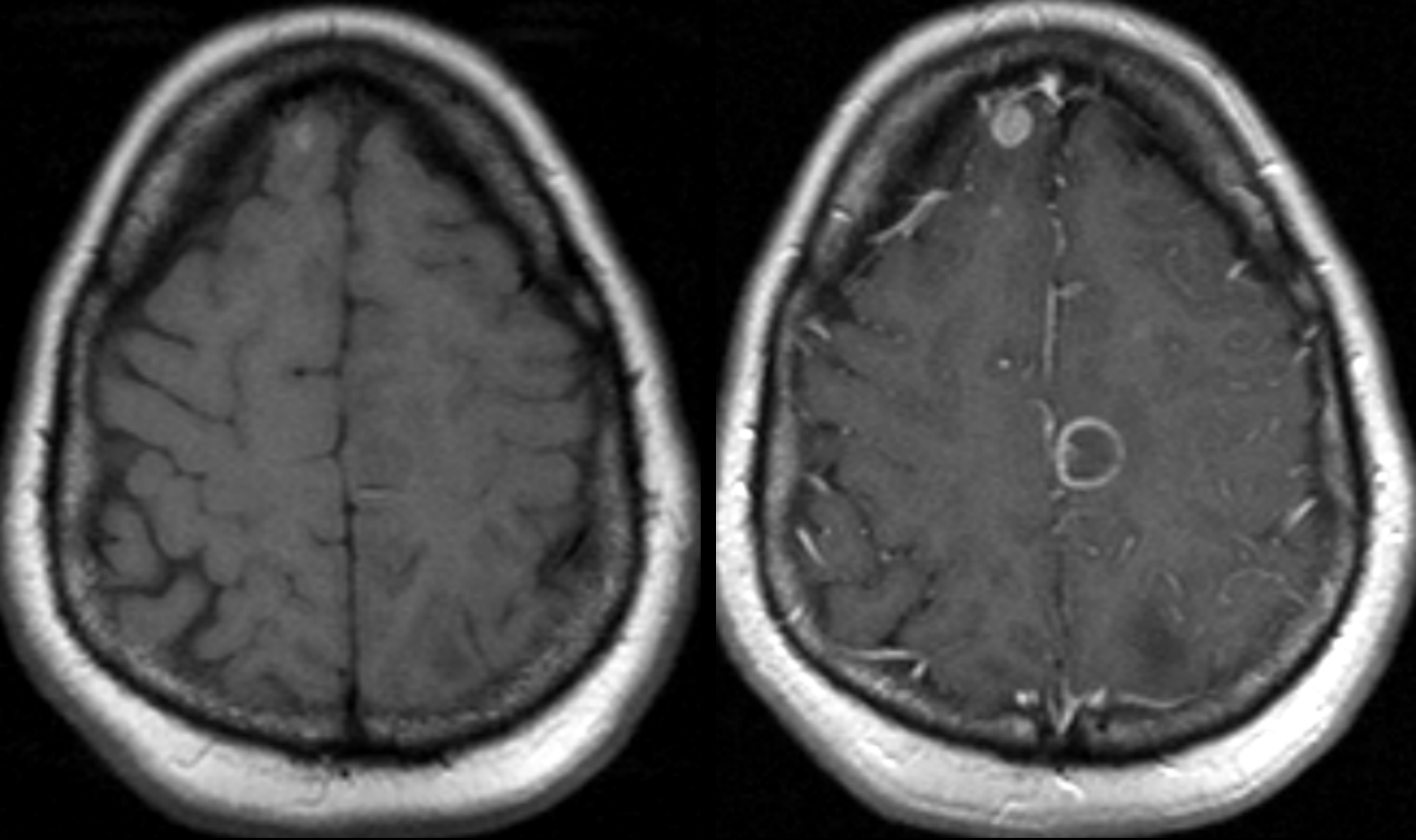
Horizontal T1W MRI Scan wo (left) and with (right) Gd



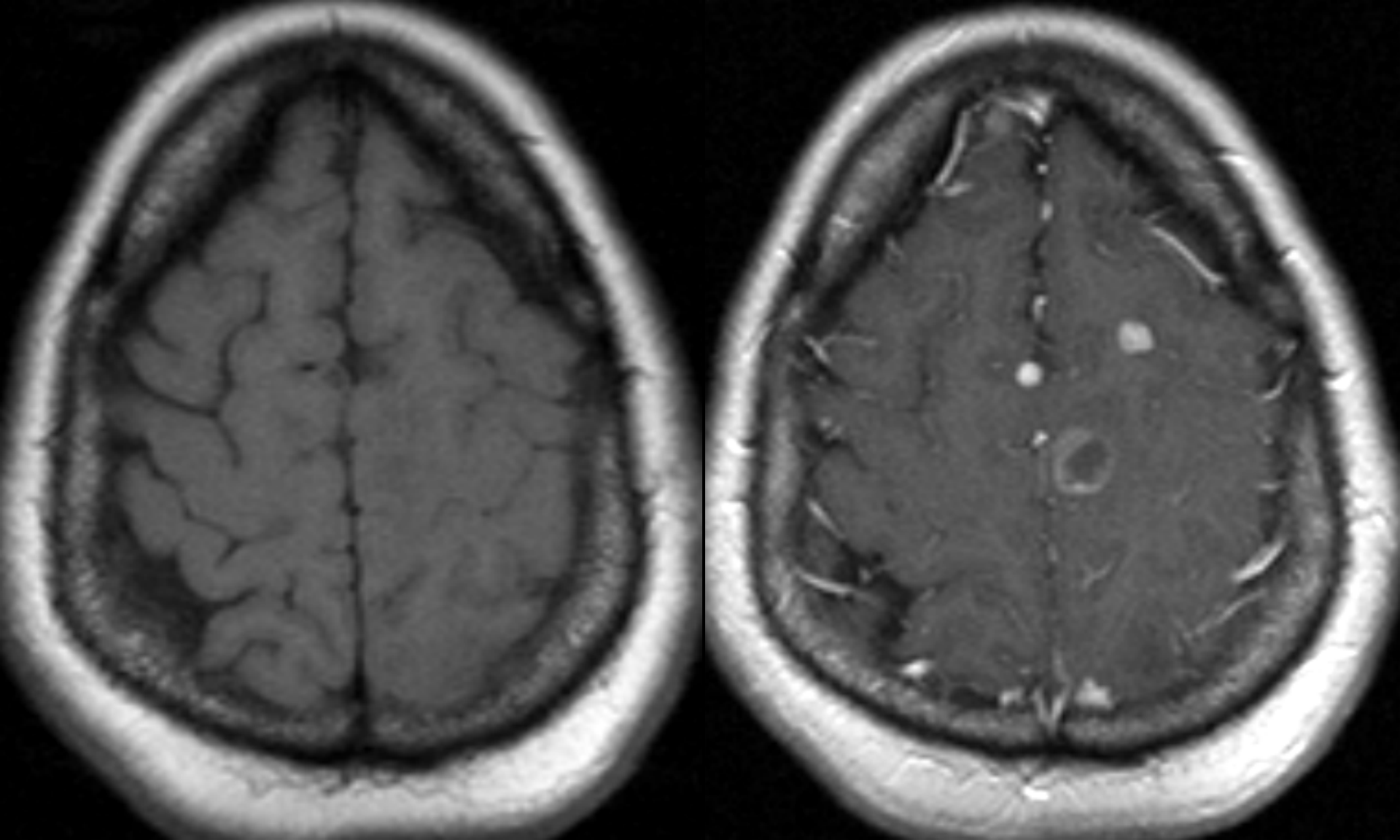
Horizontal T1W MRI Scan wo (left) and with (right) Gd



Horizontal T1W MRI Scan wo (left) and with (right) Gd



Horizontal T1W MRI Scan wo (left) and with (right) Gd



Horizontal T1W MRI Scan wo (left) and with (right) Gd