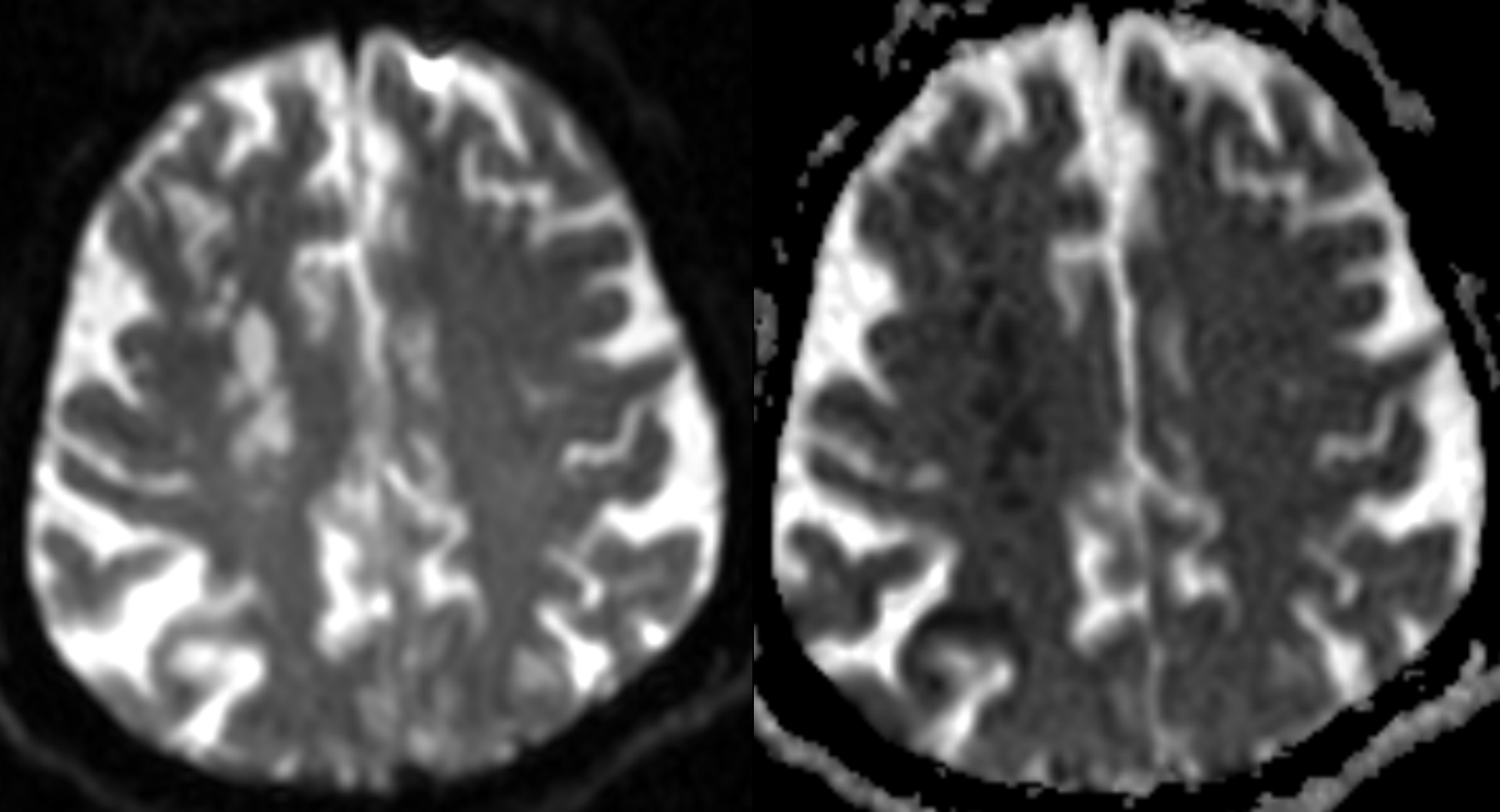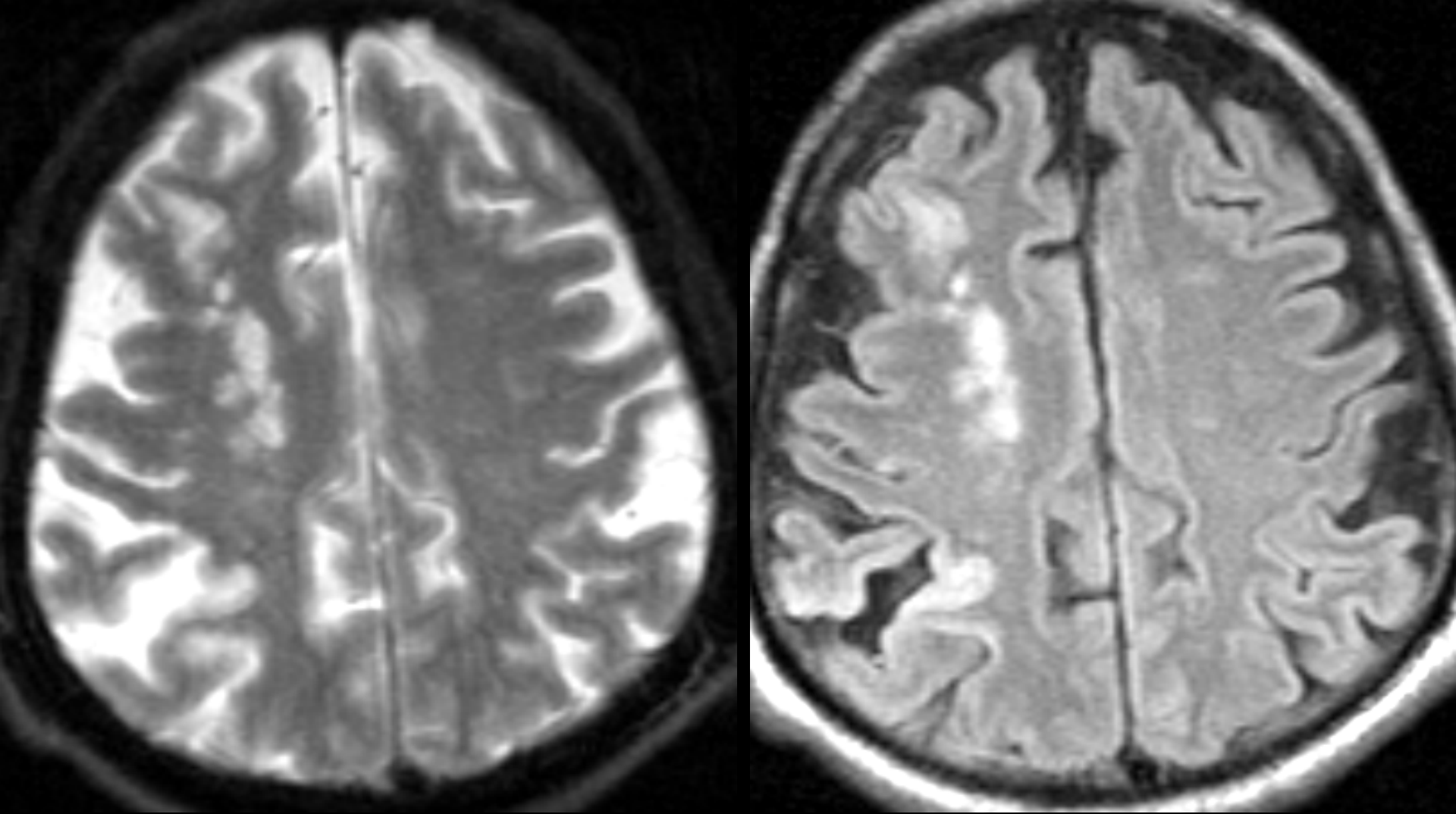


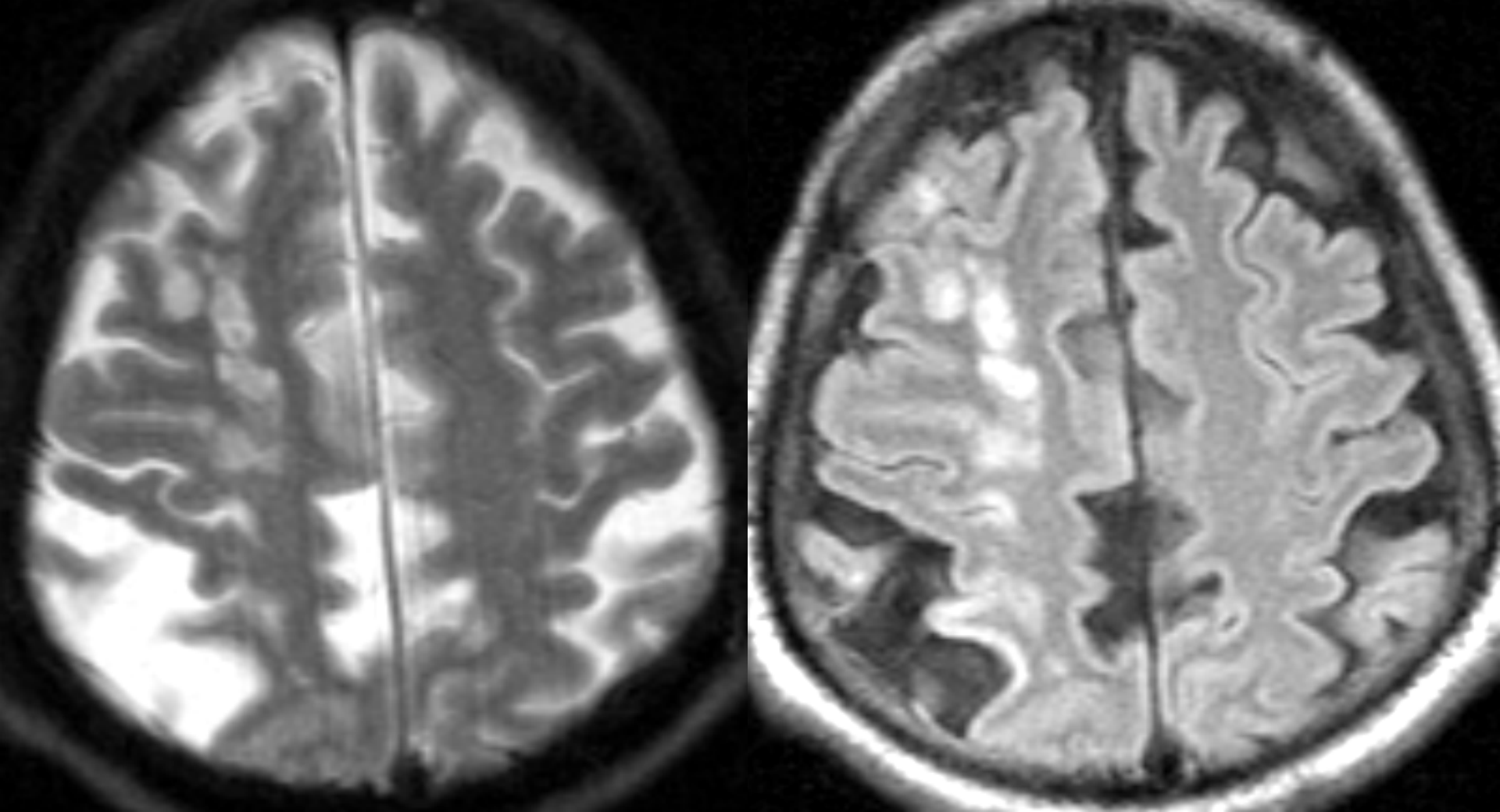
Horizontal DWI [left] & ADC [right] MRI Scan

6/23/12



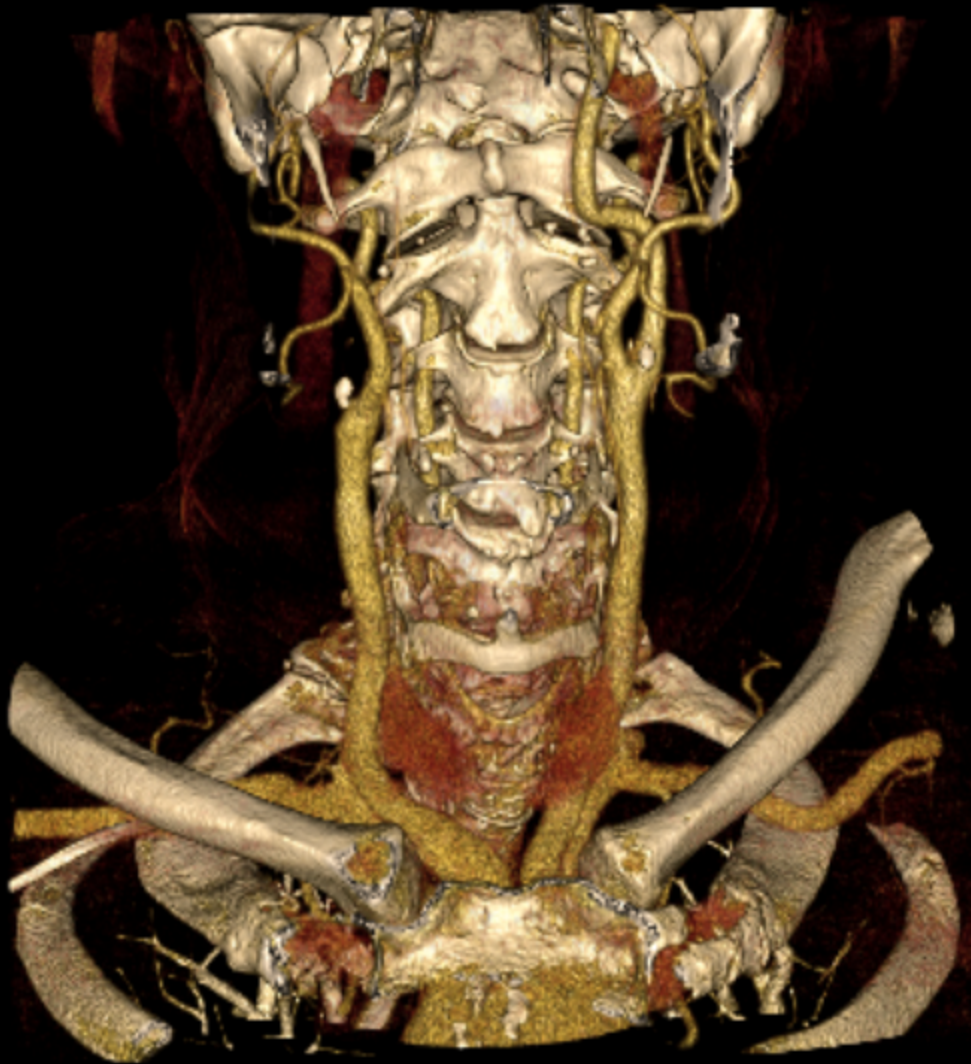Horizontal T2W [left] & FLAIR [right] MRI Scan

6/23/12

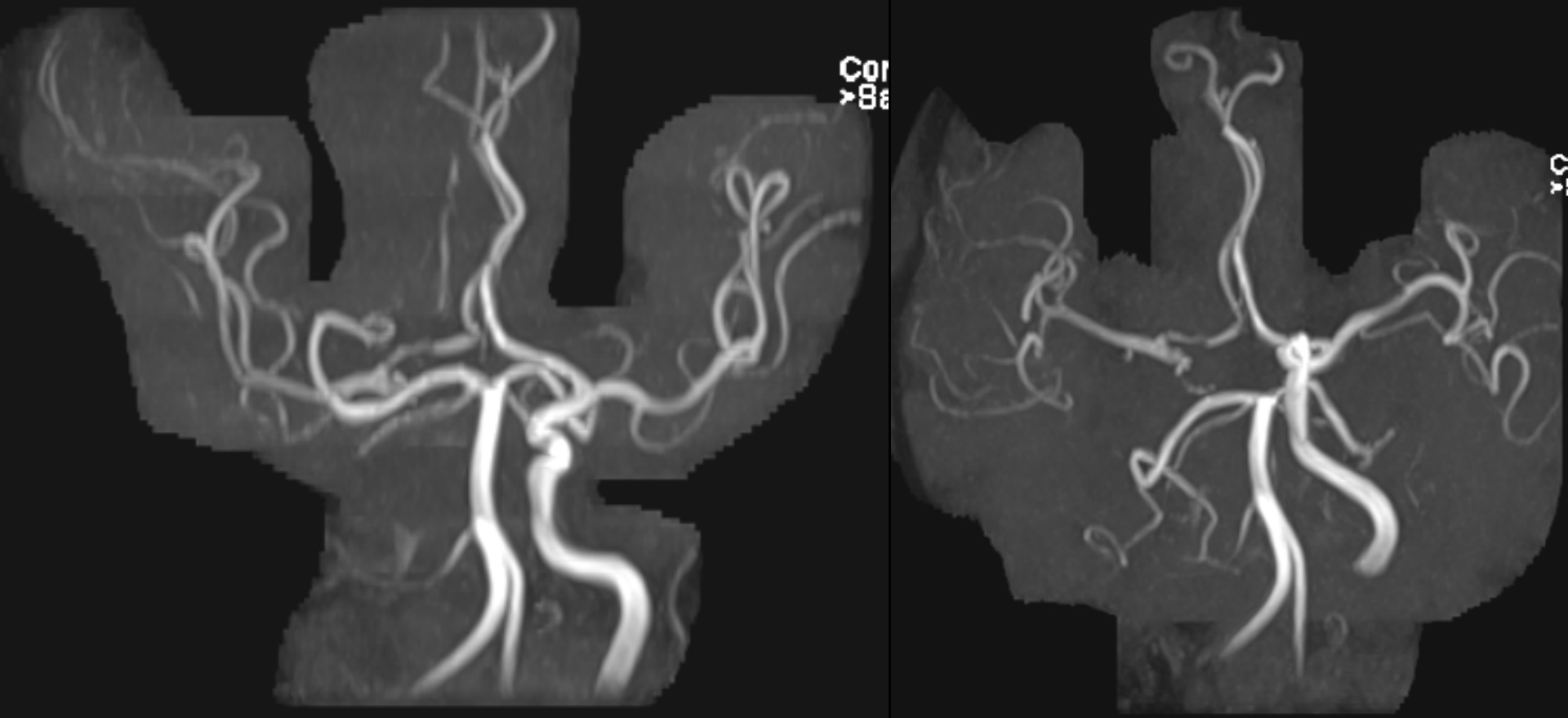

Horizontal T2W [left] & FLAIR [right] MRI Scan

6/23/12

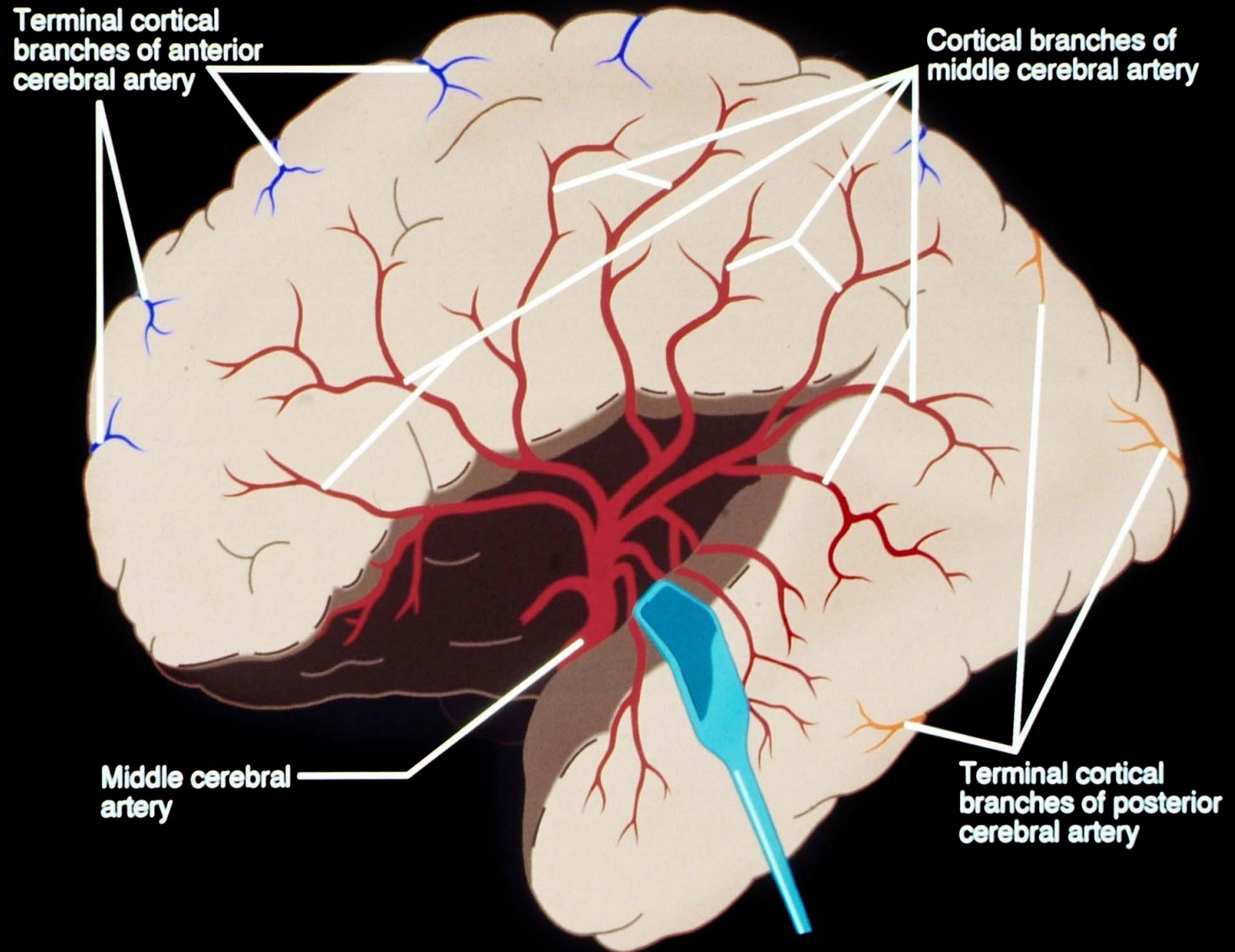


CT Angiogram – Surface Reconstruction (P-A View)

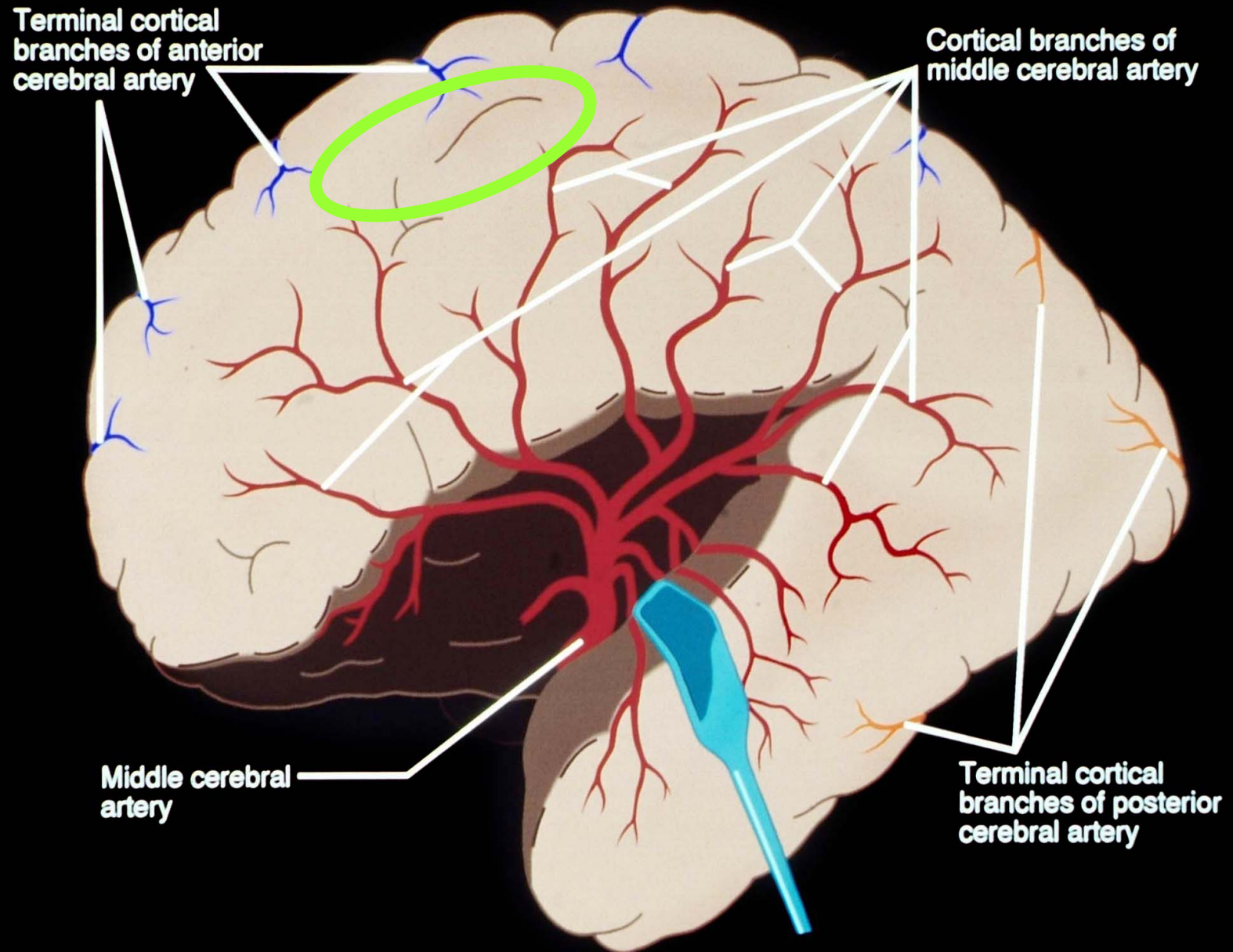


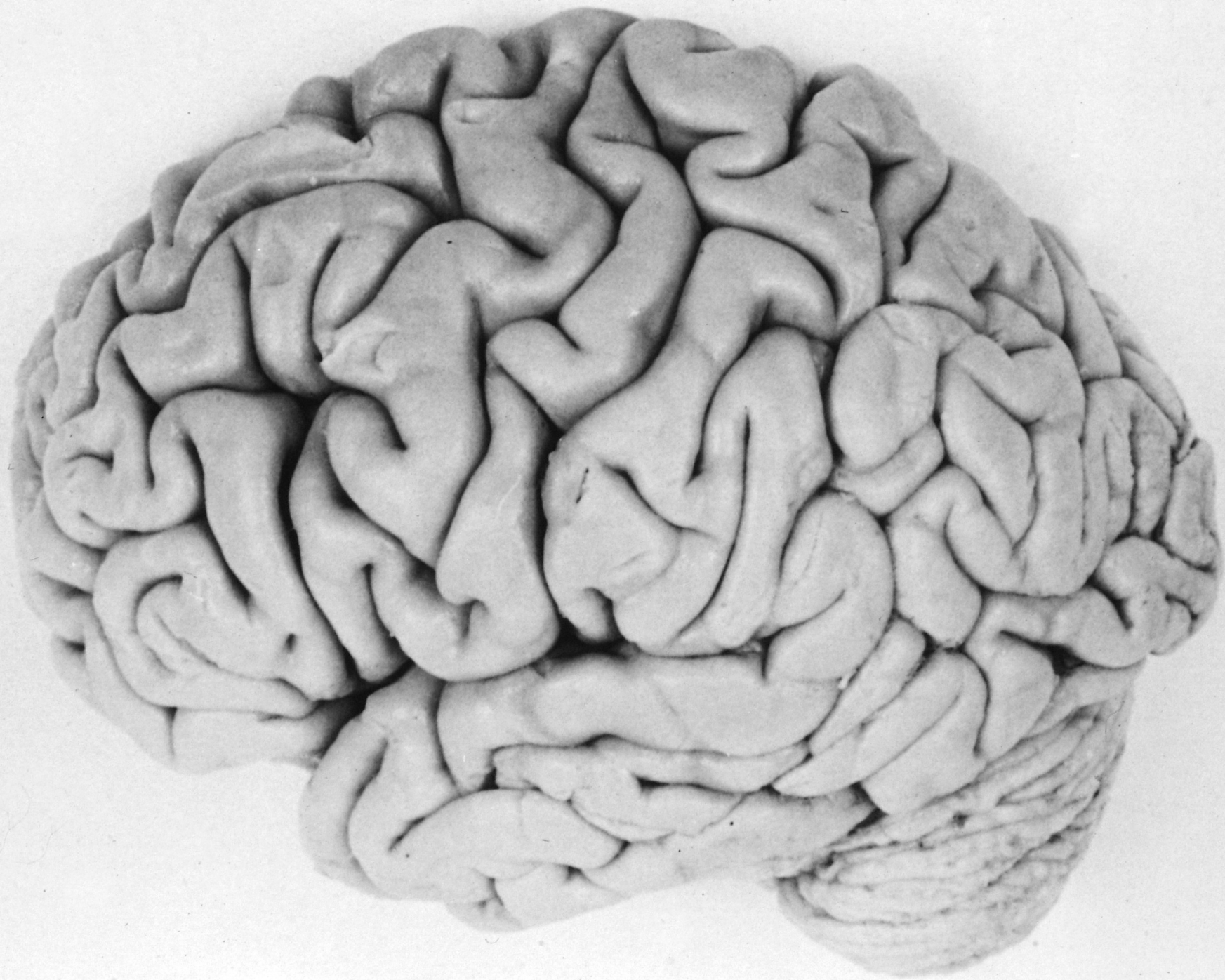MR Angiogram – P-A [left] & angled P-A [right] Views

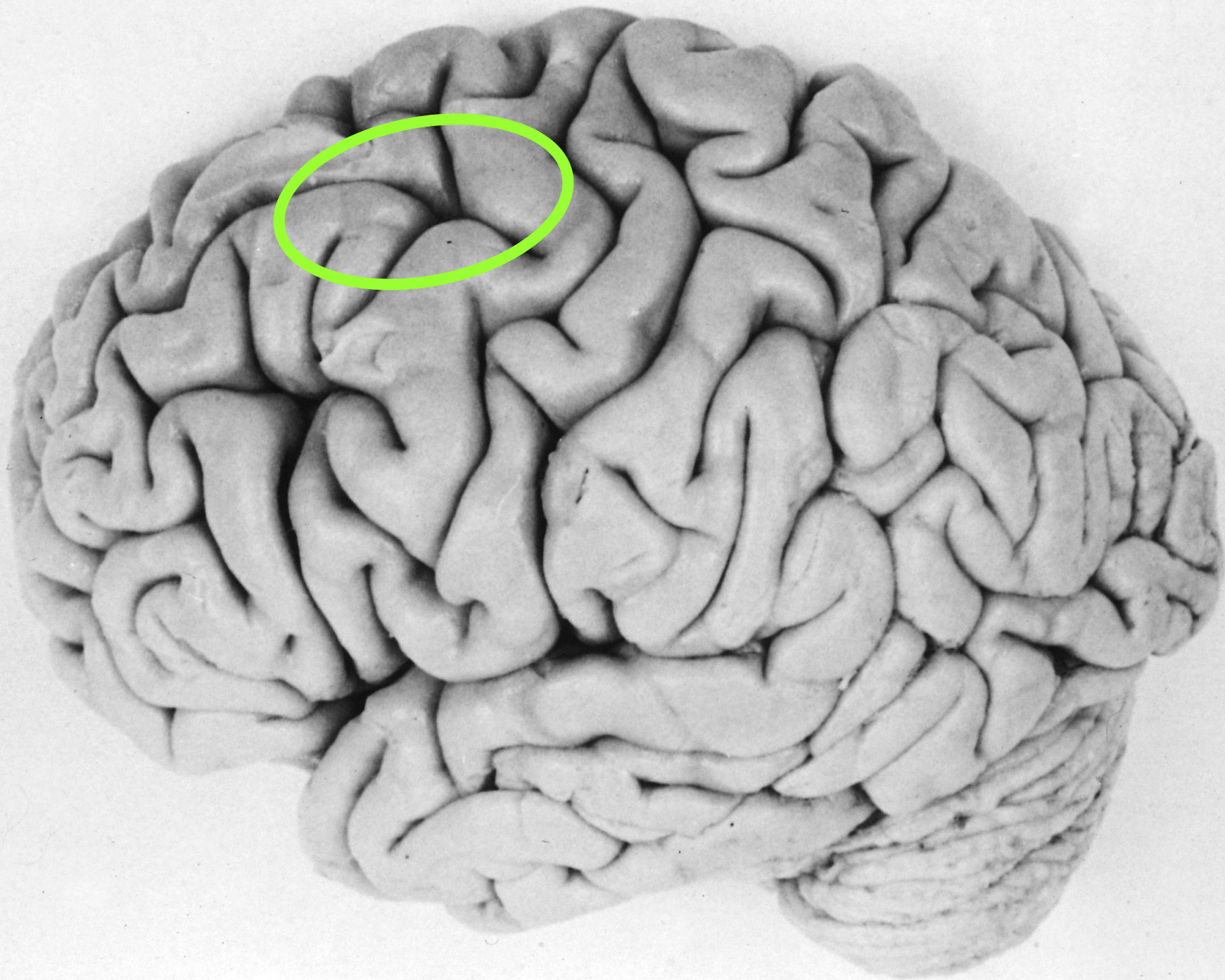Arterial Supply of the Cerebrum: Lateral View



Arterial Supply of the Cerebrum: Lateral View







Motor Homunculus



(from Penfield and Rasmussen, 1950)