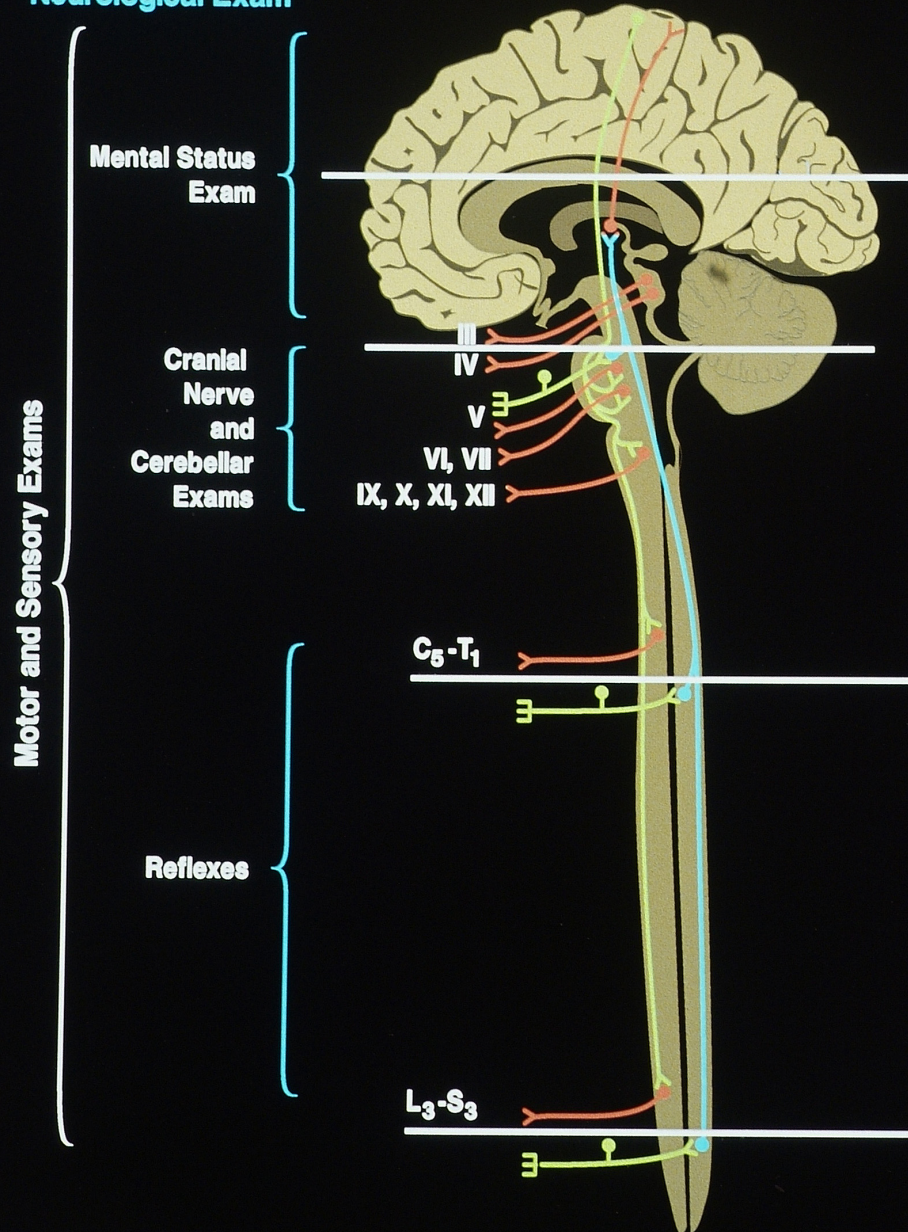
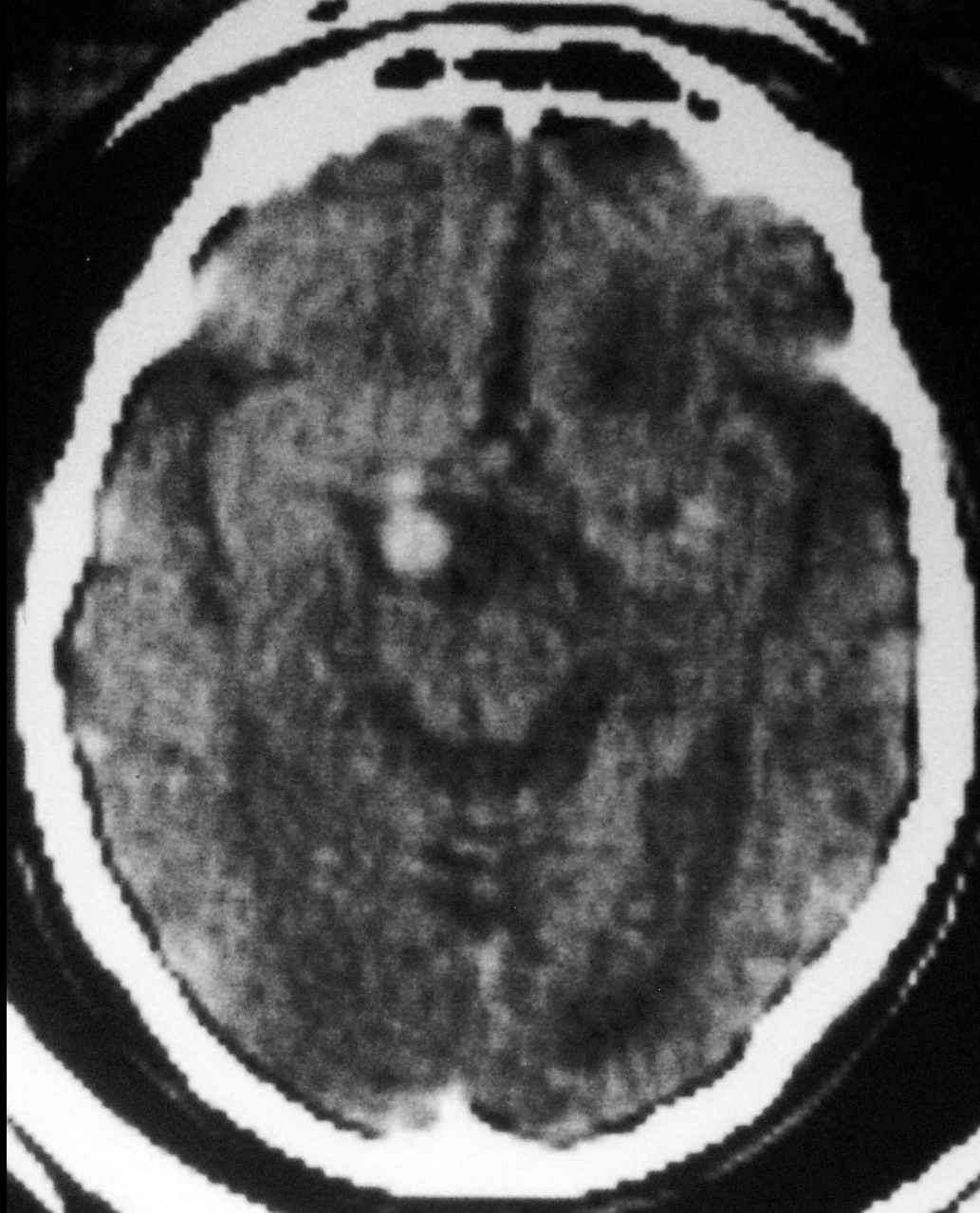

Lesion Localization in Neurologic Disease

Neurological Exam

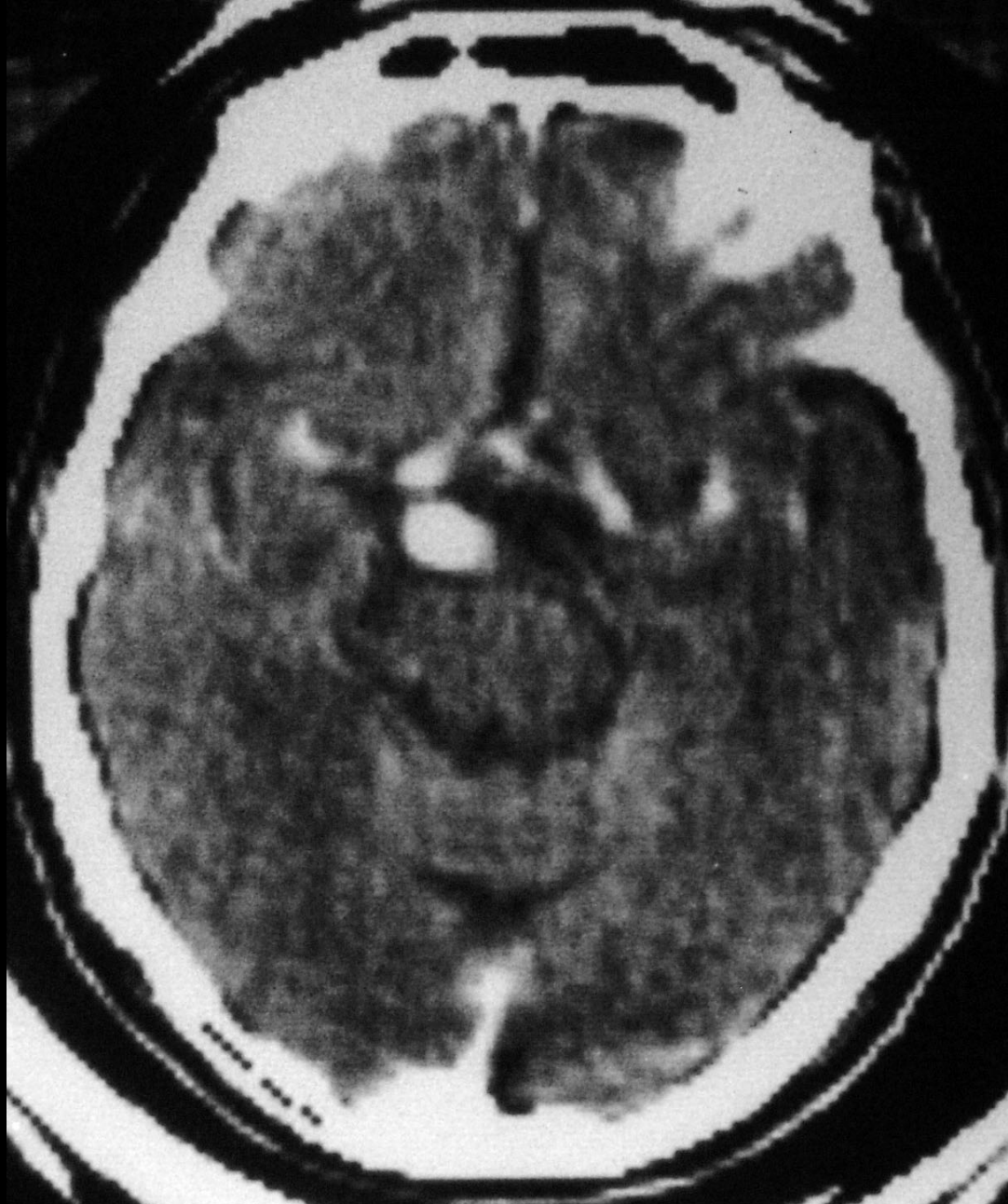




Right

Left

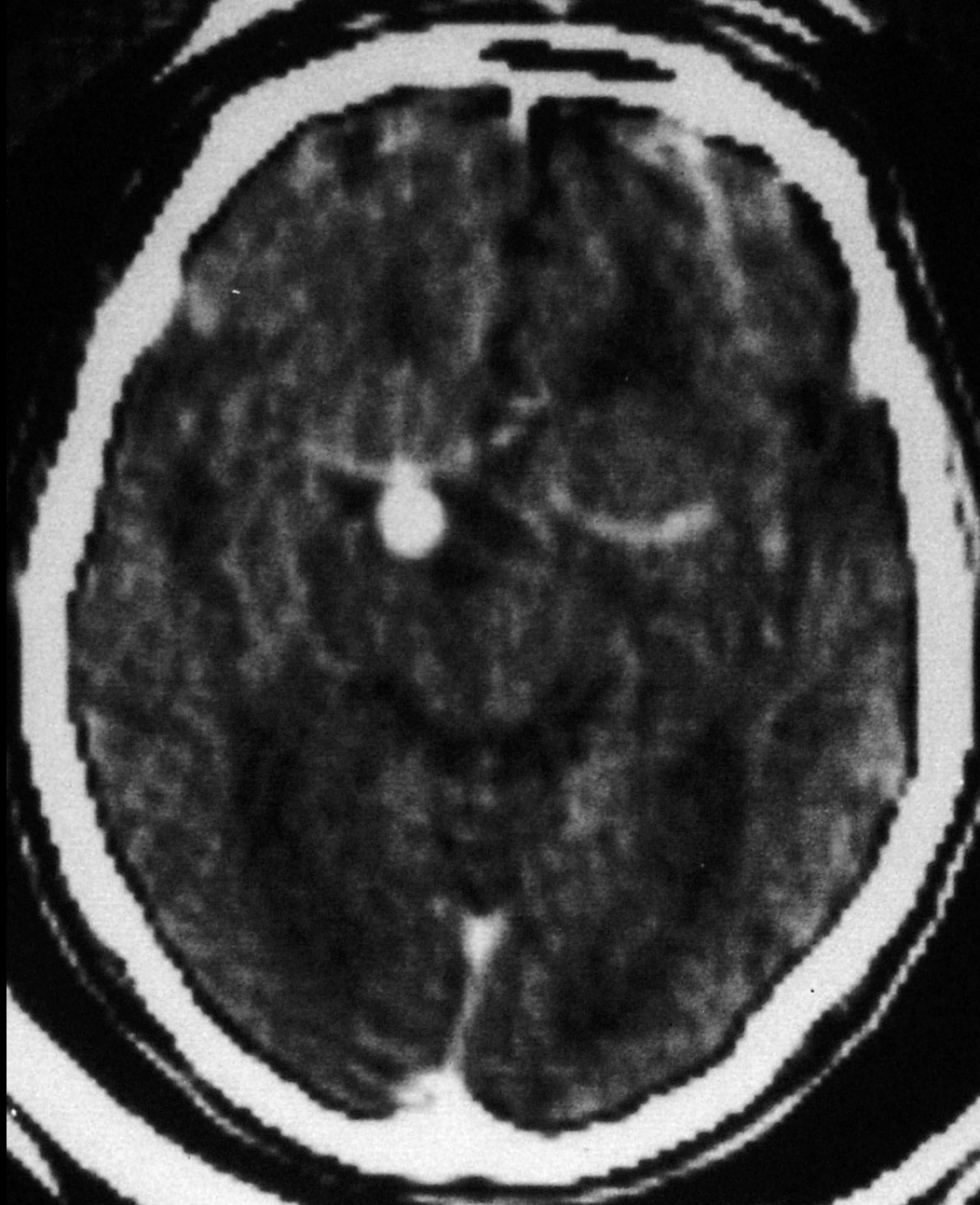
CT Scan without Contrast



Right

Left

CT Scan with Contrast



Right

Left

CT Scan with Contrast





