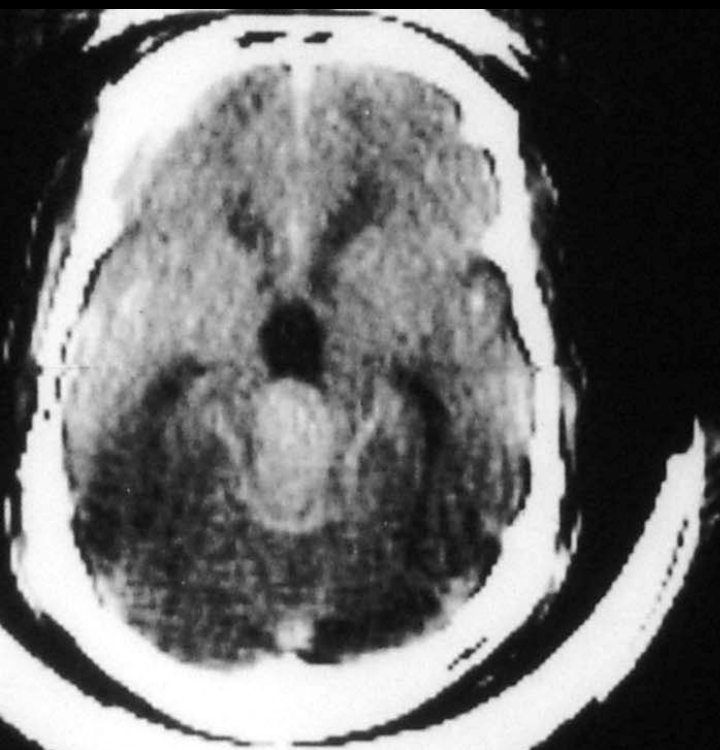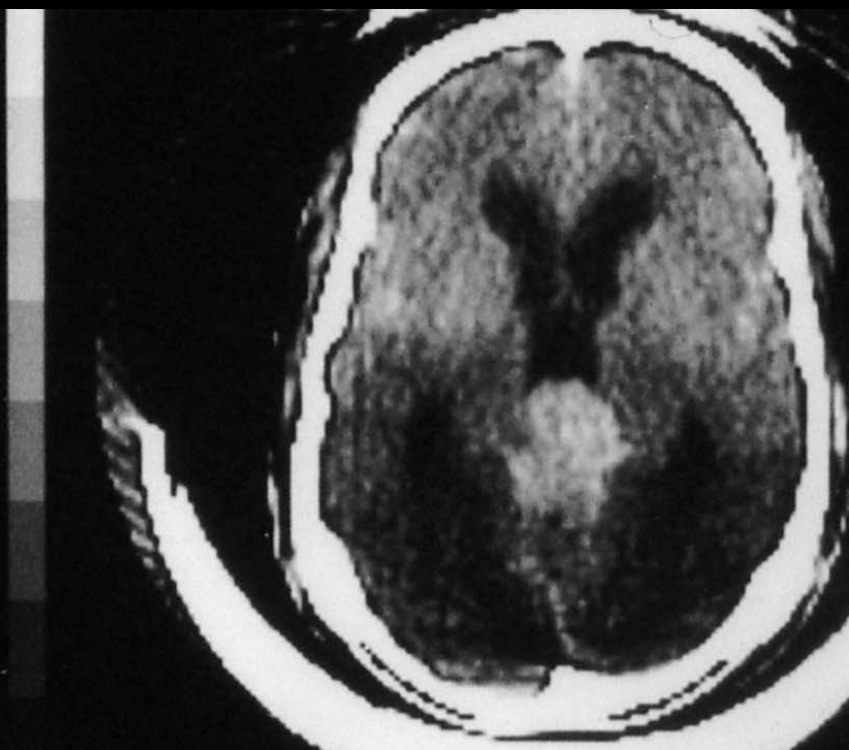


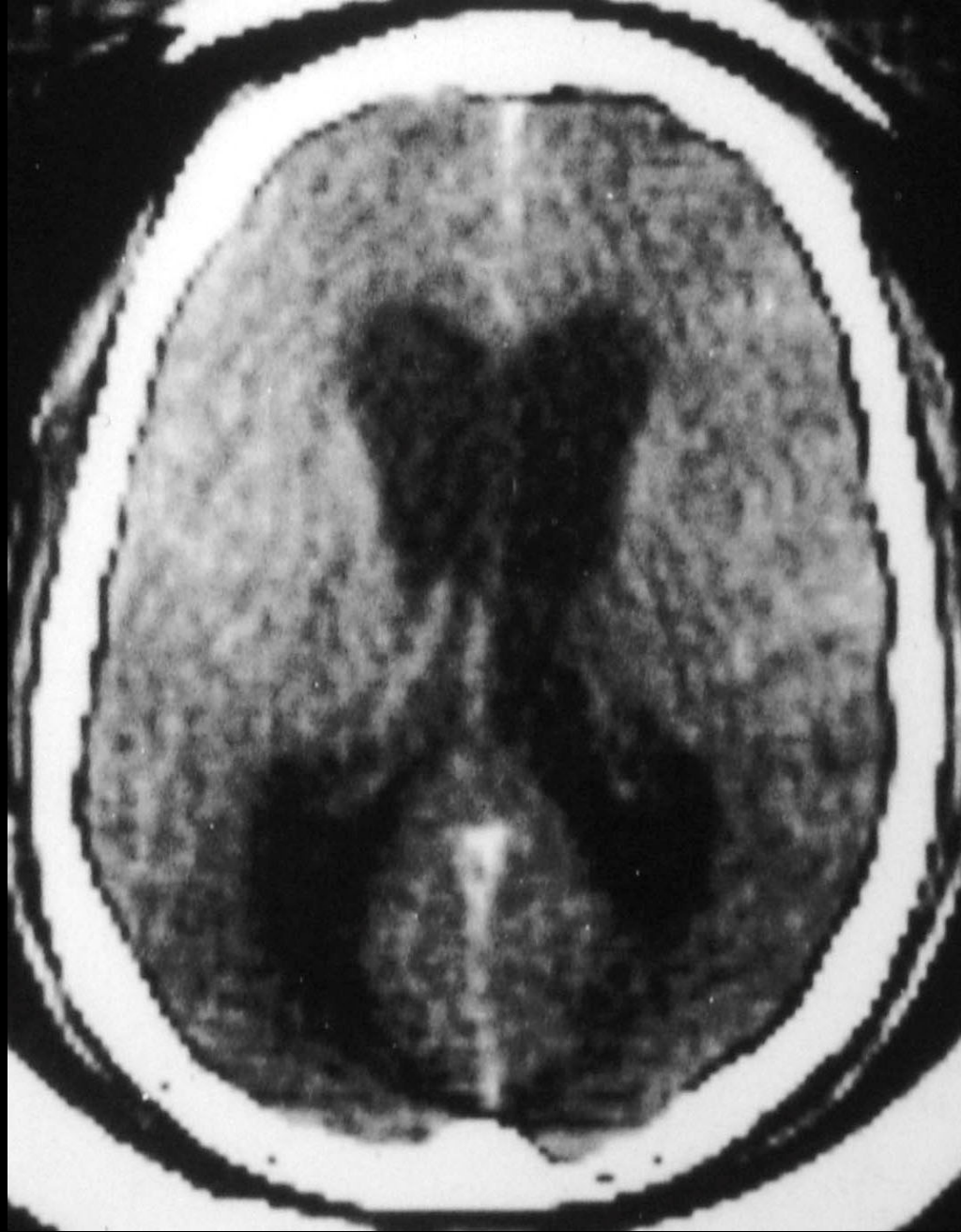+L  
004  
W  
0104



CT Scan with Contrast

Left

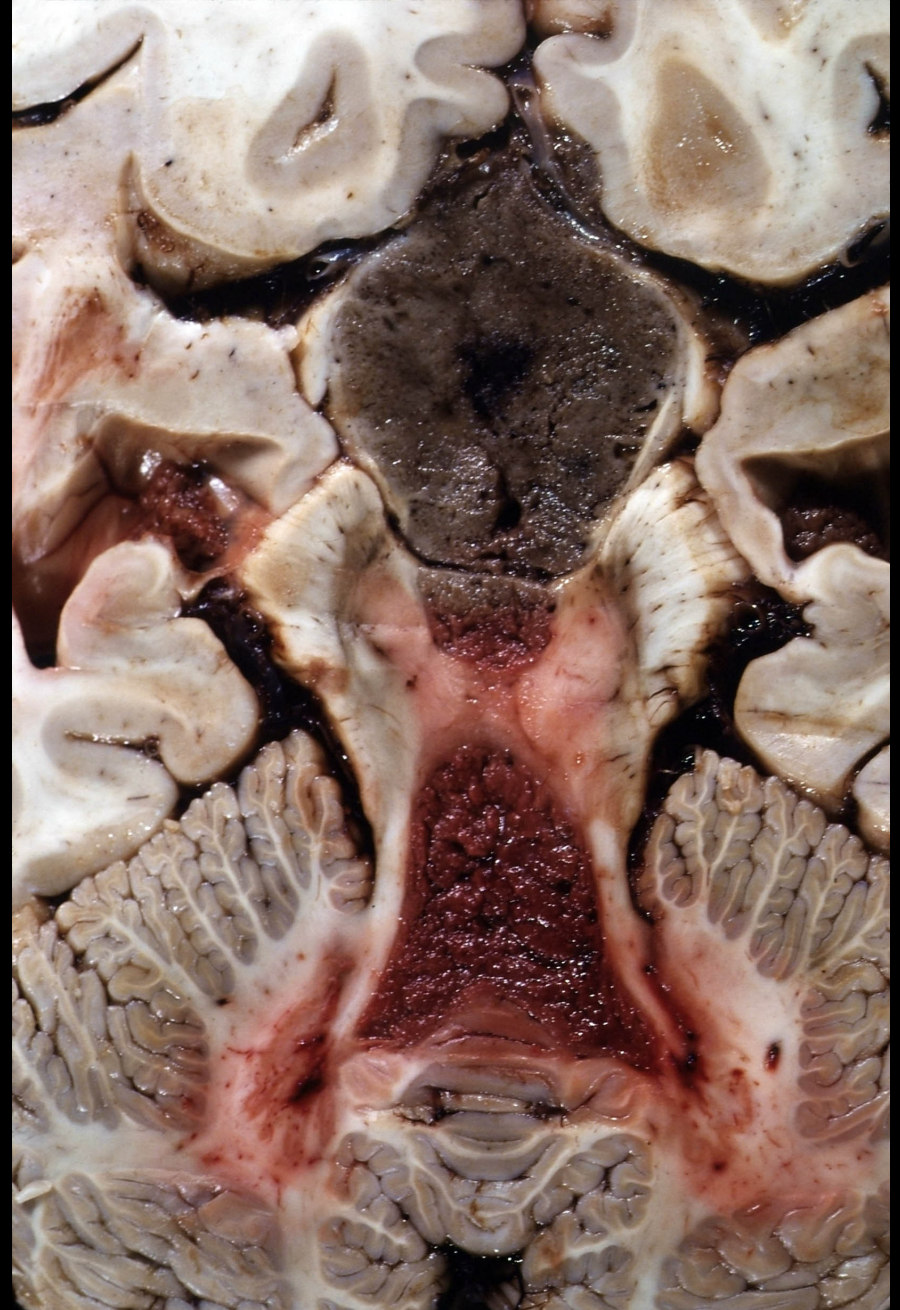
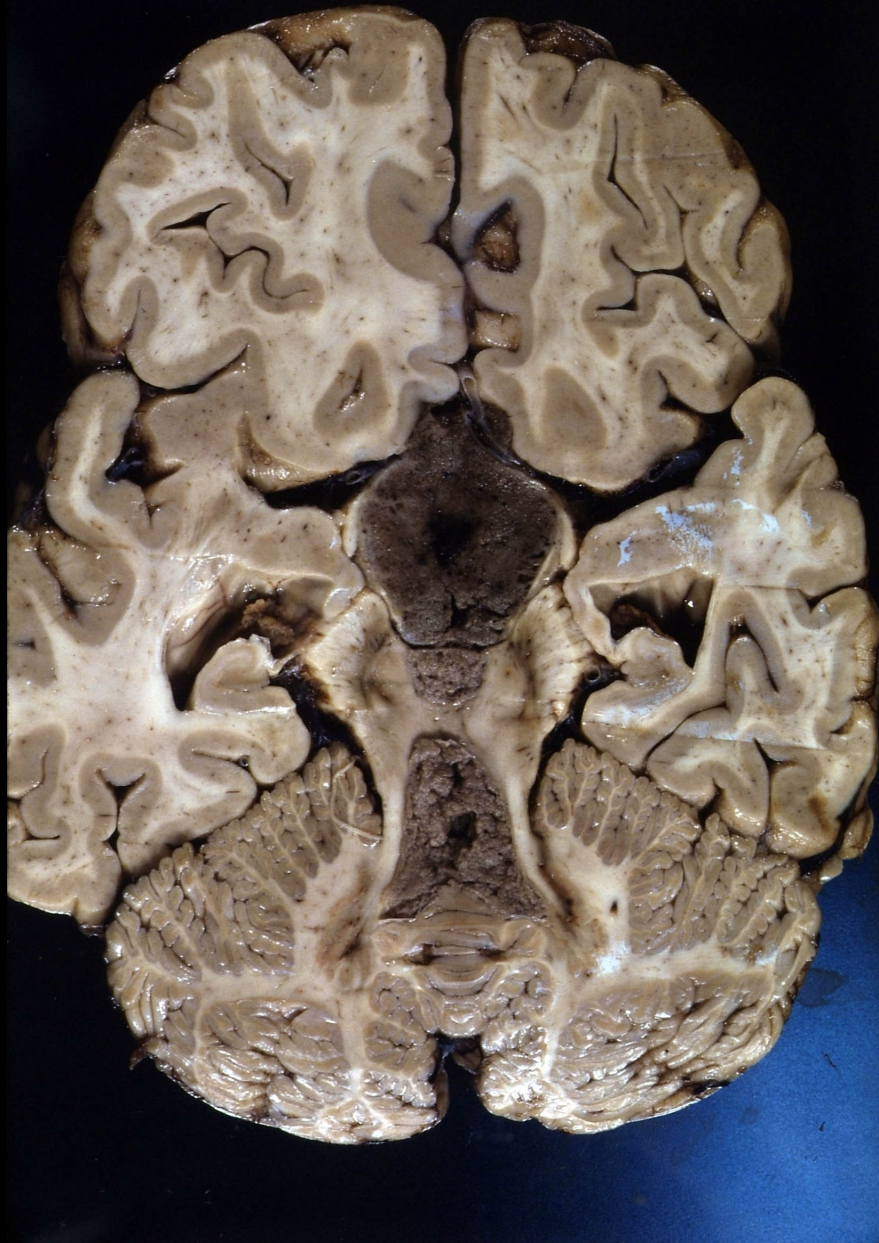Right



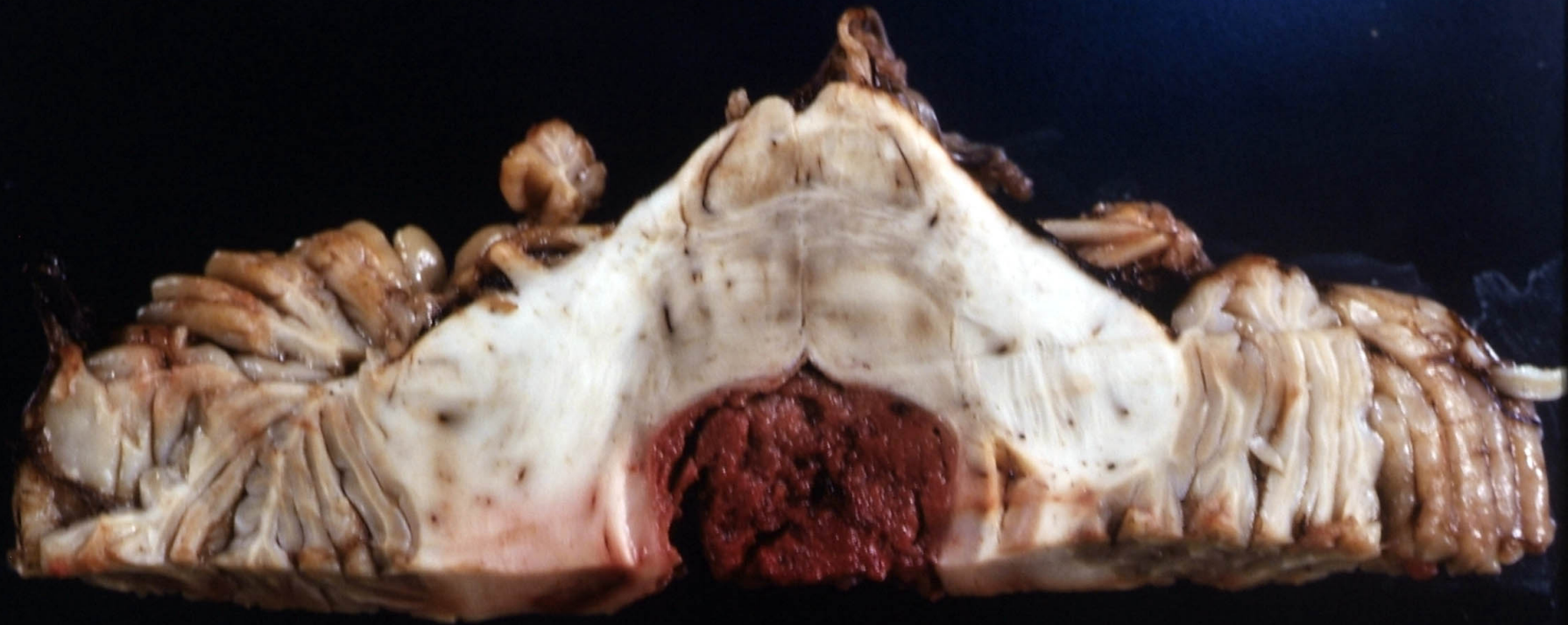Left

CT Scan with Contrast showing Hydrocephalus

Right

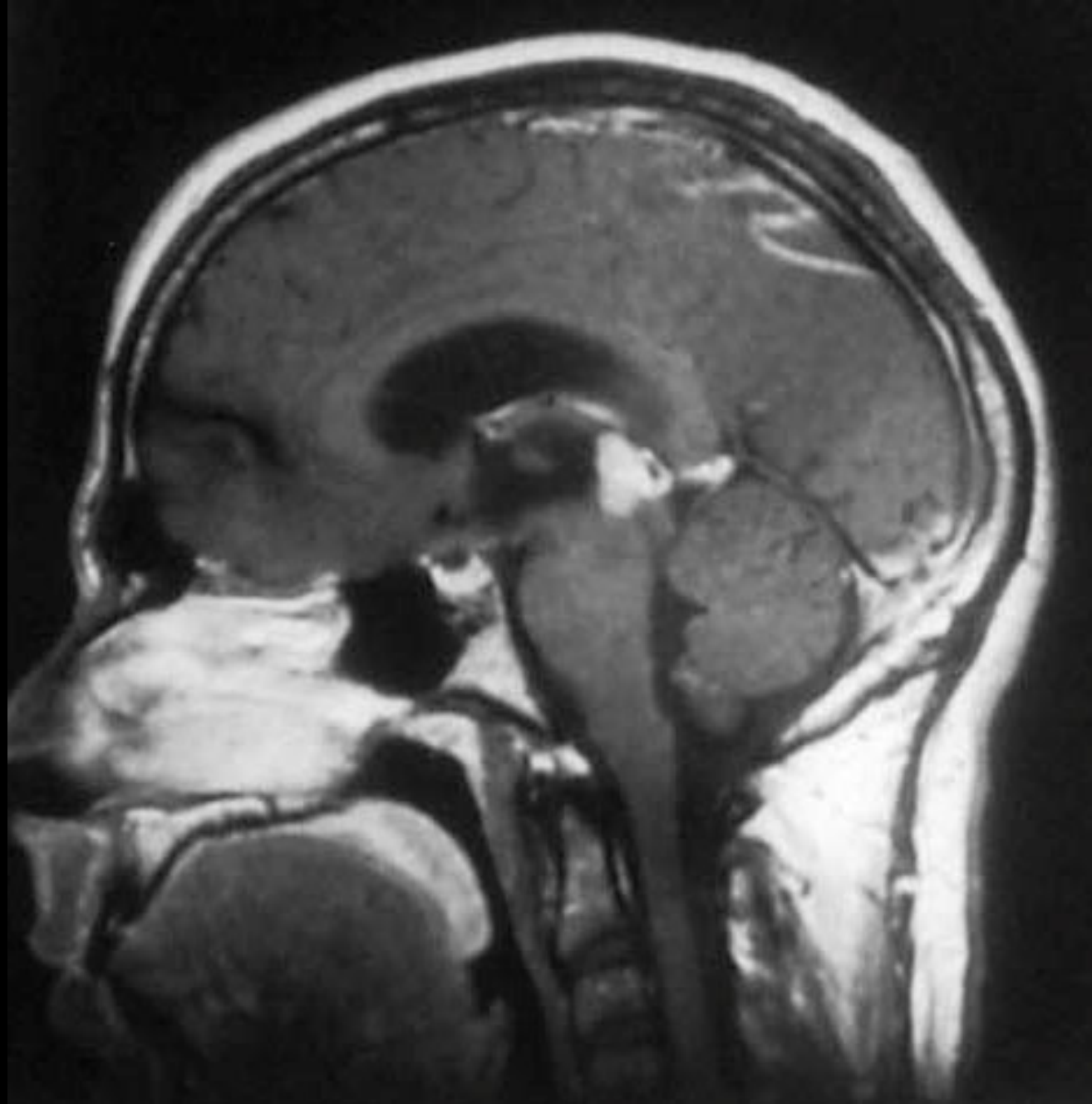


Pinealocytoma:  
Spread to Fourth Ventricle & Subarachnoid Space

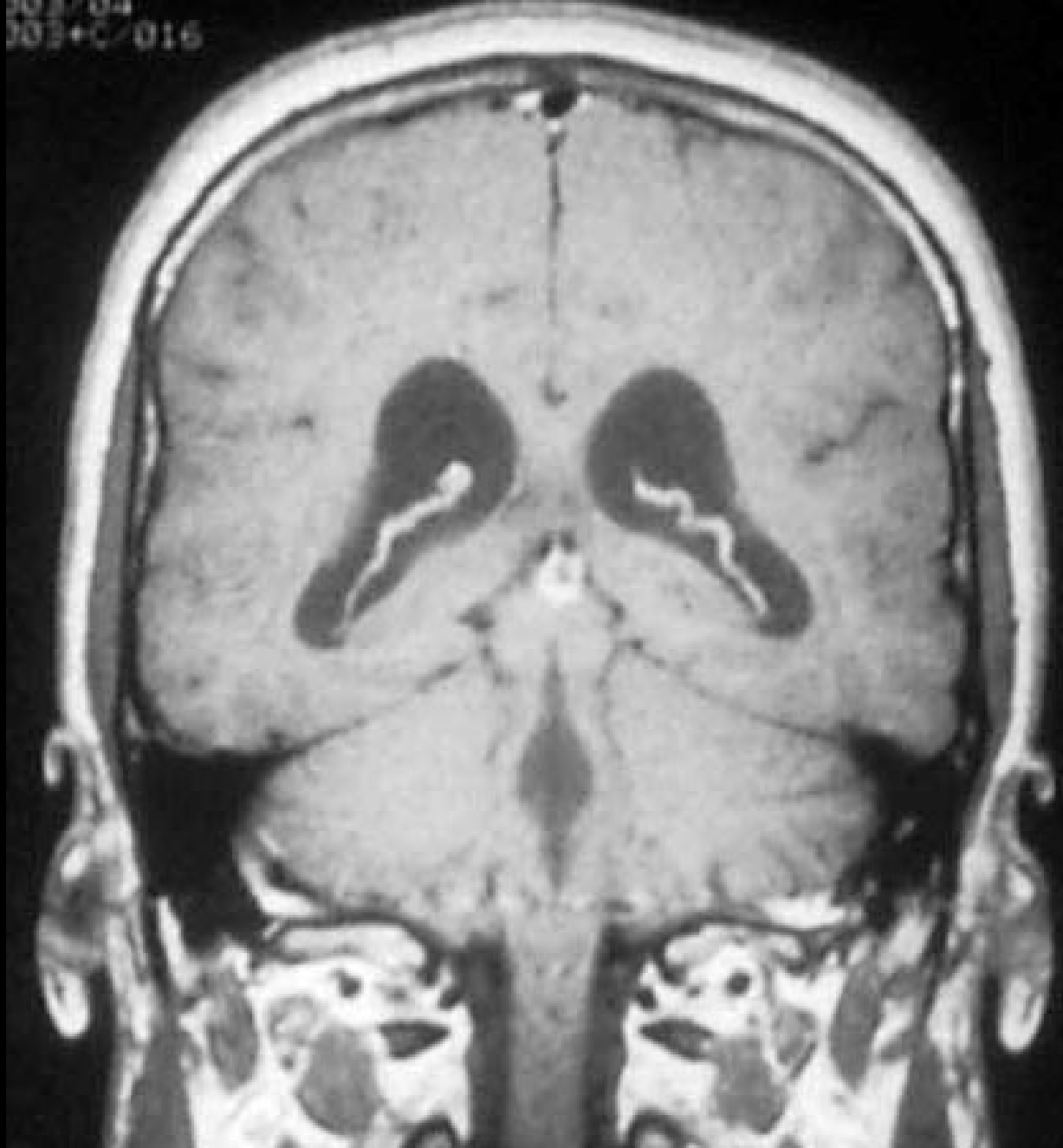


Pinealocytoma:  
Spread to Fourth Ventricle

**Another Example of a  
Pineal Tumor:  
Pineal Germinoma**



Sagittal T1W MRI Scan with Gd



Coronal T1W MRI Scan with Gd