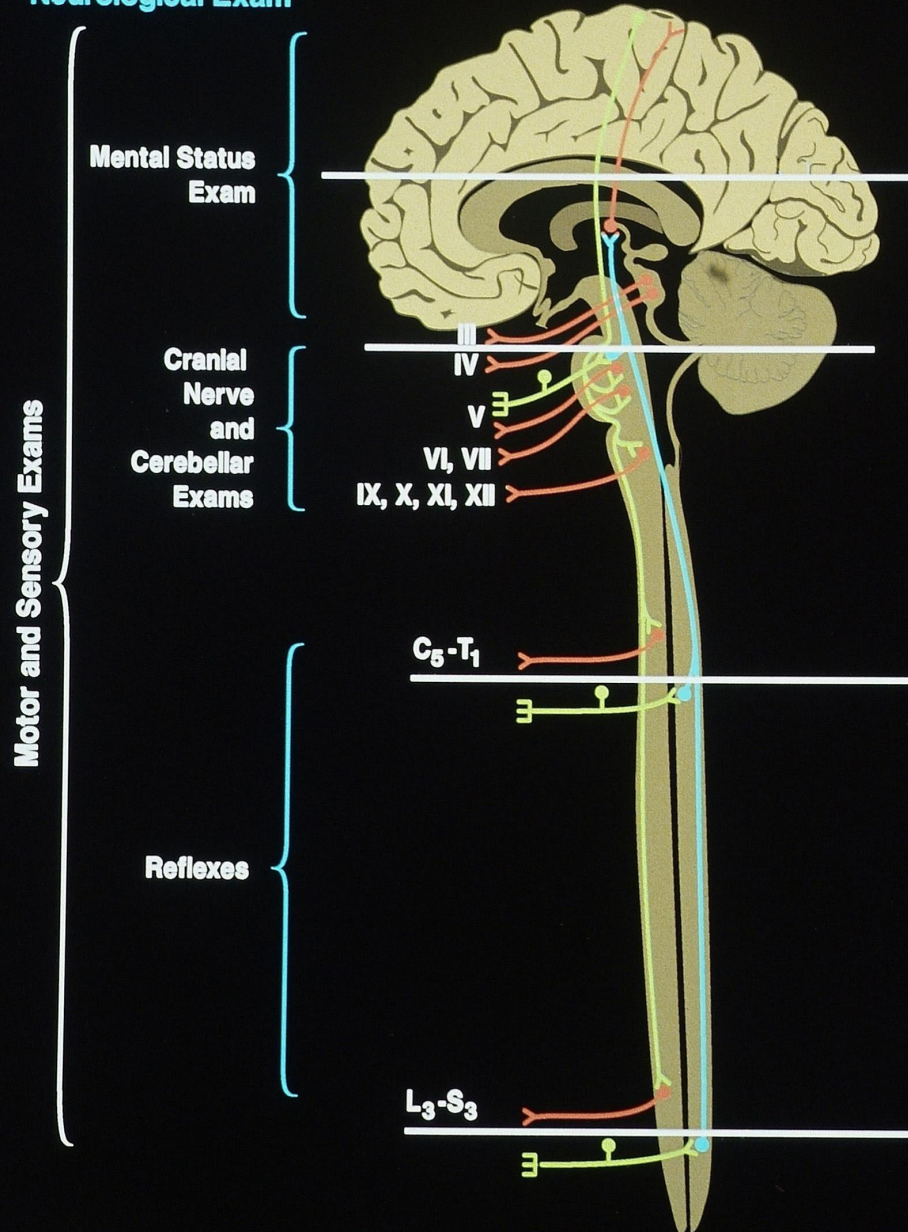
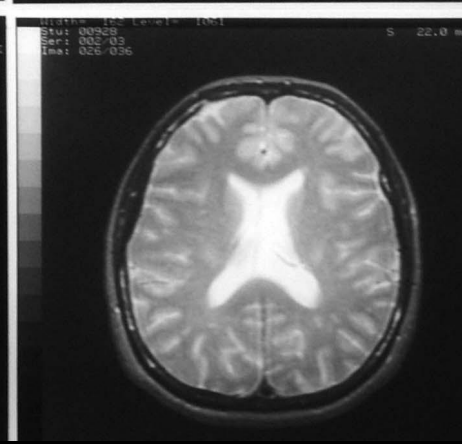
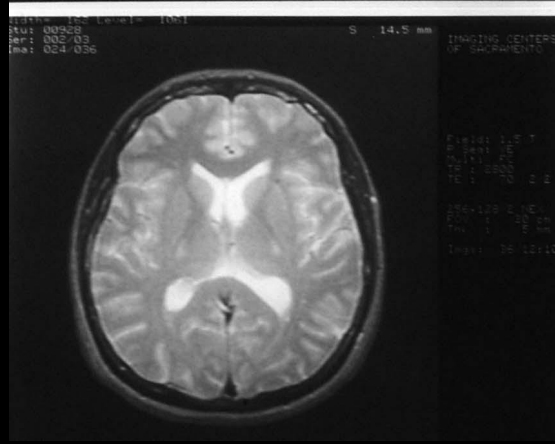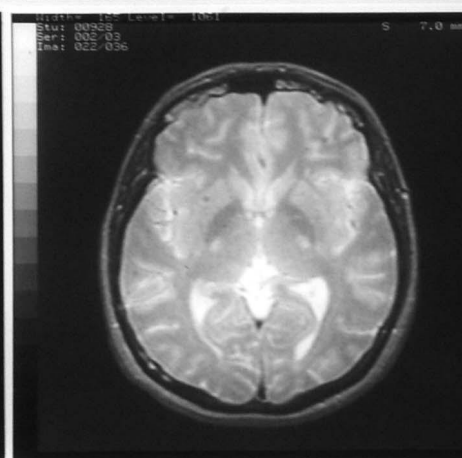
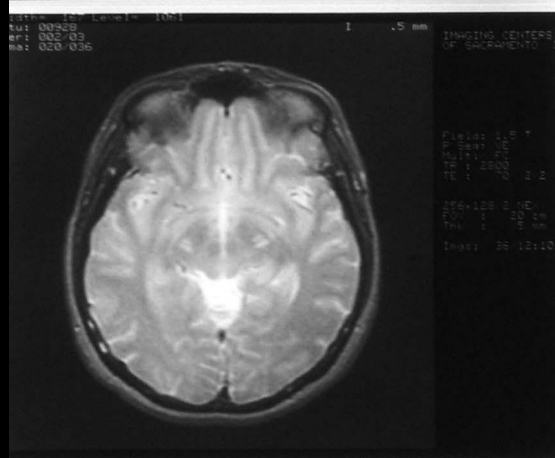
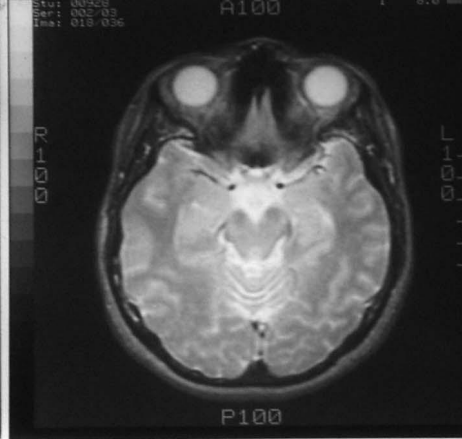
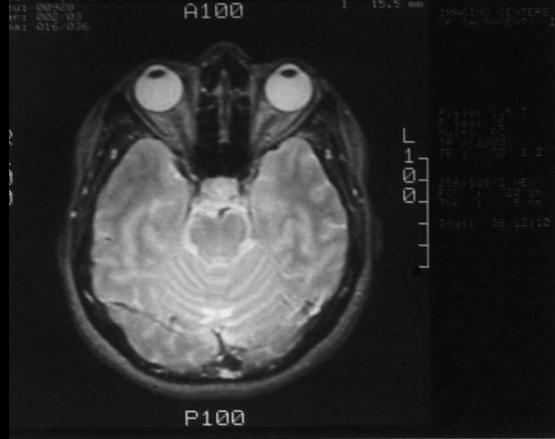


Lesion Localization in Neurologic Disease

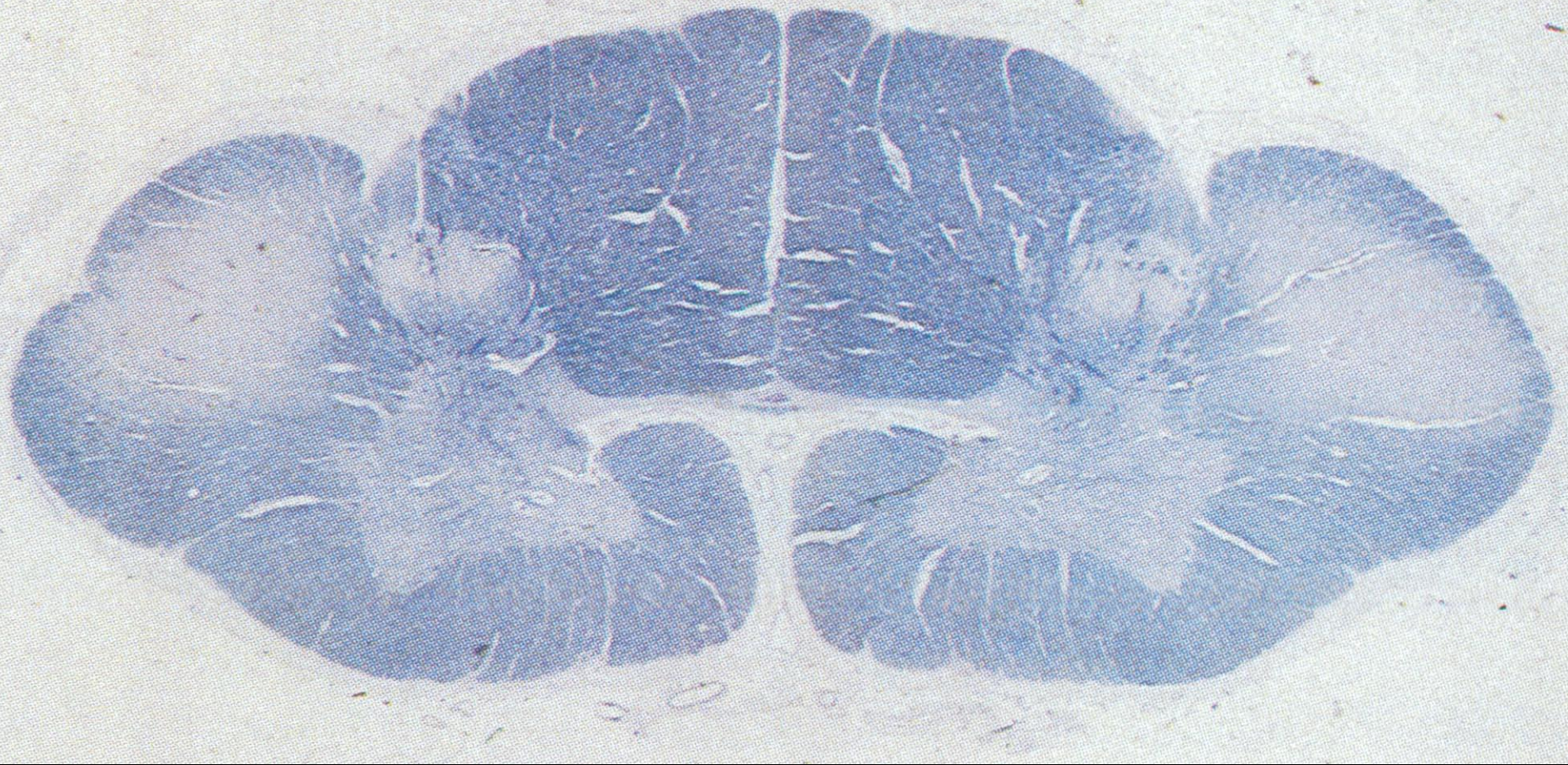
Neurological Exam



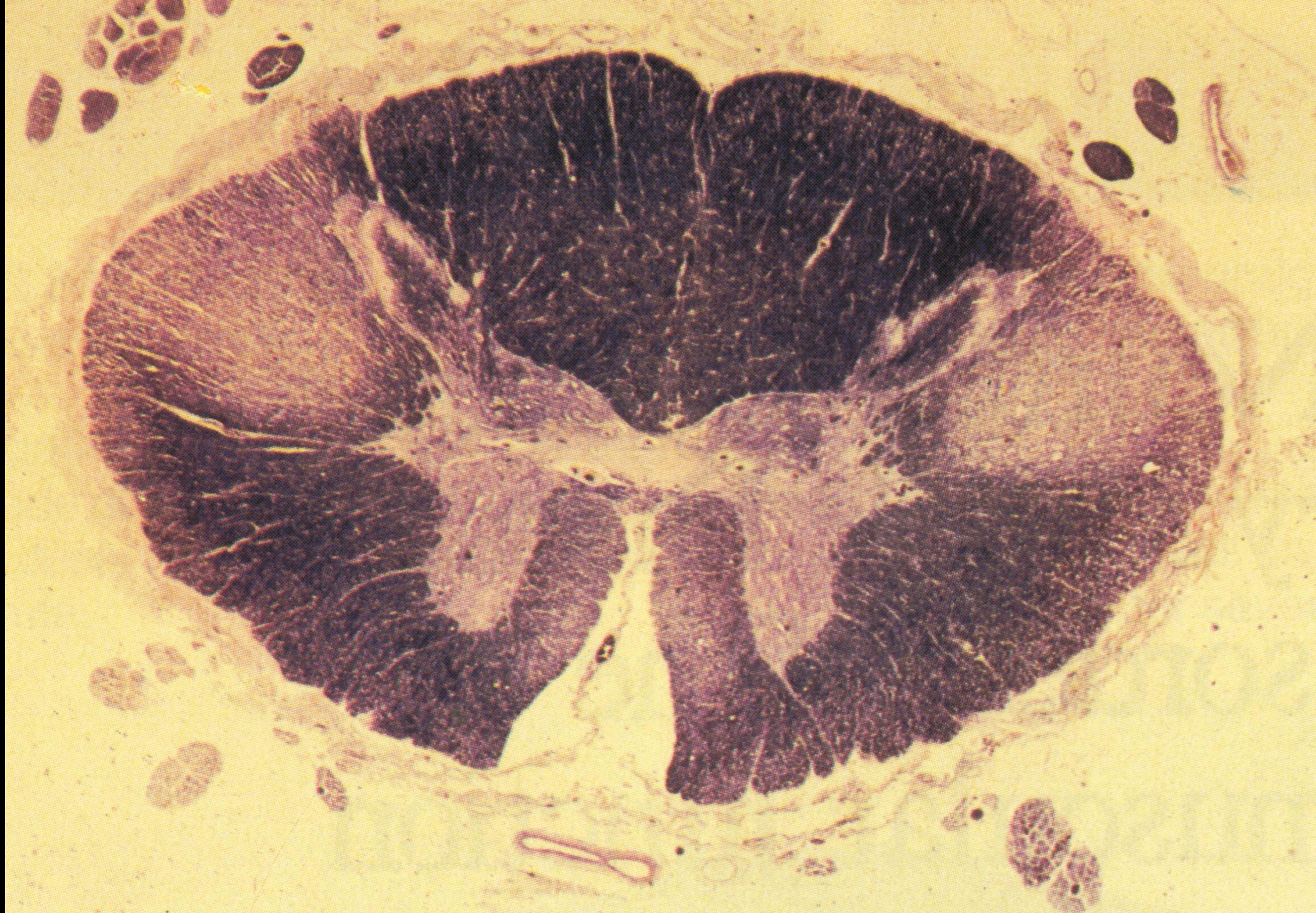An Example of an Evaluation of a Similar Patient, Using Modern MRI Imaging



Horizontal T2W MRI Scan



Amyotrophic Lateral Sclerosis (ALS)
(Lateral Corticospinal Tract Degeneration)



Amyotrophic Lateral Sclerosis (ALS)
(Anterior & Lateral Corticospinal Tract Degeneration)

Myelin Stain