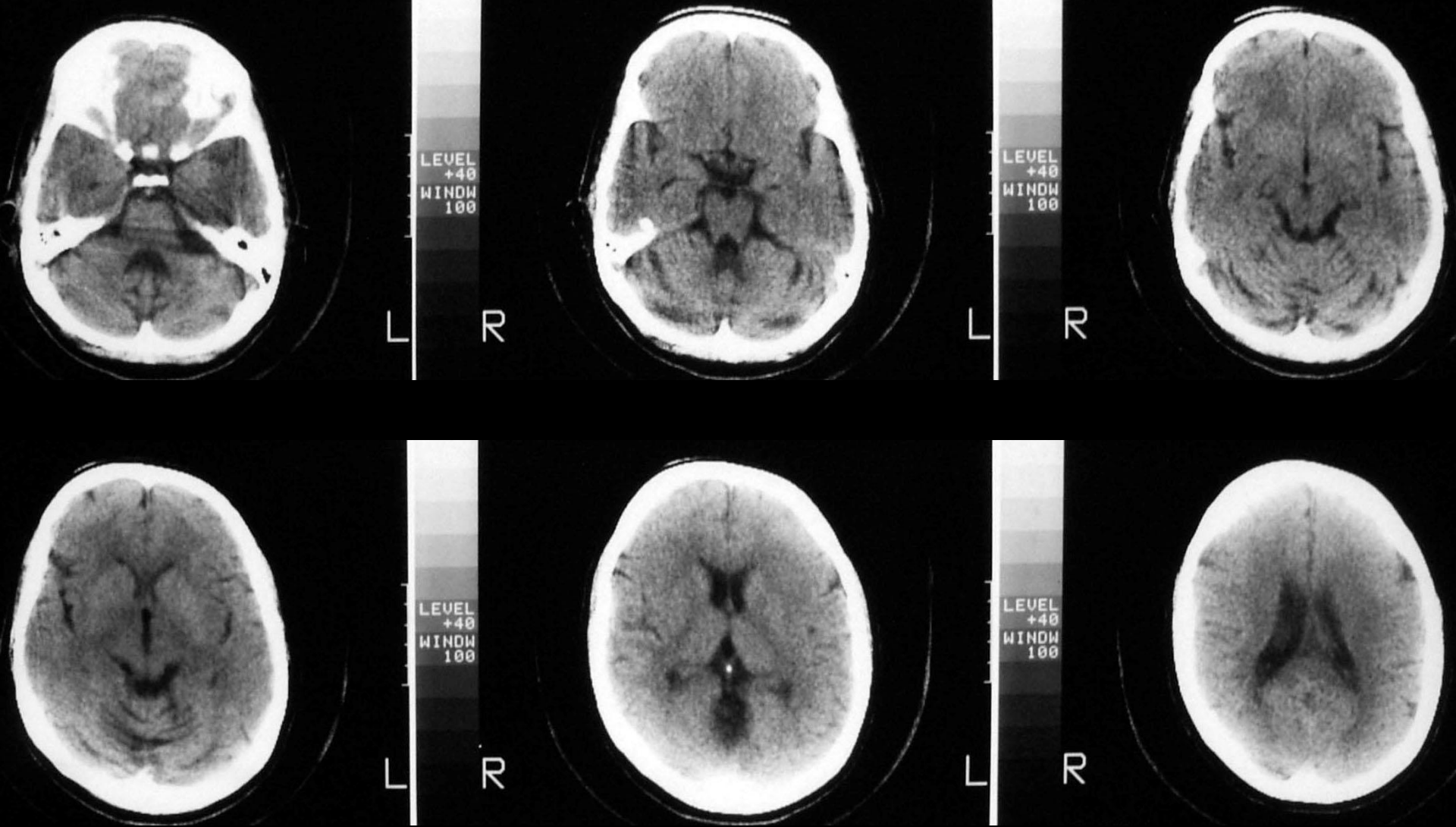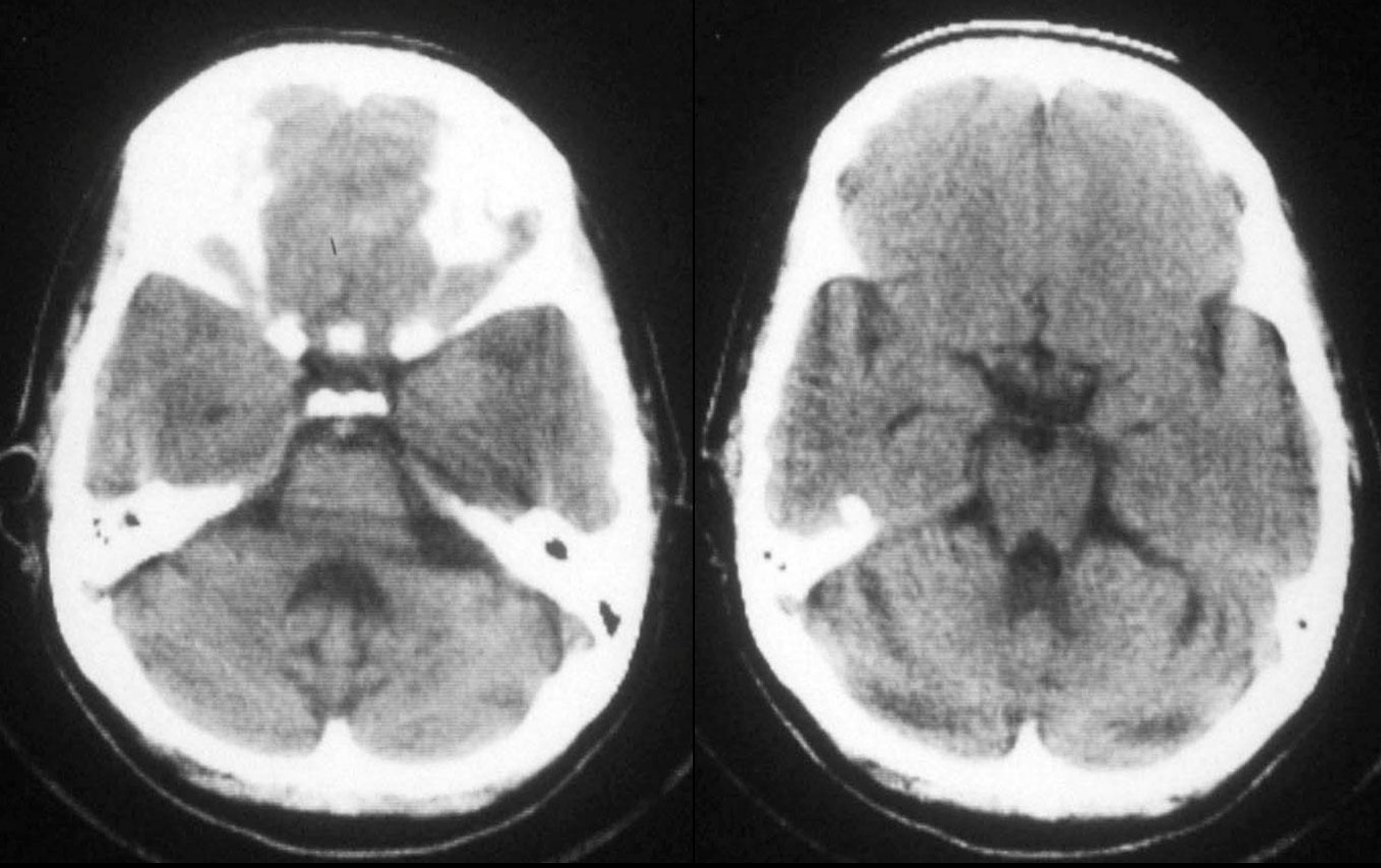


CT Scan without Contrast



CT Scan without Contrast

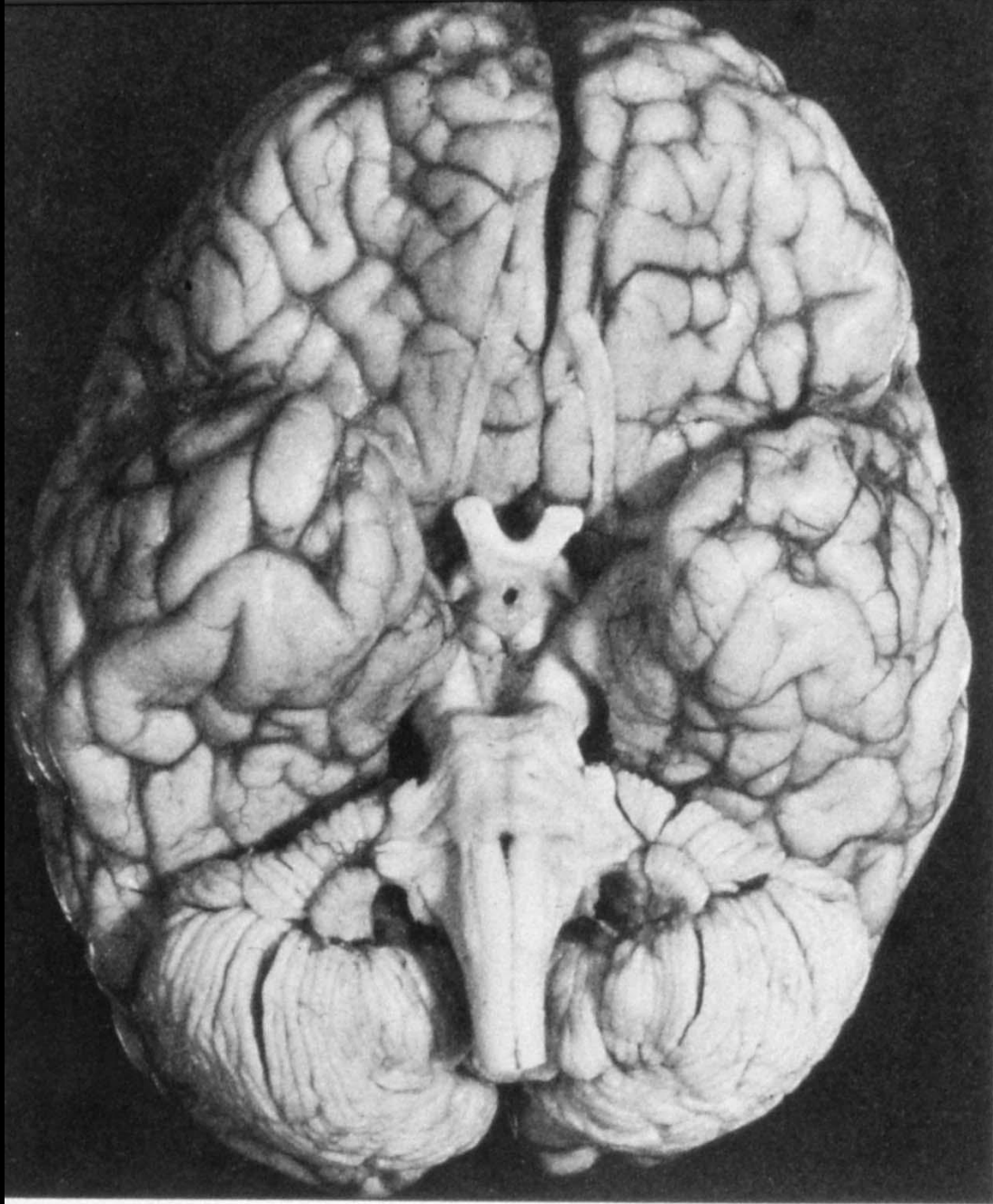


Fig. 173a. Olivopontocerebellar atrophy

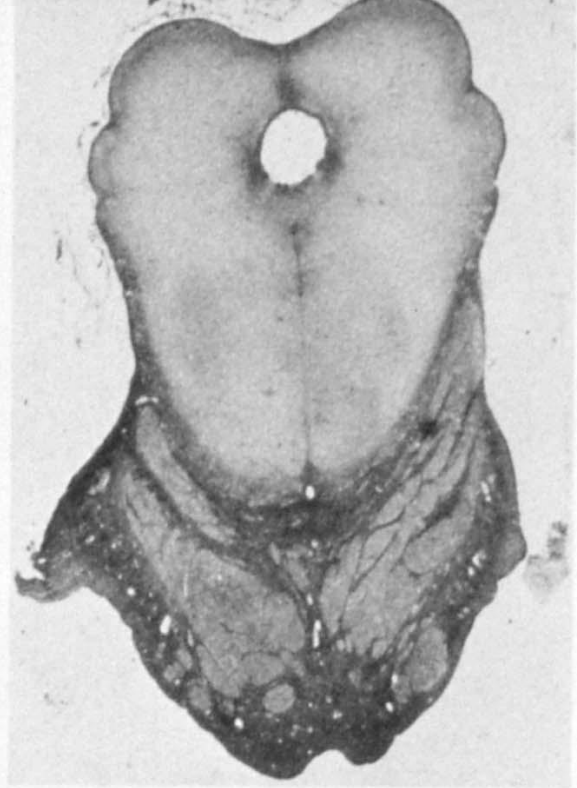


Fig. 173b. Holzer stain of pons (above)

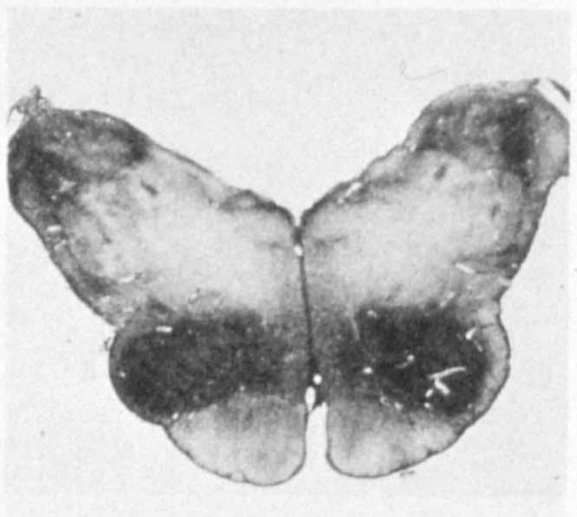
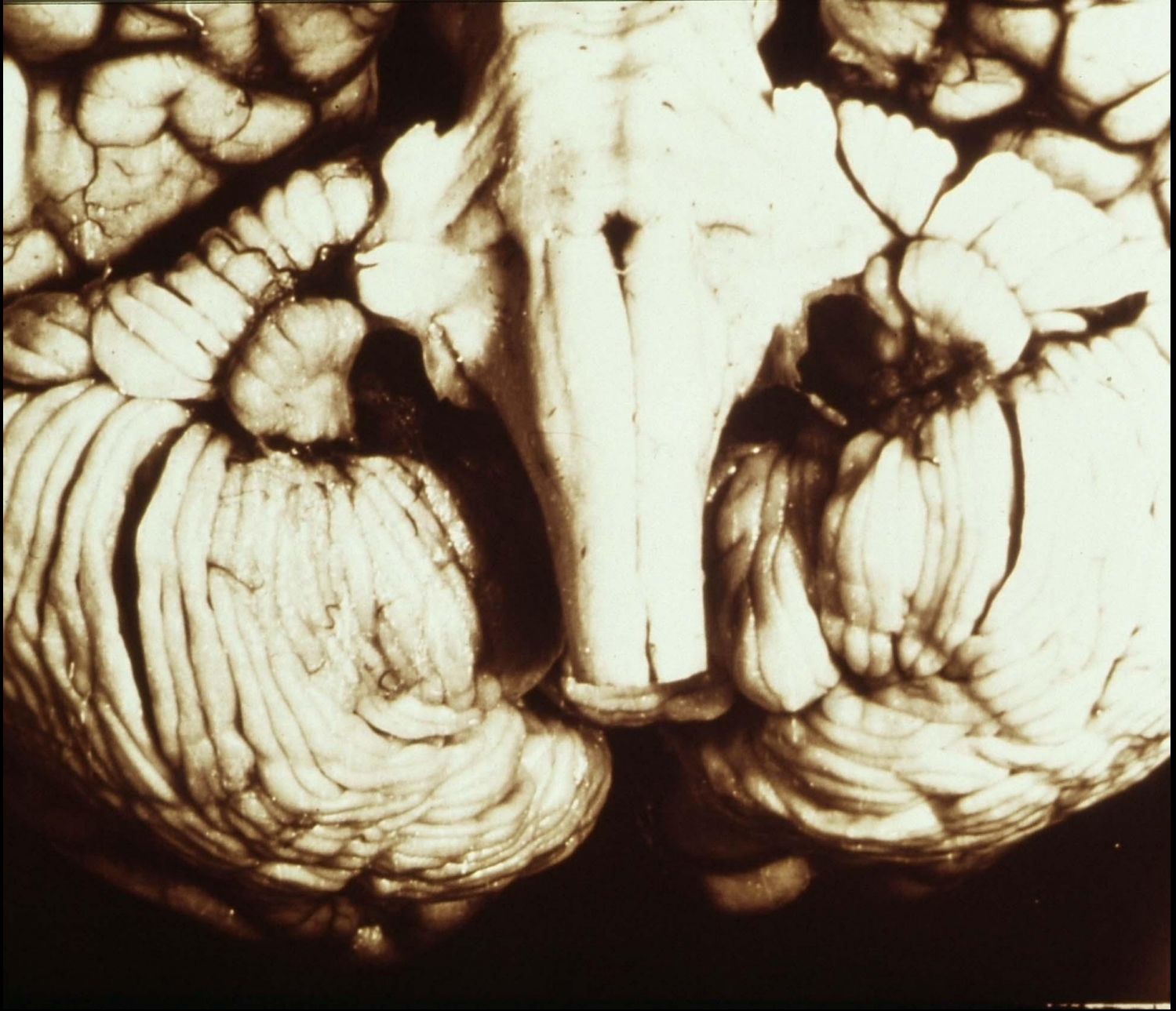

Fig. 173c. Holzer stain of medulla



Olivopontocerebellar Atrophy (OPCA)
(Gross Brain Stem and Cerebellum)