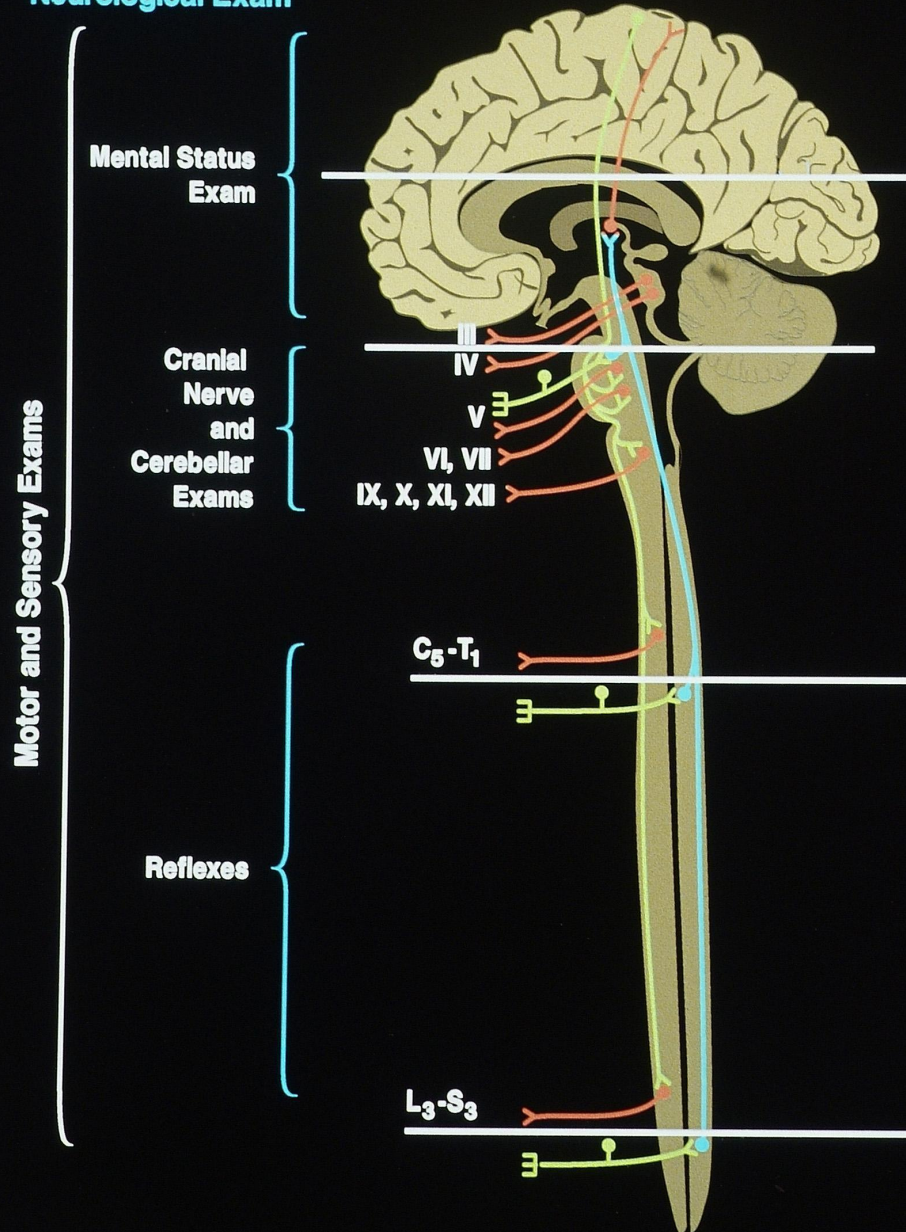
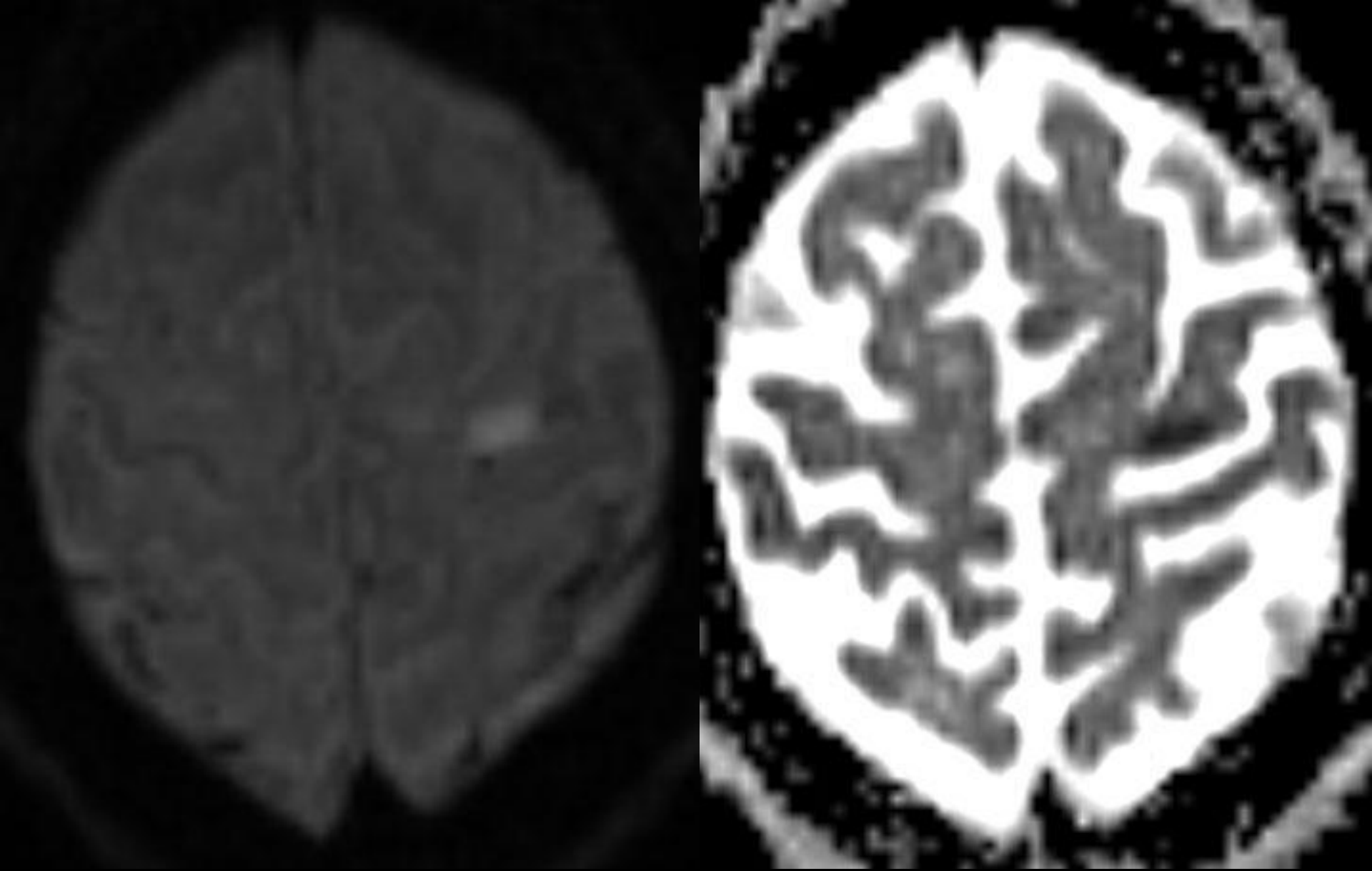


Lesion Localization in Neurologic Disease

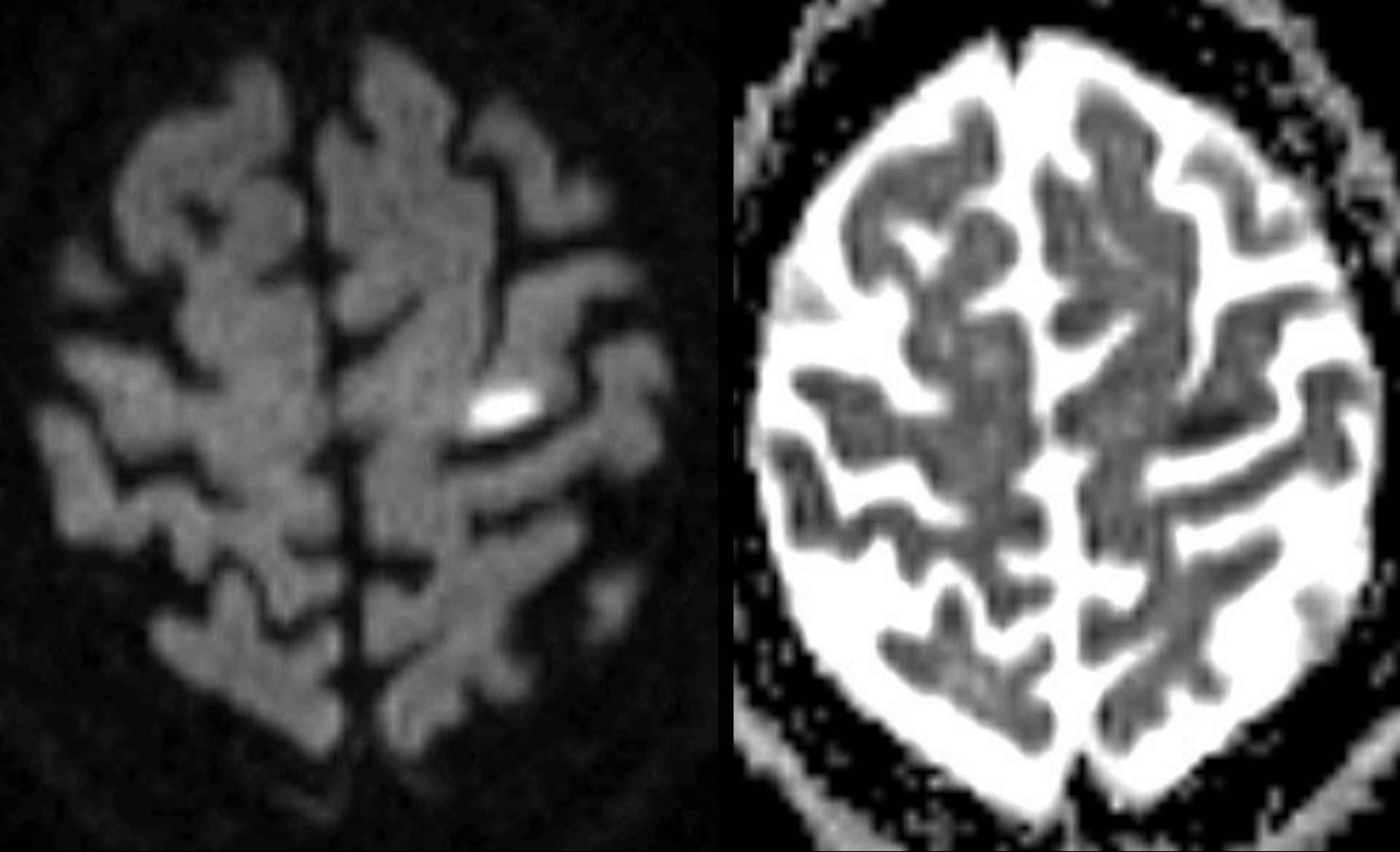
Neurological Exam



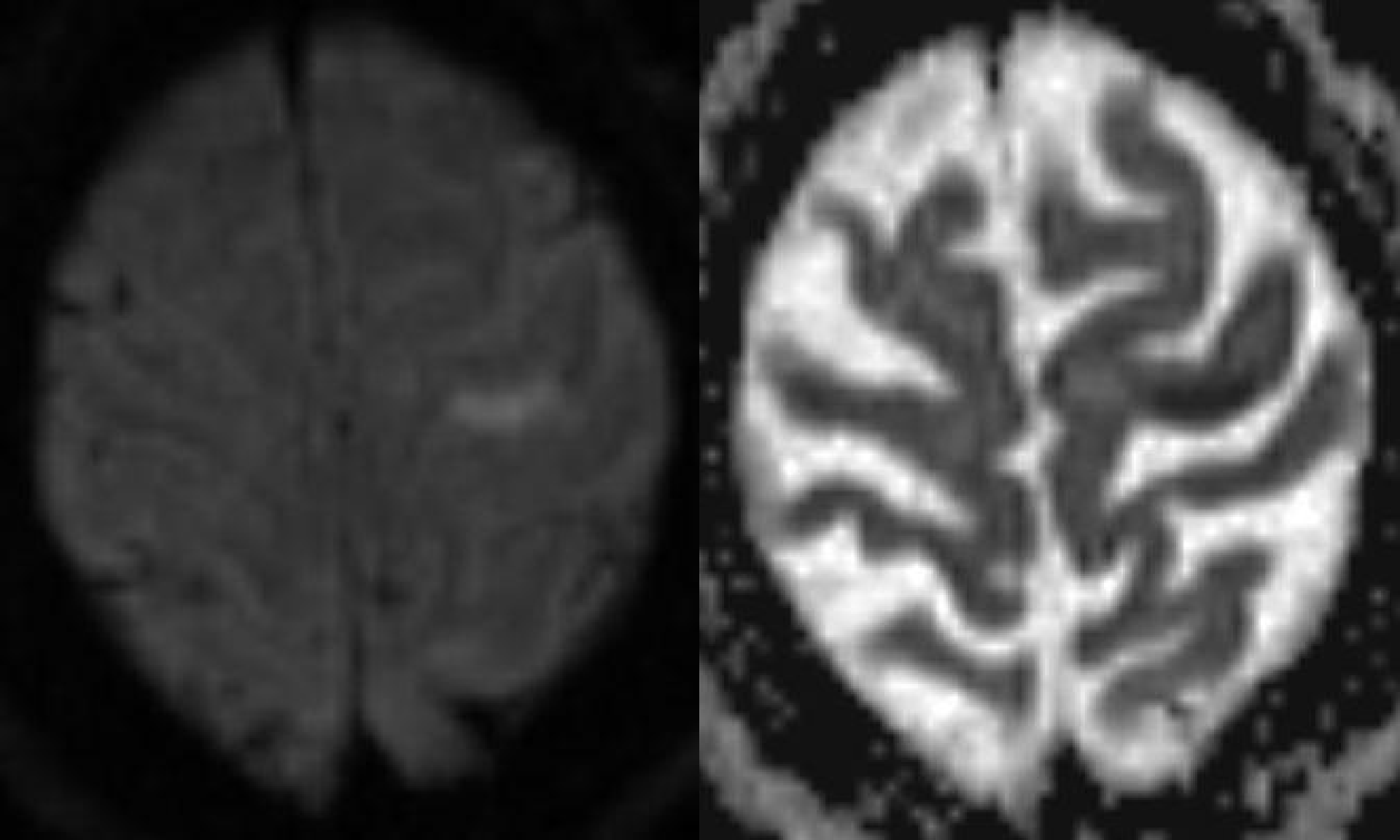


Horizontal DWI [left] & ADC [right] MRI Scan

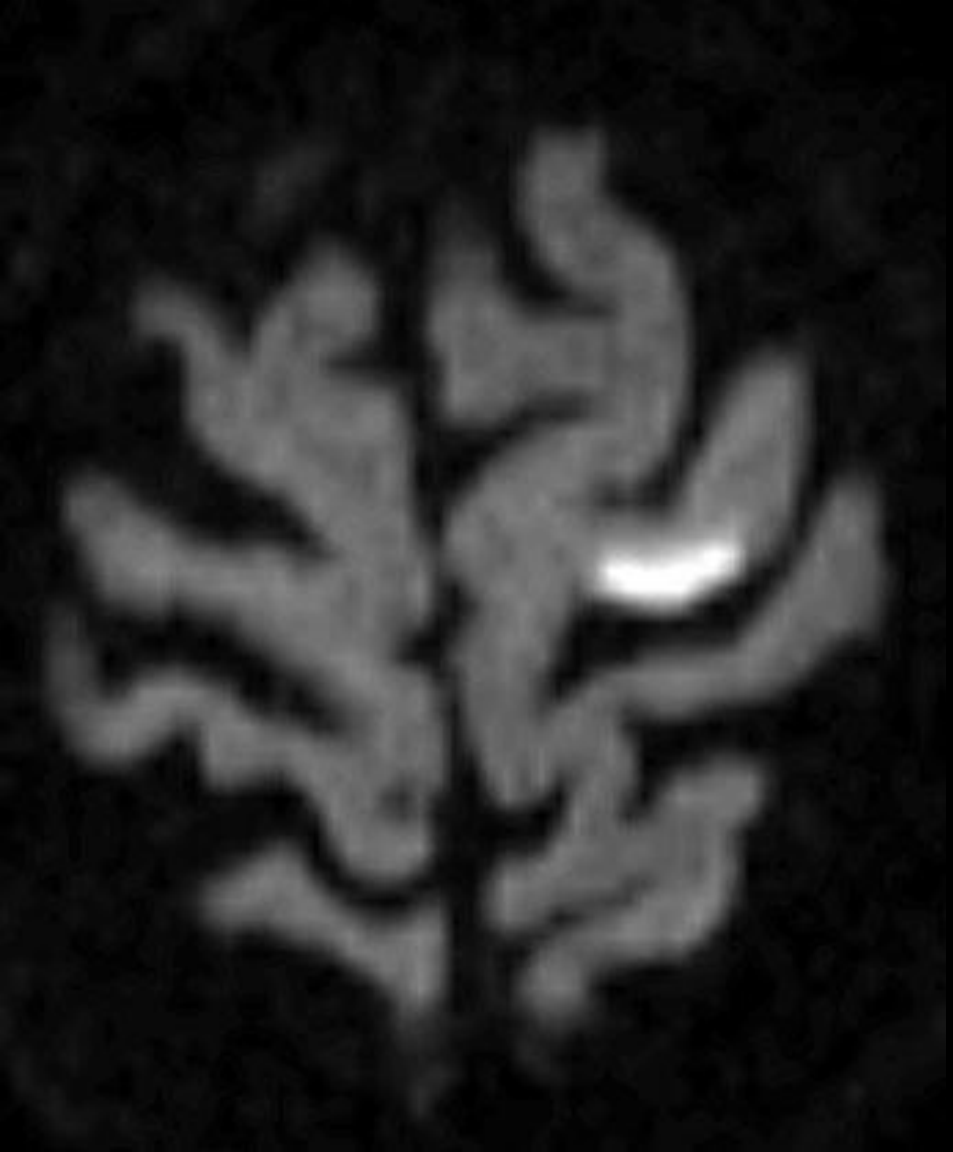2/16/12



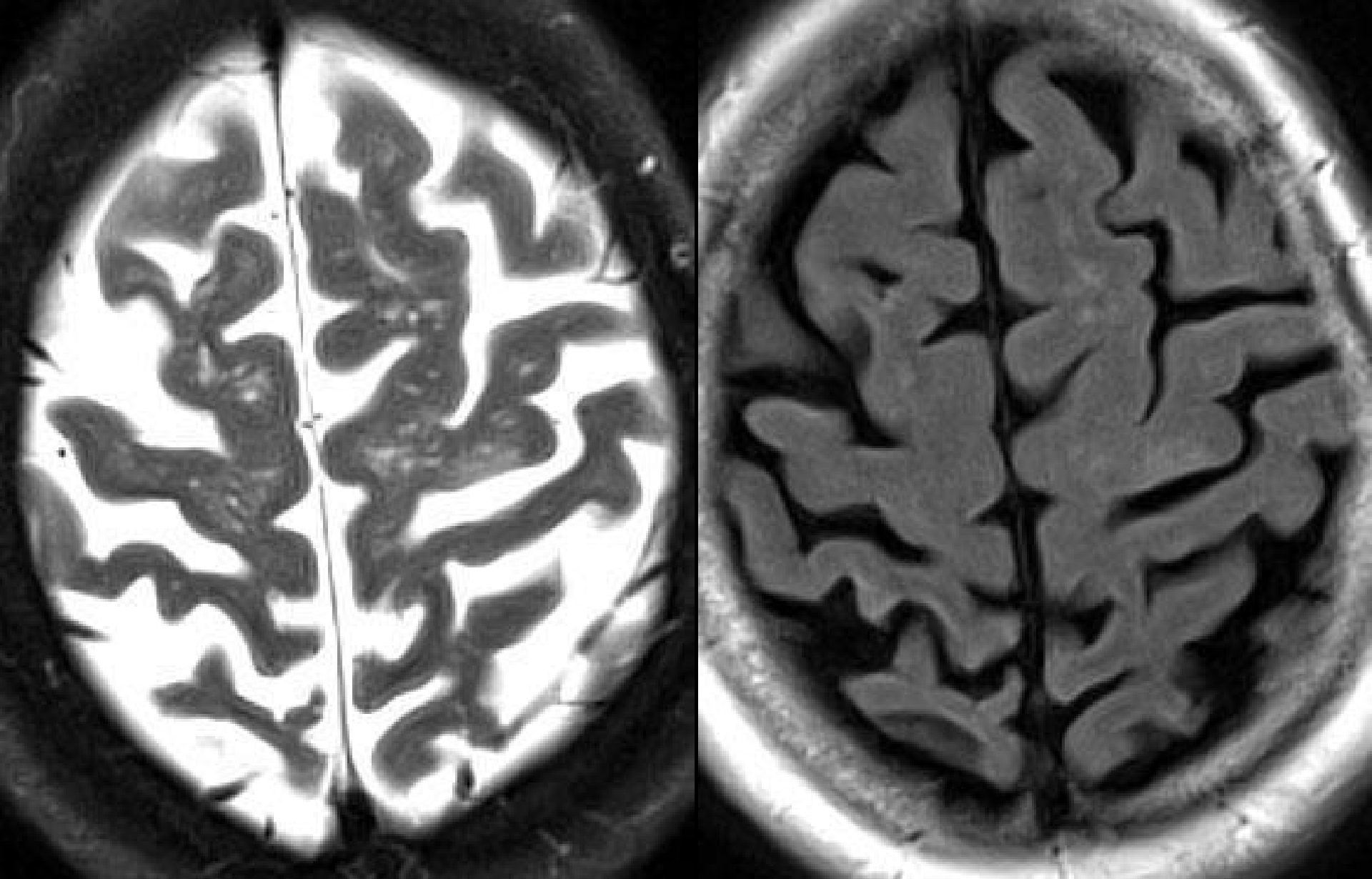
Horizontal DWI [left] & ADC [right] MRI Scan



Horizontal DWI [left] & ADC [right] MRI Scan

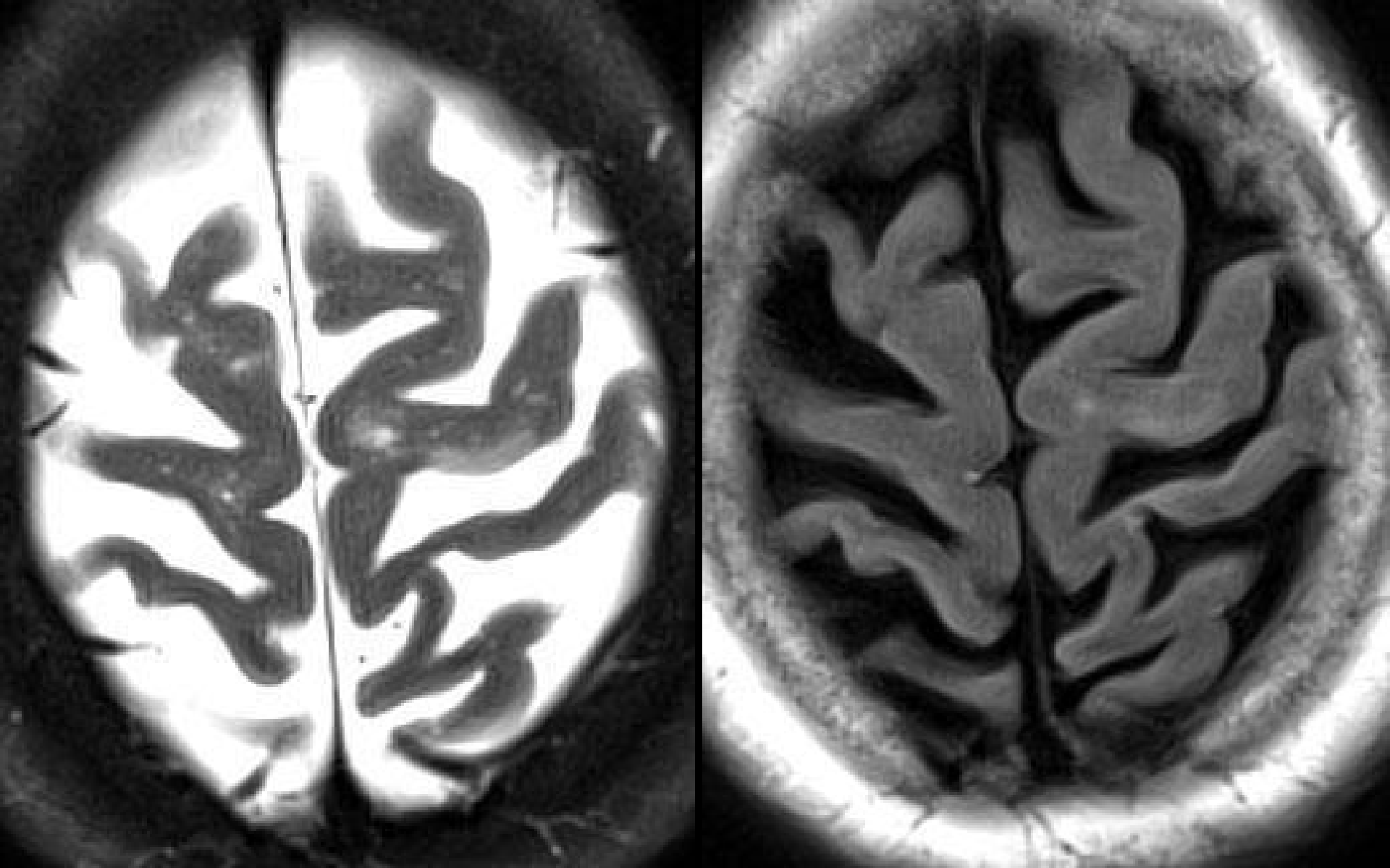


Horizontal DWI [left] & ADC [right] MRI Scan



Horizontal T2W [left] & FLAIR [right] MRI Scan

2/16/12



Horizontal T2W [left] & FLAIR [right] MRI Scan

2/16/12

Motor Homunculus



(from Penfield and Rasmussen, 1950)