

PennHIP Report

Referring Veterinarian: Dr Timothy Bostley Email: hiltonvet@gmail.com	Clinic Name: Hilton Veterinary Hospital Clinic Address: 251 East Avenue Hilton, NY 14468 Phone: (585) 392-2937 Fax: (585) 392-5417
--	--

Patient Information

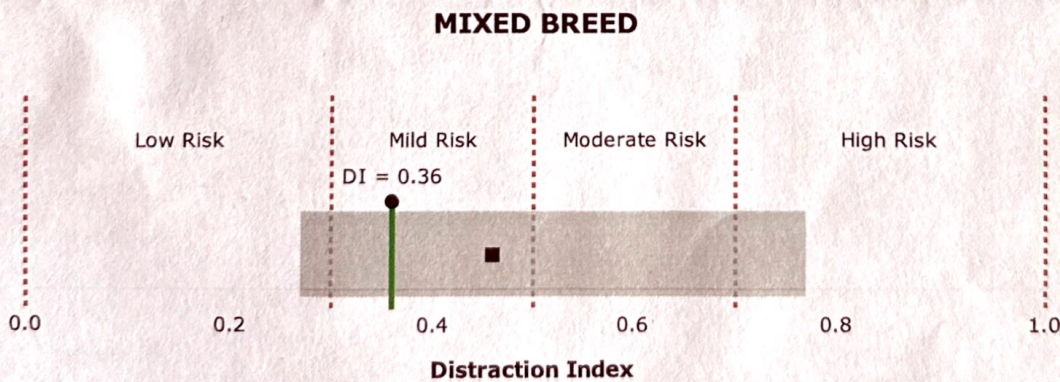
Client: Warner, Jill Patient Name: Truman -GUARDIAN HAS Reg. Name: PennHIP Num: 154988 Species: Canine Date of Birth: 27 Feb 2020 Sex: Male Date of Study: 22 Mar 2021 Date of Report: 04 Apr 2021	Tattoo Num: Patient ID: 15997-1 Registration Num: Microchip Num: Breed: MIXED BREED Age: 13 months Weight: 39 lbs/17.7 kgs Date Submitted: 02 Apr 2021
--	---

Findings

Distraction Index (DI): Right DI = 0.36, Left DI = 0.35. Osteoarthritis (OA): No radiographic evidence of OA for either hip. Cavitation/Other Findings: No cavitation present.
--

Interpretation

Distraction Index (DI): The laxity ranking is based on the hip with the greater laxity (larger DI). In this case the DI used is 0.36.
 OA Risk Category: The DI is between 0.31 and 0.49. This patient is at mild risk for hip OA.
 Distraction Index Chart:



BREED STATISTICS: This interpretation is based on a cross-section of 10834 canine patients of the MIXED BREED breed in the AIS PennHIP database. The gray strip represents the central 90% range of DIs (0.27 - 0.77) for the breed. The breed average DI is 0.46 (solid square). The patient DI is the solid circle (0.36).