

Log in



LETTER TO THE EDITOR | ARTICLES IN PRESS

# Immune-mediated hepatitis with the Moderna vaccine, no longer a coincidence but confirmed

Gloria Shwe Zin Tun • Dermot Gleeson • Amer Al-Joudeh • Asha Dube

Published: October 04, 2021 • DOI: <https://doi.org/10.1016/j.jhep.2021.09.031>



## Keywords

[Immune-mediated liver damage](#) • [drug induced liver injury](#) • [autoimmune hepatitis](#) • [covid-19](#)

To the Editor:

We have read with interest the recent cases suggesting the possibility of vaccine-induced immune-mediated hepatitis with Pfizer-BioNTech and Moderna mRNA-1273 vaccines for the SARS-CoV-2 virus.<sup>1, 2, 3, 4, 5, 6, 7</sup> However, as the cohort of vaccinated individuals against COVID-19 increases, previously reported cases could not exclude a coincidental development of autoimmune hepatitis as an incidence of 3/100,000 population per year.<sup>[8]</sup> Our case demonstrates conc



evidence of vaccine-induced immune-mediated hepatitis with a rapid onset of liver injury after the first Moderna dose, which on re-exposure led to acute severe autoimmune hepatitis.

## Case description

A 47-year-old Caucasian man, previously completely well, received his 1st Moderna vaccine dose on the 26 April 2021. He noted malaise and jaundice 3 days after. Investigations on the 30<sup>th</sup> April showed serum bilirubin 190 µmol/L (normal 0-20), alanine aminotransferase (ALT) 1,048 U/L (normal 10-49), alkaline phosphatase (ALP) 229 U/L (normal 30-130), albumin 41 g/L (normal 35-50). Blood count, renal function and international normalized ratio (INR) were normal. Liver function tests (LFTs) last checked 4 years previously were normal. He denied paracetamol use and reported minimal alcohol intake. Ultrasound scan, CT thorax, abdomen and pelvis and MRI pancreas performed to exclude malignancy, showed no significant findings. Serum IgG was raised at 25.1 g/L (normal 6-16), IgM 2.2 g/L (0.5-2) and serum was positive for anti-nuclear antibody. Serological tests for HAV, HBV, HCV, HEV, EBV and CMV were negative.

His jaundice faded and LFTs improved: bilirubin falling on 25<sup>th</sup> June to 69 µmol/L and ALT to 332 U/L. The patient received his 2<sup>nd</sup> Moderna vaccine dose on the 6 July 2021 (despite reporting the jaundice to the vaccination centre) and the jaundice returned a few days after. Blood tests on 20th July found bilirubin 355 µmol/L, ALT 1,084 U/L and a raised prothrombin time (PT) of 18.4 seconds. After liver biopsy on the 21st July 2021, prednisolone 40 mg/day was commenced and he was transferred to our service.

On examination, he was alert, deeply jaundiced, with hepatomegaly but no ascites. Repeat abdominal ultrasound showed a mildly fatty liver, patent portal and hepatic vein flow, with no ascites. Review of the liver biopsy showed acute active hepatitis: widespread areas of bridging necrosis, marked interface hepatitis, lymphoplasmatic inflammation including eosinophils, ballooned hepatocytes, multi-nucleated giant cells, and emperipolesis ([Fig.1](#)). There was minimal fibrosis, Ishak stage 1. The pattern of injury on histology was consistent with acute hepatitis, with features of autoimmune hepatitis or possible drug-induced liver injury (DILI), triggering an autoimmune-like hepatitis.

 Figure thumbnail gr1

stological findings and biochemical findings.



w full caption



H&E-stained section of liver biopsy indicates acute hepatitis. (A) The parenchymal hepatocytes are arranged into rosette forms (marked with arrows) with cholestasis. (B) BN from hepatocyte loss, some by apoptosis (arrow). (C) Diagram showing trend of bilirubin and ALT following Moderna vaccine dose 1 and 2 with response to prednisolone. ALT, alanine aminotransferase; BN, bridging necrosis.

[View Large Image](#) | [Download Hi-res image](#) | [Download \(PPT\)](#)

Prednisolone 40 mg/day was continued and LFTs improved ([Fig. 1](#)). He was discharged on prednisolone and on follow-up, blood tests continue to improve, and PT normalised within 2 weeks.

## Discussion


This case illustrates immune-mediated hepatitis secondary to the Moderna vaccine, which on inadvertent re-exposure led to worsening liver injury with deranged synthetic function. This occurred in a well man with no other medical problems. The onset of jaundice associated with the mRNA vaccine was unusually rapid. This was also illustrated in the other cases where symptoms developed over a median of 7 days (range 4-35). Latency is usually longer in other causes of DILI, but can vary depending on mode of injury.

The mRNA vaccine pathway triggers pro-inflammatory cytokines including interferon and cross-reactivity has been illustrated between the antibodies against the spike protein and self-antigens.<sup>[9],[10]</sup>

Seven cases of suspected immune-mediated hepatitis have been reported with SARS-2-COV mRNA vaccines (3 with Pfizer and 4 with Moderna).<sup>1, 2, 3, 4, 5, 6, 7</sup> Liver histology was assessed in every case and findings were similar to ours, indicating acute hepatitis with interface hepatitis, lymphoplasmacytic infiltrate and absence of fibrosis. Eosinophils as part of the infiltrate, which can be noted in DILI were present in 3 cases. All 7 patients responded well to steroids (n = 5 prednisolone, n = 1 budesonide and n = 1 methylprednisolone). In 3 cases there were features suggesting coincidental autoimmune hepatitis: a 35-year-old lady in her third trimester of pregnancy with positive double-stranded DNA, an 80-year-old lady with a history of autoimmune conditions and a 41-year-old lady with strongly positive auto-antibody panel after both doses of vaccination. In the other 4 cases, a raised IgG, with at least 1 positive antibody was noted in 3 cases.<sup>4, 5, 6, 7</sup>



case has confirmed immune-mediated hepatitis secondary to the Moderna vaccine, inadvertent re-exposure led to acute severe hepatitis. Treatment with corticosteroid thera



be favourable. We wish to highlight that immune-mediated reactions from the SARS-CoV-2 mRNA vaccines are very rare and during the COVID pandemic, the vaccination programme continues to be crucial. We report this case to encourage vigilance for drug-induced reactions and to raise awareness to vaccination centres to incorporate it into their routine checks before administering second doses. Long-term follow up of identified individuals will be essential in determining the prognosis of this immune-mediated liver injury.

## Financial support

The authors received no financial support to produce this manuscript.

## Authors' contributions

DG and AAJ conceptualised the work. GT wrote the initial draft and all authors contributed to and approved the final manuscript.

## Conflict of interest

The authors declare no conflicts of interest that pertain to this work.

Please refer to the accompanying ICMJE disclosure forms for further details.

## Supplementary data

The following is the supplementary data to this article:








[Download .pdf \(.32 MB\)](#)

[Help with pdf files](#)

Multimedia component 1



## References

1. Bril F. • Al Diffalha S. • Dean M. • Fettig D.M. • et al.  
**Autoimmune hepatitis developing after coronavirus disease 2019 (COVID-19) vaccine: causality or casualty?.**  
*J Hepatol.* 2021; **75**: 222-224  
[View in Article](#)   
[Scopus \(31\)](#) • [PubMed](#) • [Abstract](#) • [Full Text](#) • [Full Text PDF](#) • [Google Scholar](#)
2. Rocco A. • Sgamato C. • Compare D. • Nardone G. • et al.  
**Autoimmune hepatitis following SARS-CoV-2 vaccine: may not be a casualty.**  
*J Hepatol.* 2021; **75**: 728-729  
[View in Article](#)   
[Scopus \(7\)](#) • [PubMed](#) • [Abstract](#) • [Full Text](#) • [Full Text PDF](#) • [Google Scholar](#)
3. Londono M.C. • Gratacos-Gines J. • Saez-Penataro J.  
**Another case of autoimmune hepatitis after SARS-CoV-2 vaccination. Still casualty?.**  
*J Hepatol.* 2021;  
<https://doi.org/10.1016/j.jhep.2021.06.004>  
[View in Article](#)   
[Scopus \(8\)](#) • [PubMed](#) • [Abstract](#) • [Full Text](#) • [Full Text PDF](#) • [Google Scholar](#)
4. Ghielmetti M. • Schaufelberger H.D. • Mieli-Vergani G. • Cerny A. • et al.  
**Acute autoimmune-like hepatitis with atypical anti-mitochondrial antibody after mRNA COVID-19 vaccination: a novel clinical entity?.**  
*J Autoimmun.* 2021; **123**: 102706  
[View in Article](#)   
[Scopus \(4\)](#) • [PubMed](#) • [Crossref](#) • [Google Scholar](#)
5. McShane C. • Kiat C. • Rigby J. • Crosbie O. • et al.  
**ie mRNA COVID-19 vaccine - a rare trigger of Autoimmune Hepatitis?.**  
*Hepatol.* 2021; (S0168-8278(21)01896-1) 



[View in Article](#) 

[Scopus \(7\)](#) • [PubMed](#) • [Abstract](#) • [Full Text](#) • [Full Text PDF](#) • [Google Scholar](#)

6. Tan C.K. • Wong Y.J. • Wang L.M. • Ang T.L. • et al.  
**Autoimmune hepatitis following COVID-19 Vaccination: true causality or mere association?.**

*J Hepatol.* 2021; **18** (S0168-8278(21)00424-4)

[View in Article](#) 

[Google Scholar](#)

7. Lodato F. • Larocca A. • D'Errico A. • et al.  
**An unusual case of cholestatic hepatitis after m-RNABNT162b2 (Comirnaty) SARS-CoV-2 vaccine: coincidence, autoimmunity or drug related liver injury?.**

*J Hepatol.* 2021;

<https://doi.org/10.1016/j.jhep.2021.07.005>

[View in Article](#) 

[Scopus \(3\)](#) • [PubMed](#) • [Abstract](#) • [Full Text](#) • [Full Text PDF](#) • [Google Scholar](#)

8. Grønbaek L. • Otete H. • Ban L. • Crooks C. • et al.  
**Incidence, prevalence and mortality of autoimmune hepatitis in England 1997-2015. A population-based cohort study.**

*Liver Int.* 2020; **40**: 1634-1644

[View in Article](#) 

[Scopus \(13\)](#) • [PubMed](#) • [Crossref](#) • [Google Scholar](#)

9. Vojdani A. • Kharrazian D.  
**Potential antigenic cross-reactivity between SARS-CoV-2 and human tissue with a possible link to an increase in autoimmune diseases.**

*Clin Immunol.* 2020; **217**: 108480

[View in Article](#) 

 [Scopus \(81\)](#) • [PubMed](#) • [Crossref](#) • [Google Scholar](#)



10. Teijaro J.R. • Farber D.L.

**COVID-19 vaccines: modes of immune activation and future challenges.**

*Nat Rev Immunol.* 2021; **21**: 195-197

[View in Article](#) ^

[Scopus \(96\)](#) • [PubMed](#) • [Crossref](#) • [Google Scholar](#)

## Article Info

### Publication History

Published online: October 04, 2021

Accepted: September 26, 2021

Received in revised form: September 22, 2021

Received: September 13, 2021

### Publication stage

In Press Journal Pre-Proof

### Identification

DOI: <https://doi.org/10.1016/j.jhep.2021.09.031>


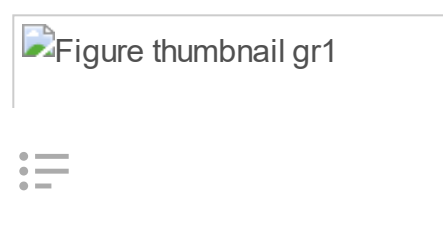
### Copyright

Crown Copyright © 2021 Published by Elsevier B.V. on behalf of European Association for the Study of the Liver. All rights reserved.

### ScienceDirect

[Access this article on ScienceDirect](#)

## Figures





**Fig. 1** Histological findings ...


## Linked Article

[Autoimmune hepatitis developing after coronavirus disease 2019 \(COVID-19\) vaccine: Causality or casualty?](#)

*Journal of Hepatology*, Vol. 75, Issue 1

[Preview](#) • [Full-Text](#) • [PDF](#)

## Related Articles

<a href="#">Home</a>	<a href="#">HCV Miniseries</a>	<a href="#">Researcher Academy</a>	<a href="#">Contact Information</a>	<a href="#">EASL Website</a>
<b>ARTICLES AND ISSUES</b>	<a href="#">Lay Summaries</a>	<a href="#">Submit Your Manuscript</a>	<a href="#">Editorial Board</a>	<a href="#">Join EASL</a>
<a href="#">Articles in Press</a>	<a href="#">Practice Guidelines</a>	<a href="#">Guide for Reviewers</a>	<a href="#">Information for Advertisers</a>	<b>MORE PERIODICALS</b>
<a href="#">Current Issue</a>	<a href="#">Reviews</a>	<a href="#">WebShop</a>	<a href="#">Pricing</a>	<a href="#">Find a Periodical</a>
<a href="#">List of Issues</a>	<a href="#">Snapshots</a>	<b>JOURNAL INFO</b>	<a href="#">New Content Alerts</a>	<a href="#">Go to Product Catalog</a>
<a href="#">Supplements</a>	<a href="#">Thematic Miniseries on NAFLD-derived HCC</a>	<a href="#">About the Journal</a>	<b>NEWS AND MEDIA</b>	<b>FOLLOW US</b>
<b>COLLECTIONS</b>	<b>MANUSCRIPT</b>	<a href="#">Abstracting/Indexing</a>	<a href="#">Embargo Policy</a>	<a href="#">Facebook</a>
<a href="#">ILC 2021</a>	<a href="#">About Open Access</a>	<a href="#">About Open Access</a>	<a href="#">Press Releases</a>	<a href="#">Twitter</a>
<a href="#">Digital Liver Cancer Summit 2021</a>	<a href="#">Author Information</a>		<a href="#">Subscribe</a>	<a href="#">Youtube</a>
 <a href="#">Expert Opinion Series</a>			<b>EASL</b>	



We use cookies to help provide and enhance our service and tailor content. To update your cookie settings, please visit the [Cookie Settings](#) for this site.

Copyright © 2022 Elsevier Inc. except certain content provided by third parties. The content on this site is intended for healthcare professionals.

[Privacy Policy](#) [Terms and Conditions](#) [Accessibility](#) [Help & Contact](#)

