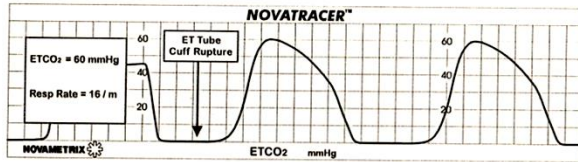
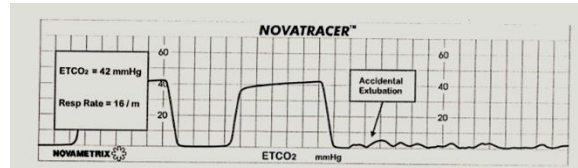


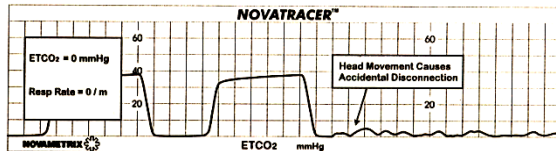
Ruptura del manguito del tubo endotraqueal



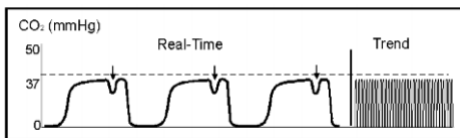
Salida accidental del TE




Desconexión accidental del Paciente



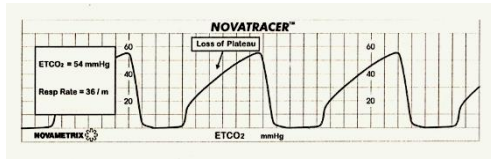
Paciente curarizado. Lucha del paciente contra el respirador.



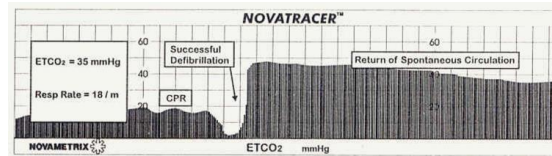
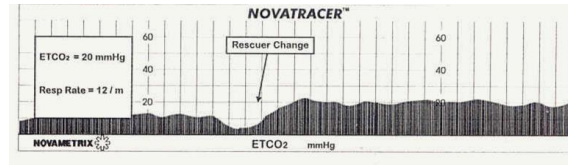
VÁLVULA DEFECTUOSA CON REINHALACIÓN




Broncoespasmo




Evaluación de las maniobras de reanimación cardiopulmonar.



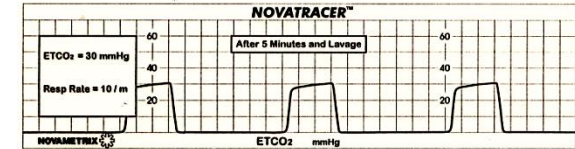
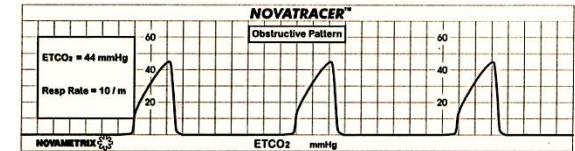
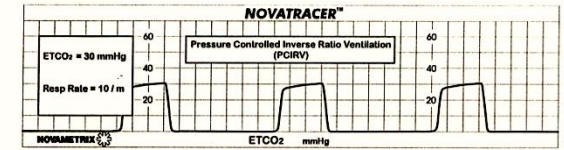
Cuerpo extraño en vía aérea. Broncoespasmo.



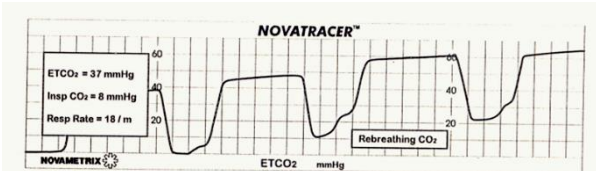
Hiperventilación



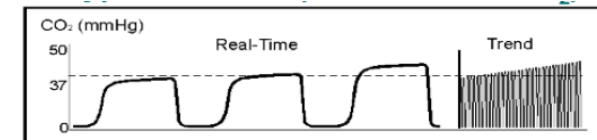
Inversión I:E y TE obstruido



Válvula espiratoria Defectuosa



Incremento en metabolismo. Absorción exógena de CO2 (laparoscopia). Aumento de la temperatura corporal



<https://anestesiastore.com>

