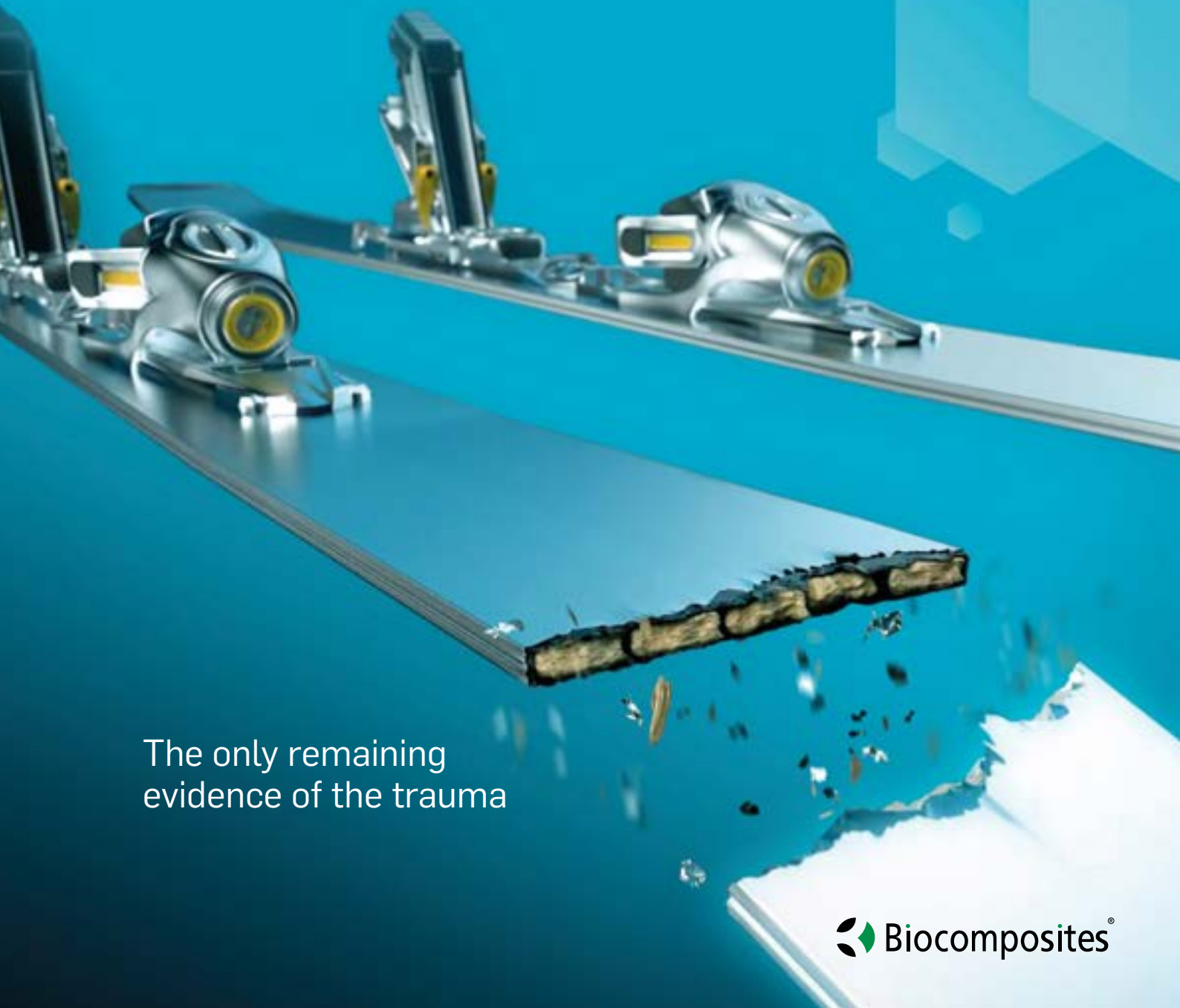

# genex<sup>®</sup>

POWER TO RESTORE WITHOUT LEAVING A TRACE



The only remaining  
evidence of the trauma

 Biocomposites<sup>®</sup>

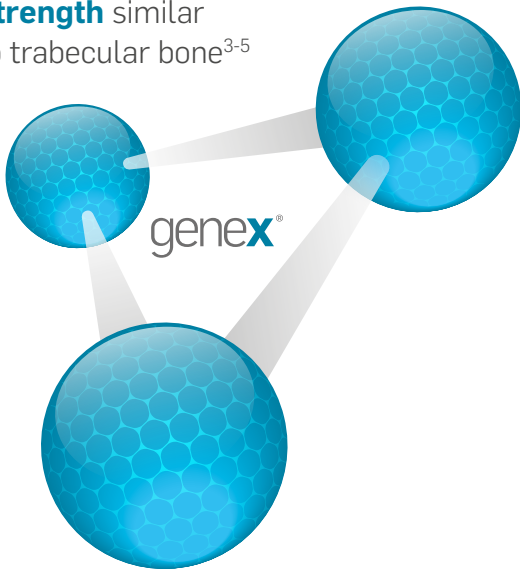
## Perfect partner for trauma

Your choice of synthetic bone graft not only influences the efficiency of each surgical procedure, it has considerable impact on the long-term outcome.

genex is a catalyst for bone healing. It complements the body's natural healing processes, enabling the optimal remodeling of bone architecture to that of native trabecular bone. In 12 months, genex is completely absorbed and remodeled while leaving no foreign artifacts to impair structural integrity.<sup>1,2</sup>

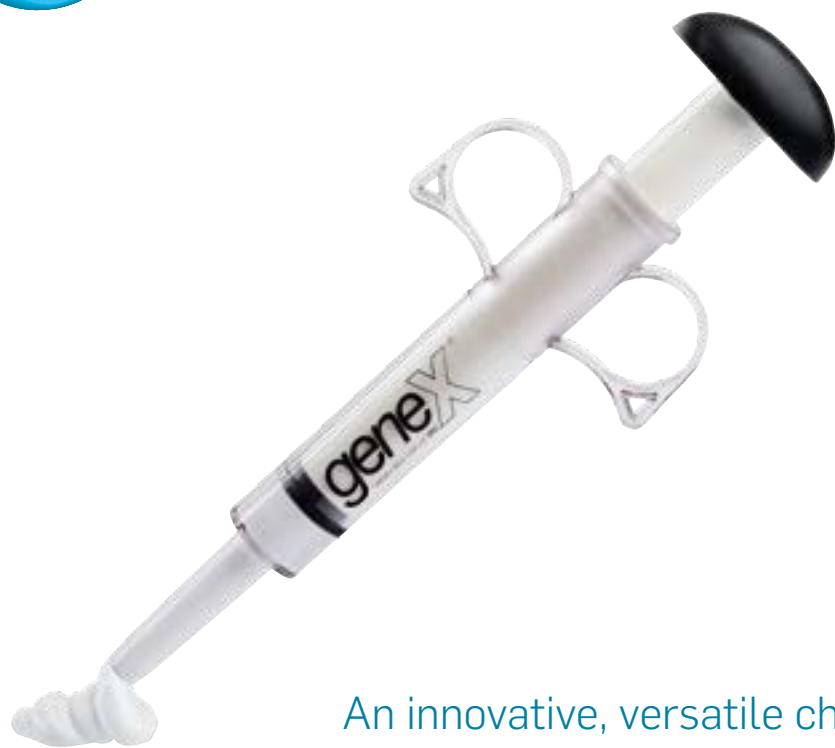✓ designed to promote regeneration of bone in osseous defects

**Strength** similar to trabecular bone<sup>3-5</sup>



**Persistence** 50:50 biphasic absorption supports early bone formation and provides a longer term osteoconductive scaffold to complement bone healing and remodeling

**Workability** predictable consistency and handling experience – like no other



An innovative, versatile choice that supports natural healing, then vanishes without a trace



## Biphasic composite of exceptional purity, balance and characteristics

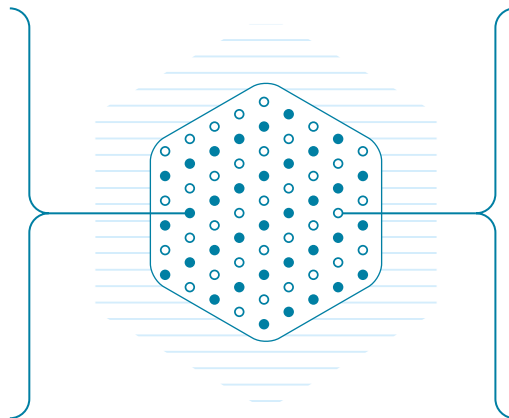
geneX is specifically formulated to provide the desired balance of scaffold strength and persistence in the body with optimum handling, workability and remodeling.

Our proprietary recrystallization and purification methods give geneX its distinct properties and removes impurities.<sup>6</sup>

- ✘ No inflammatory pyrophosphates
- ✘ No slow and non-absorbing compounds such as hydroxyapatite

### 50% calcium sulfate osteoconductive carrier

- Provides early structure
- Absorbs quickly and completely to create pores for early bone ingrowth
- Proprietary DRy26™ recrystallization method



### 50% $\beta$ -tricalcium phosphate osteoconductive scaffold

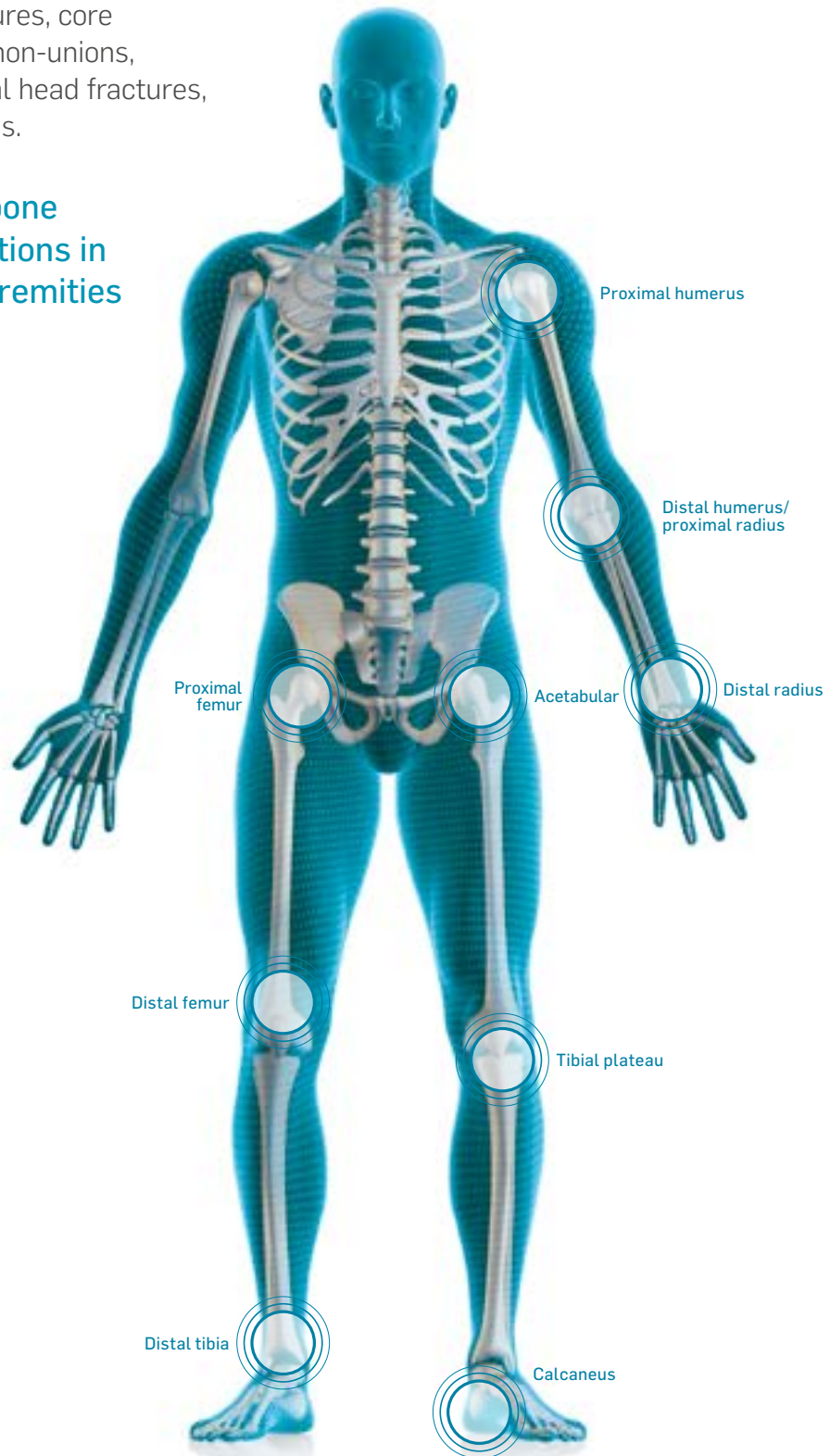
- Facilitates bone healing and remodeling
- Fully absorbs at a rate that complements bone healing
- Proprietary 15 step purification method

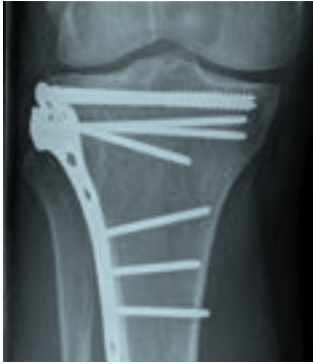Combined in a 50:50 ratio, geneX undergoes further enhancements to give it the ability to enhance osteogenic response and catalyze bone growth

## Strengthens outcomes

genex offers successful long-term outcomes across a range of surgical applications, including tibial plateau fractures, core decompressions, long-bone non-unions, critical bone defects, humeral head fractures, acetabular voids and revisions.

Optimal remodeling of bone across a range of indications in the upper and lower extremities

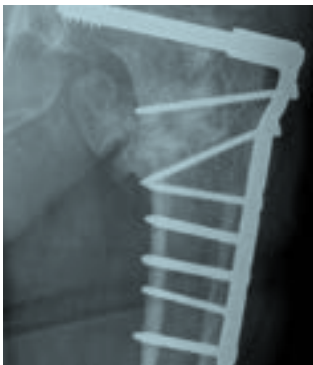




### Tibial plateau fracture<sup>7</sup>

**Patient presented with:** Comminuted Schatzker type II fracture of right leg. X-ray examination revealed 2 large fragments and several small fragments.

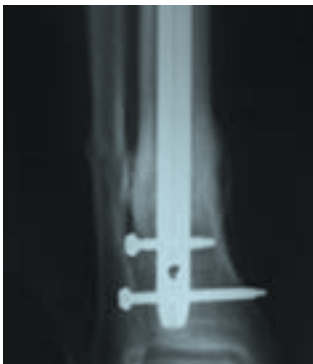**Outcome:** At 15 months' follow-up the fracture had healed and knee was stable, with a range of motion of 0–130°. genex had completely absorbed.



### Proximal femur fracture<sup>2</sup>

**Patient presented with:** Failed intramedullary nailing of an extracapsular neck of femur fracture. Patient complained of prominent metalwork and pain.

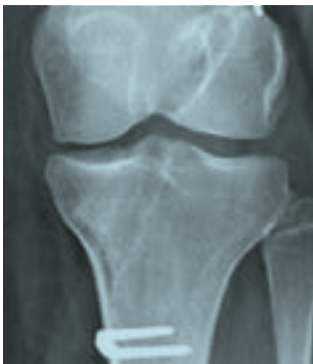**Outcome:** At 12 months' follow-up the fracture had healed with complete absorption of genex. Patient had a good range of hip motion and was able to walk and manage stairs.



### Distal tibia non-union<sup>8</sup>

**Patient presented with:** Healed fibula with a non-union of the distal tibia and a fracture through the nail, 19 months after the initial operation.

**Outcome:** At 10 months' follow-up the non-union had healed completely, patient had fully recovered and was scheduled to have the intramedullary nail removed.



### Single stage revision ACL reconstruction<sup>9</sup>

**Patient presented with:** Malposition of the femoral tunnels following failed ACL reconstruction.

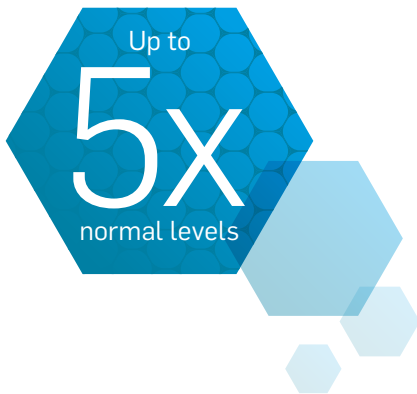
**Outcome:** At 7 months' follow-up bone reformation was seen with genex. At 2 years' follow-up the patient had a normal ACL examination and returned to day-to-day activities and some active sports.

## Completely absorbs to leave no trace

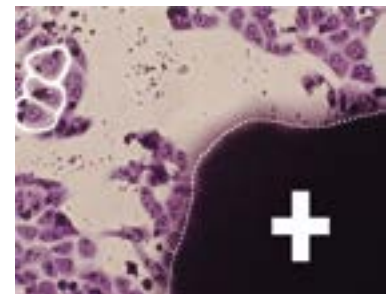
geneX is a precisely balanced  $\beta$ -tricalcium phosphate/calcium sulfate hemihydrate compound with distinct design properties:

- ✓ contains no hydroxyapatite (HA)
- ✓ negatively charged surface chemistry
- ✓ compressive strength similar to trabecular bone
- ✓ enhances osteogenic response
- ✓ completely absorbed within 12 months
- ✓ restores strong healthy bone

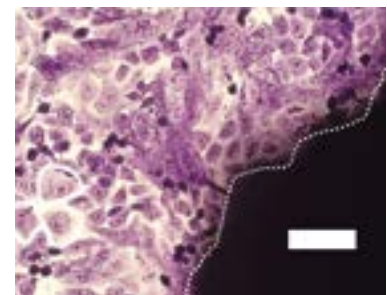
## Enhances the osteogenic response to accelerate bone growth<sup>10</sup>



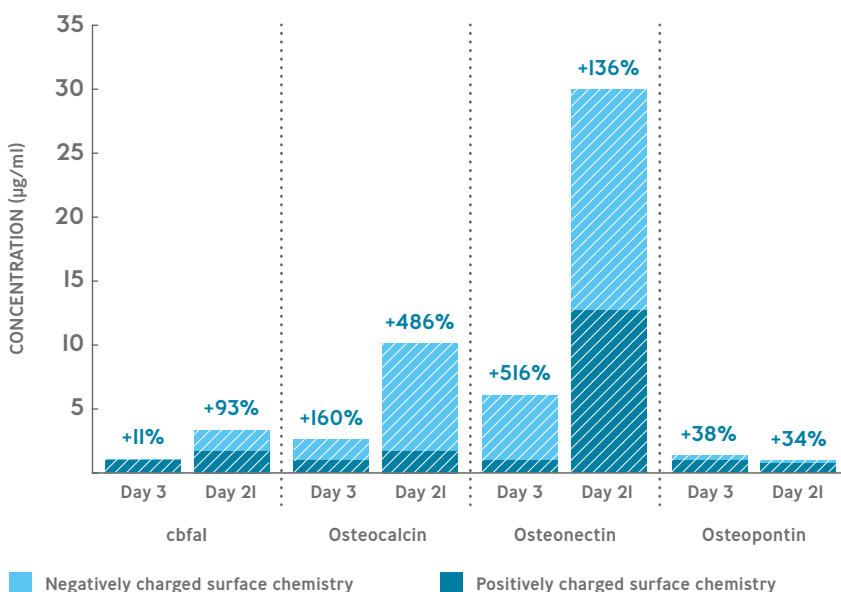
*In-vitro* human osteoblast culture, 3 days<sup>11</sup>



Positive surface charge



Negative surface charge



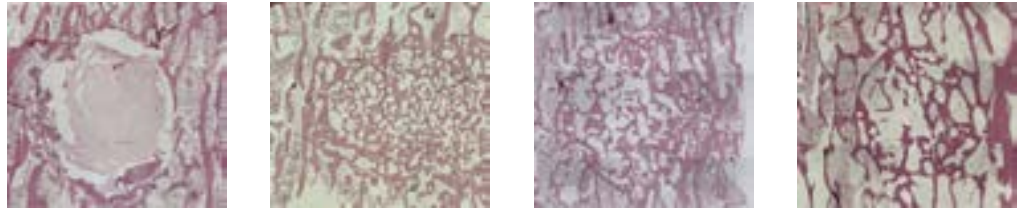


## Completely absorbed within 12 months<sup>1,2</sup>

geneX contains no hydroxyapatite. HA can only be absorbed at 1–2% per year<sup>12</sup>

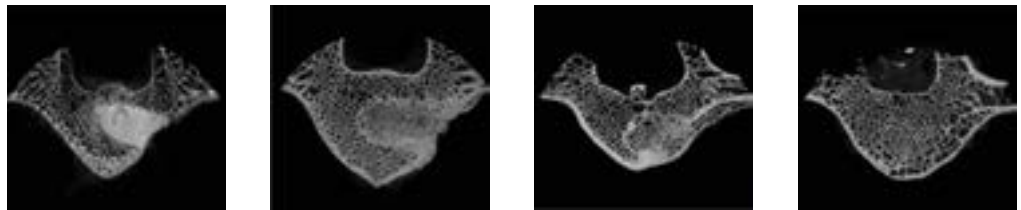
geneX

Decalcified histology  
H&E stain

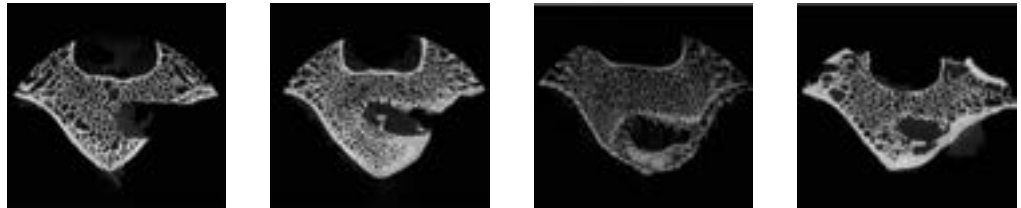


geneX

Micro-CT



Sham control  
Micro-CT



geneX implantation

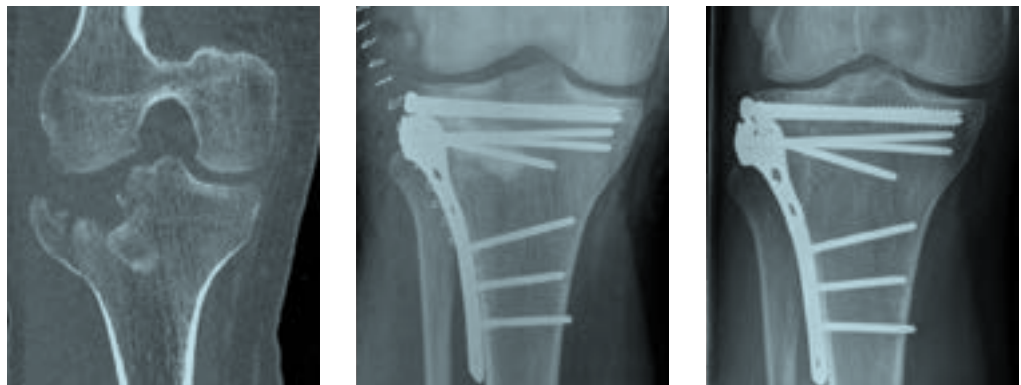8 weeks

16 weeks

36 weeks

## Restores strong healthy bone within a clinically relevant timeframe<sup>7</sup>

geneX restores bone to normal trabecular structure<sup>1</sup>



Tibial plateau fracture

Post-operative

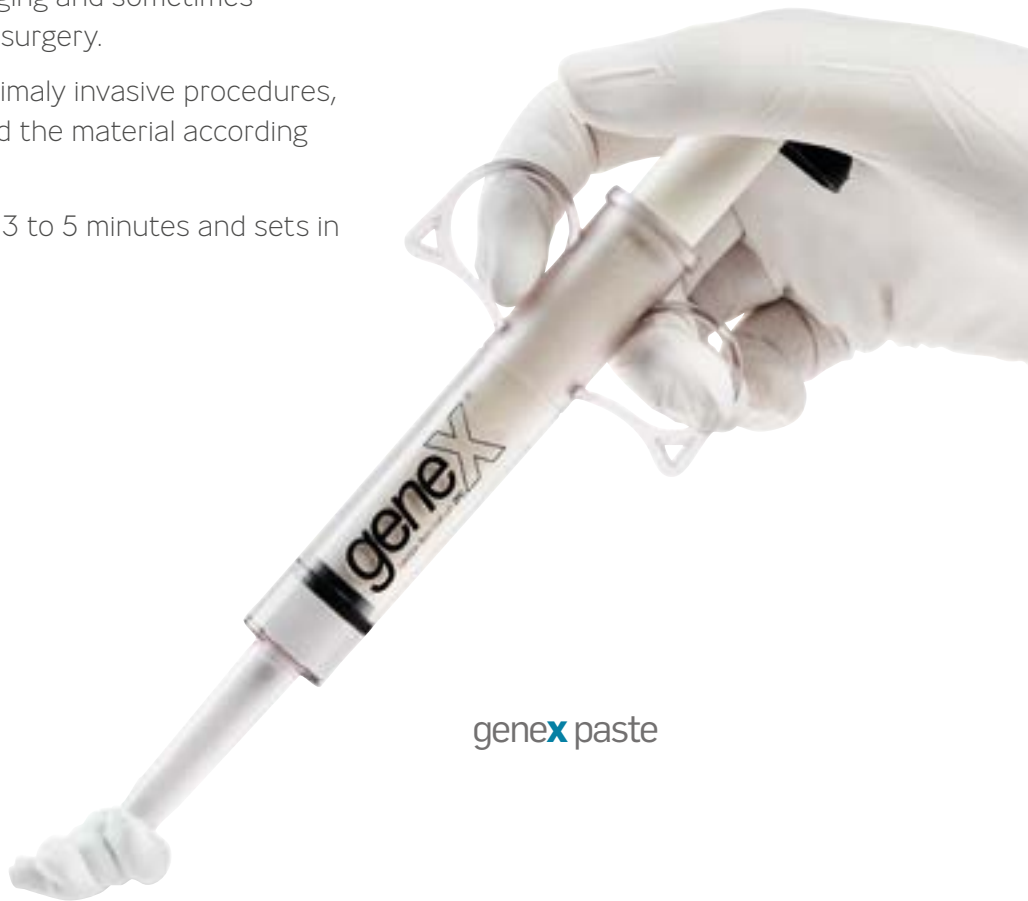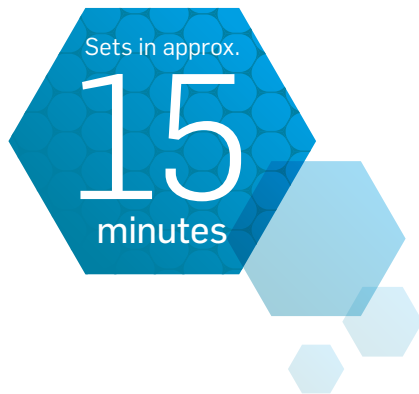15 months

## Unrivalled flexibility for delivery and application

With one of the most comprehensive bone graft substitute systems at your fingertips, **genex** equips you with everything you need to adapt to the wide ranging and sometimes unpredictable demands of trauma surgery.

From difficult-to-reach sites or minimally invasive procedures, **genex** enables you to inject or mold the material according to your chosen technique.

**genex paste** has a working time of 3 to 5 minutes and sets in approximately 15 minutes.



genex paste

## Overview

### genex

Paste volume	Setting times	In the pack	Order code
5cc	15 minutes	<ul style="list-style-type: none"> <li>• Powder and solution</li> <li>• Syringe</li> <li>• Spatula</li> </ul>	900-005
10cc	15 minutes		900-010





## Case study

### Courtesy of Mr Hemant K Sharma

Consultant Orthopaedic Surgeon, Hull, UK

#### Clinical particulars

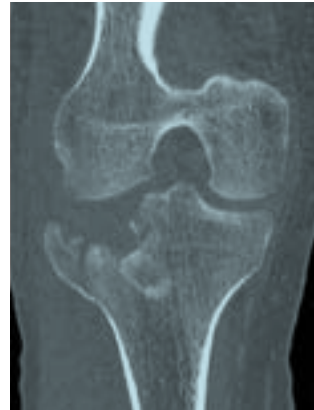22-year-old male presented with a comminuted Schatzker type II fracture of right leg. X-ray examination revealed 2 large fragments and several small fragments.

#### Treatment

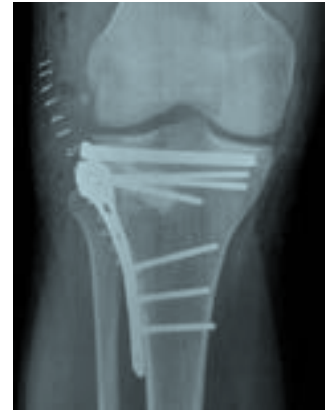Using an anterolateral approach, the lateral fragment was rotated to open the fracture, fragments elevated and held with temporary K-wires. The joint was visualized through submeniscal approach. 7cc of geneX paste was implanted and the lateral fragment closed with a clamp. 2 partially threaded 6.5mm cancellous screws were placed subchondrally just below the elevated intra-articular segment. Locking plate and a combination of locking and non-locking screws were placed.

#### Outcome

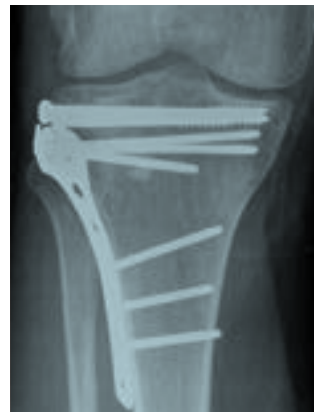At 15 months' follow-up the fracture had healed with complete absorption and remodeling of geneX. The knee was stable, with a range of motion of 0–130°. Patient reported normal function with occasional clicking and aching at the end of the day, with some discomfort at lateral joint line.



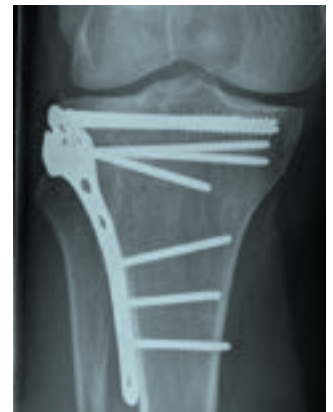Presentation – CT scan



Post-operative



6 months



15 months

## Case study

Courtesy of Mr Aamer Nisar  
and Mr Shiva Gopal

Consultant Orthopaedic Surgeons, Hull, UK

### Clinical particulars

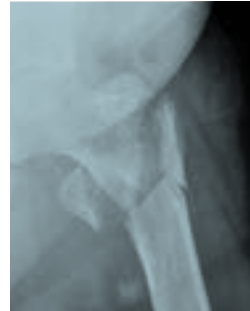86-year-old male sustained a comminuted extracapsular fracture of left proximal femur following a fall. This was nailed, however, subsequently at 4 months the screw backed out and patient complained of prominent metalwork and pain.

### Treatment

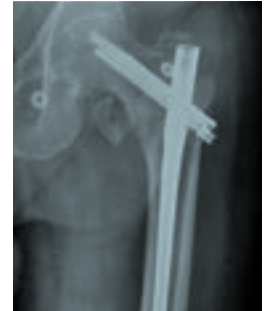CT suggested partial union. Following Multidisciplinary Team discussion, revision of the fixation was planned. Nail was removed and examination suggested the fracture site was still mobile. Bone grafts were harvested using a reamer system. The autologous grafts and geneX paste were then implanted at the fracture site, and the fracture was plated with a combination of locking and non-locking screws. Patient was instructed to be touch weight-bearing for 6 weeks.

### Outcome

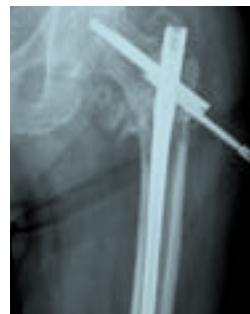At 12 months' follow-up the fracture had healed with complete absorption and remodeling of geneX. Patient had a good range of hip motion and was able to walk independently and manage stairs.



Presentation



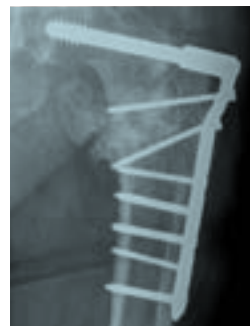Post-operative



4 months –  
screw backing out



4 months



1 year post-revision



## Case study

### Courtesy of Professor James B Richardson

Consultant Orthopaedic Surgeon/Professor of Orthopaedics, Oswestry, Shropshire, UK

#### Clinical particulars

34-year-old male initially treated for right tibia and fibula fracture with a bilateral intramedullary nail, presented 19 months after the initial operation with acute pain around the fracture site. X-ray examination revealed a healed fibula with a non-union of the distal tibia and a fracture through the nail.

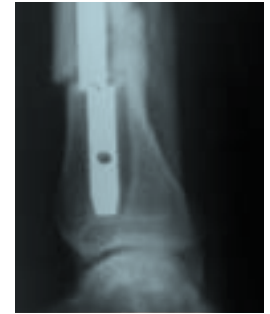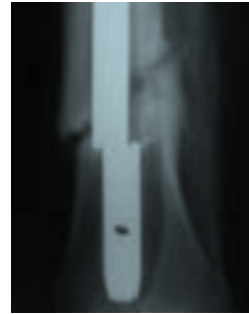
#### Treatment

The broken nail was extracted and a new nail inserted and locked distally with 2 locking bolts. The fracture site was decorticated and packed with geneX paste. Closure was achieved with vicryl and a drain was placed over the proximal wound. The patient demonstrated good movement of toes and right ankle. Mobilization to partial and full weight-bearing was recommended as soon as the patient was comfortable to do so.

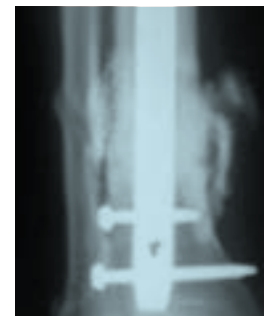
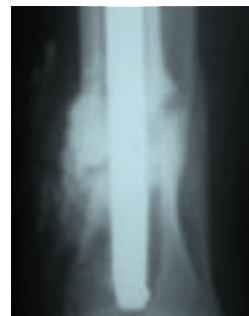#### Outcome

At 3 months' follow-up the wound was clean and the bone appeared to be healing satisfactorily. The patient had mobilized fully and was extremely pleased with the outcome.

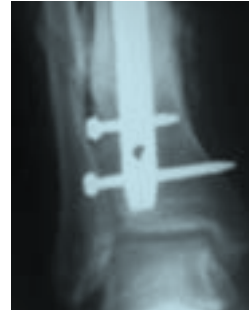At 10 months' follow-up the non-union had healed completely. The patient had fully recovered and was scheduled to have the intramedullary nail removed.



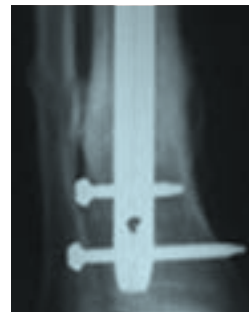
Presentation



Post-operative



3 months



10 months

## Case study

### Courtesy of Mr Peter Thompson

Consultant Orthopaedic Surgeon,  
Coventry & Warwickshire, UK

#### Clinical particulars

24-year-old female had a hamstring ACL reconstruction in 2006, revision in 2009 and graft failure in 2016. Revision surgery was planned using a graft from the opposite leg.

CT scan confirmed malposition of the femoral tunnels: one was very anterior (type III) and the other (type II) would breakthrough upon drilling an anatomical femoral socket. The double tibial tunnel also caused a 1.7cm diameter cavity (Fig. 3).

#### Treatment

Single-stage revision ACL reconstruction was possible by filling the type II femoral tunnel and tibial cavity with genex paste before drilling tunnels in an anatomical position. The new femoral socket partly overlaps the previous tunnel filled with genex (Fig. 4).

#### Outcome

Post-operative x-rays (Fig. 5, 6) show graft fixation with a suspensory button on the femur, a bioabsorbable interference screw and soft tissue staple on the tibia. genex can be seen in the tunnels of the distal femur and proximal tibia (arrows). Bone reformation is seen at 7 months (Fig. 7, 8).

Normal ACL examination with return to day-to-day activity and some active sports 2 years post-operatively.

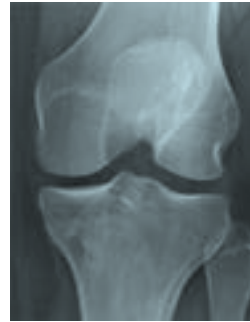

Figure 1

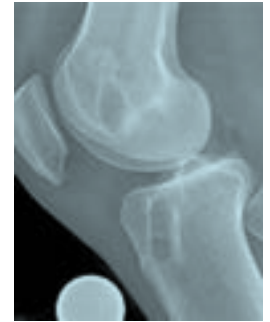

Figure 2

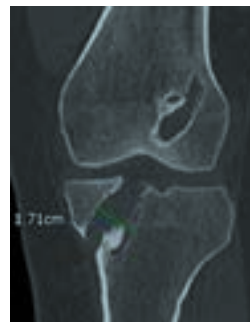


Figure 3

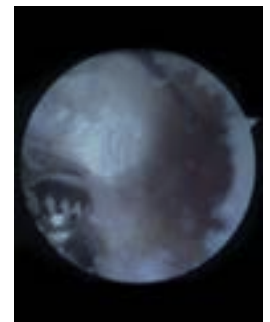

Figure 4

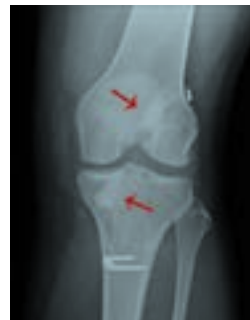

Figure 5

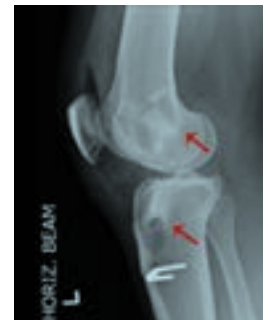

Figure 6

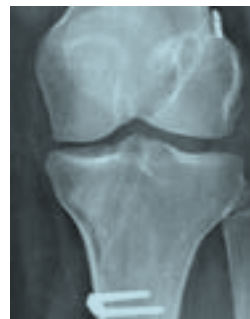

Figure 7

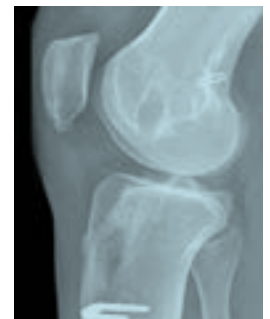
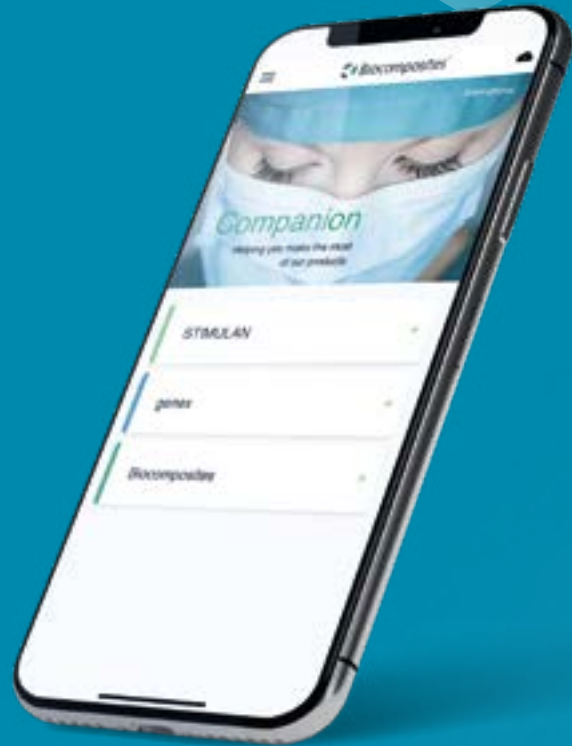
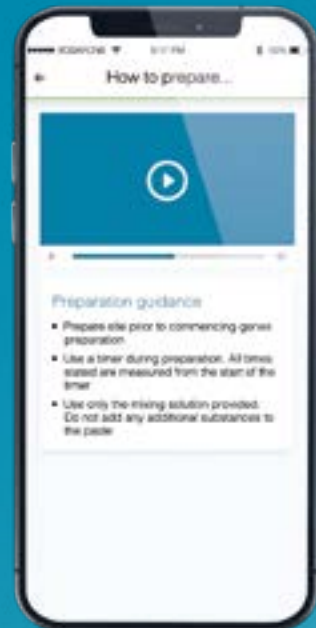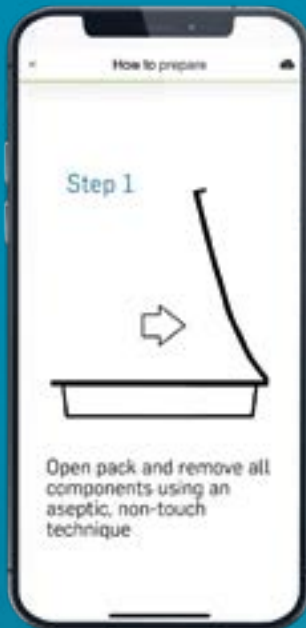
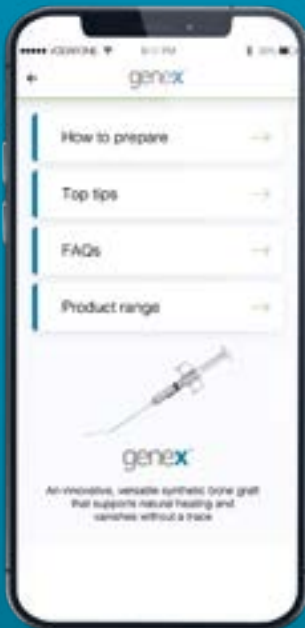Figure 8

# The Biocomposites companion

Your essential guide to making the most of **genex** – all in one straightforward app. Our accessible app provides all the information you need to meet different clinical demands when using **genex**. From surgeons' tips to how-to videos, this is the expert support tool you need, right at your fingertips.



- ✓ How to prepare: step-by-step videos
- ✓ Top tips: tried and tested advice for surgeons
- ✓ FAQ's: common questions answered
- ✓ Product range: what's available



To download your Biocomposites Companion, simply scan the QR code.



## References

1. Yang HL et al. Bone healing response to a synthetic calcium sulfate/  $\beta$ -tricalcium phosphate graft material in a sheep vertebral body defect model. *J Biomed Mater Res B Appl Biomater* 2012;100B(7):1911–21.
2. Clinical case study: Mr A Nisar and Mr S Gopal; Proximal femur fracture, Data on file.
3. Biocomposites internal testing: Biomaterials Compressive strength; Applicable methodology ISO/DIS 18531:2015(E) Implant for surgery – Calcium phosphate bioceramics – Characterization of hardening bone paste materials. 2015, MA0390R1.
4. Misch CE, Qu Z, Bidez MW. Mechanical properties of trabecular bone in the human mandible: implications for dental implant treatment planning and surgical placement. *J Oral Maxillofac Surg.* 1999 Jun;57(6):700-6; discussion 706-8. doi: 10.1016/s0278-2391(99)90437-8. PMID: 10368096.
5. Dunham CE, Takaki SE, Johnson JA, Dunning CE. Mechanical properties of cancellous bone of the distal humerus. *Clin Biomech (Bristol, Avon).* 2005 Oct;20(8):834–8. doi: 10.1016/j.clinbiomech.2005.05.014. PMID: 16023773.
6. Biocomposites internal and external testing: genex technical file: Section 3.1.7 (Rev1) Final product specification, 2022.
7. Clinical case study: Mr HK Sharma; Tibial plateau fracture, Data on file.
8. Clinical case study: Prof JB Richardson; Distal tibia non-union, Data on file.
9. Clinical case study: Mr P Thompson; Single stage revision ACL reconstruction: Data on file.
10. Cooper JJ et al. Enhancing the osteogenic potential of bioabsorbable implants through control of surface charge. Presented at the Society for Biomaterials 2007 Annual Meeting, April, 2007: Chicago, Illinois, USA.
11. J J Cooper, J A Hunt., The Significance of Zeta Potential in Osteogenesis. Poster presented at Society for Biomaterials 2006 Annual Meeting, Pennsylvania, USA.
12. Pina S, Ferreira JMF. Bioresorbable plates and screws for clinical applications: A review. *J Healthcare Engineering* 2012;3(2):243–60.

For indications, contraindications, warnings and precautions see Instructions for Use.

©2022, Biocomposites, genex and Power to Restore are trademarks/registered trademarks of Biocomposites Ltd. All rights reserved. No unauthorized copying, reproduction, distributing or re-publication is allowed unless prior written permission is granted by the owner, Biocomposites Ltd.

Patents granted: EP 1390086 B1, US 8632796, CN ZL02809194.9, US 8496955





## POWER TO RESTORE WITHOUT LEAVING A TRACE

---

✓ Perfect partner for trauma

---

✓ Optimized to be completely absorbed and remodeled<sup>1,2</sup>

---

✓ Versatility at your fingertips

---

At Biocomposites, we are proud to be driving improved outcomes across a wide range of clinical applications for patients and surgeons.

Our team of specialists is singularly focused on the development of innovative calcium compounds for surgical use.

With over 30 years' experience and an unrivaled dedication to quality, the products we research, engineer and manufacture are at the forefront of calcium technology.



All Biocomposites' products are engineered, manufactured and shipped from our facilities in Keele, UK.