



OUTCOMES OF FLEXIBLE PARTIAL DENTURE WITH ESTHETIC CLASPS AS AN IMPLANT PROVISIONAL PROSTHESIS IN THE ANTEROR MAXILLA

Mostafa Helmy Mostafa Ahmed*

ABSTRACT

Introduction: A patient submitted to delayed loading protocol ought to be given a provisional restoration at the interval between the first and second phase of implant therapy. This provisional restoration is made to satisfy the prerequisites of mastication, aesthetics, & to reduce the psychological trauma associated with teeth loss. **The reason for this examination** was to assess clinical & radiographic outcomes of the provisionally-used flexible removable partial denture (RPD) on both; the implants placed as well as the adjacent abutment teeth.

Materials & methods: For the outcome of this clinical research study, ten patients with lost teeth in the anterior maxilla were treated by implant placement. Directly following sutures removal & gingival healing, every single patient received new flexible provisional RPD with aesthetic clasps (resting on adjacent abutment teeth) being fabricated in the usual manner. and mandibular complete dentures prior to implant placement. After common denture delivery adjustments, every patient was instructed to use the denture in a conventional manner for six months, with a follow-up appointment every month. After six months of implants placement (to ensure complete implants osseointegration), patients completed the implant restoration phase till receiving anterior fixed restorations. Clinical & radiographic outcomes for the implants and the abutments were measured Three times (at time of insertion, three months and six months, respectively)

Results: For parametric data; Repeated measures Analysis of Variance (ANOVA) was used to study the changes by time, while for non-parametric data; Friedman's test was used to study the changes by time. Those studies revealed that: There was no statistically significant changes in mean clinical & radiographic measurements around both the implants & the abutments throughout the whole study period.

Conclusion: Using flexible RPD with aesthetic clasps as a provisional restoration during the period of implants osseointegration was favourable and preserved the health of supporting structures of the abutment teeth as well as the implants, in addition to enhanced aesthetics & psychological confidence of the patients.

KEYWORDS: Flexible denture, Acetal resin, Dental implants, Provisional restoration, aesthetics

* Lecturer of Removable Prosthodontics, Faculty of Dentistry, Cairo University.

INTRODUCTION

For lost anterior teeth in the maxilla, Different treatment approaches had been proposed; such as resin-bonded fixed partial denture, removable partial denture, conventional fixed partial denture, as well as dental implants. ⁽¹⁾

The management of such cases using osseointegrated implants is considered one of the best treatment modalities, where dental implants have become a predictable treatment modality for totally or partially edentulous patients. ⁽²⁾

Dental implants were classified according to the time of loading into immediate, early and delayed loading.⁽³⁻⁵⁾ A patient submitted to delayed loading protocol has to be provided with a provisional restoration at the interval between the first and second stage of implant therapy. This provisional restoration is made to enhance mastication, aesthetics, speech as well as to reduce the psychological trauma associated with teeth loss. ⁽⁶⁻¹⁰⁾

An approach has been proposed for provisional restoration, which is the use of flexible RPD with aesthetic clasps that might be of value when used during the osseointegration period. ⁽¹¹⁻¹⁷⁾

This investigation will evaluate both clinical & radiographic outcomes of the provisionally-used flexible removable partial denture on both; the implants placed as well as the adjacent abutment teeth.

MATERIALS AND METHODS

Ten patients with lost or non-restorable anterior maxillary teeth were selected from the outpatient clinic of the prosthodontic department, Faculty of Dentistry, Cairo University.

Criteria of patients' selection:

- Middle-aged males or females between 20-35 years with an average of 25 years old.
- Maxillary anterior teeth (central incisors and/or lateral incisors), either non-restorable (indicated for extraction) or being lost (due to trauma or previous extraction). (*Fig.1, 2*)

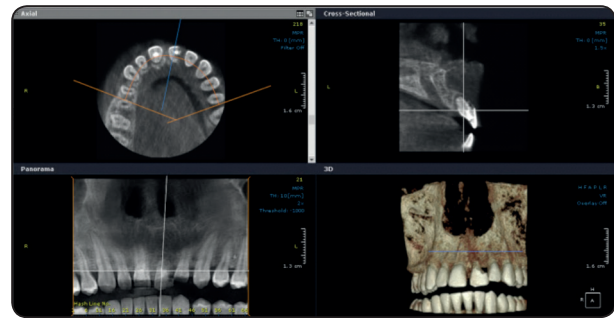


Fig. (1) Non-restorable central incisor (s) in maxilla (indicated for extraction).

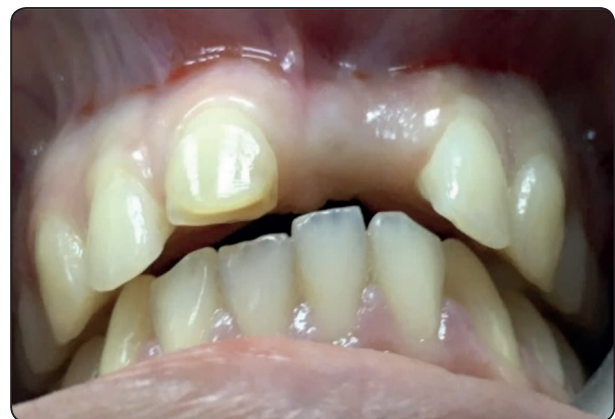

Fig. (2) Missing left central incisor in maxilla.

- Residual bone with enough width for gaining implant anchorage.
- Integrated opposing dentulous arch.
- Healthy periodontal condition of the abutments.
- Patients were free from any systemic diseases that might influence the bone healing quality.
- Patients with reliable oral hygiene.
- Patients with Angle's class I maxillo-mandibular relationship with accepted occlusion & Free from bad oral habits (e.g. bruxism).
- Uncooperative patients were avoided.

Patient examination:

The patients were asked for their approval to the conduction of the research.

After taking full patient's personal, medical and dental history, each patient received a thorough clinical and radiographic examination.

Intra-oral examination:

- i) **Visual examination:** The mucosa of the edentulous area was examined to detect any sign of inflammation. Also, the presence of super-eruption of the mandibular tooth opposing the edentulous area was observed.
- ii) **Digital examination:** The mucoperiosteum covering the edentulous area was palpated to detect the presence of any flabbiness of the tissue or sharp ridge. The width of the ridge labio-lingually was clinically evaluated by palpating the ridge between the thumb and index fingers.
- iii) **Abutment examination:** Abutments bounding the edentulous area were evaluated regarding caries, mobility, periodontal condition and drifting of teeth.

Construction of diagnostic casts:

Upper and lower alginate impressions* were made and poured into stone plaster** to obtain diagnostic casts that were mounted on a fixed condylar path articulator using an inter-occlusal wax record.

Radiographic evaluation:

CBCT as well as Panoramic radiographs were made for all patients to evaluate the following:

- Quality of the bone at the edentulous ridge area.
- Presence or absence of remaining roots or any other pathological lesions.
- Amount of the bone available in the middle of the edentulous ridge area between the crest of the alveolar ridge and the nasal floor.

Construction of Flexible RPD with aesthetic clasps:

Following the surgery and after suture removal with assurance of adequate healing of the soft tissues,

- A stock tray appropriate to the patient arch was loaded with putty rubber base impression*** and inserted in the patient mouth.
- After complete setting of the impression, the tray was removed and the area of interest was slightly relived and then loaded with a light body rubber base impression*** and re-inserted into the patient mouth.
- Following complete setting of the impression, the tray had removed and the impression was detected for accuracy and then disinfected****. Meanwhile, a bite registration record for the edentulous area had been taken as well as an alginate impression of the opposing lower arch was obtained.
- After one hour, the impression was poured using extra-hard stone to obtain the master cast on which the design of the provisional restoration was drawn. Then, the master cast had been duplicated to obtain the refractory cast upon which the metallic provisional restoration was made.
- Following the usual steps of construction, the flexible RPD was inserted into the patient mouth & checked for accuracy, retention, stability and appearance.

Pre-surgical steps:

- A preoperative CBCT x-ray was made to determine the required implant length & diameter. In addition to construction of an accurate surgical stent.

* Cavex RW Harlem, Holland

** Gludur Gulini Chemei GmbH, Germany.

***Panasil, kettenbach, Germany.

****Disinfectant spray, Dentsply, France.

- The surgical stent was sterilized chemically* to be used during surgery & the patient was instructed to take a prophylactic antibiotic pre-operatively** and to rinse with chlorohexidine mouth wash*** 4 hours before surgery.

Construction of the radiographic template:

- On the cast, all undercuts were blocked out using modelling wax**** & the cast was painted with a separating medium. A self-cured acrylic resin was mixed and applied at dough stage on the stone cast to cover the edentulous area as well as the anterior and the posterior abutments. Then, a Rinn XCP Anterior bite block***** was hard-pushed on the acrylic resin with the film backing plate parallel to the long axis of the abutments & then the acrylic resin was presented inside the side holes of the bite block. Finally, the template was finished, polished and tried in the patient's mouth to test its precision and to adjust any overextension or pressure areas that might disturb accurate fitting of the template.
- The acrylic template was reserved in water to be used throughout the follow-up periods.

SURGICAL PROCEDURES

Two-stage surgery was followed and the flexible provisional prosthesis was inserted during the healing period in-between:

First surgical phase:

- The entire surgical instruments were autoclaved.
- The patient was asked to gargle with chlorohexidine mouth wash*****.
- The surgical place as well as the circumoral tissues were also disinfected by wiping them with betadine solution.

* Micro 10, A.B. Pharma, Switzerland.

** Augmentin 625mg Beecham MUP.

*** Listerine mouthwash, USA.

**** Cavex, Harlem, Holland.

***** Rinn Corporation, XCP instruments for extension cone paralleling technique.

***** Betadine MW, El-Nil.

***** Ubestesin, 3M ESPE, Germany.

***** ROOTT dental implant, Trate AG, Switzerland.

- The surgical template was sterilized by submerging it in 2% glutaraldehyde solution for twenty minutes.
- Infiltration anaesthesia was given at the surgical site using 4% articaine anaesthetic solution*****. Also, field block anaesthesia was applied to diminish the bleeding as much as possible.
- A full thickness mucoperiosteal flap was made at the edentulous area, where the incision was done slightly toward the palatal side of the ridge for about two millimetres. The mesial and distal lines of the incision were done with great conservative approach to preserve the adjacent interdental papillae. (*Fig.3*)
- The flap was reflected using a sharp mucoperiosteal elevator and the bone file was used for filing the bone in one direction. The surgical template was carefully inserted & the drilling was performed according to the implant system's instructions till complete preparation of the osteotomy site.

Implant insertion:

- The sterile box of the implant***** was unwrapped, and then the inner vial was also opened. (*Fig.4*)
- The implant osteotomy was washed thoroughly using sterile saline solution.
- The sterile implant was introduced into its site by screwing it using moderate finger pressure [self-tapping]. Once resistance was felt, the abutment was unscrewed from the implant fixture & the ratchet wrench was adapted to the implant and the screwing process was continued. (*Fig.5*)

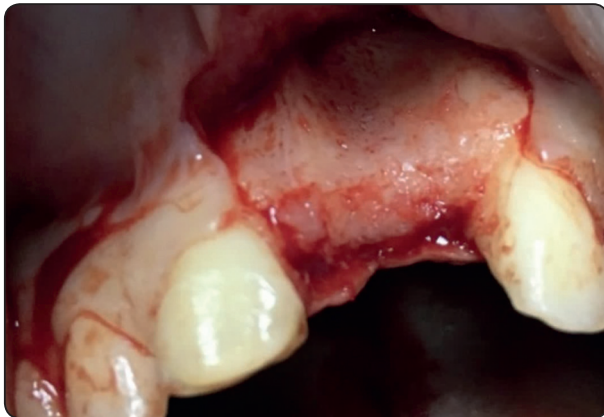


Fig. (3): A full thickness mucoperiosteal flap reflection.

- The screwing process was stopped when the implant becomes flushed with the crest of the bone or preferably 0.5mm below the crestal bone level.

The universal hex driver was then introduced to install the covering screw onto the implant in a clock wise direction.

- ❖ *N.B: some cases required bone augmentation to build insufficient labial bone &/or to cover any exposed implant threads. (Fig.6)*

- The mucoperiosteal flap was repositioned to its place and sutured using (0000) black silk sutures. (Fig.7)



Fig. (4): The implant in a sterile double packing & after opening.

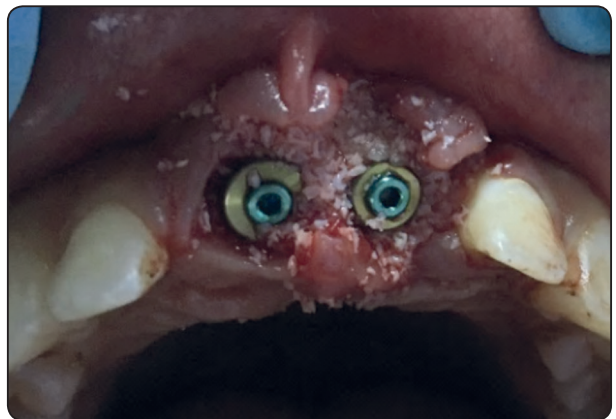

Fig. (6): Bone augmentation to cover any exposed implant threads.

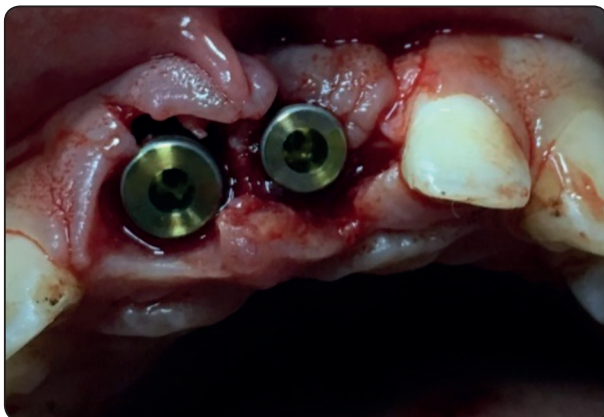


Fig. (5): Implants Installation.

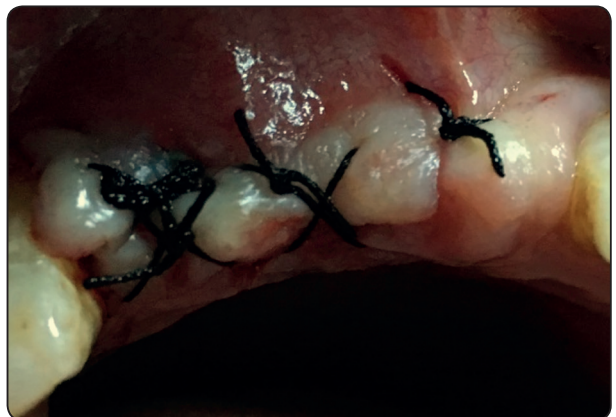


Fig. (7): Closure of the mucoperiosteal flap with interrupted sutures.

- The radiographic template was then introduced into the patient's mouth, seated over the maxillary teeth and checked for accuracy & stability in place.
- The imaging plate of the Digora system inside its protective plastic shield was held in its exact position in the bite block and the whole assembly was fitted to the indicator arm & reinserted into the patient's mouth. Then, the indicator arm was fitted to the external plastic aiming ring. A long cone, sixteen inches in length was mounted to the X-ray tube and the plastic aiming ring was fixed flush-ended with the round end of the long cone.
- Finally, a radiographic picture was obtained for the implants and read out by the Digora computerized system to calculate the first radiographic readings. (Fig. 8)
- Common post-operative instructions were given to the patient & The sutures were removed after seven days.
- The patients could wear their flexible RPD directly after suture removal with assurance of adequate healing of the soft tissues. In addition to slight relief of the denture fitting surface from the labial flange. (Fig.9)
- The patient was then asked for a recall appointment after three months, for the second clinical & radiographic assessments.

a) Second surgical phase:

Following six months, the patient was recalled and the following procedures were carried out:

- A periapical radiograph was made for the implant to ensure osseointegration.
- The same procedures of obtaining the clinical as well as the radiographic readings were performed to record The Third readings.
- Infiltration anaesthesia was given at the surgical site.
- A probe was used to determine the exact position of the head of the implant guided by the surgical template.

- The universal hex driver was used to unscrew the covering screw of the implant. The gingival former was then introduced, fixed onto the implant using the universal hex driver. Then, left in the patient's mouth for ten days to obtain the normal gingival contour. (Fig.10)

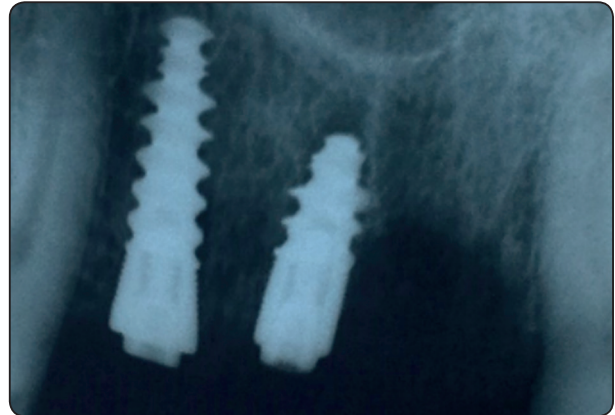


Fig. (8): Post-operative periapical radiograph.

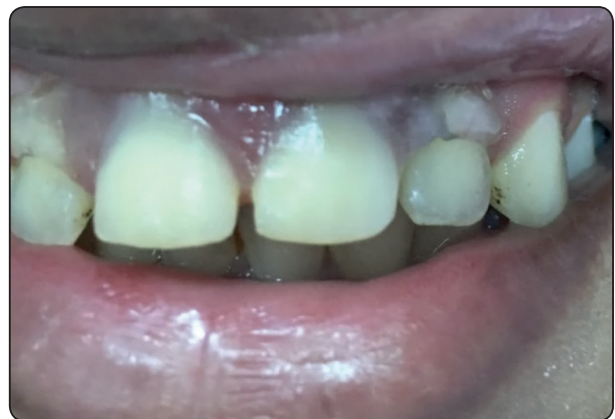

Fig. (9): The flexible RPD with Aesthetic clasps intraorally.

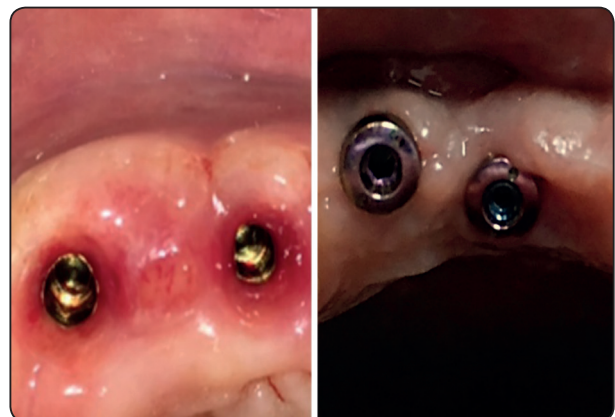

Fig. (10): Healing of gingiva by the gingival former.

- Patients were then recalled, unscrewing the gingival former and Extended transfer mounts were fixed to the implant fixture using the universal hex driver & gently tightened to ensure intimate fitting over the hex of the implant. **(Fig.11)**
- An open-tray impression was made as follows; a perforated stock tray of suitable size was selected & a window was created opposite to the transfer mounts and slightly wider mesio-distally. Rapid dryness of the surgical field was accomplished using pieces of gauze. Then, a light-body impression material was injected around the implants necks and the transfer mounts, followed by insertion of the stock tray loaded by a putty rubber base impression material in the patient's mouth. The tray was secured in place and detected for complete seating and finally, the open-tray impression making was completed by manipulating the oral tissues in the usual manner. Following complete setting of the impression material, the screw driver was utilized to unscrew those mounts from the implant fixtures. The tray was then removed from the patient's mouth and the impression was cleaned, dried and checked for its accuracy in addition to enclosing the transfer mounts accurately in their places.
- The covering screws are placed onto the implants & secured in place & the patient wear his flexible denture.
- The implant analogues were fitted accurately into their corresponding mounts in the impression, using the screw driver.
- A small cotton pellet was utilized to varnish the impression surfaces surrounding the analogues with Vaseline. Then, a gingival mimic was created around the analogues using a plastic impression syringe loaded with a rubber base impression material of a different type and colour. The impression was then poured utilizing extra-hard dental stone to create the master cast with a well-trimmed base and borders.

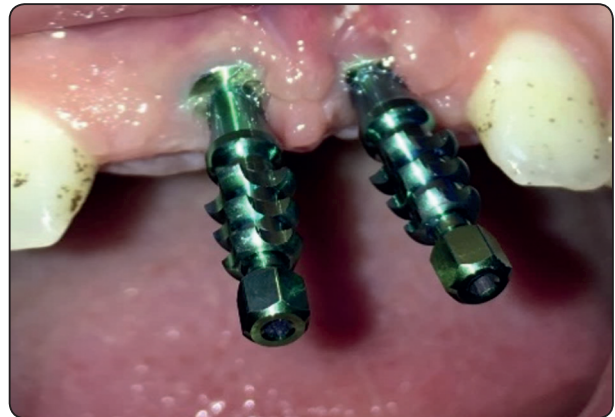

Fig. (11): Extended transfer mounts attached to the implant fixtures.

- In the laboratory, angulated zirconium screw-retained abutments on were fabricated by the aid of CAD/CAM software and milling machine. Then, the custom-made zirconium abutments were tried in the patient's mouth, prepared for accurate finish line & marginal adaptation. **(Fig.12)**

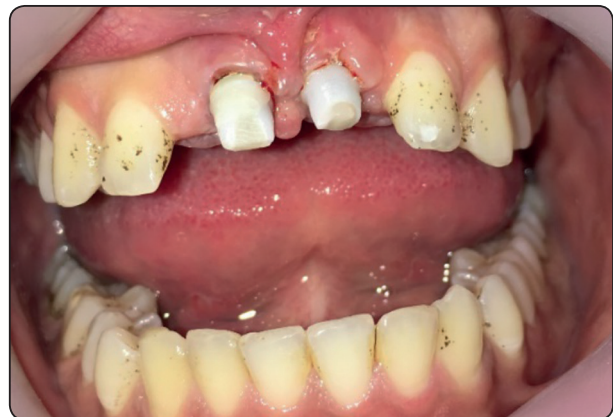

Fig. (12): Custom-made zirconium abutments.

- A shade colour selection was performed. Then, an accurate rubber base impression material was made and sent to the laboratory for final fabrication of porcelain crowns in the usual manner.
- The porcelain crowns were inserted into the patient's mouth, and checked for accuracy, contour, passive fit and occlusion. Finally, the porcelain crowns were cemented to the implant abutment and the patients were instructed to follow oral hygiene measurements. **(Fig.13)**

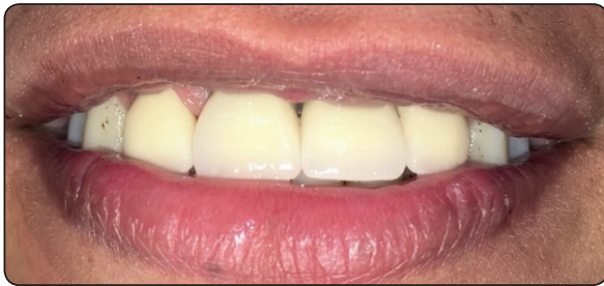

Fig. (13): Delivery & cementation of Porcelain crowns.



Fig. (14): The graduated pressure-sensitive Periodontal probe.

Evaluation of the patients:

For all patients; clinical & radiographic outcomes were gained; at the time of flexible RPD insertion, three months and six months later respectively. As follows:

Clinical evaluation:

This included the following:

Gingival index (GI):

Gingival tissues around the abutments were isolated & gently dried by a piece of gauze and subsequently each surface was discretely recorded according to the gingival index scores.

The gingival index scores were recorded as follows:

- For the first abutment: Three surfaces were scored; the buccal, lingual and distal surfaces.
- For the second abutment: Three surfaces were scored; the buccal, lingual and mesial surfaces.

The mean value of the scored surfaces for the anterior as well as the posterior abutments was calculated.

Pocket depth measurements:

- The periodontal pocket depth was measured using a graduated periodontal probe called *pressure-sensitive probe** (Fig.14) with the

advantage of applying a constant pressure during all measurements.

- The pocket depth was measured in six sites around each of the anterior and posterior abutments in both groups; the mid-buccal, mid-lingual, mesiobuccal, mesiolingual, distobuccal and disolingual sites.
- The periodontal probe was gently inserted inside the gingival crevice parallel to the long axis of the measured abutment tooth at each of the six previously mentioned sites.
- The pocket depth is measured from a constant point on the abutment tooth till the depth of the gingival crevice that represents the clinical attachment level.

The mean value of the scored surfaces for the anterior as well as the posterior abutments was calculated.

Radiographic evaluation:

Direct digital radiography utilizing the Digora computerized system* was applied for making intra-oral digital radiographic images to assess the following:

1. Changes in the mesial and distal marginal bone height around the implants and the abutments.
2. Changes in bone density around the implants.

The imaging plate was introduced into a protective bag which was sealed by the Digora system. The stored images of every single patient

* Hawa Click-Probe, Kerr, Switzerland

** Orion corporation, Soredex, Finland.

were interpreted at the end of the follow up period. Digital images were made for the implants, the abutments bounding the edentulous area immediately following Prosthesis placement, three months later as well as at the end of the study period (six months later).

Image analysis:

The Digital images were used to analyze and evaluate the following:

a) Marginal bone height measurements (linear analysis):

The linear measurement system supplied by the special software of the Vista-scan machine was used for assessing the mesial and distal marginal bone height around the implant and the abutments in both groups at the time of provisional restoration insertion, three months later and finally at the end of the study (six months later).

- *For the implant, measurements were made as follow:* The distance from the shoulder of the implant to the crest of the alveolar ridge, where a line was drawn tangential to the implant and parallel to its long axis. The mean value of both mesial and distal readings was taken, tabulated and statistically analyzed.
- *For the abutments, measurements were made as follow:* The distance from the crest of the alveolar ridge to the apex of the abutment tooth was measured. The mean value of the readings in the anterior and posterior abutments was taken, tabulated and statistically analyzed.

The increase in the marginal bone height measurements denotes bone resorption.

b) Measurements of bone density (Radiometric/Densitometric analysis):

The Digora system software was utilized for assessment of the changes in bone density mesial & distal to each implant. *The measurements were*

as follows: Two lines were drawn; the first line extended mesial to the implant from the shoulder of the implant to the apex of the implant and parallel to its long axis, while the second line extended distal to the implant from the implant shoulder to its apex. Bone density alongside each of the two lines was documented and then the mean value of both readings was calculated for further assessment.

Statistical analysis:

Data were awarded as means and standard deviation (SD) values.

Statistical tests:

The data was stated as means \pm standard deviations and mean percentage changes.

For parametric data; Repeated measures Analysis of Variance (ANOVA) was utilized to analyze the changes by time. Bonferroni's post-hoc test was applied for pair-wise comparisons when ANOVA test is significant.

For non-parametric data, Friedman's test was used to assess the changes by time. Dunn's test was applied for pair-wise comparisons when Friedman's test is significant.

Significance level:

The significance level was set at $P \leq 0.05$. Statistical analysis was made with SPSS 20* (Statistical Package for Scientific Studies) for Windows.

RESULTS

Numerical information was examined for normality by checking the distribution of information and using tests of normality (Kolmogorov-Smirnov and Shapiro-Wilk tests). Gingival Index (GI) scores exhibited non-normal (non-parametric) distribution while Pocket Depth (PD), bone height and bone density calculations exhibited normal (parametric) distribution. Data were given as mean and standard deviation (SD) values.

*SPSS, Inc., Chicago, IL, USA.

For parametric data; Frequent measures Analysis of Variance (ANOVA) was applied to assess the changes by time. Bonferroni's post-hoc test was performed for pair-wise comparisons when ANOVA test is significant.

With respect to parametric data; Friedman's test was applied to investigate the changes by time. Dunn's test was performed for pair-wise divergences when Friedman's test is significant.

The significance level was set at $P \leq 0.05$. Statistical analysis was performed with IBM® SPSS® Statistics Version 20 for Windows.

❖ *N.B: Two cases required bone augmentation to build insufficient labial bone &/or to cover any exposed implant threads. Those cases results were excluded from the study & have been replaced by another two cases which didn't need any bone augmentation.*

Changes around the abutments

I. Clinical evaluation:

Gingival Index (GI) Measurements:

On the first or second abutment abutments; there was no statistically significant change in mean GI scores from base line to 3 months as well as from 3 months to 6 months.

Pocket Depth (PD) Measurements:

Either at first or second abutments; there was no statistically significant change in mean PD from base line to 3 months as well as from 3 months to 6 months.

II. Radiographic evaluation:

Measurements of Bone height:

Measurements on both abutments, displayed that; there was a non-statistically significant increase in mean bone height measurement from base line to 3 months & from 3 months up to 6 months.

The implants outcomes (Radiographic evaluation):

❖ **Bone height Measures:**

A non-statistically significant improvement in mean bone height measurement regarding the period from base line to 3 months and from 3 months to a half year.

❖ **Bone density Measures:**

A non-statistically significant drop in mean bone density magnitudes from base line up to 3 months.

From 3 months to 6 months; There was non-statistically significant increase in mean bone density measurement.

TABLE (I): Mean, standard deviation (SD) values, results of repeated measures ANOVA test and Friedman's test the changes by time in different variables around the abutments

Variable	Abutment	Base line		3 months		6 months		P- value
		Mean	SD	Mean	SD	Mean	SD	
GI	First abutment	0.00	0.00	0.20	0.27	0.31	0.29	0.082
	Second abutment	0.00	0.00	0.10	0.22	0.30	0.27	0.097
PD	First abutment	6.21	0.04	6.23	0.06	6.26	0.05	0.055
	Second abutment	6.22	0.52	6.24	0.53	6.27	0.51	0.075
Bone height	First abutment	0.37	0.10	0.41	0.16	0.43	0.21	0.125
	Second abutment	0.39	0.13	0.42	0.15	0.46	0.18	0.082

*: Significant at $P \leq 0.05$

® IBM Corporation, NY, USA.

® SPSS, Inc., an IBM Company.

TABLE (II): Mean, standard deviation (SD) values, results of repeated measures ANOVA test and Friedman’s test the changes by time in different variables around the implants

Variable	Base line		3 months		6 months		P- value
	Mean	SD	Mean	SD	Mean	SD	
Bone height	0.35	0.11	0.38	0.14	0.39	0.20	0.095
Bone density	1444.12	9.84	138.05	13.33	141.30	16.11	0.055

*: Significant at $P \leq 0.05$

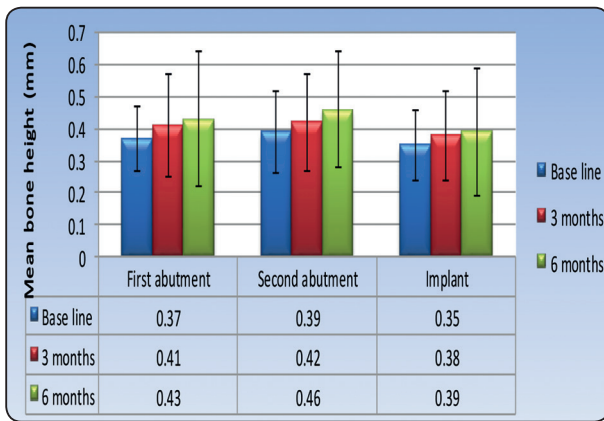


Fig. (15): A chart representing mean and standard deviation values for bone height measurements.

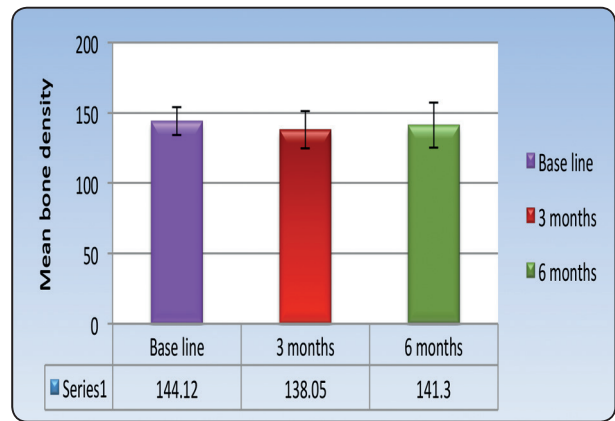


Fig. (16): A chart representing mean and standard deviation values for bone density measurements around implants.

DISCUSSION

Discussion of Methodology

During patient selection, the selected female patients were less than forty years of age to avoid the effect of hormonal disturbance associated with menopause on bone condition. In this study, the maxillary anterior region with intact opposing dental arch was selected to evaluate the ability of the flexible RPD with the aesthetic clasps to restore the function as well as the esthetics. ⁽¹⁸⁻²⁰⁾

Patients were selected with healthy periodontal condition of the abutment teeth to evaluate the effect of the flexible provisional restoration on sound, healthy peridontium. Therefore, the results obtained were only correlated to the effect of the prosthesis and were not affected by unhealthy peridontium. ⁽²¹⁾

Patients with marked drifting of the abutment teeth were excluded from this study for two reasons: first, to guarantee sufficient space for implant placement without endangering the adjacent abutment teeth, and second, to estimate the effect of the provisional restoration on properly standing abutments.

Patients were motivated for good oral and denture hygiene. Regular home care of the remaining natural teeth and implants was essential to ensure proper condition of the abutment teeth as well as proper implant condition after construction of the final prosthesis. ⁽²²⁻²³⁾

Patients with superior general health were only selected, to avoid the reflection of any systemic disorder on the bone condition, and hence, implants osseointegration. ⁽²⁴⁾

Bone quality and quantity were evaluated radiographically to ensure primary stability of the implant at the time of its placement as advocated by **many authors** ⁽²⁵⁻²⁷⁾

A rubber base impression material was utilized to ensure accurate recording of fine details, and hence, obtaining an accurate provisional restoration. ⁽²⁸⁾

An extra hard dental stone was utilized for impression pouring to avoid any fractures during removal of the impression from the stone cast.

Before construction of the surgical stent, a diagnostic set up of the missing tooth was carried out, so that the constructed surgical stent would facilitate the proper determination of the implant site labio-lingually and mesio-distally. ⁽²⁹⁾

A full-thickness mucoperiosteal flap was done in this study to ensure complete coverage of the implant during the healing period after flap repositioning. The mesial and distal incision lines of the flap were extended two millimeters palatally to provide adequate flap reflection without undue tissue trauma during the surgical procedure. ⁽³⁰⁾

Proper control of the frictional heat generation during preparation of the implant site was carefully considered to avoid necrosis of the surrounding bone cells which represent a primary cause for failure of osseointegration ^(31, 32).

A healing period of six months was allowed before the second surgical phase to ensure proper osseointegration before loading of the implant as was recommended by **Several authors**. ⁽³³⁻³⁶⁾

The cases were followed up for six months to ensure proper evaluation of the supporting tissue changes occurring around the implant and the abutment teeth.

At the second surgical phase, the gingival former was placed over the implant and left in the patient's mouth for two weeks to allow proper healing of the soft tissues around it, and formation of a healthy

gingival collar around the implant before being replaced by the implant abutment.

Gingival index scores give a clue about the condition of the gingival tissues around the abutment teeth. However, it is not a very reliable method of evaluation as was proposed by **some authors**. ⁽³⁷⁻³⁹⁾

Although the pocket depth measurement reflects the periodontal condition of the abutment teeth, however, it was not carried out around the implant to avoid damaging the attachment and breaking the biological seal around the implant which might adversely affect the osseointegration process. ⁽⁴⁰⁾ The graduated pressure-sensitive probe was utilized to apply a controlled pressure during pocket depth measurements.

Radiographic evaluation was carried out using the Digora computerized systems to ensure accurate recording of the changes occurring in the bone density and the bone height around the implants and the abutment teeth ⁽⁴¹⁾.

The construction of a radiographic template for each patient permitted accurate reproducibility of film positioning during the different follow up periods of the study.

A special sixteen-inch-long cone made of lead supplied by the machine helped the prevention of divergence of the x-rays and ensured directing only parallel rays to the imaging plate. ⁽⁴²⁾

The use of linear bone density & height measurements in case of the implant and the abutment teeth rather than area measurements helped to avoid overlapping of a part of the abutment root or the implant over the measured area, thus affecting the results. ⁽⁴³⁾

In this investigation, the measurements of the cases were carried out at the time of prosthesis insertion, after three months and finally after six months to evaluate the effect of time on the supporting tissue changes.

Discussion of Results

During the recall periods of all patients, there were no complaints from the installed implant and all the patients followed the oral hygiene instructions in order to avoid any harmful effect which might influence the results of this study.

Regarding the gingival index (GI) values, the statistically non-significant change in the mean GI values in patients using the Flexible RPD after three and six months from prosthesis insertion may be due to the gentle effect of the acetal resin clasps on the gingival tissues. ⁽⁴⁴⁻⁴⁶⁾

In the same way, Regarding the pocket depth (PD) measurements, the statistically non-significant change in the mean PD values in patients using the Flexible RPD after three and six months from prosthesis insertion may be due to the low impact forces exerted by the acetal resin clasps on the abutment teeth during the healing period. ⁽⁴⁷⁾

Also, the loss of the marginal bone height around the abutment teeth was statistically non-significant after three and six months of prosthesis insertion may be attributed to the less harmful effect on the gingival tissues around the abutment teeth. ⁽⁴⁸⁾

The non-significant increase in the mean bone height measurements around the implants, indicating increased crestal bone resorption in the first three months compared to those measurements after six months of prosthesis insertion may be explained by the continuous remodelling process of bone surrounding the implant resulting in bone resorption, followed by bone deposition. ⁽⁴⁹⁾ The crestal bone resorption around implants is a well-known phenomenon occurring mostly in the initial phase of functional implant loading and considered as an immediate bone response after insertion of the implant supported prosthesis. The mean marginal bone loss in the present study from base line to six months is considered within accepted permissible limits occurring with most dental implants. ⁽⁵⁰⁾

Regarding changes of bone density around the implants, it was evident that there was a non-significant decrease of mean values of bone density at the first 3 months. This was mainly attributed to the surgical trauma during implant surgery and immediate insertion of the flexible prosthesis as well as the precautions given to the patient to maintain soft diet for the longest possible period during the first three month of treatment. On the other hand, the statistically non-significant increase in the bone density measurements in periods from three to six months, indicating favourable bone reaction to the applied forces that were within the physiologic limit tolerated by the bone and hence, favourable progress of the osseointegration process.

It is worth to mention that the changes in the bone height and density were confirmed by the data of the clinical investigations. In addition, the changes in the bone height and density around the implants can be considered favourable reactions to those prostheses, where the forces applied by this flexible RPD have been within the physiologic limit tolerated by the patient.

The findings of this investigation showed that this flexible RPD with aesthetic clasps could preserve the integrity of the implants together with maintaining the abutment teeth in a healthy condition. In other words; to maintain the process of osseointegration but not at the expense of the natural abutment teeth.

CONCLUSION

This study was performed to estimate the outcome of flexible RPD with aesthetic clasps as a provisional prosthesis during the period of implants osseointegration both clinically and radiographically.

- Ten patients were picked from the outpatient clinic of the prosthodontic department, Faculty of Oral and Dental Medicine, Cairo University, with edentulous anterior maxilla. All Patients obtained a flexible RPD with acetal resin aesthetic clasps as a provisional restoration at

the interval between the first and second stage of implant therapy.

- Clinical evaluation of the abutment teeth involved the recording of gingival index scores as well as pocket depth measurements (using a pressure-sensitive periodontal probe). Radiographic assessment included the use of Digora computerized system for estimating the changes in the marginal bone height around the implants as well as the abutment teeth, in addition to the bone density magnitudes around the implants. Both clinical and radiographic evaluations were applied at the time of prosthesis insertion, three months and six months later.
- A statistically non-significant increase in the gingival index scores as well as the periodontal pocket depth measurements was observed throughout the whole study period.
- A statistically non-significant loss in the marginal bone height was observed in all patients around the abutment teeth as well as the implants. In addition, the changes in the bone density measurements around the implants were statistically insignificant.

From the results of this study, the following conclusions could be achieved:

- The flexible RPD with acetal resin aesthetic clasps used as a provisional restoration preserved the health of supporting structures of the abutment teeth as well as the implants during the osseointegration period.
- Aesthetics & psychological confidence of the patients were highly improved.
- The gingival index scores and the pocket depth measurements were close to normal.
- The changes in the bone height and density around the implants and the abutments were more favourable with the use of the flexible RPD with acetal resin aesthetic clasps

CONFLICT OF INTEREST

This clinical study was self-funded by the author, with no conflict of interest.

REFERENCES

1. The Glossary of Prosthodontic Terms: The Academy of Prosthodontics. 9th ed. J. Prosth. Dent 2017; 117(5S):20-114.
2. Fueki K, Ohkubo C, Yatabe M, Arakawa I, Arita M, Ino S, Kanamori T, Kawai Y, Kawara M, Komiyama O, Suzuki T, Nagata K, Hosoki M, Masumi S, Yamauchi M, Aita H, Ono T, Kondo H, Tamaki K, Matsuka Y, Tsukasaki H, Fujisawa M, Baba K, Koyano K, Yatani H.: Clinical application of removable partial dentures using thermoplastic resin. Part I: Definition and indication of non-metal clasp dentures. J Prosthodont Res 2014; 58:3-10.
3. Fueki K, Ohkubo C, Yatabe M, Arakawa I, Arita M, Ino S, Kanamori T, Kawai Y, Kawara M, Komiyama O, Suzuki T, Nagata K, Hosoki M, Masumi S, Yamauchi M, Aita H, Ono T, Kondo H, Tamaki K, Matsuka Y, Tsukasaki H, Fujisawa M, Baba K, Koyano K, Yatani H.: Clinical application of removable partial dentures using thermoplastic resin. Part II: Material properties and clinical features of non-metal clasp dentures. J Prosthodont Res 2014; 58:71-84.
4. Hamanaka I, Takahashi Y, Shimizu H.: Mechanical properties of injection-molded thermoplastic denture base resins. Acta Odontol Scand 2011; 69:75-79.
5. Takabayashi Y.: Characteristics of denture thermoplastic resins for non-metal clasp dentures. Dent Mater J 2010; 29:353-361.
6. Hamanaka I, Takahashi Y, Shimizu H.: Properties of injection-molded thermoplastic polyester denture base resins. Acta Odontol Scand 2014; 72:139-144.
7. Abhay PN, Karishma S.: Comparative evaluation of impact and flexural strength of four commercially available flexible denture base materials: An in vitro study. J Indian Prosthodont Soc 2013; 13:499-508.
8. Hamanaka I, Shimizu H, Takahashi Y.: Shear bond strength of an autopolymerizing repair resin to injection-molded thermoplastic denture base resins. Acta Odontol Scand 2013; 71:1250-1254.
9. Takahashi Y, Yoshida K, Shimizu H.: Effect of location of glass fiber-reinforced composite reinforcement on the flexural properties of a maxillary complete denture in vitro. Acta Odontol Scand 2011; 69:215-221.
10. Gundawar S, Zamad A, Gundawar S.: Light weight dentures: An innovative technique. Contemp Clin Dent 2014; 5:134-137.

11. Inami T, Tanimoto Y, Yamaguchi M, Shibata Y, Nishiyama N, Kasai K.: Surface topography, hardness, and frictional properties of GFRP for esthetic orthodontic wires. *J Biomed Mater Res B* 2016; 104:88–95.
12. Al-Omiri, M., Hantash, R.A. & Al-Wahadni, A.: Satisfaction with dental implants: a literature review. *Implant Dentistry* 2005; 14: 399–406.
13. Cochran, D.L., Morton, D. & Weber, H.P.: Consensus statements and recommended clinical procedures regarding loading protocols for endosseous dental implants. *International Journal of Oral and Maxillofacial Implants* 2004; 19(Suppl): 109–113.
14. Evans, C.D. & Chen, S.T.: Esthetic outcomes of immediate implant placements. *Clinical Oral Implants Research* 2008; 19: 73–80.
15. Hammerle, C.H., Chen, S.T. & Wilson, T.G., Jr.: Consensus statements and recommended clinical procedures regarding the placement of implants in extraction sockets. *International Journal of Oral and Maxillofacial Implants* 2004; 19(Suppl): 26–28.
16. Lekholm, U., Grondahl, K. & Jemt, T.: Outcome of oral implant treatment in partially edentulous jaws followed 20 years in clinical function. *Clinical Implant Dentistry and Related Research* 2006; 8: 178–186.
17. Levi, A., Psoter, W.J., Agar, J.R., Reisine, S.T. & Taylor, T.D.: Patient self-reported satisfaction with maxillary anterior dental implant treatment. *International Journal of Oral and Maxillofacial Implants* 2003; 18: 113–120.
18. Salinas, T.J., Block, M.S. & Sadan, A.: Fixed partial denture or single-tooth implant restoration? Statistical considerations for sequencing and treatment. *Journal of Oral and Maxillofacial Surgery* 2004; 62: 2–16.
19. Strassburger, C., Heydecke, G. & Kerschbaum, T.: Influence of prosthetic and implant therapy on satisfaction and quality of life: a systematic literature review. Part 1—characteristics of the studies. *International Journal of Prosthodontics* 2004; 17: 83–93.
20. Vogel, R., Smith-Palmer, J. & Valentine, W.: Evaluating the health economic implications and cost-effectiveness of dental implants: a literature review. *International Journal of Oral and Maxillofacial Implants* 2013; 28: 343–356.
21. Shah J, Bulbule N, Kulkarni S, Shah R, Kakade D.: Comparative evaluation of sorption, solubility and microhardness of heat cure polymethylmethacrylate denture base resin and flexible denture base resin. *J Clin Diagn Res* 2014; 8: ZF01–ZF04.
22. Kunaal Dh.: Oral Rehabilitation Considerations for Partially Edentulous Periodontal Patients. *Journal of Prosthodontics* 2012; 21: 494–513.
23. Zitzmann, N.U., Krastl, G., Weiger, R., Kuhl, S. & Sendi, P.: Cost-effectiveness of anterior implants versus fixed dental prostheses. *Journal of Dental Research* 2013; 92: 183S–188S.
24. Rhrig A, Peeters J.: Test Report on ClearSplint flexible resin. mdt medical device testing GmbH Physical-chemical Laboratory. Ochsenhausen, Germany. (Personal communication.) 2009; Feb. 13: 54–73.
25. Abd El Salam El Askary: Diagnostic Considerations for Esthetic Implant Therapy. *Fundamentals of Esthetic Implant Dentistry* 2009; 2: 13-75.
26. Nagakura, M, Tanimoto, Y, Nishiyama.: Fabrication and physical properties of glass–fiber reinforced thermoplastics for non-metal-clasp dentures. *J Biomed Mater Res Part B* 2015; 00B:1-7.
27. Yu SH, Cho HW, Oh S, Bae JM.: Effects of glass fiber mesh with different fiber content and structures on the compressive properties of complete dentures. *J Prosthet Dent* 2015; 113:636–644.
28. Wadachi J, Sato M, Igarashi Y.: Evaluation of the rigidity of dentures made of injection-molded materials. *Dent Mater J* 2013; 32: 508–511.
29. Tanimoto Y.: Dental materials used for metal-free restorations: Recent advances and future challenges. *J Prosthodont Res* 2015; 59:213–215.
30. Abhay PN, Karishma S.: Comparative evaluation of impact and flexural strength of four commercially available flexible denture base materials: An in vitro study. *J Indian Prosthodont Soc* 2013; 13:499–508.
31. Hamanaka I., Shimizu H., Takahashi Y.: Shear bond strength of an autopolymerizing repair resin to injection-molded thermoplastic denture base resins. *Acta Odontol Scand* 2013; 71:1250–1254.
32. Thomas D., John R. and Theodora V.: Implant Prosthodontics, current perspective and future direction. *Quintessence* 2005; 15: 1-14.
33. Veeraiyan DN., Ramalingam K. and Bhat V.: Textbook of prosthodontics, 4th ed. Jaypee Bros., New Delhi 2007; 355-477.
34. Roberto V and Bo Rangert: Immediate and early function of implants placed in extraction sockets of maxillary infected teeth: A pilot study. *J. Prosthet. Dent.* 2007; 97: 96-108.
35. Marco C., Luiz A. and Sergio S.: Influence of implant positioning in extraction sockets on osseointegration: histomorphometric analyses in dogs. *Clin. Oral Impl. Res.* 2010; 21 (1): 43-49.

36. Daniele B., Antonio R., Jan L. and Tord B.: Implants in fresh extraction sockets: a prospective 5-year follow-up clinical study. *Clin. Oral Impl. Res.* 2008; 19 (12): 1226-1236.
37. Zembić A., Glauser R. and Khraisat A.: Immediate vs. early loading of dental implants: 3-year results of a randomized controlled clinical trial. *Clin. Oral Impl. Res.* 2010; 21 (5): 481-489.
38. Guy Huynh-Ba., Bjarni EP. and Mariano S.: Analysis of the socket bone wall dimensions in the upper maxilla in relation to immediate implant placement. *Clin. Oral Impl. Res.* 2010; 21 (1): 37-42.
39. Seung MI., Byung HO., Jingxu LI. and Feng X.: Bone healing around implants following flap and mini-flap surgeries: A radiographic evaluation between stage-one and stage-two surgery. *J. Oral Maxillofac. Surg.* 2008; 105 (3): 293-296.
40. Warkwick J. and Mary P.: Immediate restoration/loading of immediately placed single implants: is it an effective bimodal approach? *Clin. Oral Impl. Res.* 2009; 20 (7): 645-659.
41. Nikolaos T., Stephen M. and John D.: Immediate placement and immediate provisional abutment modeling in anterior single-tooth implant restorations using a CAD/CAM application: A clinical report. *J. Prosthet. Dent.* 2006; 95: 181-185.
42. Del Castellino R and Drago C: Indexing and provisional restoration of single implants. *J. Oral Maxillofac. Surg.* 2005; 63: 11-21.
43. Presson J. and Tord B.: Bone tissue formation adjacent to implants placed in fresh extraction sockets: an experimental study in dogs. *Clin. Oral Impl. Res.* 2006; 17 (4): 351-358.
44. Marco C., Luiz A. and Sergio S.: Hard tissue formation adjacent to implants of various size and configuration immediately placed into extraction sockets: an experimental study in dogs. *Clin. Oral Impl. Res.* 2010; 21 (9): 885-890.
45. Mariano S., Denis C. and Jorge FE.: A prospective, randomized-controlled clinical trial to evaluate bone preservation using implants with different geometry placed into extraction sockets in the maxilla. *Clin. Oral Impl. Res.* 2010; 21 (1): 13-21.
46. Andres F. and Leif H.: Early functional loading of sand-blasted and acid-etched (SLA) Straumann implants following immediate placement in maxillary extraction sockets: Clinical and radiographic result. *Clin. Oral Impl. Res.* 2007; 18 (4): 441-451.
47. Juan B., Célia CA., Vanesa N., Luis Al., Fernando M. and Isabel R.: Biological width following immediate implant placement in the dog: flap vs. flapless surgery. *Clin. Oral Impl. Res.* 2010; 21 (6): 624-631.
48. Singh G. and Goyal M.: Immediate endosseous implant stability placed in fresh extraction sockets—a short term evaluation. *Int. J. Oral and Maxillofac. Surgery* 2007; 36 (11): 1112-1113.
49. Wenstrom JI. and Karlsson S.: Implant supported single-tooth restorations: A 5-year prospective study. *J. Clin. Periodontol.* 2005; 32: 567-574.
50. Antonio A. and Flavio T.: Immediate/early function with tapered implants supporting maxillary and mandibular posterior fixed partial dentures: Preliminary results of a prospective multicenter study. *J. Prosthet. Dent* 2007; 97: 52-58.