

Clinical Case Report: Anterior Maxillary Teeth Restoration with Immediate Post-Extraction Implantation. FILO Implantology Approach.

Dr. Alvaro Bastida

Medical & Surgical Degree, Stomatologist.

Private practice. Vigo, Spain

Key words: Immediate post-extraction implantation, aesthetic important area, flapless, immediate loading, one-piece implant, FILO implantology.

Background

- Patient: 30 years old female. Non-smoker. Medical History within normal limits (WNL)
- Initial Presentation: June 2014
- Treatment Completed: August 2014

Clinical Assessment

- Temporomandibular Joints: WNL.
- Extraoral: WNL; low lip and smile line.
- Intraoral: The patient had a poor condition metal-ceramic bridges in front maxillary area, with mobility due to destroyed teeth from canine to canine (fig. 1).
- Occlusion: Class I.
- Periodontal: Gingivitis in front maxillary area.

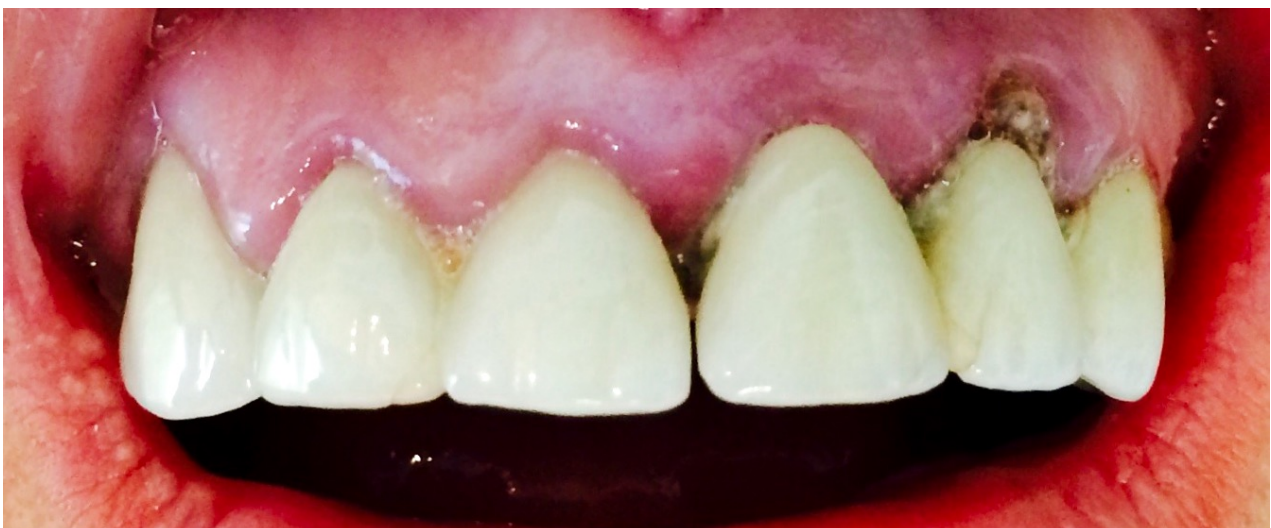

Fig. 1

Radiographic Assessment

OPG showed broken and decayed front maxillary roots, with old endontics and periapical granulomas (fig. 2)

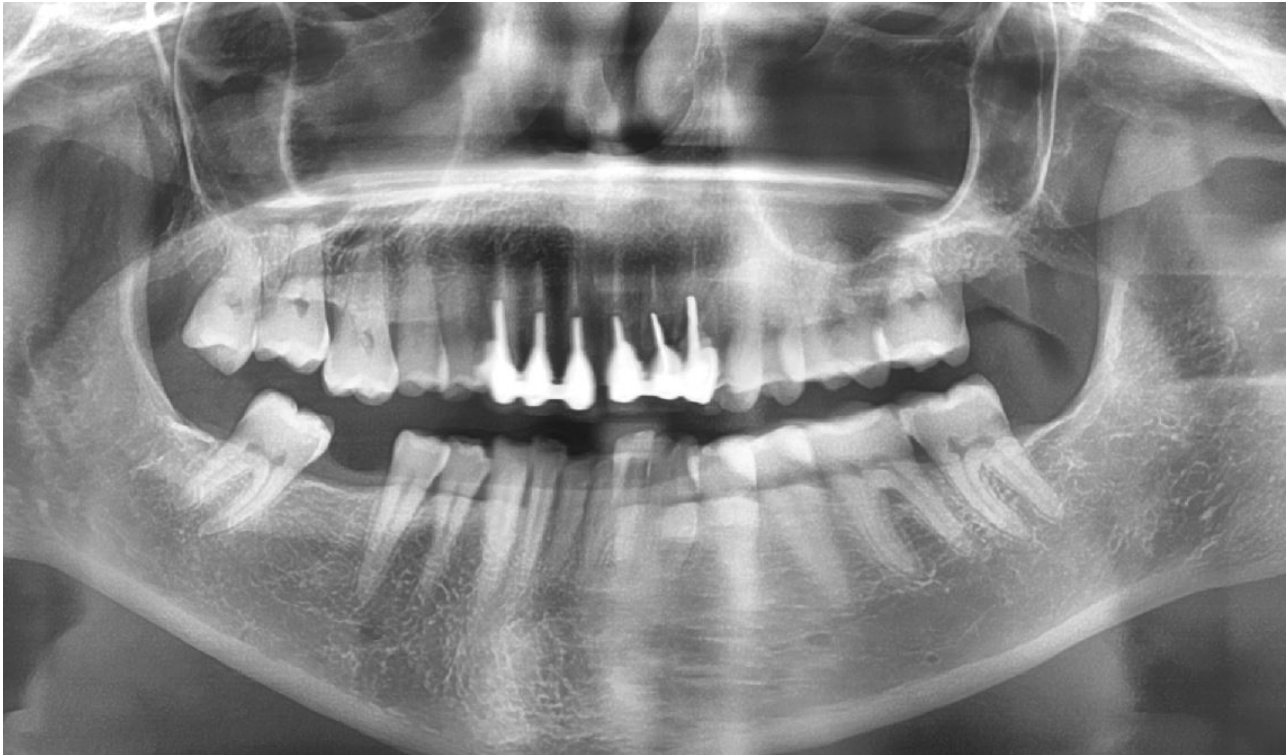

Fig. 2

Treatment Plan

1. Antibiotherapy with Amoxicilin, 750 mg / 8 h. / 1 week previous to surgery.
2. Teeth maxillary extraction from canine to canine
3. Inmediate post-extraction implantation with four ROOTT COMPRESSIVE fixations.
Temporary bridge.
4. After 2 months, zirconia final crown placement.

FILO Implantology

Implant restoration was performed following the FILO implantology principles:

- Flapless surgery
- Inmediate Loading
- One-piece implants.

This approach allows a short treatment time, simple to perform and safe results.

First FILO principle is a **flapless surgery**. Periosteum provides 70% bone blood suply. Laboratory research has shown that architecture of the trabeculae inside a hollow bone is destroyed by simply raising a full thickness flap and without performing any surgery on the bone itself. Raising a flap will be itself endanger the implant's stability. Avoiding a flap helps to preserve the bone flow nutrients and the available spongeous bone remains constant after implant placement. Moreover there are no scalpel or suture, therefore less surgical time and better postoperative.

Second FILO principle is **immediate loading**. We can short treatment time and reducing patient discomfort / inconvenience with immediate loading implants. This treatment approach has been studied and has shown predictable results. Immediate implant loading achieved similar success rates as those reported in the delayed 2-stage approach. Primary implant stability is a key factor to consider before attempting immediate implant loading.

Third FILO principle is using of **one-piece implants**. There are an experience of over 50 years using this kind of implants. They are solid fixations, without hollow pieces, little screws or connections as two-piece implants. This avoids typical problems: loosened or broken screw, peri-implantitis by microgaps, breaking implant walls... Thin one-piece implant can withstand the same load than a two pieces wider implant.

In the present case it was placed a ROOTT COMPRESSIVE implant (TRATE AG company). This one-piece implant has interesting features that fit very well to FILO approach (fig. 9):

- **Conical shape** with small apical diameter, suitable to transgingival insertion in flapless surgery and to bypass anatomical structures —as maxillary sinus and mandibular nerve— and platform switching to improve soft tissue adaptation.
- **Compressive threads** that compact cancellous bone —improving its quality by corticalization effect. They also get easily high torque and primary stability. This is ideal for immediate loading.
- **Implant neck** with a polished surface and narrow diameter, very well tolerated by soft tissues —even no attached gingiva—. This prevents peri-implantitis and avoid gingival grafts in many cases. And it has an special feature: it is bendable 15° to 20° to adjust the abutment slope angle. So we can put parallel abutments even if implant insertion has not been parallel.



Fig. 3

Implant Surgery

It was necessary a careful teeth extraction, with complete removing of the infected tissues by Molt curette.

1° **Pilot Drill** (fig. 4): Drilling was done into the teeth sockets following the direction of palatin wall (fig. 5). A periapical X-ray with the pilot drill is required to verify the proper direction of insertion. Whenever possible it is suitable to reach the opposite cortical with the drill tip. That way, when the implant is inserted, it will get a double retention way: *bicorticalization* —mechanical anchoring in both cortical— and *osseointegration* into the cancellous bone.



Fig. 4

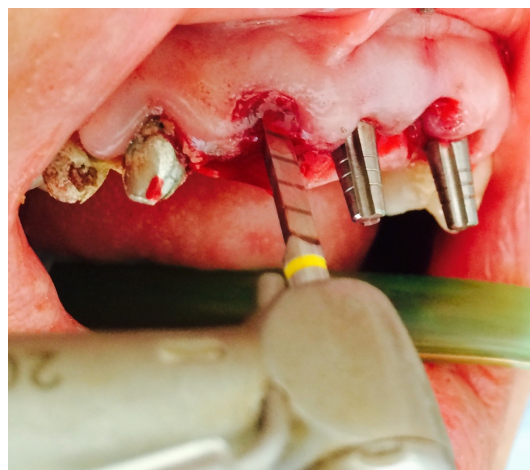


Fig. 5



Fig. 6

2° **Compressive Screw** (fig. 6): This instrument is inserted manually, with wrench. It condenses the cancelous bone making a corticalization effect in soft bone —improving its quality— and prepares the implant socket.

3° **Compressive Implant** (fig. 7): They were chosen ROOTT COPRESSIVE implants 4.0 mm diameter, 16.0 mm length size. They were inserted manually, with wrench, until reach the opposite cortical —in the present case the nasal floor (fig. 8). It is very important to achieve primary stability by at least 35 Nw/cm² insertion torque.

The direction of implant insertion followed the bone crest axis. So that the abutment was a little bit prominent to buccal. This was corrected immediately after insertion by bending implant neck to a proper prosthetic position. The bending is an easy but sensitive procedure. It requires especial training.

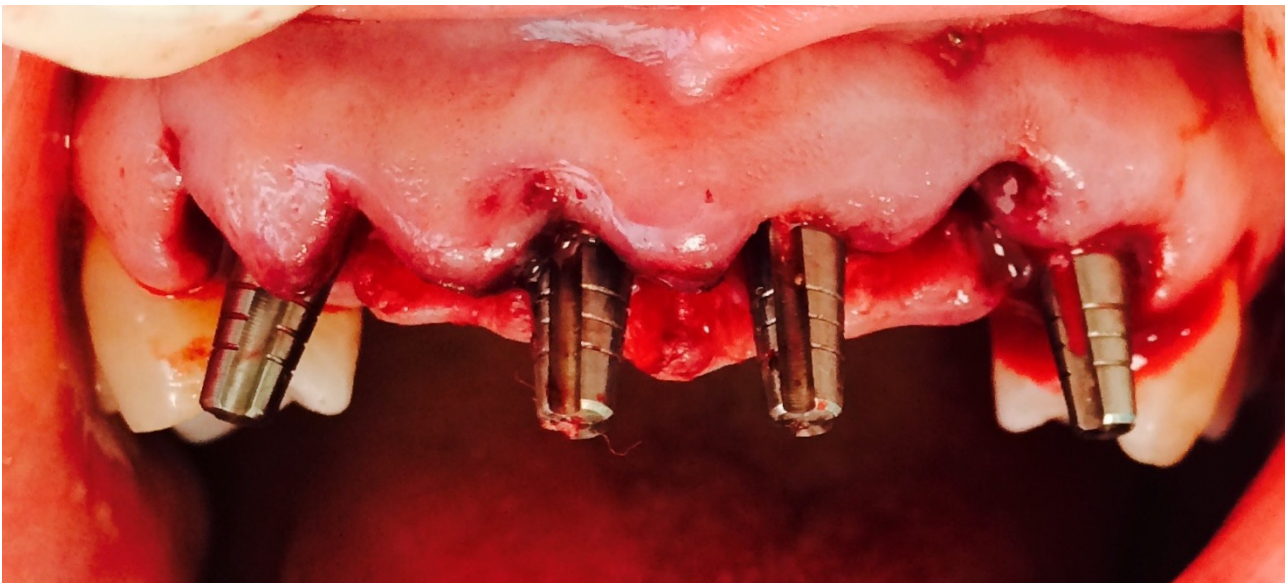


Fig. 7

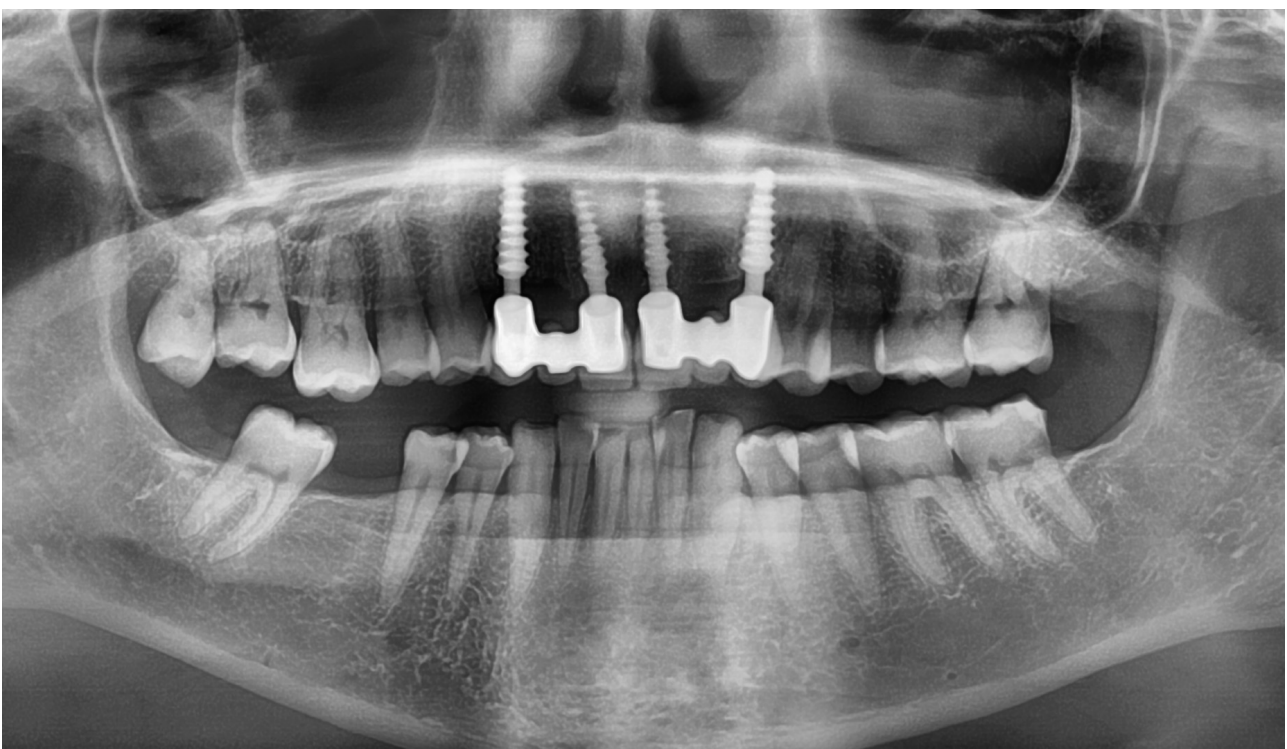

Fig. 7

Prosthesis

Immediately after surgery a temporary plastic bridge was placed. The temporary bridge remained in non-functional immediate loading for 2 months. The temporary non-functional way is recommended in anterior maxillary.

After two months hard and soft tissue are healed (fig. 8) and we can take steps to make the final crown. Impression cup, burn out cup and implant analog delivered with each ROOTT COMPRESSIVE implant are very suitable in prosthetic phase. If it is necessary we can grind abutments —like a natural tooth— to achieve the final parallelism.

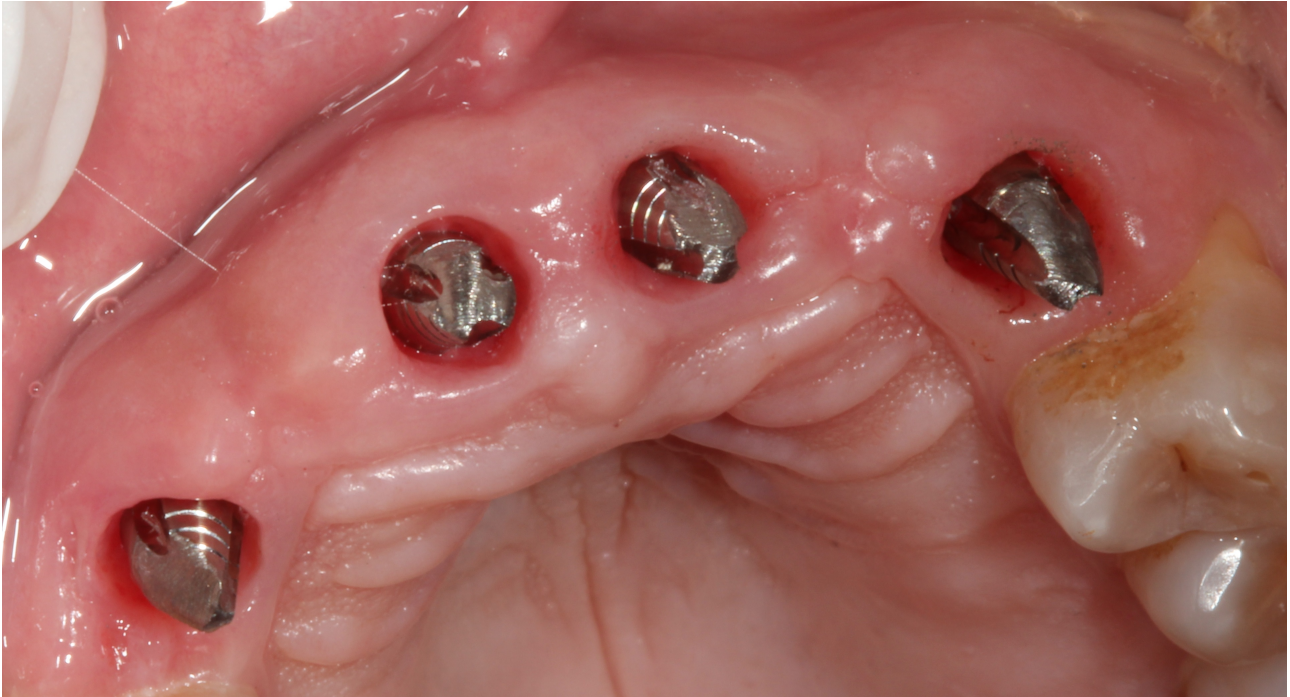


Fig. 8

Finally the final metal-ceramic crown is placed and fixed with resin cement (fig. 9).

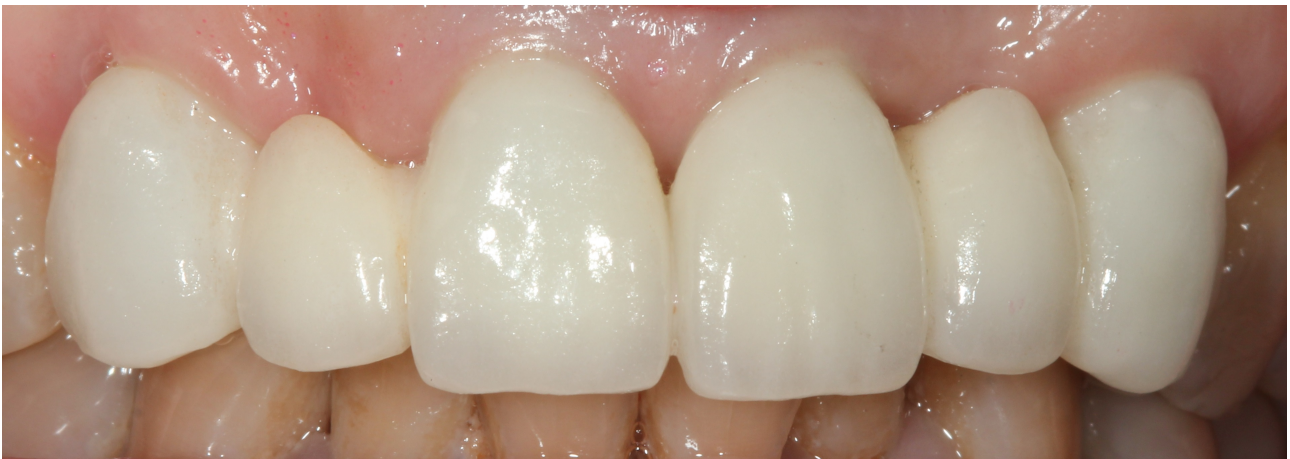

Fig. 9

Commentary

The FILO implantology is a short in time, simple to use and safe in results approach to implant restoration. It is very suitable in bone atrophy situations, avoiding many times bone graft procedures. Also it is very suitable to post-extraction situations? In the presented case they were achieved excellent results both functional and aesthetic.

References

Post-extraction implants

Schropp L, Isidor F. Timing of implant placement relative to tooth extraction. *J Oral Rehabil* 2008; 35 (Suppl 1):33–43.

Malchiodi L, Ghensi P, Cucchi A, Corrocher G. A comparative retrospective study of immediately loaded implants in postextraction sites versus healed sites: results after 6 to 7 years in the maxilla. *Int J Oral Maxillofac Implants* 2011; 26:373–384.

Enríquez-Sacristán C, Barona-Dorado C, Calvo-Guirado JL, Leco-Berruocal I, Martínez-González JM. Immediate post-extraction implants subject to immediate loading: A meta-analytic study. *Med Oral Patol Oral Cir Bucal*. 2011 Nov 1;16 (7):e919-24.

Barone A, Rispoli L, Voza I, Quaranta A, Covani U. Immediate restoration of single implants placed immediately after tooth extraction. *J Periodontol*. 2006;77:1914-20.

Chaushu G, Chaushu S, Tzohar A, Dayan D. Immediate loading of single-tooth implants: immediate versus non-immediate implantation. A clinical report. *Int J Oral Maxillofac Implants*. 2001;16:267- 72.

Chen ST, Darby IB, Reynolds EC, Clement JG. Immediate implant placement postextraction without flap elevation. *J Periodontol*. 2009;80:163-72.

Buser D, Halbritter S, Hart C, Bornstein MM, Grütter L, Chapuis V, et al. Early implant placement with simultaneous guided bone regeneration following single-tooth extraction in the esthetic zone: 12-month results of a prospective study with 20 consecutive patients. *J Periodontol*. 2009;80:152-62.

Cooper LF, Rahman A, Moriarty J, Chaffee N, Sacco D. Immediate mandibular rehabilitation with endosseous implants: simultaneous extraction, implant placement, and loading. *Int J Oral Maxillofac Implants*. 2002;17:517-25.

Crespi R, Capparè P, Gherlone E, Romanos GE. Immediate occlusal loading of implants placed in fresh sockets after tooth extraction. *Int J Oral Maxillofac Implants*. 2007;22:955-62.

Wagenberg B, Froum SJ. A retrospective study of 1925 consecutively placed immediate implants from 1988 to 2004. *Int J Oral Maxillofac Implants*. 2006;21:71-80.

Kahnberg KE. Immediate implant placement in fresh extraction sockets: a clinical report. *Int J Oral Maxillofac Implants*. 2009;24:282-8.

Crespi R, Capparè P, Gherlone E, Romanos GE. Immediate versus delayed loading of dental implants placed in fresh extraction sockets in the maxillary esthetic zone: a clinical comparative study. *Int J Oral Maxillofac Implants*. 2008;23:753-8.

Immediate Loading Implants

Ganeles, J., Rosenberg, M.M., Holt, R.L. & Reichman, L.H. (2001) Immediate loading of implants with fixed restorations in the completely edentulous mandible: report of 27 patients from a private practice. *International Journal of Oral and Maxillofacial Implants* 16: 418–426.

Jaffin, R.A., Kumar, A. & Berman, C.L. (2000) Immediate loading of implants in partially and fully edentulous jaws: a series of 27 case reports. *Journal of Periodontology* 71: 833–838.

Jo, H.Y., Hobo, P.K. & Hobo, S. (2001) Freestanding and multiunit immediate loading of the expandable implant: an up-to-40-month prospective survival study. *Journal of Prosthetic Dentistry* 2: 148–155.

Salama, H., Rose, L.F., Salama, M. & Betts, N.J. (1995) Immediate loading of bilaterally splinted titanium root-form implants in fixed prosthodontics – a technique reexamined: two case reports. *International Journal of Periodontics and Restorative Dentistry* 15: 344–361.

Tarnow, D.P., Emtiaz, S. & Classi, A. (1997) Immediate loading of threaded implants at stage 1 surgery in edentulous arches: ten consecutive case reports with 1- to 5-year data. *International Journal of Oral and Maxillofacial Implants* 12: 319–324.

Testori, T., Szmukler-Moncler, S., Francetti, L., Del Fabbro, M., Scarano, A., Piattelli, A. & Weinstein, R.L. (2001) Immediate loading of osseointegrated implants: a case report and histologic analysis after 4 months of occlusal loading. *International Journal of Periodontics and Restorative Dentistry* 5: 451–9.

Aparicio, C., Rangert, B. & Sennerby, L. (2002) Immediate/early loading of dental implants: a report from the Sociedad Espanola de Implantos World Congress consensus meeting in Barcelona, Spain. *Clinical Implant Dentistry and Related Research* 5: 57–60.

Bischof, M., Nedir, R., Szmukler-Moncler, S., Bernard, J.P. & Samsom, J. (2004) Implant stability measurement of delayed and immediately loaded implants during healing A clinical resonance-frequency analysis study with sandblasted-and-etched ITI implants. *Clinical Oral Implants Research* 15: 529–539.

Chiapasco, M. (2004) Early and immediate restoration and loading of implants in totally edentulous patients. *International Journal of Oral Maxillofacial Implants* 19Suppl.: 76–91.

Glauser, R., Sennerby, L., Meredith, N., Ree, A., Lundgren, A.K., Gottlow, J. & Hammerle, C.H. (2004) Resonance frequency analysis of implants subjected to immediate or early loaded functional occlusal loading Successful vs. failing implants. *Clinical Oral Implants Research* 15: 428–434.

Glauser, R., Zembic, A. & Hammerle, C.H.F. (2006) A systematic review of marginal soft tissue at implants subjected to immediate loading or immediate restoration. *Clinical Oral Implants Research* 17Suppl. 2: 82–92.

Susarla SM, Chuang SK, Dodson TB. Delayed versus immediate loading of implants: survival analysis and risk factors for dental implant failure. *J Oral Maxillofac Surg* 2008; 66:251–255.

Gallucci GO, Morton D, Weber HP. Loading protocols for dental implants in edentulous patients. *Int J Oral Maxillofac Implants* 2009; 24:132–146.

Testori T, Galli F, Capelli M, et al. The therapeutic approach of the Galeazzi Orthopaedic Institute Implant Department. In: Testori T, Galli F, Del Fabbro M, eds. *Immediate loading: a new era in oral implantology*. Berlin: Quintessence Publishing, 2011:189–293.

Del Fabbro M, Testori T, Francetti L, Taschieri S, Weinstein R. Systematic review of survival rates for immediately loaded dental implants. *Int J Periodontics Restorative Dent* 2006; 26:249–263.

Grunder U. Immediate functional loading of immediate implants in edentulous arches: two-year results. *Int J Periodontics Restorative Dent* 2001; 21:545–551.

Davarpanah M, Caraman M, Jakubowicz-Kohen B, Kebir-Quelin M, Szmukler-Moncler S. Prosthetic success with a maxillary immediate-loading protocol in the multiple-risk patient. *Int J Periodontics Restorative Dent* 2007; 27:161–169.

Degidi M, Piattelli A, Felice P, Carinci F. Immediate functional loading of edentulous maxilla: a 5-year retrospective study of 388 titanium implants. *J Periodontol* 2005; 76:1016–1024.

One-piece Implants

Barrachina-Diez JM, Tashkandi E, Stampf S, Att W. Long-term outcome of one-piece implants. Part I: implant characteristics and loading protocols. A systematic literature review with meta-analysis. *The International Journal of Oral & Maxillofacial Implants* [2013, 28(2):503-518]

Finne K, Rompen E, Toljanic J. Three-year prospective multicenter study evaluating marginal bone levels and soft tissue health around a one-piece implant system. *The International Journal of Oral & Maxillofacial Implants* [2012, 27(2): 458-466]

- Froum SJ, Cho SC, Elian N, Romanos G, Jalbout Z, Natour M, Norman R, Neri D, Tarnow DP. Survival rate of one-piece dental implants placed with a flapless or flap protocol--a randomized, controlled study: 12-month results. *The International Journal of Periodontics & Restorative Dentistry* [2011, 31(6):591-601]
- Fanali S, Carinci F, Zollino I, Brunelli G, Monguzzi R. Effect of one-piece implant diameter on clinical outcome. *European Journal of Inflammation* 2011; 3 (S):7-12.
- Fanali S, Carinci F, Zollino I, Brunelli G, Monguzzi R. Effect of one-piece implant length on clinical outcome. *European Journal of Inflammation* 2011; 3 (S):13-18.
- Fanali S, Carinci F, Zollino I, Brunelli G, Monguzzi R. Effect of distance between one piece implants on crestal bone resorption. *European Journal of Inflammation* 2011; 3 (S):1-6.
- Hahn J. Clinical evaluation of one-piece implants used for immediate function. A preliminary report of bone level up to 2-year. *Eur J Dent Implantol.* 2006;2(suppl 1):12-15
- Drago CJ. Clinical and histological assessment of a one-piece implant system: a pilot study. *Dent Praxis* 2005;11/12:319-325.
- Hahn J. One-piece root-form implants: a return to simplicity. *J Oral Implantol.* 2005;2:77-84
- Hahn J (2007) Clinical and Radiographic Evaluation of One-Piece Implants Used for Immediate Function. *Journal of Oral Implantology*: June 2007, Vol. 33, No. 3, pp. 152-155.
- Finne K, Rompen E, Toljanic J. Prospective multicenter study of marginal bone level and soft tissue health of a one-piece implant after two years. *J Prosthet Dent* 2007; 97:S79-85.
- Fortin T, Bosson JL, Isidori M, Blanchet E. Effect of flapless surgery on pain experienced in implant placement using an image-guided system. *Int J Oral Maxillofac Implants* 2006; 21:298-304.
- Rocci A, Martignoni M, Gottlow J. Immediate loading in the maxilla using flapless surgery, implants placed in predetermined positions, and prefabricated provisional restorations: a retrospective 3-year clinical study. *Clin Implant Dent Relat Res* 2003; 5 Suppl 1:29-36.
- Degidi M, Piattelli A. Immediate functional and non-functional loading of dental implants: a 2- to 60-month follow-up study of 646 titanium implants. *J Periodontol* 2003; 74:225-41.
- Stephen M. Parel DDS Sterling R. Schow DMD Early Clinical Experience With a New One-Piece Implant System in Single Tooth Sites. *Journal of Oral and Maxillofacial Surgery* September 2005, Vol.63(9):2-10, doi:10.1016/j.joms.2005.05.150
- Kaj Finne, Eric Rompen, Joseph Toljanic. Prospective multicenter study of marginal bone level and soft tissue health of a one-piece implant after two years. *The Journal of Prosthetic Dentistry.* June 2007, Vol.97(6):S79-S85, doi:10.1016/S0022-3913(07)60011-0
- Tramonte S.M.: Un nuovo metodo di impianto endosseo. V° Congresso Nazionale SIOCMF, Napoli 1962, pp23-29.
- Tramonte S.M.: A proposito di una modificazione sugli impianti alloplastici. *Rass.Trim.Odont.*, 1963; 44(2): 129 – 136.
- Tramonte S.M.: L'impianto endosseo razionale – Lusy, Milano, 1964, pp2-67.
- Tramonte S.M.: Intrabone implants with drive screws – *The journal of implants and Transplant Surgery*, 1965; 6: 43-47.
- Tramonte S.M.: Implante endosseo racional. Metodo personal. *Actos de la IV reunion de la S.E.I.* , Madrid, 1965, pp 80-83.
- Tramonte S.M.: A further report on intra-osseous implants with improved drive screws – *The Journal of Implant and Transplant Surgery* vol.11 pgs 35-37, 1965
- Tramonte SM.: On some interesting cases of intra-osseous implantation using self-cutting screws. *Ann Stomatol (Roma)*. 1966; 15(4): 313-23.
- Tramonte SM.: Intraosseous implantation, prejudices and fears *Inf Dent.* 1966; 48(8): 798-801.
- Tramonte S.M.: L'impianto a vite autofilettante – *Riv. Ital. Implant.*, 1966; 1: 22- 25.

Tramonte S.M.: Implantologie endo-osseuse: préjugées et craintes – *Ifor. Dentarie*, 1966; 8: 23-30.

Tramonte S.M. : Su alcuni casi particolarmente interessanti di impianto endosseo con vite autofilettante. *Ann. Stom. Vol. XV*, 1966; 4: 45-48.

Tramonte S.M.: L'impianto a vite autofilettante – *Riv. Ital. Implant. N°1/1966*

Tramonte SM.: Intraosseous self-threading implantations. Personal method *Dent Cadmos*. 1971; 39(2):192-208.

Tramonte S.M.: L'impianto endosseo autofilettante – *Dental Cadmos*, 1971; 2: 61-64.

Tramonte S.M.: La vite autofilettante. Ed Lusy, Milano, 1974, pp 2-53.

Tramonte S.M.: L'impianto a vite autofilettante nella sostituzione di un solo dente mancante. *Riv. Eur. Implant.*, 1978; 4: 15-21.

Tramonte S.M.: L'impianto endosseo a vite autofilettante – *Riv. Eur.Implant.*, 1979; 1: 25-29.

Tramonte S.M.: Implantologia: sì o no? – *Riv. Eur. Implant. N°1*: 31-35, 1980

Tramonte S.M.: Su di un caso particolarmente interessante. *Riv. Eur. Implant.*, 1981; 2: 12-25.

Tramonte S.M.: Vite endossea autofilettante – *Attualità Dentale*, 1989; 7: 44-49.

TramonteS.M.: Self-threading endosseouscrew. *Attual Dent.* 1989; 5(7): 44-49.

Tramonte S.M. L'impianto endosseo a vite autofilettante. Trent'anni di esperienza personale. Milano: Editrice Cominplant; 1991.

Tramonte S.M. L'impianto endosseo a vite a carico immediato. Atti del 27° Meeting Internazionale Impianti e Trapianti Dentari del GISI. Bologna: 1997. p. 71.

Garbaccio D. -"Vite Autofilettante Bicorticale di Garbaccio"- *Dental Post* 4/1974

Garbaccio D. -"Vite Bicorticale"-Atti del V Meeting Internazionale del G.I.S.I.-Bologna 1975
36. S.O.I.A. (Società Odontologica Impianti Alloplastici): *Bollettino Odonto-Implantologico* – Lugli, Roma 1977

Garbaccio D. -"La vite autofilettante bicorticale: principio bio-meccanico, tecnica chirurgica e risultati clinici"-*Dental Cadmos* 6/1981

Garbaccio D. -"La vite autofilettante bicorticale di Garbaccio"-*Odontostomatologia ed Implantoprotesi* 1/1983

Garbaccio D. -"La vite autofilettante bicorticale: estensione alle zone edentule distali superiori ed inferiori"-*Dental Cadmos* 2/1983

Garbaccio D. - Grafelmann H.L. -"Die Bicortical-schraube fur den Einzelzahnersatz"-*Orale Implantologie* 3/1986