



## Clinical Case Report

Anterior Maxillary Single-Tooth Restoration  
with Osseous GTR Procedures  
and FILO Implantology Approach

Dr. Alvaro Bastida

Medical & Surgical Degree, Stomatologist.  
Private practice. Vigo, Spain

THE SPACE FREE OF STEREOTYPES

[opdeco.org](http://opdeco.org)

# Clinical Case Report

Dr. Alvaro Bastida

## Key words

Single tooth restoration, aesthetic important area, severe atrophy of alveolar ridge, osseous guided tissue regeneration (GTR), one-piece implant, flapless, immediate loading, FILO implantology.

## Background

Patient: 35 years old male. Non-smoker. Medical History within normal limits (WNL)

Initial Presentation: May 2014

Treatment Completed: December 2014

## Clinical Assessment

Temporomandibular Joints: WNL.

Extraoral: WNL; low lip and smile line.

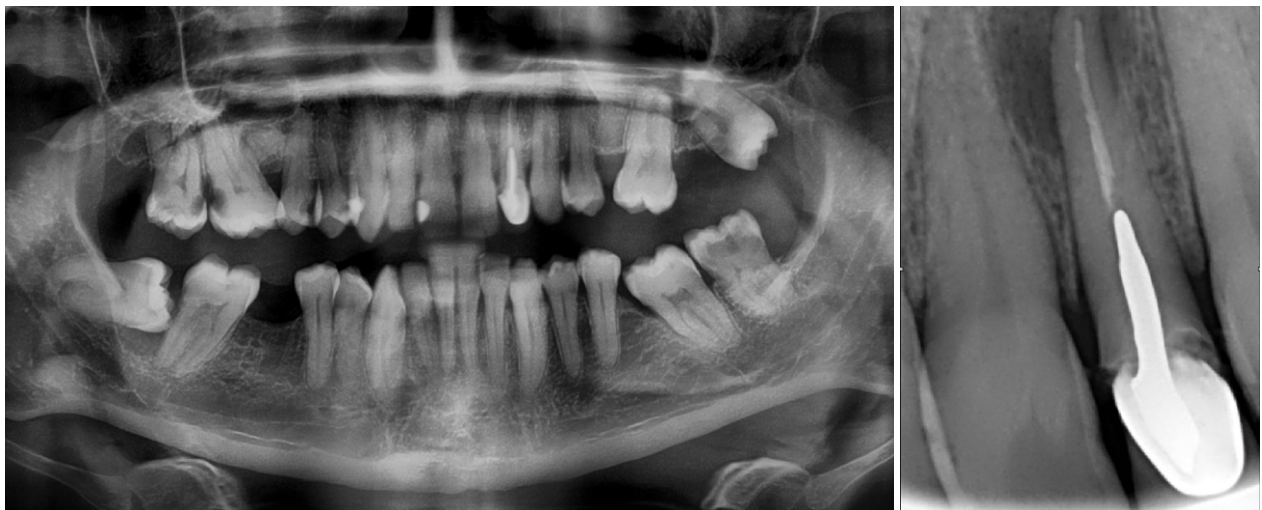Intraoral: The patient had left lateral incisor mobility and a buccal active fistula with purulent discharge.

Occlusion: Class I.

Periodontal: WNL

## Radiographic Assessment

Periapical X-ray and OPG showed a periapical cyst

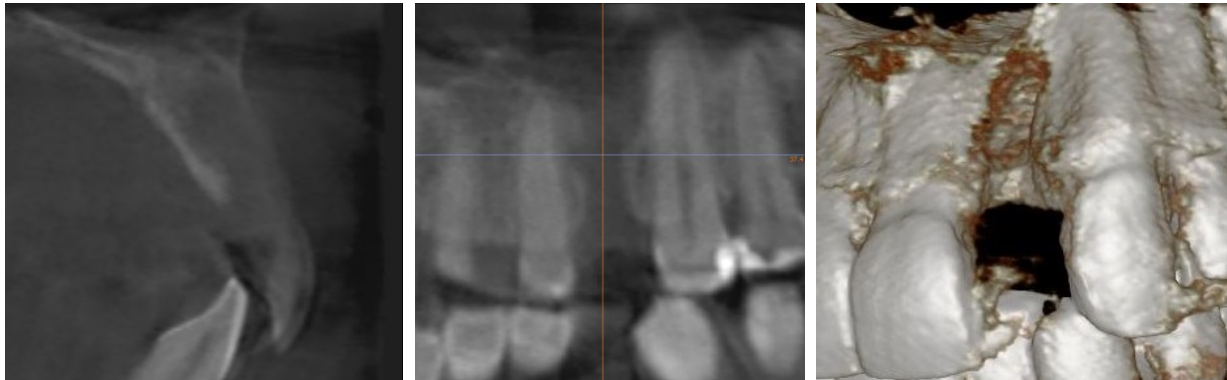


## Treatment Plan

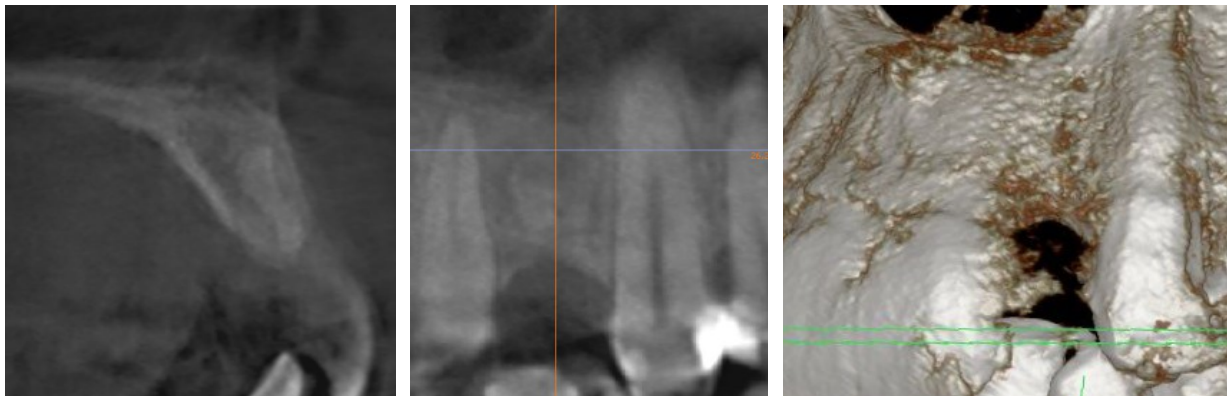
1. Antibiotherapy with Amoxicilin, 750 mg / 8 h. / 1 week previous to surgery.
2. Left lateral incisor extraction.
3. Osseous GTR.
4. After 6 months, one-piece implant placement (ROOTT COMPRESSIVE). Temporary crown.
5. After 2 months, metal-ceramic final crown placement.

## Tooth extraction & Osseous GTR

It was necessary a careful tooth extraction, with complete removing of the cyst infected tissues by Molt curette. There was a great bone destruction. Only the palatal tooth socket wall was preserved



Then it was performed an osseous guided tissue regeneration (GTR) using synthetic nano-crystalline hydroxyapatite bone substitution material (OSTIM TM) and collagen resorbable barrier membrane. Six months later the bone had grown enough



## FILO Implantology

After osseous GTR it was possible to put an implant restoration. It was performed following the FILO implantology principles:

- Flapless surgery
- Immediate Loading
- One-piece implants

This approach allows a short treatment time, simple to perform and safe results.

First FILO principle is a **flapless surgery**. Periosteum provides 70% bone blood supply. Laboratory research has shown that architecture of the trabeculae inside a hollow bone is destroyed by simply raising a full thickness flap and without performing any surgery on the bone itself. Raising a flap will be itself endanger the implant's stability. Avoiding a flap helps to preserve the bone flow nutrients and the available spongy bone remains constant after implant placement. Moreover there are no scalpel or suture, therefore less surgical time and better postoperative.

Second FILO principle is **immediate loading**. We can short treatment time and reducing patient discomfort/inconvenience with immediate loading implants. This treatment approach has been studied and has shown predictable results. Immediate implant loading achieved similar success rates as those reported in the delayed 2-stage approach. Primary implant stability is a key factor to consider before attempting immediate implant loading

Third FILO principle is using of **one-piece implants**. There are an experience of over 50 years using this kind of implants. They are solid fixations, without hollow pieces, little screws or connections as two-piece implants. This avoids typical problems: loosened or broken screw, peri-implantitis by microgaps, breaking implant walls... Thin one-piece implant can withstand the same load than a two pieces wider implant.



In the present case it was placed a ROOTT COMPRESSIVE implant (TRATE AG company). This one-piece implant has interesting features that fit very well to FILO approach:

#### Conical shape

with small apical diameter, suitable to transgingival insertion in flapless surgery and to bypass anatomical structures as maxillary sinus and mandibular nerve and platform switching to improve soft tissue adaptation.

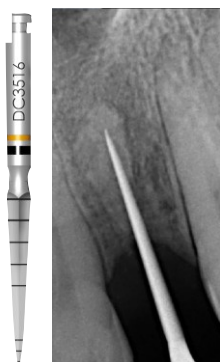#### Compressive threads

that compact cancellous bone improving its quality by corticalization effect. They also get easily high torque and primary stability. This is ideal for immediate loading.

#### Implant neck

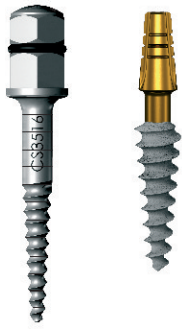with a polished surface and narrow diameter, very well tolerated by soft tissues even no attached gingiva. This prevents peri-implantitis and avoid gingival grafts in many cases. And it has an special feature: it is bendable 15° to 20° to adjust the abutment slope angle. So we can put parallel abutments even if implant insertion has not been parallel.

## Implant Surgery



#### Pilot Drill

Drilling is transgingival, without punch. A periapical X-ray with the pilot drill is required to verify the proper direction of insertion. The final drilling depth is determined by bone height plus gingival thickness at the drilling point. In the present case the bone lenght from crest cortical to nasal floor cortical was 16 mm and the gingival thicknes was 3 mm. Then the drilling depth was 19 mm. Whenever possible it is suitable to reach the opposite cortical with the drill tip. That way, when the implant is inserted, it will get a double retention way: bicorticalization – mechanical anchoring in both cortical and osseointegration into the cancellous bone.



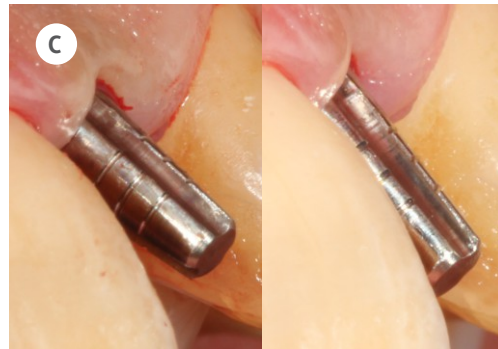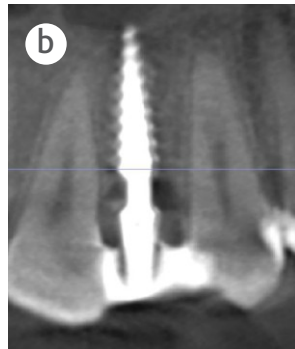
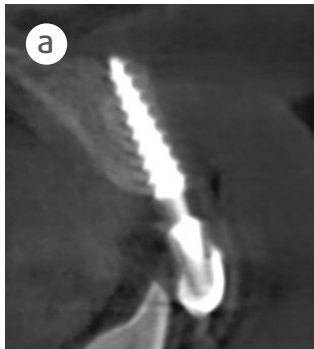
### Compressive Screw

This instrument is inserted manually, with wrench. It condenses the cancelous bone making a corticalization effect in soft bone improving its quality and prepares the implant socket.

### Compressive Implant

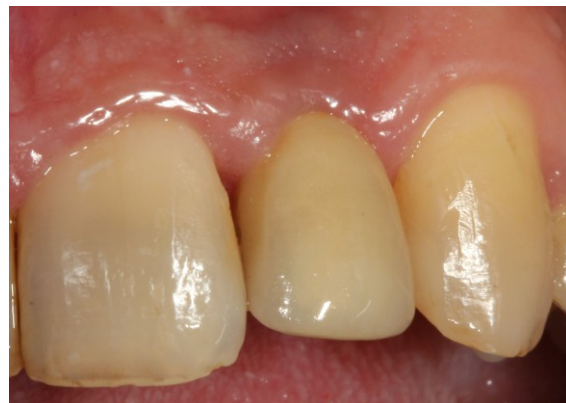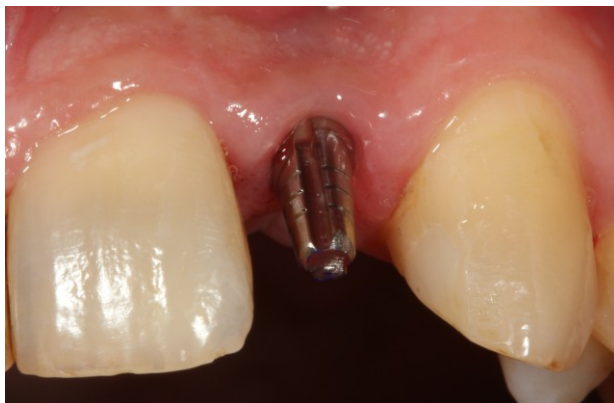It was chosen 4.0 mm diameter, 16.0 mm length size. It is inserted manually, with wrench, until reach the opposite cortical—in the present case the nasal floor. It is very important to achieve primary stability by at least 35 Nw/cm<sup>2</sup> insertion torque.

The direction of implant insertion followed the bone crest axis. So that the abutment was a little bit prominent to buccal. This was corrected immediately after insertion by bending implant neck to a proper prosthetic position. The bending is an easy but sensitive procedure. It requires especial training.



## Prosthesis

Immediately after surgery a temporary plastic crown is placed and splinted to adjacent teeth by fiber glass strip. The temporary crown remained in non-functional immediate loading. The temporary non-functional way is recommended in anterior maxillary. After two months hard and soft tissue are healed and we can take steps to make the final crown. Impression cup, burn out cup and implant analog delivered with each ROOTT COMPRESSIVE implant are very suitable in prosthetic phase. Finally the final metal-ceramic crown is placed and fixed with resin cement



## Commentary

The FILO implantology is a short in time, simple to use and safe in results approach to implant restoration. It is very suitable in bone atrophy situations, avoiding many times bone graft procedures. However there are some cases where it is necessary and appropriate to associate the FILO principles with GTR procedures. In the presented case they were achieved excellent results both functional and aesthetic.