

PennHIP Report

Referring Veterinarian: Dr Amber Herron

Clinic Name: Caring Hands Veterinary Hospital (Billings, MT)

Email: aherronvet@gmail.com

Clinic Address: 533 So. 24th St. W
Billings, MT 59102

Fax: (406) 652-0551

Patient Information

Client: Mailloux, Trina

Tattoo Num:

Patient Name: Vira

Patient ID: 44802

Reg. #

Reg. #

PennHIP Num: 172270

Microchip Num: 605335802

Species: Canine

Breed: AUSTRALIAN SHEPHERD

Date of Birth: 08 Feb 2020

Age: 26 months

Sex: Female

Weight: 62.7 lbs/28.4 kgs

Date of Report: 20 Apr 2022

Findings

Distraction Index (DI): Right DI = 0.27, Left DI = 0.32.

Osteoarthritis (OA): No radiographic evidence of OA for either hip.

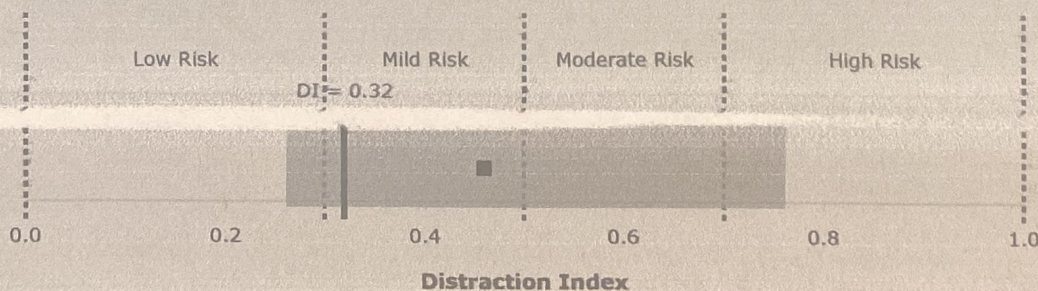
Interpretation

Distraction Index (DI): The laxity ranking is based on the hip with the greater laxity (larger DI). In this case the DI used is 0.32.

OA Risk Category: The DI is between 0.31 and 0.49. This patient is at mild risk for hip OA.

Distraction Index Chart:

AUSTRALIAN SHEPHERD



BREED STATISTICS: This interpretation is based on a cross-section of 1878 canine patients of the AUSTRALIAN SHEPHERD breed in the AIS PennHIP database. The gray strip represents the central 90% range of DIs (0.26 - 0.76) for the breed. The breed average DI is 0.46 (solid square). The patient DI is the solid circle (0.32).

SUMMARY: The degree of laxity (DI = 0.32) falls within the central 90% range of DIs for the breed. This amount of hip laxity places the hip at a mild risk to develop hip OA. No radiographic evidence of OA for either hip.