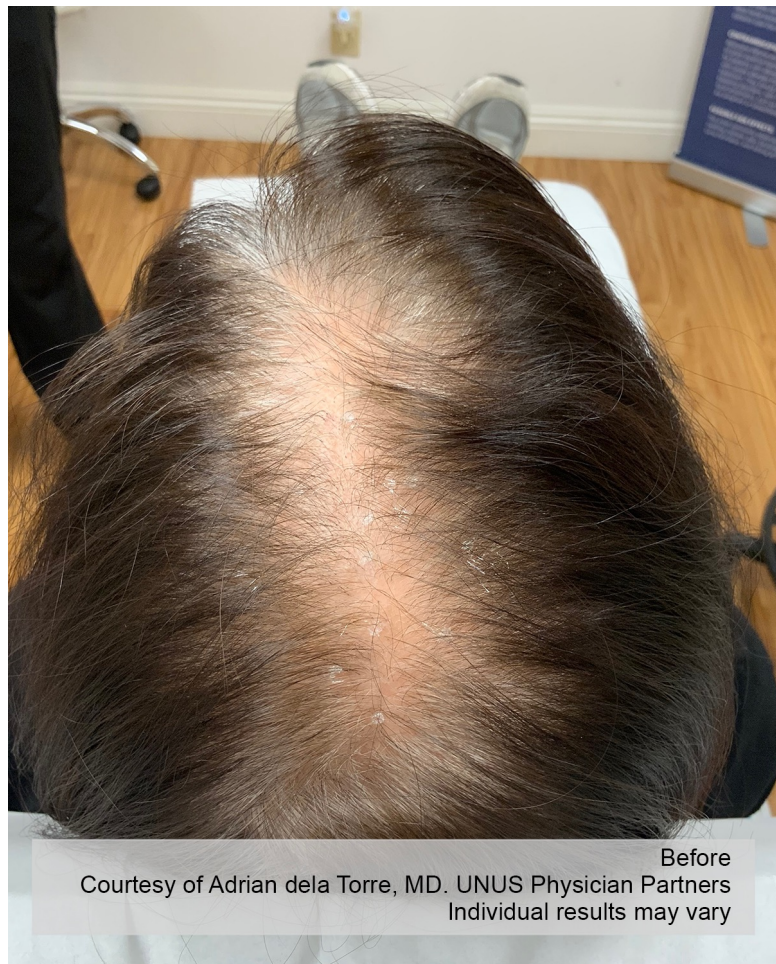
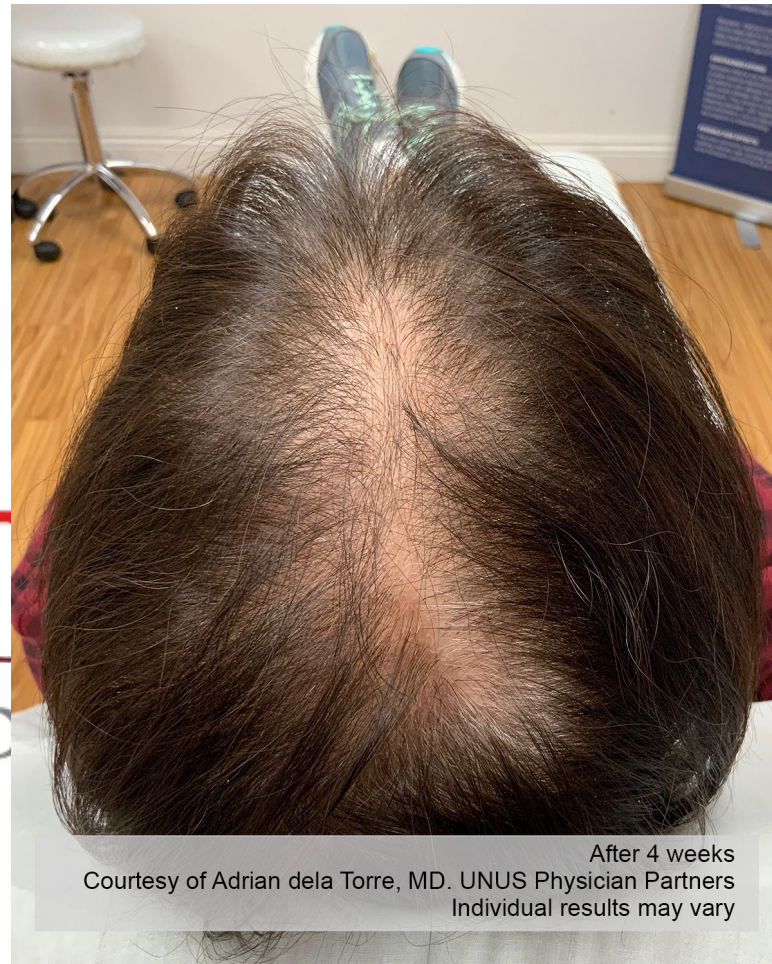
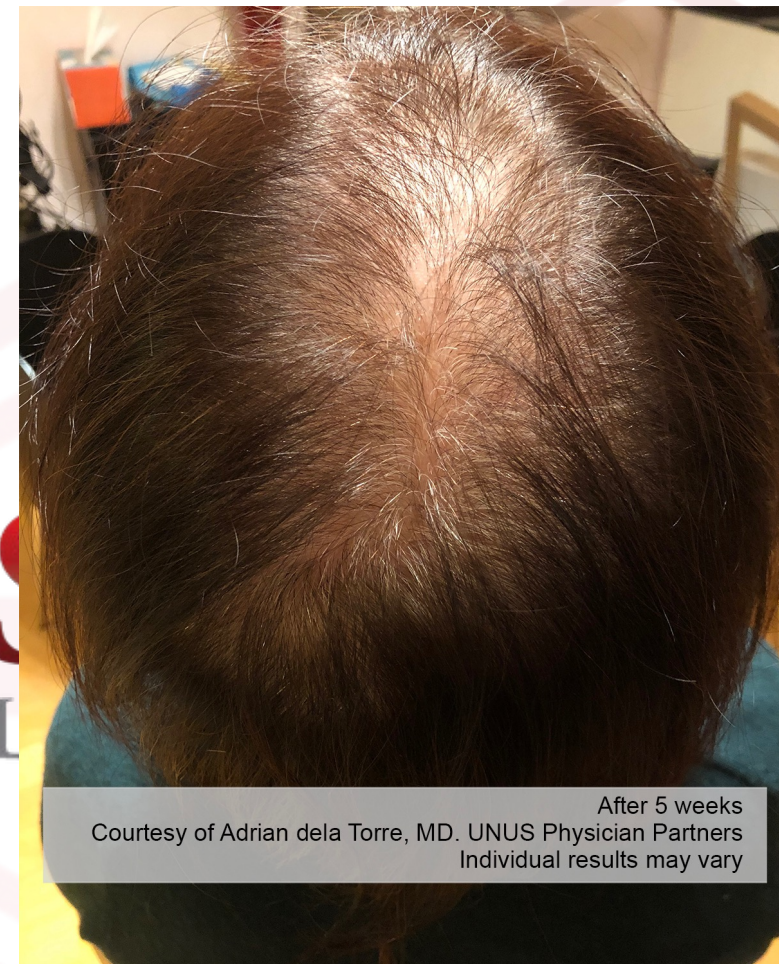
Patient Case Study



Before



4 weeks



5 weeks