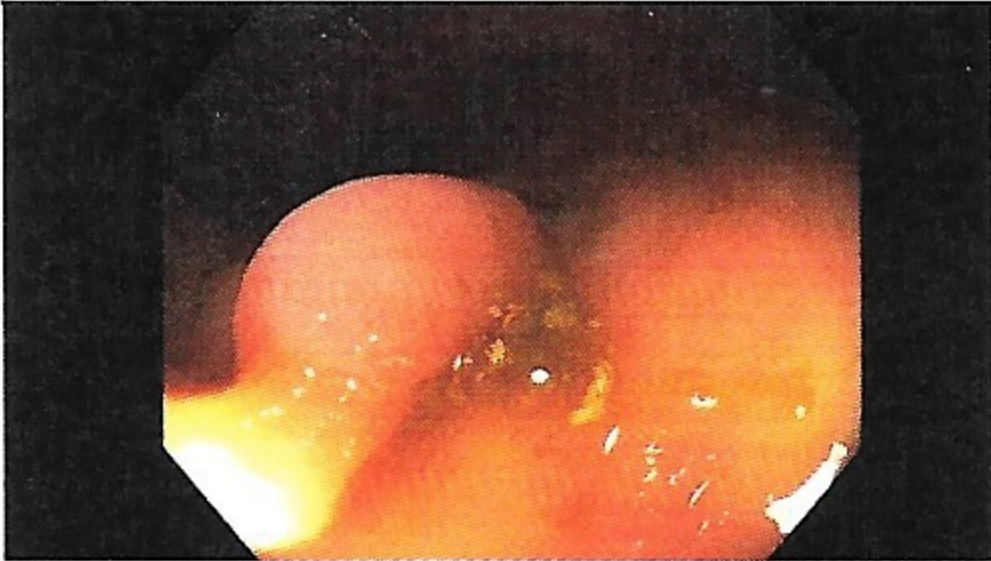

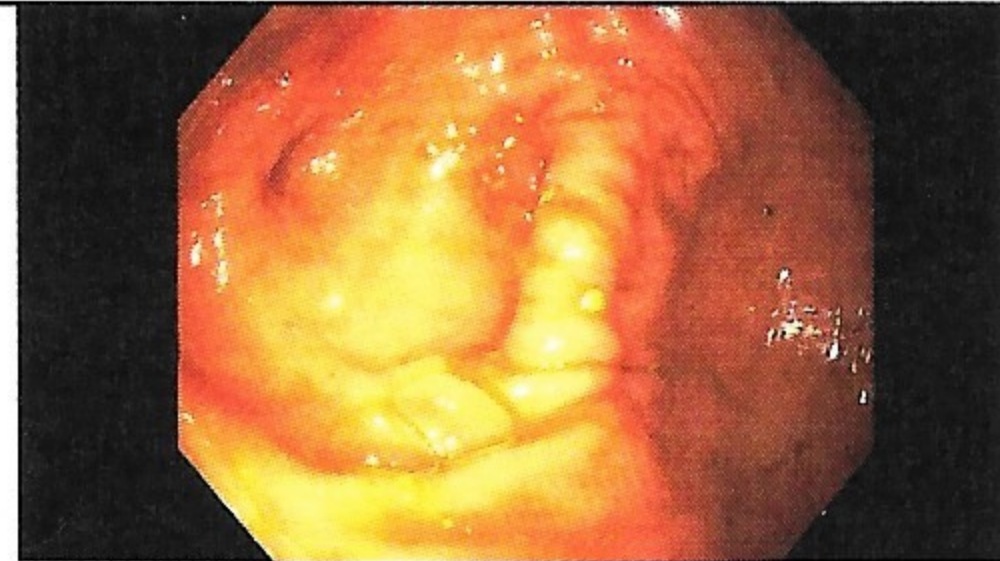
Physician's GI Procedure Report

MIM #561

Patient Name:	Rickey	Procedure Date:	10/24/2019 10:20 AM
Admit Type:	Outpatient	Gender:	Male
Room:	GI MEMORIAL OR 01 UNCH	Instrument Name:	PCF-H190DL-2942948
Note Status:	Held		



4 Ascending Colon



5 Cecum

Impression: - One 9 mm polyp in the ascending colon, removed with a cold snare. Resected and retrieved. Clips (MR conditional) were placed.

Recommendation:

- Patient has a contact number available for emergencies. The signs and symptoms of potential delayed complications were discussed with the patient. Return to normal activities tomorrow. Written discharge instructions were provided to the patient.
- Resume previous diet.
- Continue present medications.
- Await pathology results.
- Repeat colonoscopy in 5 years for surveillance.
- Return to referring physician (date not yet determined).

Procedure Code(s): --- Professional ---
45385, Colonoscopy, flexible; with removal of tumor(s), polyp(s), or other lesion(s) by snare technique

Diagnosis Code(s): --- Professional ---
Z12.11, Encounter for screening for malignant neoplasm of colon
D12.2, Benign neoplasm of ascending colon

CPT ® 2018 © American Medical Association. All rights reserved.

The codes documented in this report are preliminary and upon coder review may be revised to meet current compliance requirements.

Held

TODD HUNTLEY BARON, MD

Rahman Nakshabendi, MD

RAHMAN NAKSHABENDI, MD
10/24/2019 11:10:55 AM