

Physician's GI Procedure Report

MIM #561

Patient Name:	Rickey Esto	Procedure Date:	10/24/2019 10:20 AM
Admit Type:	Outpatient	Gender:	Male
Room:	GI MEMORIAL OR 01 UNCH	Instrument Name:	PCF-H190DL-2942948
Note Status:	Held		

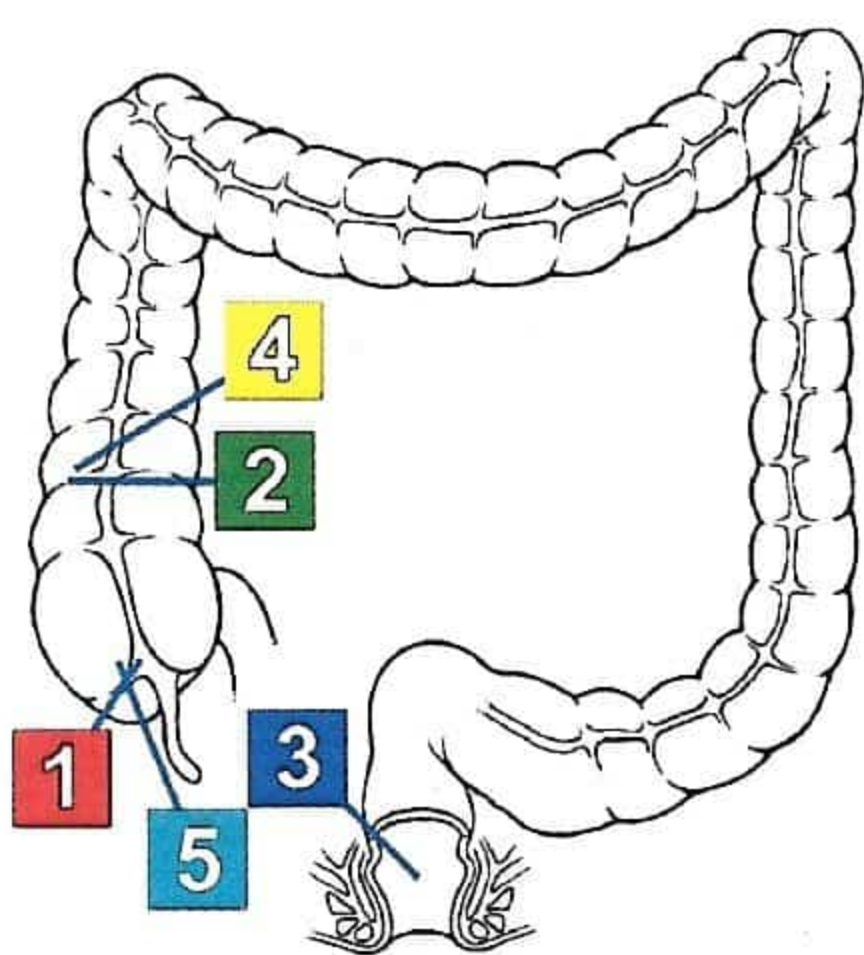
Procedure: Colonoscopy
Indications: Screening for colorectal malignant neoplasm
Providers: TODD HUNTLEY BARON, MD, RAHMAN NAKSHABENDI, MD, LAUREN E. MOSKAL, Christina Torres, Carolina Montes torres, Boosaba Wareham, Technician
Referring MD:
Medicines: See the Anesthesia note for documentation of the administered medications
Complications: No immediate complications.

Procedure: Pre-Anesthesia Assessment:
 - Prior to the procedure, a History and Physical was performed, and patient medications and allergies were reviewed. The patient's tolerance of previous anesthesia was also reviewed. The risks and benefits of the procedure and the sedation options and risks were discussed with the patient. All questions were answered, and informed consent was obtained. Prior Anticoagulants: The patient has taken Coumadin (warfarin), last dose was 4 days prior to procedure. ASA Grade Assessment: IV - A patient with severe systemic disease that is a constant threat to life. After reviewing the risks and benefits, the patient was deemed in satisfactory condition to undergo the procedure. After obtaining informed consent, the scope was passed under direct vision. Throughout the procedure, the patient's blood pressure, pulse, and oxygen saturations were monitored continuously. The Colonoscope was introduced through the anus and advanced to the cecum, identified by appendiceal orifice and ileocecal valve. The colonoscopy was performed without difficulty. The patient tolerated the procedure well. The quality of the bowel preparation was adequate to identify polyps 6 mm and larger in size. The appendiceal orifice was photographed. The quality of the bowel preparation was adequate to identify polyps 6 mm and larger in size. [Anatomical Structures].

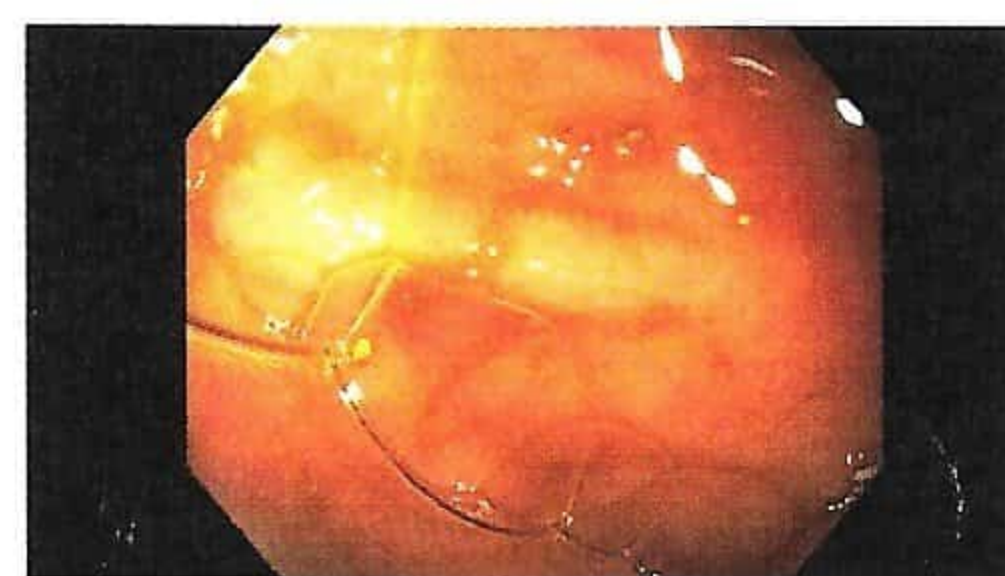
Findings:

- A 9 mm polyp was found in the ascending colon. The polyp was semi-pedunculated. The polyp was removed with a cold snare. Resection and retrieval were complete. To prevent bleeding after mucosal resection, two hemostatic clips were successfully placed (MR conditional). There was no bleeding at the end of the procedure.

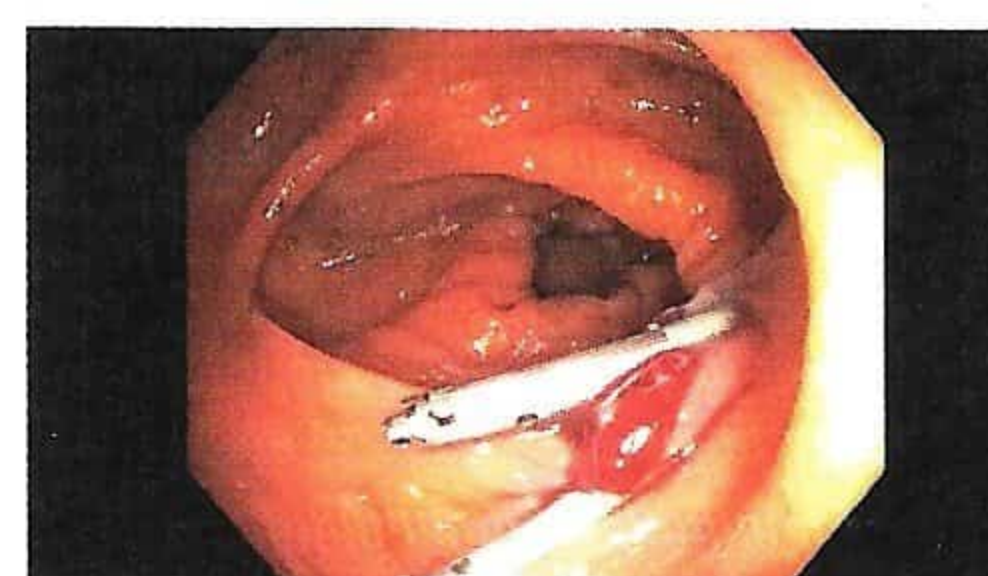Add'l Images:



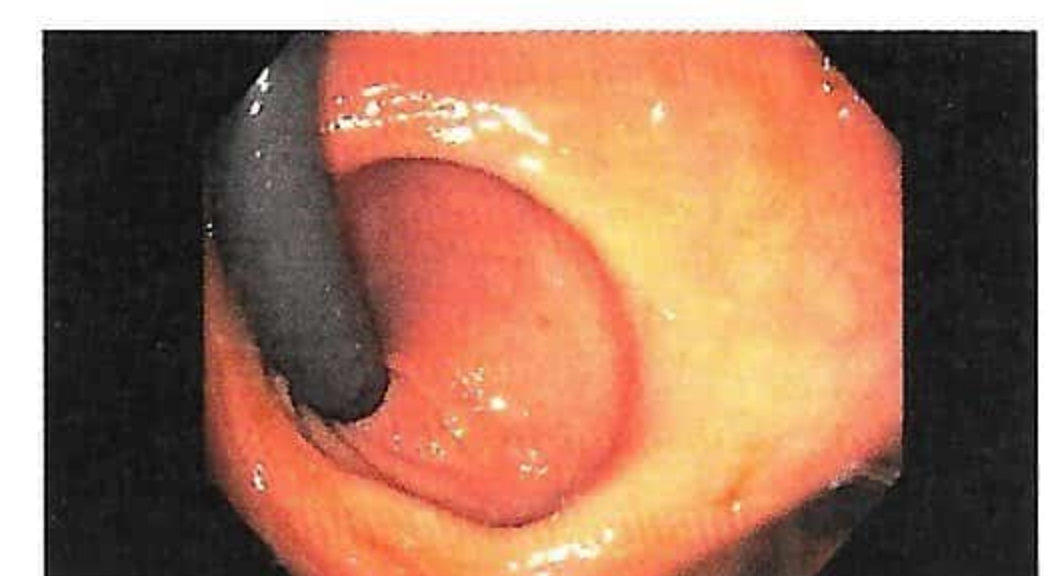The Colon



1 Appendiceal Orifice



2 Ascending Colon



3 Rectum