

Growth pattern of Rahman syndrome

Toshiki Takenouchi^{1,2}  | Tomoko Uehara¹  | Kenjiro Kosaki¹ | Seiji Mizuno³

¹ Center for Medical Genetics, Keio University School of Medicine, Tokyo, Japan

² Department of Pediatrics, Keio University School of Medicine, Tokyo, Japan

³ Department of Pediatrics, Central Hospital, Aichi Human Service Center, Aichi, Japan

Correspondence

Kenjiro Kosaki, MD, Center for Medical Genetics, Keio University School of Medicine, 35 Shinanomachi, Shinjuku-ku, Tokyo, 160-8582, Japan.
Email: kkosaki@keio.jp

Funding information

Ministry of Health, Labour and Welfare; Research on rare and intractable diseases; Japan Agency for Medical Research and Development; Initiative on rare and undiagnosed diseases. Grant number: JP17ek0109151

Recently, in a cohort study with “overgrowth syndrome with intellectual disability,” five subjects were reported to have de novo heterozygous truncating variants in *HIST1H1E*, which encodes linker histone H 1.4. However, their growth pattern appeared complex that four out of five patients had a decreasing height percentile over time, and three of these patients began with above-average heights but exhibited reductions to average heights or below when they were older. Herein, we report a female patient with intellectual disability and distinctive facial features including a wide nasal bridge and prominent cheek bones. She did not exhibit skeletal overgrowth, but she had a short stature at 21 years of age. An exome analysis identified a de novo heterozygous 1-bp duplication in *HIST1H1E*, that is, c.433dup p.(Ala145Glyfs*51). The physical features of the proposita were essentially the same as those observed in patients with the aforementioned *HIST1H1E*-related overgrowth syndrome. Our review of the growth trajectories in seven patients showed that five of seven patients did not exhibit skeletal overgrowth. This “lack of overgrowth in overgrowth syndrome” is reminiscent of a subset of patients with a short stature who have Sotos syndrome, a prototypic overgrowth syndrome. Considering this complexity in growth, this newly identified condition should be referred to as Rahman syndrome.

KEYWORDS

HIST1H1E, histone, exome, overgrowth, Rahman syndrome, Sotos syndrome

1 | INTRODUCTION

The dysregulation of histone modification leads to overgrowth syndromes, such as Sotos syndrome caused by variants in *NSD1* (Kurotaki et al., 2002) and Weaver syndrome caused by variants in *EZH2* (Tatton-Brown et al., 2011). Overgrowth syndromes are sometimes accompanied by intellectual disability in addition to skeletal overgrowth. In a recent study of 710 individuals with skeletal overgrowth, five subjects were reported to have de novo heterozygous truncating variants in *HIST1H1E*, which encodes linker histone H 1.4. These five patients exhibited characteristic growth pattern, intellectual disability, and distinctive facial features, suggesting a novel recognizable syndrome. Tatton-Brown et al. (2017) noted that at least four out of five patients exhibited a temporal change from overgrowth to a short stature by their teens. We provide further evidence to support that this linear growth pattern.

2 | CLINICAL REPORT

The proposita was born at 36 weeks of gestation. Her birth weight was 2,876 g (+1.6 SD), her length was 49 cm (+1.4 SD), and her head circumference was 33.4 cm (+0.9 SD). At the age of 3 years and 3 months, her height was 90.0 cm (−1.0 SD), her weight was 13.9 kg (+0.2 SD), and her head circumference was 48.5 cm (−0.2 SD). At the age of 15 years, her height was 151.1 cm (−1.1 SD), her weight was 49 kg (−0.3 SD), and her head circumference was 54.4 cm (−0.1 SD). The patient exhibited a developmental delay, and she stood with support at 11 months of age and began to walk by herself at 30 months. She spoke her first words at 3 years of age. She had a severe intellectual disability with an intellectual quotient of 18 and a “friendly and happy predisposition.” At the age of 21 years, her height was 151.8 cm (−1.4 SD), and her head circumference was 54.4 cm (0SD); these measurements were compatible with relative

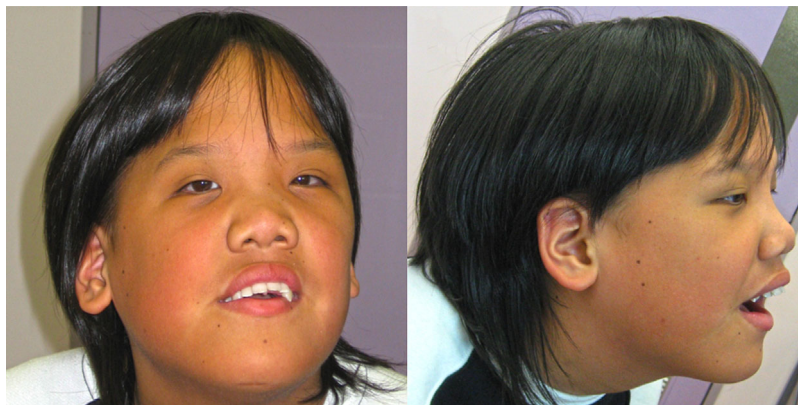

FIGURE 1 Facial photographs. Note the wide nasal bridge, prominent cheek bones, telecanthus, short palpebral fissures, high hairline, and long philtrum. [Color figure can be viewed at wileyonlinelibrary.com]

macrocephaly. Her father was 166 cm tall and her mother was 158 cm tall, yielding a calculated target height of 155.5 cm. On examination, she had distinctive facial features with wide nasal bridge, prominent cheek bones, telecanthus, short palpebral fissures, high hairline, and long philtrum (Figure 1). Other physical features included a high-arched palate, wide uvula, strabismus, epicanthal folds, simple auricles, auditory hypersensitivity, high-pitched voice, skin with hyperkeratosis, and multiple lentigines. At the age of 21 years, she was found to have early onset cataracts as a complication of diabetes mellitus. She did not have epilepsy or congenital heart diseases.

3 | MOLECULAR ANALYSIS

The ethics committees of Keio University and Central Hospital, Aichi Human Service Center approved the present research protocol. The study was conducted in agreement with the World Medical Association Declaration of Helsinki. Written informed consent was obtained, and peripheral blood samples were collected from the proposita and her parents. A G-band analysis showed a normal female karyotype of 46,XX. DNA was extracted using the standard

phenol extraction method. A microarray analysis using SurePrint G3 Unrestricted CGH Array 1 × 1 M (Agilent Technologies, Santa Clara, CA) was negative. A whole exome analysis was performed in trio using SureSelect XT Human All Exon V6 (Agilent Technologies) on a HiSeq 2500 platform (Illumina, San Diego, CA), as described previously (Takenouchi et al., 2015). The analysis revealed a de novo heterozygous 1bp duplication in exon 1 in *HIST1H1E* [NM_005321.2], that is, c.433dup/chr6 (GRCh37): g.26157051dup, which predicted a premature termination of the protein, that is, p.(Ala145Glyfs*51). The duplication was located within the 12-bp region (chr6 (GRCh37): g.26157048-g.26157059) in the carboxyl terminal domain of HIST1H1E in which all previously reported variants have been located (Helsmoortel et al., 2015; Tatton-Brown et al., 2017).

4 | DISCUSSION

In the present report, we document a female patient with intellectual disability and a heterozygous de novo truncating variant in *HIST1H1E*. She had a mild short stature and distinctive facial

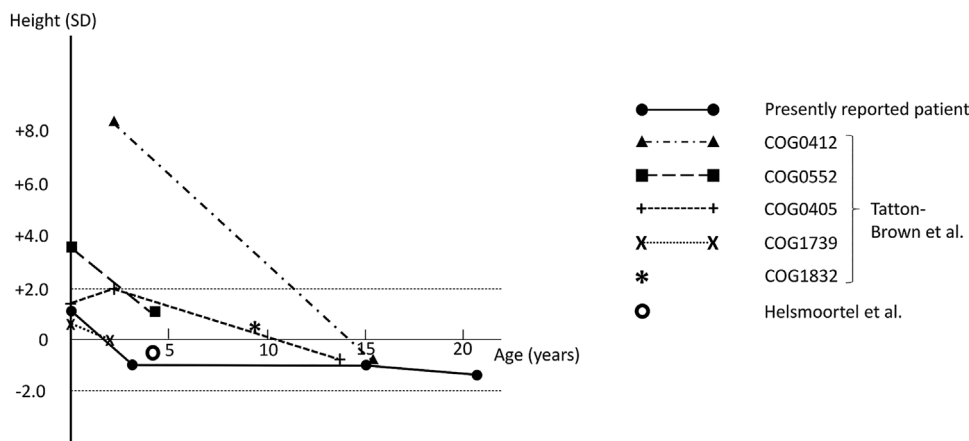


FIGURE 2 Review of growth characteristics of patients with *HIST1H1E* variants. The vertical axis represents the standard deviation in height. The horizontal axis represents patient age. Note that all seven patients showed decreasing height percentile during their childhood and adolescence

features including wide nasal bridge and prominent cheek bones; these characteristics were remarkably similar to those reported in a recent paper by Tatton-Brown et al. (2005) on patients with constitutional *HIST1H1E* variants. Although the disorder was reported as a form of “overgrowth with intellectual disability,” the presently reported patient did not exhibit skeletal overgrowth. The present observation supports that skeletal overgrowth might not be an essential feature of *HIST1H1E*-related disorder.

We delineated the growth patterns of a total of seven patients, including the presently reported patient, with overgrowth syndrome caused by *HIST1H1E* variants. All seven patients exhibited a progressive reduction in height percentile with age. They all reached average heights or below when they were older (Figure 2). In the presently reported patient, her final height might have been influenced by her poorly controlled diabetes (Helsmoortel et al., 2015). The present observation further supports the notion that skeletal overgrowth is not an essential feature of *HIST1H1E*-related disorder. Considering this complexity in growth, this newly identified *HIST1H1E*-related disorder should be referred to as Rahman syndrome.

The presently reported patient had a short (not tall) stature during her childhood. This observation agrees with findings for the delineation of a prototypic overgrowth syndrome, Sotos syndrome: in a cohort of *NSD1*-positive patients, 26/151 (17%) patients with intragenic variants in *NSD1* did not have a tall stature (Tatton-Brown et al., 2005). The short stature of the presently reported patient might have been influenced by variants in genes other than *HIST1H1E*. However, our exome analysis did not reveal any variant that would cause a short stature.

In conclusion, skeletal overgrowth may not be an essential feature of *HIST1H1E*-related disorder. Even without skeletal overgrowth, this condition may be recognizable through facial features that are very similar across two ethnic groups, namely Caucasians and Japanese.

ACKNOWLEDGMENTS

The authors thank Mrs. Yumi Obayashi and Keiko Tsukue for their technical assistance in the preparation of this article. This work was

supported by Research on rare and intractable diseases from the Ministry of Health, Labour and Welfare, Japan, and Initiative on rare and undiagnosed diseases (Grant number: JP17ek0109151) from Japan Agency for Medical Research and Development.

ORCID

Toshiki Takenouchi  <http://orcid.org/0000-0002-7311-4135>

Tomoko Uehara  <http://orcid.org/0000-0002-1497-7686>

REFERENCES

- Helsmoortel, C., Vandeweyer, G., Ordoukhanian, P., Van Nieuwerburgh, F., Van der Aa, N., & Kooy, R. F. (2015). Challenges and opportunities in the investigation of unexplained intellectual disability using family-based whole-exome sequencing. *Clinical Genetics*, 88, 140–148.
- Kurotaki, N., Imaizumi, K., Harada, N., Masuno, M., Kondoh, T., Nagai, T., . . . Matsumoto, N. (2002). Haploinsufficiency of *NSD1* causes Sotos syndrome. *Nature Genetics*, 30, 365–366.
- Takenouchi, T., Yamaguchi, Y., Tanikawa, A., Kosaki, R., Okano, H., & Kosaki, K. (2015). Novel overgrowth syndrome phenotype due to recurrent de novo *PDGFRB* mutation. *Journal of Pediatrics*, 166, 483–486.
- Tatton-Brown, K., Douglas, J., Coleman, K., Baujat, G., Cole, T. R., Das, S., . . . Rahman, N. (2005). Genotype–phenotype associations in Sotos syndrome: An analysis of 266 individuals with *NSD1* aberrations. *American Journal of Human Genetics*, 77, 193–204.
- Tatton-Brown, K., Hanks, S., Ruark, E., Zachariou, A., Duarte Sdel, V., Ramsay, E., . . . Rahman, N. (2011). Germline mutations in the oncogene *EZH2* cause Weaver syndrome and increased human height. *Oncotarget*, 2, 1127–1133.
- Tatton-Brown, K., Loveday, C., Yost, S., Clarke, M., Ramsay, E., Zachariou, A., . . . Rahman, N. (2017). Mutations in epigenetic regulation genes are a major cause of overgrowth with intellectual disability. *American Journal of Human Genetics*, 100, 725–736.

How to cite this article: Takenouchi T, Uehara T, Kosaki K, Mizuno S. Growth pattern of Rahman syndrome. *Am J Med Genet Part A*. 2018;176A:712–714.

<https://doi.org/10.1002/ajmg.a.38616>