



Diagnosis of hip dysplasia in dogs according to the guidelines of the Fédération Cynologique Internationale (FCI)

Tijana Kukurić^{a*}, Bojan Toholj^a, Ljubica Spasojević Kosić^a, Ivan Stančić^a

^aUniversity of Novi Sad, Faculty of Agriculture, Department of Veterinary Medicine, Novi Sad, Serbia

*Author contact: tijana.kukuric@gmail.com

ABSTRACT

The detection of hip dysplasia in dogs is a significant diagnostic challenge, which aims to eliminate disease from the population. The aim of this paper is to determine the presence of hip dysplasia in our patients and to emphasize the importance of diagnosis and prevention of the disease. During the research, a total of 14 dogs were examined. We used standards for evaluation of hip dysplasia according to the FCI guidelines. Evaluation is formed especially for each hip joint, and the final estimate of dysplasia is guided by that hip joint that give a poorer score. The results of the study show that: five (which is 36%) of 14 examined dogs, were dysplastic. The most presented parameter (13 dogs) was a insufficient coverage of femur head with acetabulum edge, while the least-represented parameter (2 dogs) was the presence of Morgan lines. Considering the existence of hip joint problems, a higher percentage of dogs should be covered by preventive examinations. Owners have a main role in the prevention of this disease, therefore proper education of the owners is a key in the elimination of the disease.

KEY WORDS: Hip dysplasia, evaluation, FCI, parameters, dogs, rentgenograms

Introduction

Canine hip dysplasia (HD) is significant and relatively frequent disease of dogs. The disease has a strong hereditary component. However, non-genetic factors such as nutrition, lack of movement or intensive training at an early age are also important for the development and manifestation of the disease (Barr, 1987). Heavy dogs, with rounded conical conformation, less developed muscles and early physical maturity are the most affected (Mikkelsen, 2007). It has been noted that breeds with a more developed musculature, with a flat foot position, are less susceptible to disease (Riser, 1975). According to the definition, hip dysplasia is an abnormality in development. Puppies are therefore born with normal hips, and the instability of coxofemoral joints occurs during postnatal re-engineering (Kealy, 2005). It is generally accepted that the initial instability factor is the initial instability of the joint. Then follows a vicious circle, in which the basic instability of the joint worsens with every movement and weight, stimulating the femoral head beyond its anatomical position (Richardson, 2010). Clinical signs related to HD can be manifested as mild or occasional lameness to a clinical sings in which the signs are not expressed, as a consequence of the development of degenerative changes and pain (Fry, 1992). Diagnosis of hip dysplasia is performed by clinical examination and radiography. Clinical tests for early diagnosis of dog HD are based on the determination of increased joint mobility. The most common is the Ortolani test. Many organizations, such as the Orthopedic Animal Foundation (OFA), the Federation Cynologique Internationale (FCI) and the British Veterinary Association/Kennel Club (BVA/KC) have developed diagnostic protocols for HD. In addition, specific HD estimation programs have been developed: for example, Pennsylvania Hip Improvement Program (PennHIP) and Dorsolateral Subluxation Score (DSL) (Grundström, 2014). The Orthopedic Foundation for Animals, FCI and BVA/KC use standard ventro-dorsal projections for the radiographic recording of sedated or anaesthetized animals. The condition of the hip is assessed based on the described assessment methods. Radiographic assessment of the condition focuses on signs of incongruence, degenerative joint diseases and joint instability. Differences between programs are in evaluation methods (Verhoeven, 2012). The recommended age, for most diagnostic protocols, in which the radiographic assessment is performed is one year old, or over 18 months in large breeds (Grundström, 2014).

The aim of this research was analysis of the protocol for diagnosis of hip dysplasia according to the FCI system and its application to dogs of the appropriate age, as well as the setting of a decision algorithm for the existence of hip dysplasia in dogs, using the table.

Material and method

The investigation was carried out at the Veterinary teaching hospital, University of Novi Sad. A total of 14 dogs, different breeds and both sexes, were brought by their owners, for a diagnosis of hip dysplasia and obtaining the appropriate certificate. For regular diagnosis, it is necessary to respect all prerequisites: minimum of one year of age, and in addition, that he is permanently marked with a microchip. In order to enable the patient's correct positioning, sedation is necessary. For sedation we used medetomidine (Domitor®, Orion Corporation Orion Pharma, FIN) at a dose of 10-20 µg/kg. After i.m. applications, effects are seen within 10 to 15 minutes, in the form of sedation and muscle relaxation. After obtaining a X-ray images, we used atipamezol (Antisedan®, Orion Corporation Orion Pharma, FIN) as reverse drug to increase a speed recovery of dogs from sedation. We used the X-ray device ZooMax (EU), with the setting of parameters kV and mAs according to the size of the patient, and Agfa CR 10-X digital processing unit. We assessed the degree of hip dysplasia according to FCI guidelines. The estimate is based on a total of 6 parameters: Norberg angle, coverage of femur head, craniolateral edge of the acetabulum, presence of subchondral ossification, changes in the femur head and presence of Morgan lines. Each of these parameters has been assigned a certain numerical value, in order to obtain their final numerical value, and accordingly assign appropriate final estimates of degree of HD. Estimates according to the parameter are presented in Table 1.

Table 1.

Working table for assessing hip dysplasia according to the FCI guidelines (CFH- center of the femur head, DEA- dorsal edge of acetabulum)

Tabela 1.

Radna tabela za ocenu displazije kukova prema FCI smernicama (CFH- centar glave butne kosti, DEA- dorzalni rub acetabuluma)

| Points | 0 | 1 | 2 | 3 | 4 | 5 |
|--|---|---|--|---|--|---|
| <u>Parameter 1</u> Norberg angle | >105° | <105° | 100-105° | 90-100° | 80-90° | <80° |
| <u>Parameter 2</u> Coverage of femur head | CFH medially in relation to the DEA (>2mm). | CFH medially relative to the DEA (1-2mm). | CFH covers the DEA (>2mm). | CFH laterally in relation to the DEA (1-5mm), the joint space centrally extended. | CFH laterally in relation to the DEA (6-10mm), the joint space significantly expanded. | CGBK laterally in relation to the DEA (>10mm), the joint space in the luxation. |
| <u>Parameter 3</u> Craniolateral edge of the acetabulum | Parallel with the head of the femur bone. | Horizontal. | Slightly flattening, mild exostoses. | Moderately flattening, medium exostoses. | Significantly flattening, medium exostoses. | Edge is missing, the acetabulum is significantly deformed. |
| <u>Parameter 4</u> Presence of subchondral ossification | Narrow, evenly thickening. | Wide, evenly thickening. | Lateral thickening of the small degree, mild reduction medial. | Lateral thickening of the medium stage, medium reduction medial. | Laterally significant thickening, medially not visible. | Connected with the lateral pelvic edge or missing. |
| <u>Parameter 5</u> Changes in the femur head | Head round and neck clearly expressed. | Round head and neck cylindrical. | Head slightly flattening, neck with mild exostoses. | Head medium flattening, neck with mild exostoses. | Head medium flattening, neck with medium exostoses. | Head deformed, neck with massive exostoses. |
| <u>Parameter 6</u> Morgan lines | Not visible. | Small thin ridge, up to 1 mm. | Conspicuous ridge 1-2 mm. | Conspicuous ridge up to 3 mm. | Conspicuous ridge up to 4 mm. | Very expressed ridge, like exostosis. |

The estimate of dysplasia is formed separately for each hip joint, by the same score system, and the final grade is guided by that hip joint that has given a poorer score. Therefore, there are 5 categories A, B, C, D and E. Categories A and B represent a normal and approximately normal finding, and C, D and E state of dysplasia. The final score was based on Table 2.

Table 2.

Category of hip dysplasia

Tabela 2.

Kategorije displazije kukova

| Left hip/Right hip | | |
|--------------------|----------|------------------------|
| Sum of points | Category | Degree of dysplasia |
| 0-2 | A | Normal hip |
| 3-6 | B | Approximate normal hip |
| 7-12 | C | Mild dysplasia |
| 13-18 | D | Medium heavy dysplasia |
| >18 | E | Heavy dysplasia |

Result and discussion

In this study, the diagnosis of hip dysplasia in dogs and assessment of the degree of dysplasia according to the FCI system, was performed. By observing X-ray, correctly positioned patients, we used the guidelines from Table 1, to evaluate a degree of hip dysplasia. Each parameter received a score from 0 to 5, separately for the left and for the right hip. These numerical values were collected and then according to Table 2, we determined a presence and degree of hip dysplasia, based on the more deformed joint, as shown in Table 3.

Table 3.

Results by category (L- left hip, R- right hip)

Tabela 3.

Rezultati po kategorijama (L- levi kuk, R- desni kuk)

| Patient No | Sum | Category |
|------------|------------|----------|
| 1 | L 12, R 13 | D |
| 2 | L 2, R 1 | A |
| 3 | L 0, R 0 | A |
| 4 | L 2, R 0 | A |
| 5 | L 25, R 24 | E |
| 6 | L 6, R 10 | C |
| 7 | L 11, R 9 | C |
| 8 | L 4, R 4 | B |
| 9 | L 2, R 2 | A |
| 10 | L 3, R 1 | B |
| 11 | L 3, R 2 | B |
| 12 | L 19, R 16 | E |
| 13 | L 0, R 2 | A |
| 14 | L 4, R 5 | B |

The final results of this research, which refer to the number of patients who received grades A to E, while also pointing to the prevalence of hip dysplasia, are given in Figure 1. Of the total of 14 examined dogs, 5 dogs are dysplastic (36%), and these are patients with patient number 1, 5, 6, 7 and 12.

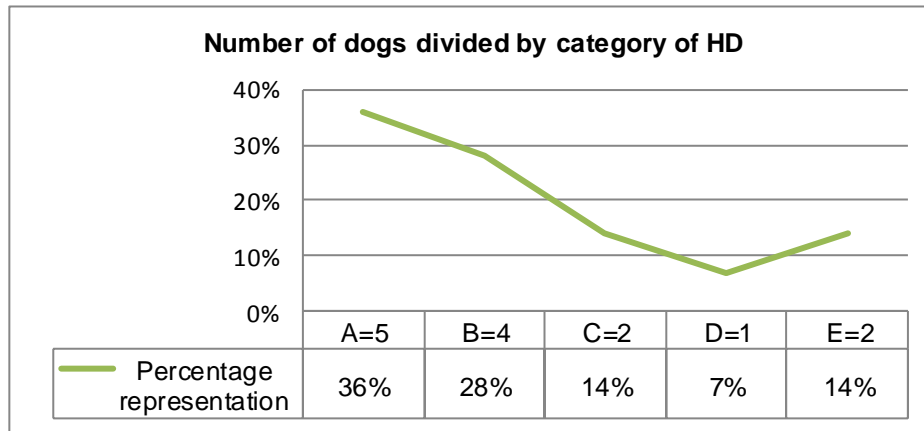


Figure 1. Number of dogs divided by category of hip dysplasia (category A=5 dogs, category B=4 dogs, category C=2 dogs, category D=1 dog and category E=2 dogs) and their percentage representation

Grafikon 1. Broj pasa podeljenih prema kategoriji displazije kukova (kategorija A=5 pasa, kategorija B= 4 psa, kategorija C=2 psa, kategorija D=1 pas i kategorija E=2 psa) i njihova procentualna zastupljenost

Similar results had Kronveit, 2010, who found incidence of HD of 24.6 %, and also Sarierler, 2017, who found incidence of 36,11%. Although their researchs are based on a significantly larger number of dogs, the final conclusion of this research does not deviate.

By analyzing the x-ray, we also determined the presence of changes caused by dysplasia. If we compare estimates in regard to the sum of the left and right hip estimates, which is graphically presetned in Figure 2, we can note that the changes, in the majority of cases, were present in proportion to both the left and right hip. So, there is no significant difference.

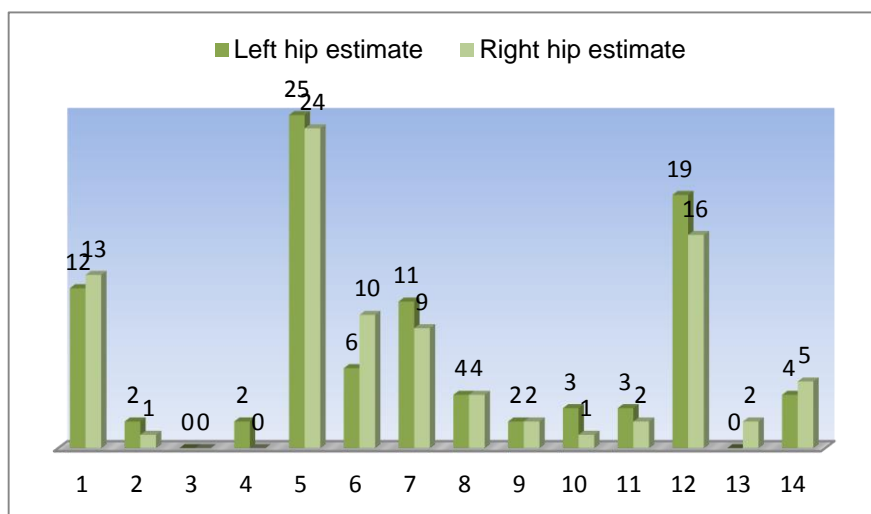


Figure 2. Comparison estimates of the left hip joint to the right hip joint, all 14 patients
Grafikon 2. Poređenje ocena levog u odnosu na desni zglob kuka, svih 14 pacijenta

Changes in the form of a reduction in Norberg's angle and the head of the femur bone were most common. Out of a total of 14 dogs, changes in Norberg's angle were present in 11 patients, and changes in the coverage of the femur head in 13 patients. There were some lower rated parameteres, even in dogs that were rated A, that is, Norberg's angle was slightly less than 105° , or the center of the femoral head was less than 2 mm in relation to the dorsal edge of the acetabulum. However, we also had a patient with normal hips, who did not have any changes to the parameter, and refers to a patient number 3 (Tab. 3) also shown in Figure 1.

On the other hand, the lowest Norberg angle below 80° had patients with patient number 5 and estimate E, a patient with a patient number 7 and estimate C and a patient with a patient number 12 and an estimate of E. As for changes in the coverage of the femur head the most expressed is in a patient with patient number 5, in which the joints were completely in the luxation, the center of the femur head compared to the dorsal edge of the acetabulum was over 10 mm. Changes in the femur bone are the next parameter to the frequency, which was present in nine dogs. Most often, this was the initial stage in which the head of the femur remained largely unchanged, but the changes involved the neck of the femur. The neck loses its shape, becomes cylindrical with a milder degree of exostoses, and in a patient with grade E, patient number 5, the head was completely deformed with massive exostoses. Due to the inadequate position between the head of the femur and the acetabulum, its easy to have deformation on the cranialateral edge of the acetabulum, covered with exostoses, also present in 9 dogs. The occurrence of the subchondral ossification of the cranial edge of the acetabulum was less commonly observed in 4 patients. Morgan's lines were the least represented, in only 2 cases, as changes that usually occur in the older age. Patient with patient number 5 had the worst finding of severe dysplasia, shown in Figure 2.

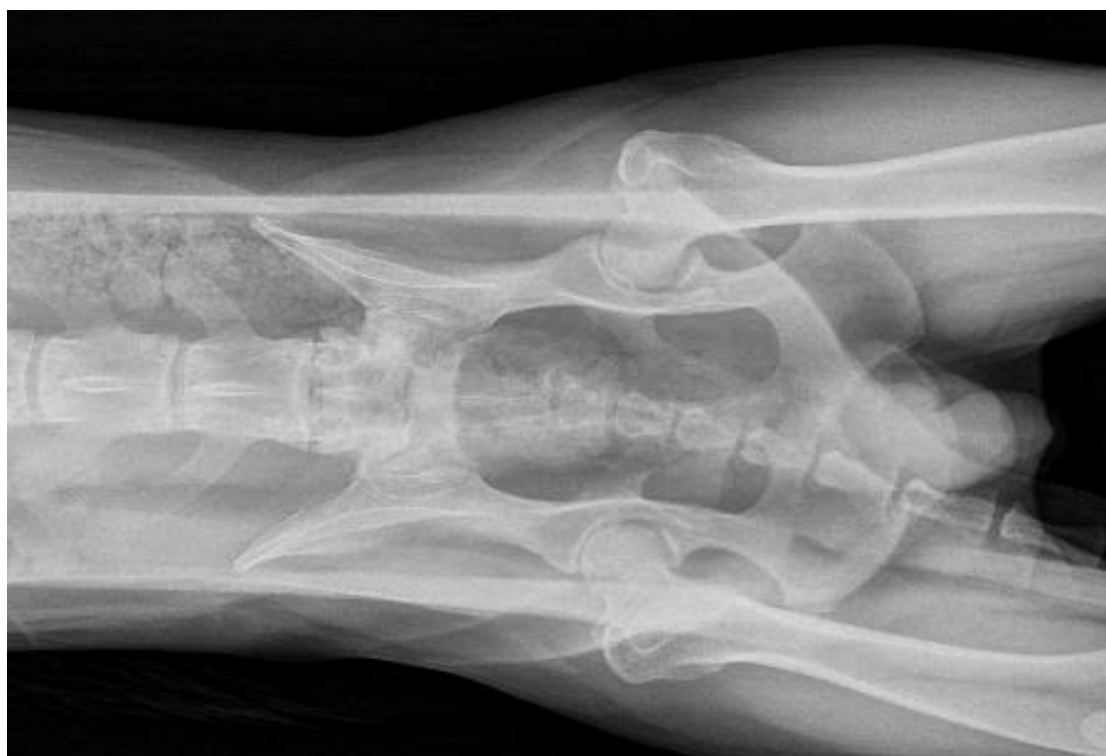

Figure 1. Ventrodorsal projection of dog hips, rated with grade A (original)
Slika 1. Ventrodorzalna projekcija kukova psa, ocenjenog sa ocenom A (original)

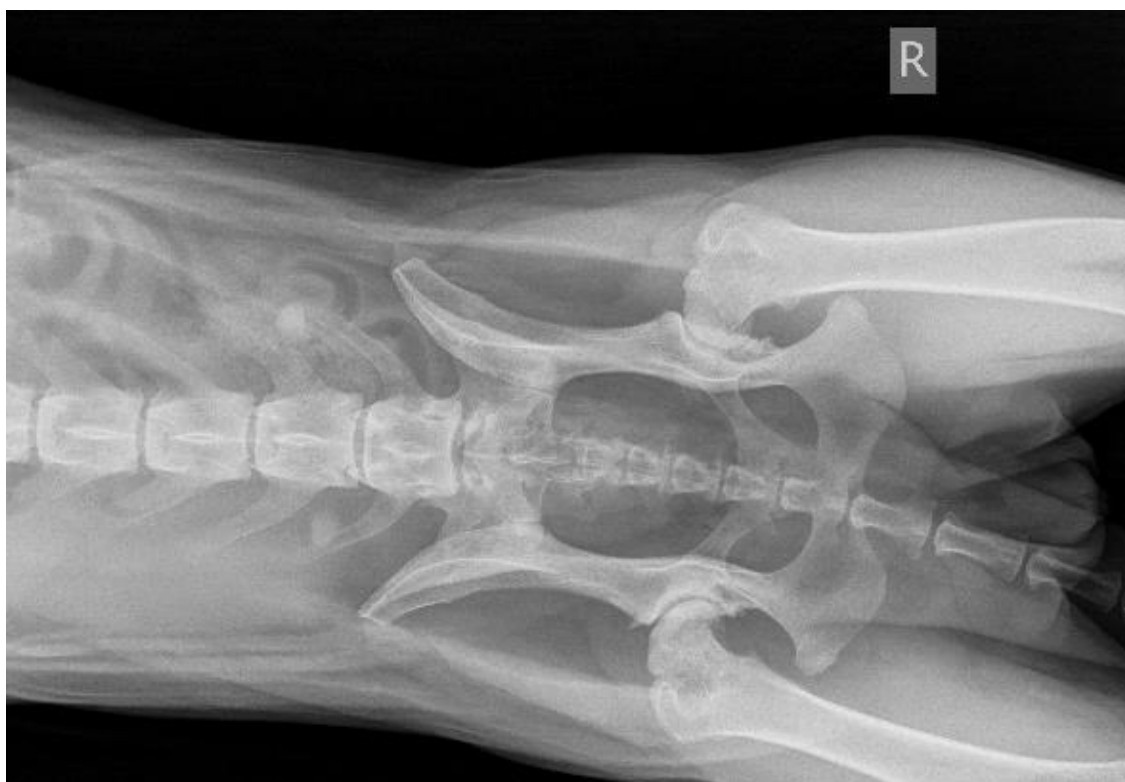

Figure 2. Ventrodorsal projection of dog hips, rated with grade E (original)
Slika 2. Ventrodorzalni projekcija kukova psa, ocenjenog na ocenom E (original)

Based on this study, hip dysplasia in dogs is frequent disease, even though it is not noticeable phenotypically and leaves significant repercussions on the health of dogs. The mandatory radiography of hips and a commitment to the programme of selection is very important for the reduction of incidence of HD and the improvement of the quality of purebred dogs. Dogs in which HD has been diagnosed have a high risk of dysplastic offspring and therefore such dogs should be excluded from breeding (Stanin, 2011). The influence of this data on the eradication of hip dysplasia in dogs lies mainly in the breeders hands and their ability to understand and accept the results, as well as to adhere to the veterinarian's recommendations.

Conclusion

In our investigation, hip dysplasia has a significant incidence, five (36%) of 14 examined dogs, were dysplastic. The most presented parameter (13 dogs) was an insufficient coverage of femur head with acetabulum edge, while the least-represented parameter (2 dogs) was the presence of Morgan lines.

Considering the existence of hip joint problems, a higher percentage of dogs should be covered by preventive examinations. Owners have a main role in the prevention of this disease, therefore proper education of the owners is a key in the elimination of the disease.

References

- Barr, A.R.S., Denny, H.R., Gibbs, C. (1987): Clinical hip dysplasia in growing dogs: the long-term results of conservative management. *Journal of Small Animal Practice* 28, 243–252.
- Fry, T.R., Clack, D.M., (1992): Canine hip dysplasia: clinical signs and physical diagnosis. *Veterinary Clinics of North America: Small Animal Practice* 22, 551–558.
- Grundström S. (2014): Influence of nutrition at young age on canine hip dysplasia in German Shepherd dogs. University of Helsinki, Small animal surgery, Licentiate of Veterinary Medicine Degree, p 2-11.
- Kealy JK, McAllister H. (2005): Bones and joints. In: Winkel AJ, editor. *Diagnostic Radiology Ultrasonography of the Dog and Cat*. fourth edition ed. Elsevier Saunders; p. 301-41.
- Mikkelsen J.M. (2007): Dynamic ultrasonography of the hip joint in early diagnosis of canine hip dysplasia. University of Copenhagen, Copenhagen, Denmark

- Richardson DC, Nap RC, Zentek J, Toll PW, Hayewinkel Haw, Zicker SC, Towell TL. (2010): Musculoskeletal disorders. In: Hand MS, Thatcher CD, Remillard RL, Roudebush P, Novotny BJ, eds. Small animal clinical nutrition. 5th ed. Topeka, Kan: Mark Morris Institute, 666-713.
- Riser WH. (1975): The dog as a model for the study of hip dysplasia. Growth, form, and development of the normal and dysplastic hip joint. *Vet Pathol*; 12(4):234-334.
- Sarıerler Murat, Cahit G. Bellek (2017): Radiological evaluation of the relationship between caudolateral curvilinear osteophyte and joint laxity and degenerative joint disease associated with Canine Hip Dysplasia. *Veterinarski arhiv* 87 (4), 501-509.
- Stanin D, Pavlak M, Vrbanac Z, Potocnjak D (2011): Prevalence of hip dysplasia in dogs according to official radiographic screening in Croatia. *Veterinarski arhiv* 81 (2), 235-248.
- Verhoeven G, Fortrie R, Van Ryssen B, Coopman F. (2012): Worldwide screening for canine hip dysplasia: Where are we now? *Vet Surg*, 41: 10-19.

Dijagnostika displazije kukova kod pasa prema smernicama Fédération Cynologique Internationale (FCI)

Tijana Kukurić^{a*}, Bojan Toholj^a, Ljubica Spasojević Kosić^a, Ivan Stančić^a

^aUniverzitet u Novom Sadu, Poljoprivredni fakultet, Departman za veterinarsku medicinu, Novi Sad, Srbija

*Autor za kontakt: tijana.kukuric@gmail.com

SAŽETAK

Dijagnostika displazije kukova kod pasa predstavlja značajan dijagnostički postupak, koji ima za cilj eliminaciju bolesti iz populacije. Cilj ovog rada je utvrđivanje zastupljenosti displazije kukova kod naših pacijenata i naglašavanje važnosti dijagnostike i prevencije oboljenja. Tokom istraživanja ispitano je ukupno 14 pasa. Korišćeni su standardi za ocenu displazije kukova u skladu sa FCI smernicama. Ocena se formira posebno za svaki zglob kuka, a konačna ocena vodi se na osnovu zgloba kuka koji da lošiji rezultat. Rezultati ispitivanja pokazuju da: pet (što je 36%) od 14 ispitanih pasa je bilo displastično. Najzastupljeniji parametar (13 pasa) bio je nedovoljna usađenost glave femura, dok je najmanje zastupljeni parametar (2 psa) bio prisustvo Morganovih linija. S obzirom na postojanje problema sa zglobovima kukova, potrebno je da što veći procenat pasa bude pokriven preventivnim pregledima. Vlasnici imaju glavnu ulogu u prevenciji ove bolesti, pa je pravilna edukacija vlasnika ključna za eliminaciju bolesti.

KLJUČNE REČI: Displazija kukova, ocena, FCI, parametri, psi, rendgenogrami

Primljen: 02.04.2019.

Prihvaćen: 11.07.2019.