

# Effect of repeated subcutaneous injections of carbon dioxide (CO<sub>2</sub>) on inflammation linked to hypoxia in adipose tissue graft

G. NISI, L. BARBERI, L. CECCACCIO, R. CUOMO, A. SISTI, A. CASTAGNA, I. ZERINI, C. BRANDI, L. GRIMALDI, C. D'ANIELLO

Department of General and Specialist Surgery, Plastic Surgery Division, Siena, Italy

**Abstract. – OBJECTIVE:** The purposes of this study was to assess the effect of repeated subcutaneous injections of CO<sub>2</sub> on adipose tissue graft survival in immunosuppressed female nude mice. The authors designed an experimental study using volume measures, histopathological analysis and nuclear magnetic resonance of fat graft. The effect of repeated subcutaneous injection of CO<sub>2</sub> is not yet investigated

**MATERIALS AND METHODS:** Approximately 0.5 ml of human fat were transplanted in a group of female nude mice. The mice were treated with 3 injections of 80 µl each carbon dioxide (total 240 µl) for 7 weeks. Initially, in vivo measurements were conducted and subsequently a comprehensive histopathological analysis was performed.

**RESULTS:** The presence of inflammation was graded absent to minimal in animals treated with CO<sub>2</sub> while a minimal to moderate grade was assigned to the control group.

**CONCLUSIONS:** CO<sub>2</sub> injection enhances the inflammatory response of the implanted tissue and reduces the reabsorption rate. The treatment may improve the graft survival in a more prolonged time-frame.

*Key Words:*

Carbon dioxide, Fat graft, Lipofilling, Carboxitherapy, Hypoxia, Inflammation.

## Introduction

The controlled injection of carbon dioxide (CO<sub>2</sub>) therapy has been used as a simple, safe, biocompatible, low-cost treatment option for wound management. CO<sub>2</sub> therapy requires a portable device that enables subcutaneous application of CO<sub>2</sub> for therapeutic purposes<sup>1</sup>. Carbon dioxide administered percutaneously promotes dilation of precapillary arterioles, reperfusion of occluded capillaries, reduction in blood viscosi-

ty, stimulation of skin heat receptors, and inhibition of cold receptors<sup>2</sup>.

The effect of such administration is effective not only in improving circulation and perfusion parameters of injection site but also inducing an increase in tissue oxygen partial pressure. This may be due to a hypercapnia-induced capillary blood flow and an increase in local oxygen (O<sub>2</sub>) availability caused by its release from hemoglobin related to reduction in pH (Bohr effect)<sup>3</sup>. Histological changes after the CO<sub>2</sub> therapy include: fracturing of the adipose tissue with release of triglycerides, thickening of the dermis, increase and realignment of the collagenous fibers, increase in the number and diameter of capillaries, increase of macrophages and fibroblasts<sup>4,5</sup>.

Adipose tissue is a dynamic and easily manipulated tissue which makes it practical for tissue augmentation or contour repair for soft tissue defects of any etiology<sup>6</sup>. The main issue related to this practice is the generation of a fat graft which establishes a long-term and stable interaction with the surrounding microenvironment, preventing the reabsorption at the recipient site<sup>7-9</sup>.

It is been proposed that, among the different cellular and molecular mechanism, the tissue inflammation due to hypoxia may enhance oxidative stress and compromise fat tissue graft taking<sup>10</sup>. The purpose of the present study<sup>11</sup> is to test the inflammation degree of fat graft after local injections of CO<sub>2</sub>.

We used the CO<sub>2</sub> to obtain the Bohr effect linked to the CO<sub>2</sub> to improve the oxygenation of the transplanted tissue in an attempt to reduce the inflammatory response linked to hypoxia.

The purpose of the present study is to test the inflammation degree of fat graft after local injections of CO<sub>2</sub>.

## Materials and Methods

This study comprised two phases, a preliminary trial (Phase I) followed by the Main experiment (Phase II). The aims of the preliminary trial (Phase I) were to develop the surgical procedure and MRI acquisition settings and to exclude that the surgical procedure did not caused any influence the implanted tissue. The purposes of the Main experiment (Phase II) was to assess the effect of repeated subcutaneous injections of CO<sub>2</sub> on the inflammation degree of human adipose tissue after fat graft in immunosuppressed CD-1 female nude mice. The effect of CO<sub>2</sub> was tested on a subcutaneous adipose tissue graft derived from transplantation of human adipose cell suspension vs sham operated animals. The graft was evaluated using magnetic resonance imaging (MRI) in anesthetized animals and histopathological examination was made after 7 week.

Procedures and facilities were in compliance with the requirements of Commission Directive 86/609/EEC concerning the protection of animals used for experimental and other scientific purposes. National legislation, harmonising with this Directive, is defined in D.L. no. 116 of 27 January 1992.

### Phase 1

The authors designed this phase to exclude that the sting of the site of infiltration of adipose tissue could cause alterations in local conditions that promote or disadvantage inflammation and/or the engraftment of the transplanted tissue .

Ten female nude mice were divided into two group: Group 1 and Group 2. Group 1 one was the control. The mice were in the same comfortable climatic conditions (temperature and humidity of the room), under sterile conditions. These mice were maintained over a period of acclimatization/quarantine for at least a week. At the end of this period they were checked by veterinarians. The environment was heated at 20-24 °C and the humidity was maintained in a range of 40-70%. The animals were subjected to a light-dark cycle of about 12 hours. Food and water were controlled by certified systems with equipment capable of assessing contaminants capable of interfering with the result of the experiment.

Anesthesia was performed by inhalation of isoflurane. Approximately 0.5 ml of human fat (taken from the abdomen) were injected into the subcutaneous plane on the right flank using a needle of 2.21 mm. The fat was taken with lipo-

suction and purified by centrifugation for 2 minutes at 3600 rotations per minute.

In the next four weeks, twice a week, the five mice of the Group 2 were stung in the area surrounding the graft with a 19G needle (total: 8 sting). After these two weeks, the mice of two groups were observed for more four weeks as follow:

- Survival and morbidity check: twice daily
- Once a week were recorded clinical signs and body weight.
- Once a day: measurement of transplant diameter

*In vivo* measurements were conducted using a 7T MRI (Bruker Pharmascan). During the procedure, the mice were anesthetized with isoflurane and monitored for temperature and respiratory rate. (matrix = 256x256, thickness = 2 mm slide, slide number = 18). The MRI study was conducted 1 day after implantation, after 8, 15, 43 and 48 days to evaluate the stability of the volume of the transplant.

After 6 weeks the fat graft reabsorption finished and the volume of graft was checked for another week. All fat grafts were stable after 7 weeks and the mice were sacrificed by exsanguination conducted in deep anesthesia after inhalation of isoflurane. The adipose tissue implanted was analyzed with light microscope.

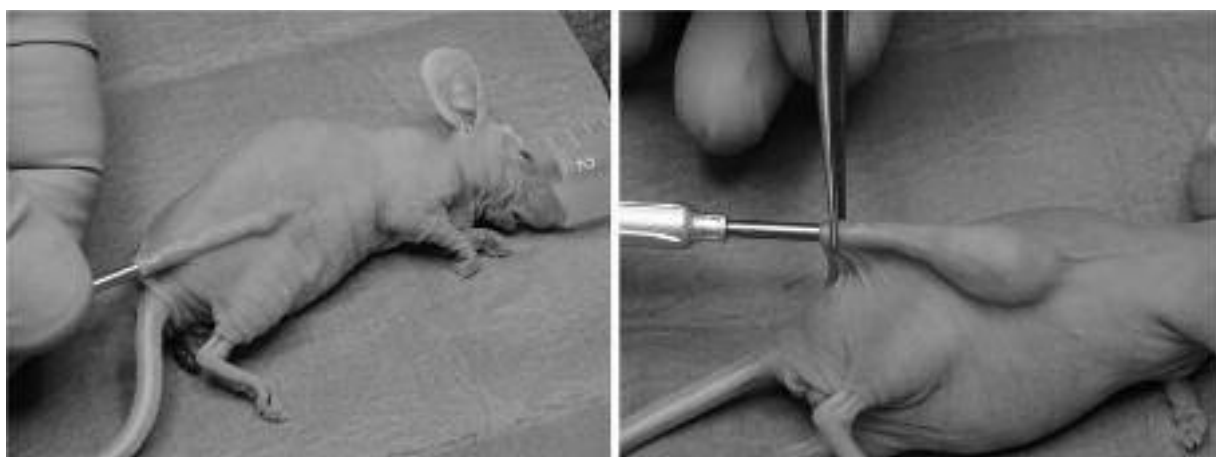### Phase two

Twenty female nude mice similar to the above were divided into two groups randomly assigned by a computerized procedure: Group 3 (control) and Group 4. They were acclimated with the same protocol of phase 1. No contamination was detected.

Each mouse was subjected at fat graft in right flank region. Approximately 0.5 ml of human fat (taken from abdomen) were transplanted after conducting deep general anesthesia with isoflurane inhalation (Figure 1). The fat was taken with liposuction and purified by centrifugation for 2 minutes at 3600 rotations per minute.

In the weeks following the 10 mice in Group 4 were treated with 8 injections of 80 µl each carbon dioxide (total 640 µl) with dedicated system and 19G needle for 4 weeks. The procedure was performed under general anesthesia for 13 times in 7 weeks and the injection was carried out at about 2 mm from the area of implantation of the fat. During this procedure, the mice were checked like phase 2.

*In vivo* measurements were conducted using a 7-tesla MRI. The acquisitions were performed with Rapid Acquisition with Refocused Echoes



**Figure 1.** Fat injection.

(TR = 842 ms, TE = 8.64 ms, matrix = 256x256, thickness = 2 mm slice, slide number = 18). The MRI study was conducted 1 day after implantation, after 22 and 43 days.

After 7 weeks the fat graft volume was stable and the mice were sacrificed by exsanguination conducted under anesthesia with isoflurane. Visual observation was conducted on the implant site. The fat was removed and divided into two parts: A and B and histological examinations were made. The surrounding skin transplantation was studied to evaluate possible abnormalities.

Tissue collection was made as follow:

- Group A: 10% formalin and paraffin embedding
- Group B: snap frozen in liquid nitrogen and stored -80 °C up to sectioning

Tissue staining was made as follow:

- Group A: Haematoxylin and Eosin
- Group B: Oil-Red-O staining five randomly selected animals per-group

Presence of intact nucleated fat cells, of vacuoles or cysts, inflammation, cellular infiltration, vascularization, fibrosis were examined microscopically.

## Results

### *Preliminary trial (Phase I)*

#### *In-Vivo Examinations*

Overall, no differences were observed between untreated and sham operated animals. The repeated anesthesia and sham procedures had no effects on the general and local condition. No effects on body weight gain and no adverse general

clinical signs or site reactions were observed in the untreated and sham surgery animals.

#### *Pathology Report*

Adipose tissue implanted showed no differences between the group A and group B. Inflammation was neutrophilic and generally concomitant with coagulative necrosis when present.

#### *Adipose Tissue Graft Measurement*

*In vivo* measurement and MRI acquisition showed a complete stability of reabsorption rate after 7 weeks in both groups. Histological examination was performed after this period. Also the reabsorption rate of adipose tissue graft was similar (approximately -18% and -29%, sham surgery and untreated animals, respectively).

Overall, no differences were observed on adipose tissue graft reabsorption during the 6 weeks of the study between untreated and sham surgery animals (Figure 2)

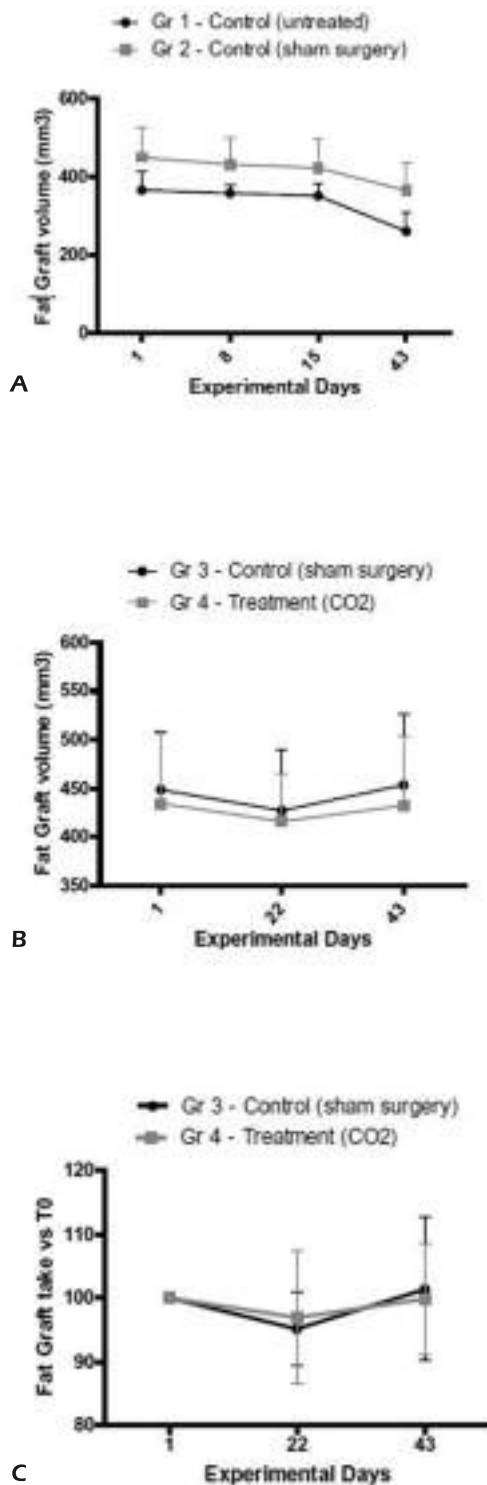
### *Main Experiment (Phase II)*

#### *In-Vivo Examinations*

All the mice had survived after 6 weeks of repeated subcutaneous injections of CO<sub>2</sub>. In general, no effects on body weight gain and no adverse general clinical signs or site reactions were observed.

#### *Adipose Tissue Graft Microscopic Observations*

The skin surrounding the implant site of control and treated animals did not show any abnormalities in both groups. Oil red O staining confirmed the lipidic nature of cell vacuoles. Inflammation



**Figure 2.** Volume misurations. **A**, Adipose tissue graft volumes (mm<sup>3</sup>) vs. time during Phase I in female CD-1 Nude Mice (mean values  $\pm$  SD, n=4-5). **B**, Adipose tissue graft volumes (mm<sup>3</sup>) vs. time during Phase II in female CD-1 Nude Mice (mean values  $\pm$  SD, n=8-9). **C**, adipose tissue graft volumes (% changes) vs. initial volume during Phase II in female CD-1 Nude Mice (mean values  $\pm$ SD, n=8-9).

mation was neutrophilic and generally concomitant with coagulative necrosis when present. The presence of inflammation was absent or minimal in animals treated with CO<sub>2</sub> and moderate in the control group. No necrosis was observed in animals treated with CO<sub>2</sub> while was minimally/moderately present in control group. Cysts/vacuoles were located in the peripheral area of the graft with a minimal presence in treated animals and moderately to extensively presence in control animals. Neovascularization was differentiated as peripheral (of the neoformed capsule effacing the skin) and internal (blood vessels seen among adipocytes). The treated group showed an overall better vascularity than the controls. A higher degree of fibrosis was seen in control animals, mainly due to the thickness of the neoformed peripheral capsule effacing the skin. Histological sections also showed a greater number of blood vessels in the group treated with CO<sub>2</sub>.

#### Adipose Tissue Graft Measurement

*In vivo* measurements and MNR acquisitions showed that the adipose tissue became stable in 7 weeks in both groups and that the carbon dioxide did not interfere on the stabilization time of the transplant. The collection of the measurements showed a different rate of resorption of the adipose tissue between the two groups: mean reabsorption percentages for the adipose tissue graft were 13.5% for the control and 1,7% for treatment group (CO<sub>2</sub>) at the final time point (Day 43) if compared to Day 1 (T<sub>0</sub>) (Figure 2). Fat graft was obtained from all animals of Phase I and II of the study as required from the study protocol. No statistical significant difference was reported due to both sham procedure showing that re-absorption rate did not change over time due to sham procedures. Mean re-absorption percentage of 18.79% for the control (untreated) group animal and 18.98% for the control (sham surgery) group animal were observed at Day 43 in respect to Day 1 (T<sub>0</sub>). Phase II- Effect of repeated subcutaneous injections of CO<sub>2</sub> on adipose tissue graft (Main Experiment). The collection of the measurements showed a different rate of reabsorption of the adipose tissue between the two groups: mean reabsorption percentages for the adipose tissue graft were 13.5% for the control and 1.7% for treatment group (CO<sub>2</sub>) at the final time point (Day 43) if compared to Day 1 (T<sub>0</sub>), however, this difference was not considered statistically significant.

## Discussion

Differences were observed between the Preliminary Trial (Phase I) and Main Experiment (Phase II) in terms of inflammation of fat graft. MRI acquisitions, whose purpose was to evaluate the stability of the graft, showed a different rate of reabsorption between the group treated with CO<sub>2</sub> than controls.

The mechanisms responsible are not completely clear and should be investigated further. A possible explanation can be linked to the fact that animals in the Phase II received CO<sub>2</sub> injection with an increasing of Bohr's effect. This probably resulted in an improved oxygenation with a reduction of inflammation linked to hypoxia, as demonstrated by the increased number of blood vessels. Probably oxidative stress determined by hypoxia was smaller and this resulted in a histological pattern with less fibrosis, cysts and vacuoles<sup>12</sup>.

MRI acquisition that was meant to indicate the end of the process of reabsorption, also showed a lower absorption of fat in the group treated with the CO<sub>2</sub>. Probably the better oxygenation and lower rate of inflammation have played an important role in the creation of vascular connections.

Independently from the observed differences in the sham operated animals, the histological results of this study suggests that repeated subcutaneous injections of CO<sub>2</sub> in the surrounding tissue of the adipose graft improve the quality of fat graft, if compared to controls. The higher degree of vascularity recorded in treated animals might represent the direct effect of CO<sub>2</sub> administration in the hypoxic environment of the graft. The induction of angiogenesis causes an adequate blood supply to the tissue thus preventing adipocytes necrosis<sup>13</sup>. In fact, ischemia causes degenerative changes in adipocytes, including detachment of the cell membrane with fatty cysts and vacuoles developing in the regions that have not been revascularized<sup>14,15</sup>. Neovascularization might thus be able to avoid necrosis and subsequent inflammatory reaction. The formation of cysts and vacuoles in the fat grafts may be attributed to inadequate vascularization as well.

As reported in a 10 weeks study by Oh<sup>16</sup> the higher degree of neovascularization is positively correlated with the long term survival of fat graft tissues, hence it is likely that in a more prolonged time frame, the effect of CO<sub>2</sub> injections would become evident. Balik et al<sup>4</sup> observed that CO<sub>2</sub> therapy could improve composite graft survival; in his experiment on rabbits, CO<sub>2</sub> therapy in-

creased the amount of collagen in grafts. CO<sub>2</sub> was not significantly different from saline infusion on composite grafts survival, but this study suggested that there is a mechanical effect caused by distension, which favored graft survival.

## Conclusions

The effects of carbon dioxide injections were evaluated in fat graft conducted in CD-1 female nude mice. Inflammation linked to hypoxia was investigated.

The results of this study suggest that repeated subcutaneous injections of CO<sub>2</sub> in the surrounding adipose tissue graft improve the histological pattern of fat graft with lower presence of necrosis, cysts and vacuoles. The fat is more vascularized in the treated group compared to the control. Furthermore the imaging analysis have demonstrated a lower reabsorption rate in the treated group, but this wasn't statistical significant. Probably subcutaneous CO<sub>2</sub> may improve the graft survival in a more prolonged time-frame.

## Conflict of Interest

The Authors declare that they have no conflict of interests.

## References

- 1) PENHAVEL MV, NASCIMENTO VH, DURAES EF, CARNEIRO FP, SOUSA JB. Effects of carbon dioxide therapy on the healing of acute skin wounds induced on the back of rats. *Acta Chir Bras* 2013; 28: 334-339.
- 2) PIAZZOLLA LP, LOUZADA LL, SCORALICK FM, MARTINS ME, DE SOUSA JB. Preliminary experience with carbon dioxide therapy in the treatment of pressure ulcers in a bedridden elderly patient. *J Am Geriatr Soc* 2012; 60: 378-379.
- 3) DURAES EF, DURAES LDE C, CARNEIRO FP, LINO RDE S JR., SOUSA JB. The effect of carbon dioxide therapy on composite graft survival. *Acta Chir Bras* 2013; 28: 589-593.
- 4) BALIK O, YILMAZ M, BAGRIYANIK A. Does carbon dioxide therapy really diminish localized adiposities? Experimental study with rats. *Aesthetic Plast Surg* 2011; 35: 470-474.
- 5) BRANDI C, D'ANIELLO C, GRIMALDI L, CAIAZZO E, STANGHELLINI E. Carbon dioxide therapy: effects on skin irregularity and its use as a complement to liposuction. *Aesthetic Plast Surg* 2004; 28: 222-225.
- 6) TRAN TT, KAHN CR. Transplantation of adipose tissue and stem cells: role in metabolism and disease. *Nat Rev Endocrinol* 2010; 6: 195-213.

- 7) RAMON Y, SHOSHANI O, PELED IJ, GILHAR A, CARMI N, FODOR L, RISIN Y, ULLMANN Y. Enhancing the take of injected adipose tissue by a simple method for concentrating fat cells. *Plast Reconstr Surg* 2005; 115: 197-201; discussion 202-193.
- 8) RIECK B, SCHLAAK S. Measurement in vivo of the survival rate in autologous adipocyte transplantation. *Plast Reconstr Surg* 2003; 111: 2315-2323.
- 9) ULLMANN Y, HYAMS M, RAMON Y, BEACH D, PELED IJ, LINDENBAUM ES. Enhancing the survival of aspirated human fat injected into nude mice. *Plast Reconstr Surg* 1998; 101: 1940-1944.
- 10) TRAYHURN P, WANG B, WOOD IS. Hypoxia in adipose tissue: a basis for the dysregulation of tissue function in obesity? *Br J Nutr* 2008; 100: 227-235.
- 11) BRANDI C, GRIMALDI L, NISI G, BRAFA A, CAMPA A, CALABRÒ M, CAMPANA M, D'ANIELLO C. The role of carbon dioxide therapy in the treatment of chronic wounds. *In Vivo* 2010; 24: 223-226.
- 12) PEER LA. Cell survival theory versus replacement theory. *Plast Reconstr Surg* (1946) 1955; 16: 161-168.
- 13) SOMMER B, SATTLER G. Current concepts of fat graft survival: histology of aspirated adipose tissue and review of the literature. *Dermatol Surg* 2000; 26: 1159-1166.
- 14) SHOSHANI O, LIVNE E, ARMONI M, SHUPAK A, BERGER J, RAMON Y, FODOR L, GILHAR A, PELED IJ, ULLMANN Y. The effect of interleukin-8 on the viability of injected adipose tissue in nude mice. *Plast Reconstr Surg* 2005; 115: 853-859.
- 15) CUOMO R, ZERINI I, BOTTERI G, BARBERI L, NISI G, D'ANIELLO C. Postsurgical pain related to breast implant: reduction with lipofilling procedure. *In Vivo* 2014;28:993-996.
- 16) OH DS, CHEON YW, JEON YR, LEW DH. Activated platelet-rich plasma improves fat graft survival in nude mice: a pilot study. *Dermatol Surg* 2011; 37: 619-625.