

Paradoxical air embolism during hepatic resection

S. Y. Lee^{1*}, B. I. W. Choi², J. S. Kim¹ and K. S. Park¹

¹Department of Anesthesiology and ²Department of Cardiology, Ajou University, School of Medicine, 5 Wonchon-Dong, Paldal-Gu, Suwon 441-749, Korea

* Corresponding author

Systemic venous air embolism is a serious complication in patients with chronic liver disease having liver surgery. Intrapulmonary arteriovenous shunting can permit air emboli to pass into the systemic circulation. We describe a case of paradoxical air embolism detected by transoesophageal echocardiography in a patient with cirrhosis who was having a hepatic resection.

Br J Anaesth 2002; **88**: 136–8

Keywords: liver, resection; embolism, air

Accepted for publication: September 5, 2001

Although the incidence of venous air embolism (VAE) and paradoxical air embolism (PAE) during hepatic resection is unknown, VAE is a potentially hazardous complication during hepatectomy.¹ Many patients who undergo hepatectomy have liver cirrhosis, and VAE is particularly dangerous in such patients because 15–45% have pulmonary abnormalities including intrapulmonary shunting caused by pulmonary vascular dilatation and arteriovenous communication.^{2–4} In these patients, paradoxical emboli can occur during air embolism even if intracardiac abnormalities are not present. Transoesophageal echocardiography (TOE) is a most sensitive method to detect VAE⁵ and can discriminate intracardiac from transpulmonary passage.^{6–8} We report a case of paradoxical embolism after transpulmonary passage of gas detected by TOE in a cirrhotic patient during hepatic resection.

Case report

A male patient (47 yr, 63 kg, ASA II) underwent resection of the right lobe of the liver for hepatoma. He had a 5-yr history of cirrhosis caused by hepatitis B. He had no clinical cardiopulmonary disease and chest x-ray and ECG were normal. The patient was premedicated with midazolam (3 mg i.v.) and glycopyrrolate (0.2 mg i.v.). Anaesthesia was induced with thiopentone and maintained with 1.0–2.0% (inspired concentration) isoflurane and nitrous oxide 50% in oxygen. Muscle relaxation was with vecuronium. Ventilation was mechanically controlled and adjusted to maintain an end-tidal concentration of carbon dioxide (FE'_{CO_2}) between 3.5 kPa and 4.5 kPa throughout surgery with PEEP of 3 cm H₂O. Arterial blood pressure was monitored invasively from the left radial artery, and oxygen

saturation with a pulse oximeter (SpO_2). Central venous pressure (CVP) was measured intermittently by transducer. After induction of anaesthesia Pa_{O_2} was 277 mm Hg and Pa_{CO_2} 35 mm Hg with FI_{O_2} of 0.5. The patient was in the supine position.

Hepatic resection using electrocautery and ultrasonic dissector was started after clamping the branches of the portal vein and the right hepatic artery supplying the right lobe of the liver.

Two hours and 20 min after the start of operation, an abrupt decrease in FE'_{CO_2} (from 32 to 15 mm Hg) and SpO_2 (from 100% to below 60%) were noted. The administration of N₂O was immediately discontinued and the patient's lungs were hyperventilated with 100% oxygen. After a few seconds, systolic arterial pressure decreased from 120 mm Hg to under 20 mm Hg and heart rate fell from 65 beats min⁻¹ to less than 20 beats min⁻¹ with severe ST depression on ECG monitoring. Embolism was suspected. The infusion tubing was checked, and was found to be satisfactory. The surgeons acknowledged that a large number of small hepatic veins were cut and open to the atmosphere. The patient's position was changed from supine to left lateral decubitus, and ephedrine 12 mg, atropine 0.4 mg and epinephrine 100 µg given through the central venous catheter. When cardiovascular measurements improved, arterial blood gas analysis showed Pa_{O_2} 161 mm Hg and Pa_{CO_2} 34 mm Hg with FI_{O_2} of 1.0. About 5–10 min after the onset of clinical signs, a TOE probe was placed. Air bubbles were seen coming from the right pulmonary vein into the left atrium (Fig. 1). No right-to-left intracardiac shunt was found by colour flow echocardiography. Although the number of air bubbles decreased progressively, they continued to appear in the left heart from the right pulmonary vein for 20 min.

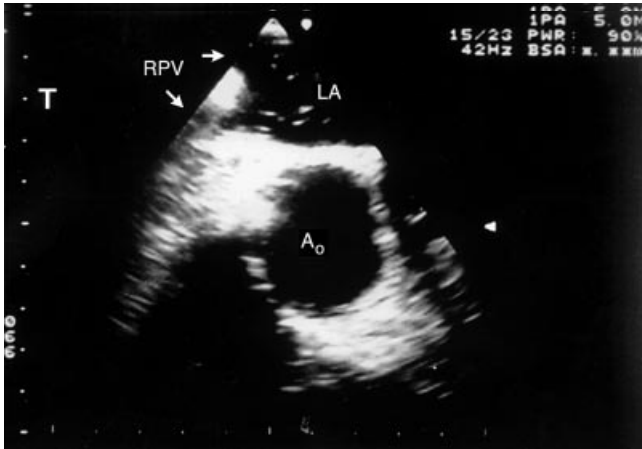

Fig 1 Short-axis view at the level of mid-oesophagus transoesophageal echocardiogram showing the right pulmonary vein (RPV), left atrium (LA), and aorta (AO). About 5 min after the reduction of end-tidal CO_2 , air bubbles were seen within the RPV as they entered the LA, indicating a right-to-left pulmonary shunt.

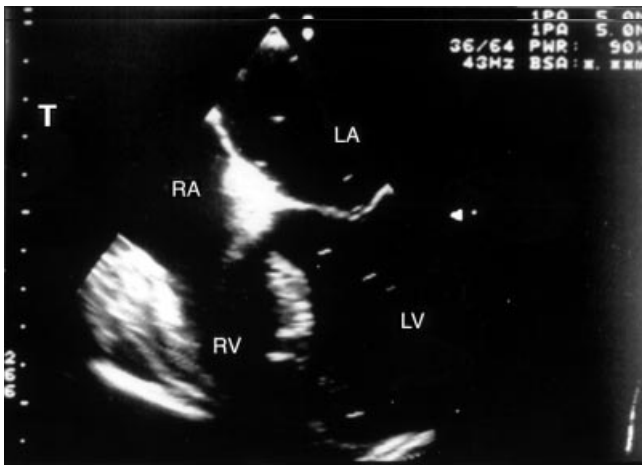


Fig 2 Four-chamber view transoesophageal echocardiogram showing the right atrium (RA), left atrium (LA), right ventricle (RV) and left ventricle (LV). About 15 min after the reduction of end-tidal CO_2 , air bubbles were seen continuously only in the LA and LV. There were no air bubbles within the right heart.

During this time no air bubbles were seen in the right heart (Fig. 2). These findings suggest that embolism had occurred from cut small hepatic veins being exposed to the air, and passed through dilated pulmonary vessels and appeared in the left heart.

After induction of anaesthesia, CVP was 7 mm Hg. It was not possible to measure CVP continuously during resuscitation period. After return of cardiovascular stability, a pulmonary arterial catheter was inserted, and pulmonary arterial pressure was 21/8 mm Hg and CVP of 6 mm Hg.

Hyperventilation was continued with 100% oxygen. An infusion of low dose dobutamine was given until the air bubbles had disappeared. At the end of surgery (1 h after the reduction of FE'_{CO_2}), PaO_2 was 395 mm Hg and PaCO_2 was 43 mm Hg with FI_{O_2} of 1.0. The patient was extubated 3 h later in the intensive care unit, and the early postoperative

course in intensive care unit was satisfactory. There was no clinical evidence of pulmonary oedema or neurological sequelae.

Discussion

Previous studies have highlighted the potential dangers of VAE during hepatic resection.¹ VAE is particularly worrisome in patients with chronic liver disease who may have intrapulmonary arteriovenous shunting,² for air can pass into the systemic circulation (i.e. paradoxical air embolization) without any intracardiac abnormalities. The incidence of VAE and PAE during hepatic resection is unknown.

VAE is unlikely to occur in patients undergoing abdominal procedures while in the supine position, unless the inferior vena cava or pelvic veins are exposed to the air.^{9,10} However, during hepatic resection, vena cava manipulation or compression may narrow its diameter at the junction with the hepatic veins. In such a situation, the venous distending pressure of the constricted portion of the inferior vena cava may be less than in the nonconstricted part, and becomes even subatmospheric when blood passes through the narrowed portion with a high flow rate. Air could be sucked into the inferior vena cava *via* the large number of small hepatic veins exposed to the atmosphere.¹ In our case, the inferior vena cava was being compressed while a large number of small hepatic veins were open to the air.

The effects of air embolism depend on the volume as well as the rate of air entry. Adornato *et al.*¹¹ reported that slow infusion of air (0.01 to $2.00 \text{ ml kg}^{-1} \text{ min}^{-1}$) passes through the right side of the heart, occludes the pulmonary circulation and causes a progressive increase in CVP, an abrupt increase in pulmonary arterial pressure (PAP) to a plateau and a progressive decrease in peripheral resistance. The reduced resistance may be compensated for by an increase in cardiac output but hypotension can follow when compensation fails. In contrast, injection of a bolus air (25 – 200 ml ; 1 – 13 ml kg^{-1}) occludes the right side of the heart, increases CVP, decreases PAP, and causes hypotension. Many clinical episodes of VAE result from combinations of slow infusion and also introduction of larger amounts. In our case, CVP and PAP were not measured during resuscitation but we noted S–T depression, shock and bradycardia. This suggests that a large volume was introduced.

Various methods can be used to prevent embolism. An increase in venous pressure by using PEEP might reduce entrainment of air into the circulation or stop air entrainment after air embolism has been detected.¹² This is controversial because an increase in venous pressure might cause paradoxical embolism if the patient had a right-to-left shunt.¹³ We used 3 cm H_2O of PEEP and, this was reduced during resuscitation. Another method to prevent VAE is changing position during operation. During the parenchymal phase of the operation, some suggest that the

patients should be in a Trendelenburg position of about 15°. ¹⁴ In our case, the patient was supine, since we have done about 200 cases of major hepatic resection with this position without previous incident.

When VAE has developed, a position of head-down and left lateral decubitus can protect from embolism effects. ¹¹ In our case, after the reduction of FE'_{CO_2} , the lateral decubitus position was used because we suspected slow entry of the air.

PAE occurs when the air in the venous system or in the right heart passes through an intracardiac channel and reaches the systemic circulation. A persistent patent foramen ovale exists in 10–35% of the population and is the most common route for PAE. ¹⁵ However, air may also reach the systemic circulation through pathological dilatation of intrapulmonary vessels normally present in some people (but more frequent in end-stage liver disease). ¹⁶ In the normal individual, pulmonary parenchymal precapillary and capillary blood vessels have a diameter of 8–15 µm. ¹⁷ However, in patients with chronic liver diseases, intrapulmonary shunting can occur by intrapulmonary vascular dilatation (up to 160 µm) at the precapillary level, or by direct arteriovenous communications. ^{17,18} Hopkins *et al.* ³ reported that 47% of cirrhotic patients had right-to-left intrapulmonary shunting, shown by contrast echocardiography. In this case, TOE demonstrated air bubbles passing from the right pulmonary vein into the left atrium. No right-to-left intracardiac shunt could be detected by colour flow echocardiography. These findings suggest that the source of PAE was from dilated pulmonary vasculature and not from an undignosed intracardiac shunt.

TOE and precordial Doppler ultrasound are the most sensitive modality in detecting VAE ⁵ and can discriminate intracardiac from transpulmonary passage. ^{6–8} In patients with intracardiac communications, immediate opacification of the left heart chambers occurs after arrival of air into the right heart chambers. However, in patients with transpulmonary passage, air passes into the pulmonary circulation where it is trapped in capillaries with diameter of 8–15 µm. It is either absorbed into alveolar space or dissolved during pulmonary transit, if the size of bubbles are less than 8 µm in diameter. ¹⁹ When pulmonary vessels are dilated at the pre-capillary level (>15 µm), delayed opacification in the left atrium occurs approximately three to six ventricular contractions after leaving the right ventricle. ⁶ In this case, we placed a transoesophageal probe about 5–10 min after the onset of signs and air bubbles were still seen arriving in the left atrium *via* the right pulmonary vein. An intracardiac shunt was not seen. These findings suggest pulmonary vasodilatation.

Intrapulmonary shunting is implicated in the pathophysiology of the hypoxaemia observed in patients with chronic liver disorders. ²⁰ However, three out of five patients with vascular dilatation had Pa_{O_2} values of 82 mm Hg or more while breathing room air. ⁴ In our case, the patient was not hypoxic before the operation.

References

- 1 Hatano Y, Murakawa M, Segawa H, Nishida Y, Mori K. Venous air embolism during hepatic resection. *Anesthesiology* 1990; **73**: 1282–5
- 2 Krowka MJ, Cortese DA. Pulmonary aspects of chronic liver disease and liver transplantation. *Mayo Clin Proc* 1985; **60**: 407–18
- 3 Hopkins WE, Waggoner AD, Barzilai B. Frequency and significance of intrapulmonary right-to-left shunting in end-stage hepatic disease. *Am J Cardiol* 1992; **70**: 516–19
- 4 Krowka MJ, Tajik AJ, Dickson ER, Wiesner RH, Cortese DA. Intrapulmonary vascular dilatations (IPVD) in liver transplant candidates. Screening by two-dimensional contrast-enhanced echocardiography. *Chest* 1990; **97**: 1165–70
- 5 Glenski JA, Cucchiara RF, Michenfelder JD. Transesophageal echocardiography and transcutaneous O_2 and CO_2 monitoring for detection of venous air embolism. *Anesthesiology* 1986; **64**: 541–5
- 6 Hind CR, Wong CM. Detection of pulmonary arteriovenous fistulae in patients with cirrhosis by contrast 2D echocardiography. *Gut* 1981; **22**: 1042–5
- 7 Krowka MJ, Cortese DA. Hepatopulmonary syndrome: an evolving perspective in the era of liver transplantation. *Hepatology* 1990; **11**: 138–42
- 8 Suriani RJ. Echocardiographic identification of paradoxical air embolism. *Anesthesiology* 1994; **81**: 1548–50
- 9 Strunin L, Davies JM. The liver and anaesthesia. *Can Anaesth Soc J* 1983; **30**: 208–17
- 10 Naulty JS, Meisel LB, Datta S, Ostheimer GW. Air embolism during radical hysterectomy. *Anesthesiology* 1982; **57**: 420–2
- 11 Adornato DC, Gildenberg PL, Ferrario CM, Smart J, Frost EAM. Pathophysiology of intravenous air embolism in dogs. *Anesthesiology* 1978; **49**: 120–7
- 12 Lee DS, Lichtmann MW, Weintraub HD. Effect of PEEP on air embolism during sitting neurosurgical procedures. *Anesth Analg* 1981; **60**: 262
- 13 Perkins NAK, Bedford RF. Hemodynamic consequences of PEEP in seated neurosurgical patients—implications for paradoxical air embolism. *Anesth Analg* 1984; **63**: 429–32
- 14 Baer HU, Blumgart LH. Venous air embolism with a water jet dissector. *Br J Anaesth* 1993; **71**: 921
- 15 Schwartz G, Fuchs G, Weihs W, Tritthart H, Schalk HV, Kaltenbock F. Sitting position for neurosurgery: experience with preoperative contrast echocardiography in 301 patients. *J Neurosurg Anesth* 1994; **6**: 83–8
- 16 Krowka MJ, Cortese DA. Hepatopulmonary syndrome. Current concepts in diagnostic and therapeutic considerations. *Chest* 1994; **105**: 1528–37
- 17 Berthelot P, Walker JG, Sherlock S, Reid L. Arterial changes in the lungs in cirrhosis of the liver. Lung spider nevi. *N Engl J Med* 1966; **274**: 291–8
- 18 Williams A, Trewby P, Williams R, Reid L. Structural alterations to the pulmonary circulation in fulminant hepatic failure. *Thorax* 1979; **34**: 447–53
- 19 Shub C, Tajik AJ, Seward JB, Dines DE. Detecting intrapulmonary right-to-left shunt with contrast echocardiography. Observations in a patient with diffuse pulmonary arteriovenous fistulas. *Mayo Clin Proc* 1976; **51**: 81–4
- 20 Edell E, Cortese DA, Krowka MJ, Rehder K. Severe hypoxemia and liver disease. *Am Rev Respir Dis* 1989; **140**: 1631–5