

PennHIP Report

Referring Veterinarian: Dr Matthew Tedstone	Clinic Name: Centre Hospitalier Universitaire Veterinaire - Faculte de medecine veterinaire
Email: matthew.tedstone@umontreal.ca	Clinic Address: Clinique des animaux de compagnie 3200 Sicotte Street. Saint Hyacinthe Quebec, QC J2S 2M2
	Phone: (450) 778-8111
	Fax:

Patient Information

Client: Vaillancourt, Nathalie	Tattoo Num:
Patient Name: Onyx	Patient ID: 101048
Reg. Name: Onyx the Sweetest Coton	Registration Num: FCC-CDN-9130
PennHIP Num: 135378	Microchip Num: 616093900610790
Species: Canine	Breed: COTON DE TULEAR
Date of Birth: 30 Mar 2018	Age: 19 months
Sex: Female	Weight: 13.2 lbs/6 kgs
Date of Study: 04 Oct 2019	Date Submitted: 04 Oct 2019
Date of Report: 07 Oct 2019	

Findings

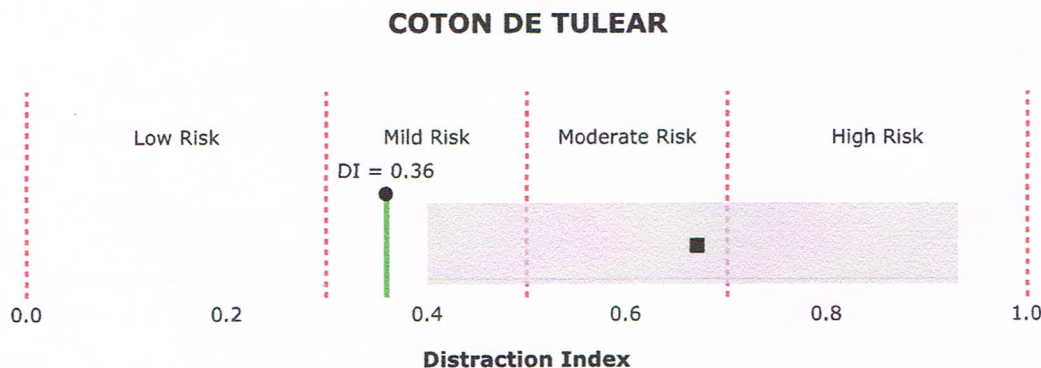
Distraction Index (DI): Right DI = 0.36, Left DI = 0.35.
 Osteoarthritis (OA): No radiographic evidence of OA for either hip.
 Cavitation/Other Findings: No cavitation present.

Interpretation

Distraction Index (DI): The laxity ranking is based on the hip with the greater laxity (larger DI). In this case the DI used is 0.36.

OA Risk Category: The DI is between 0.31 and 0.49. This patient is at mild risk for hip OA.

Distraction Index Chart:



BREED STATISTICS: This interpretation is based on a cross-section of 86 canine patients of the COTON DE TULEAR breed in the AIS PennHIP database. The gray strip represents the central 90% range of DIs (0.40 - 0.93) for the breed. The breed average DI is 0.67 (solid square). The patient DI is the solid circle (0.36).