

TECHNICAL NOTE

Percutaneous bedside femorofemoral bypass grafting for acute limb ischemia caused by intra-aortic balloon pump

Peter H. Lin, MD,^a Ruth L. Bush, MD,^b Brian S. Conklin, MS,^b Elliot L. Chaikof, MD, PhD,^b and Alan B. Lumsden, MD,^a *Houston, Tex; and Atlanta, Ga*

Acute limb ischemia is a common, recognized complication of intra-aortic balloon pump (IABP) placement in patients with failing myocardium, and an operative femorofemoral bypass graft is often necessary in IABP-dependent patients as a means of maintaining the lower-limb perfusion. In this report, we present a minimally invasive endovascular technique for creating a percutaneous temporary femorofemoral bypass graft at bedside in patients with IABP-induced limb ischemia. This temporary bypass grafting technique may obviate a potential graft infection or wound complications associated with a formal femorofemoral bypass graft. (*J Vasc Surg* 2002;35:592-4.)

Since its introduction nearly four decades ago, the intra-aortic balloon pump (IABP) has been embraced as a useful device for providing temporary cardiac support in patients with ischemic myocardium. The complication rate associated with IABP placement ranges from 8% to 18%, and complications include limb ischemia, pseudoaneurysm, ileofemoral artery dissection, thromboembolism, and localized wound infection.^{1,2} Numerous reports have noted that acute lower-limb ischemia is the most common complication caused by IABP insertion.^{3,4} When acute limb ischemia occurs as a result of IABP placement, the IABP should be weaned and removed as soon as clinically possible. In IABP-dependent patients in whom acute limb ischemia develops, an extra-anatomic bypass grafting procedure, such as a femorofemoral bypass grafting procedure, may be required to maintain the lower-extremity perfusion. In this report, we describe a percutaneous endovascular technique for creating a temporary femorofemoral bypass graft to relieve acute leg ischemia caused by IABP placement.

METHOD

Before placing the percutaneous femorofemoral bypass graft, a thorough physical examination is critical as a means of ensuring that the Doppler pedal signal is absent in the IABP-inserted (or ipsilateral) leg, and a palpable pulse is

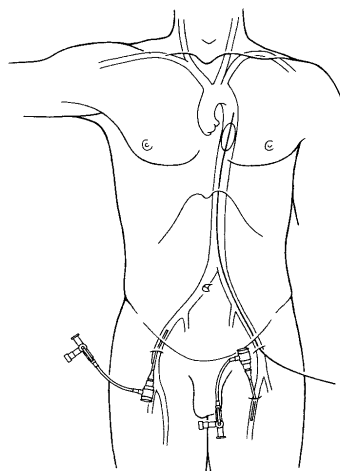


Fig 1. With ultrasound scanning guidance, a 7F introducer sheath was inserted in an antegrade fashion in the superficial femoral artery just below the IABP catheter site. The contralateral common femoral artery was accessed percutaneously, and then a 9F introducer sheath was inserted in a retrograde fashion.

present in the donor (or contralateral) common femoral artery. The bilateral groins and lower abdomen are sterilely cleaned with Betadine solution. The superficial femoral artery (SFA) in the ischemic limb is imaged with ultrasound scanning guidance and punctured percutaneously by using a Micropuncture Introducer Set (Cook, Bloomington, Ind). After the insertion of the guidewire, a 7F Super Arrow Flex introducer sheath (Arrow International, Reading, Pa) is inserted in an antegrade fashion in the SFA just below the IABP catheter site. The contralateral common femoral artery is accessed percutaneously, and then a 9F Super

From the Michael E. DeBakey Department of Surgery, Baylor College of Medicine,^a and the Division of Vascular Surgery, Department of Surgery, Emory University School of Medicine.^b

Competition of interest: nil.

Reprint requests: Peter H. Lin, MD, Michael E. DeBakey Dept of Surgery, Baylor College of Medicine, One Baylor Plaza, 404D, Houston, TX 77030 (e-mail: peterlin1000@aol.com).

Copyright © 2002 by The Society for Vascular Surgery and The American Association for Vascular Surgery.

0741-5214/2002/\$35.00 + 0 24/4/119039

doi:10.1067/mva.2002.119039

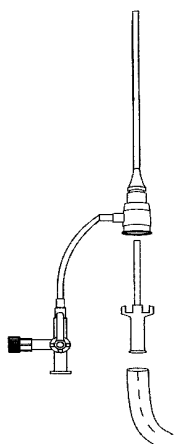


Fig 2. The dilators of both introducer sheaths were trimmed to a 2-cm segment. An 8-mm PTFE graft was connected to the end of each dilator and secured with 2-0 silk ligatures. The dilators were inserted to their respective introducer sheaths.

Arrow Flex introducer sheath is inserted in a retrograde fashion (Fig 1). Next, the dilators of both introducer sheaths are trimmed to a 2-cm segment. A 40-cm-long, 8-mm polytetrafluoroethylene (PTFE) graft (WL Gore, Flagstaff, Ariz) is connected to the end of each dilator and secured with 2-0 silk ligatures. The dilators are inserted to their respective introducer sheaths (Fig 2). The insertion of the shortened dilator into the introducer sheath keeps the one-way valve open, which establishes a femorofemoral bypass graft from the contralateral common femoral artery to the ipsilateral ischemic SFA (Fig 3). It is important to connect the donor femoral sheath first to allow the PTFE graft to be filled with blood before connecting to the ischemic SFA introducer sheath, which minimizes potential distal air embolism. A heparinized saline solution is connected and infused via the side port of the contralateral introducer sheath to maintain a partial thromboplastin time that is 1.5 times the baseline level. The introducer sheaths are securely attached to the skin with 2-0 nylon sutures, and 60-cm by 45-cm Ioban sterile drapes (3M, St. Paul, Minn) are used to tape the PTFE graft and the bilateral groin introducer sheaths.

Once the patient has been successfully weaned off the IABP, the IABP catheter is removed from the patient, and the femoral artery is closed by using a 10F Prostar percutaneous closure device (Redwood City, Calif). Before the femoral graft is disconnected and the groin sheaths are removed, the PTFE graft is test-clamped to ensure that the ipsilateral foot remains adequately perfused. After that, the groin sheaths are removed with Perclose (Redwood City, Calif) closure device deployment to achieve groin hemostasis.

RESULTS

The clinical summary of the four patients with IABP-induced limb ischemia who were treated with the percuta-

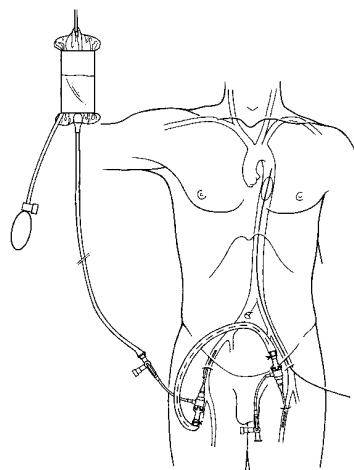


Fig 3. The insertion of the dilator into the introducer sheath kept the one-way valve open, which established a femorofemoral bypass graft from the contralateral common femoral artery to the ipsilateral ischemic SFA. A heparinized saline solution was infused via the side port of the contralateral introducer sheath to maintain a prothrombin time 1.5 times the baseline level.

neous femorofemoral bypass graft is listed in the Table. The limb ischemia was diagnosed clinically in all four patients by means of the loss of either Doppler pedal signal or palpable pedal pulses after the IABP insertion. There was no periprocedural morbidity or mortality. The percutaneous temporary femorofemoral bypass graft was a successful means of resolving IABP-induced limb ischemia in all patients. In a mean follow-up period of 7.0 ± 4.8 months, there was no recurrent ischemia, limb loss, or groin-related infection.

DISCUSSION

Since the introduction of percutaneous insertion in 1979, the use of the IABP as a temporary circulatory assist device in patients with failing myocardium has been prevalent. Numerous studies that examined IABP-related problems have found that limb ischemia was by far the most common complication, with an incidence as high as 17.4%.^{3,5} Ischemia caused by IABP insertion may be the result of a combination of factors, which include luminal obstruction of the IABP catheter, vessel spasm, thromboembolism, and dissection of the iliofemoral arterial segment.⁶ Regardless of the mechanism of the limb ischemia, the therapeutic objective is to restore the limb perfusion by either weaning the IABP as soon as clinically possible or performing an operative extra-anatomic bypass grafting procedure in IABP-dependent patients. The operative treatment of choice for IABP-related limb ischemia is an extra-anatomic femorofemoral bypass grafting procedure, in which a prosthetic graft is placed in a subpubic tunnel between the groins. A disadvantage of this bypass graft is the relatively high incidence of groin-related wound complications, which can occur in as many as 23% of patients with type 1 diabetes mellitus.⁷

Clinical summary of four patients with intra-aortic balloon pump-associated limb ischemia who were treated with a percutaneous temporary femorofemoral bypass graft

Patient	Indication for IABP	Onset of ischemia*	Duration of PTFFBG	Result at discharge	Follow-up period	Result in follow-up
1	Post-CABG LV support	Immediate	3 days	Palpable pedal pulses	4 months	Palpable pedal pulses
2	Unstable angina	4 hours	5 days	Doppler scanning pedal signal	12 months	Doppler scanning pedal signal
3	Cardiogenic shock	30 minutes	3 days	Palpable pedal pulses	10 months	Palpable pedal pulses
4	Left ventricular failure	5 hours	4 days	Doppler scanning pedal signal	2 months	Doppler scanning pedal signal

*Onset of ischemia after IABP insertion.

IABP, Intra-aortic balloon pump; CABG, coronary artery bypass graft; LV, left ventricle; PTFFBG, percutaneous temporary femorofemoral bypass graft.

In this report, we describe an endovascular technique for establishing a percutaneous temporary femorofemoral bypass graft at bedside in patients in whom limb ischemia developed after IABP insertion. All four patients in our series who underwent this temporary bypass graft placement had a good clinical outcome in a mean follow-up period of 7.0 ± 4.8 months. No recurrent ischemia or limb loss occurred after the removal of the temporary bypass grafts in our patients. With certain considerations, we believe this percutaneous temporary femorofemoral bypass graft is applicable in selected patients. First, the contralateral femoral pulse must be palpable so that it can be used as a donor artery. It is not uncommon for IABP-dependent cardiac patients to have co-existent atherosclerotic occlusive disease, particularly in the aortoiliac segment. The lack of palpable pulse in the contralateral femoral artery is suggestive of aortoiliac occlusive disease, and the placement of an introducer sheath in the contralateral diseased femoral artery may render the donor limb ischemic. Another important consideration in performing this percutaneous bypass grafting procedure is the use of ultrasound scanning as a means of identifying the ischemic SFA below the IABP site. In addition, we've found that the Micropuncture set is particularly useful in accessing the SFA with direct ultrasound scanning guidance. The Micropuncture set uses a 21-gauge puncture needle with a 0.018-in guidewire, which permits cannulating small-size vessels with relative ease. We prefer to cannulate the SFA with an Arrow Super Flex introducer sheath, which has a flexible metal-reinforced shaft. This allows the sheath to be positioned away from the IABP catheter without causing a kink in the introducer sheath.

Once the IABP is weaned and removed from the patient, the femorofemoral PTFE graft should be test-clamped before being disconnected from the groins. While the femorofemoral graft is test-occluded, the presence of either a Doppler scanning pedal signal or palpable pedal pulses in the ipsilateral foot implies an adequate antegrade flow in the previously IABP-inserted ileofemoral artery. The femorofemoral graft can then be disconnected from the groin sheaths, which can be removed safely. If the test-occlusion of the PTFE graft leads to the disappearance of the distal Doppler scanning signal, it implies that the ipsilateral ileofemoral artery remains

occluded despite the removal of the IABP catheter. In such a situation, the patient should undergo operative repair with either an ileofemoral thrombectomy or a formal femorofemoral bypass grafting procedure. Although no patient in our series required such a procedure, we believe this precaution should be followed as a means of ensuring that the removal of the temporary femorofemoral graft does not lead to recurrent limb ischemia.

In conclusion, we describe a percutaneous technique for establishing a temporary femorofemoral bypass graft in IABP-dependent patients with limb ischemia. This approach was successful in maintaining adequate limb perfusion in all patients treated in our series, and no procedural-related morbidity, including ischemic or infection complications, occurred in the follow-up period. We believe that the transient nature of the percutaneous femorofemoral bypass graft obviates the potential graft infection or wound complications associated with the formal extra-anatomic bypass graft. This percutaneous temporary femorofemoral bypass grafting procedure should be considered as a treatment option in patients with IABP-related limb ischemia.

REFERENCES

- Allen RC, Schneider J, Longenecker L, Kosinski AS, Smith RB III, Lumsden AB. Acute lower extremity ischemia after cardiac surgery. *Am J Surg* 1993;166:124-9.
- Naunheim KS, Swartz MT, Pennington DG, et al. Intraaortic balloon pumping in patients requiring cardiac operations. Risk analysis and long-term follow-up. *J Thorac Cardiovasc Surg* 1992;104:1654-61.
- Gol MK, Bayazit M, Emir M, Tasdemir O, Bayazit K. Vascular complications related to percutaneous insertion of intraaortic balloon pumps. *Ann Thorac Surg* 1994;58:1476-80.
- Busch T, Sirbu H, Zenker D, Dalichau H. Vascular complications related to intraaortic balloon counterpulsation: an analysis of ten years experience. *Thorac Cardiovasc Surg* 1997;45:55-9.
- Miller JS, Dodson TF, Salam AA, Smith RB III. Vascular complications following intra-aortic balloon pump insertion. *Am Surg* 1992; 58:232-8.
- Kvilekval KH, Mason RA, Newton GB, Anagnostopoulos CE, Vlay SC, Giron F. Complications of percutaneous intra-aortic balloon pump use in patients with peripheral vascular disease. *Arch Surg* 1991;126:621-3.
- Wasfie T, Freed PS, Rubenfire M, et al. Risks associated with intraaortic balloon pumping in patients with and without diabetes mellitus. *Am J Cardiol* 1988;61:558-62.

Submitted Apr 3, 2001; accepted May 28, 2001.