





[illegible]




I used these colors:

**I used this many
colors:**



Make a Bug



Worm


I used these colors:

**I used this many
colors:**

[illegible]

Make a Bug


©Dynamilis.com



I used these colors:

**I used this many
colors:**

inchworm

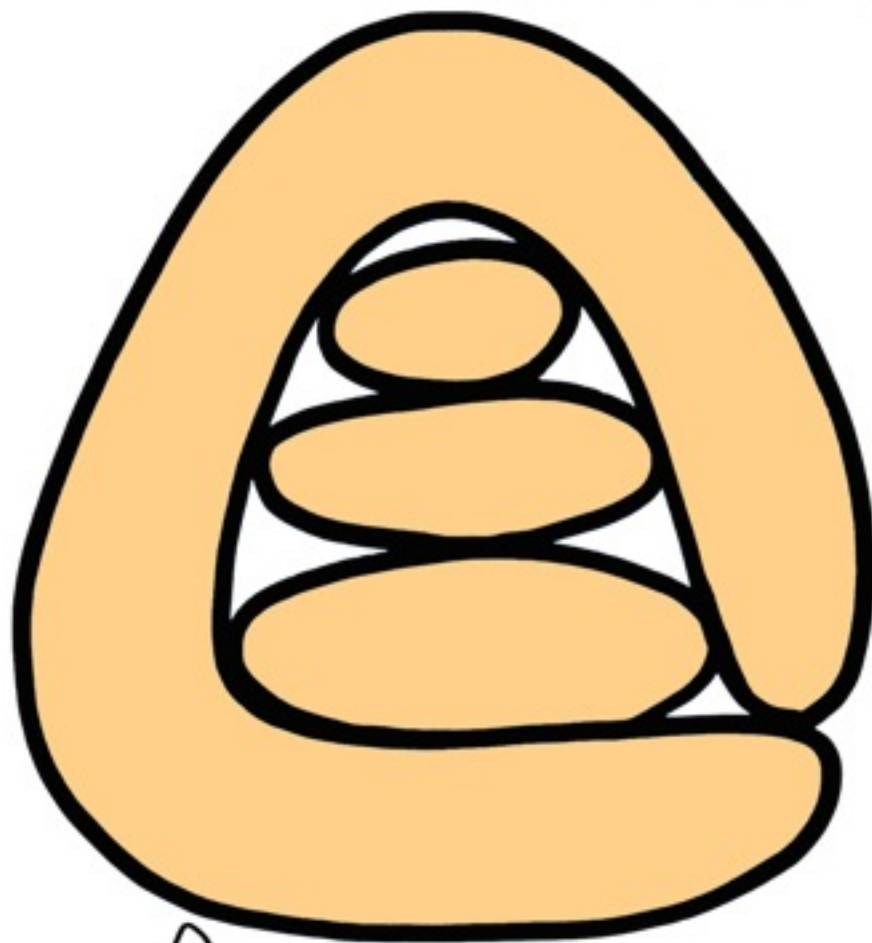


caterpillar

I used these colors:

**I used this many
colors:**

Make a Bug




hive

I used these colors:

**I used this many
colors:**

[illegible]



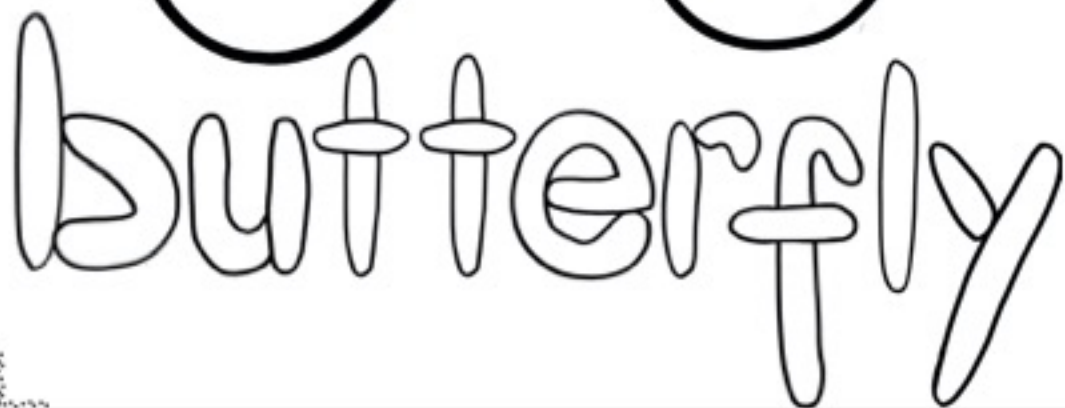



I used these colors:

**I used this many
colors:**

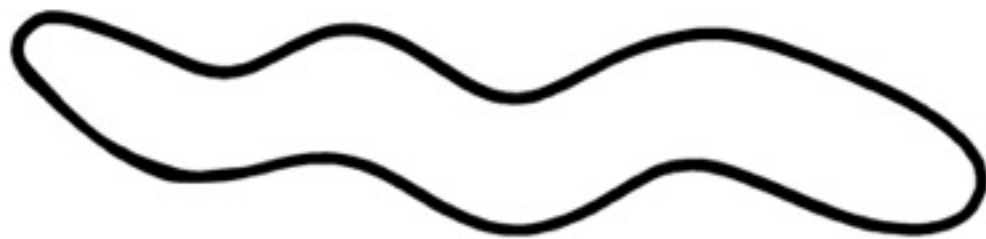[illegible]



I used these colors:

**I used this many
colors:**


Case No.	Case Name	Case Type	Case Status	Case Date	Case Time	Case Location	Case Description	Case Notes	Case Comments
1	John Doe	Medical	Open	2023-01-01	10:00	Room 101	John Doe, 45 years old, male, presented with chest pain and shortness of breath. ECG showed ST-segment depression. Initial treatment with aspirin and nitroglycerin was administered. Patient was transferred to the CCU for further monitoring.	ECG: ST-segment depression in leads II, III, aVF, and V4-V6. Troponin T: 0.05 ng/mL. Creatinine: 1.2 mg/dL. Hemoglobin: 14 g/dL. Hematocrit: 42%.	Dr. Smith
2	Jane Smith	Medical	Closed	2023-01-02	11:30	Room 102	Jane Smith, 62 years old, female, presented with a fall from a height of 10 feet. She sustained a laceration on her right forearm and a fracture of her right radius. The laceration was repaired with 3-0 nylon sutures. The radius fracture was stabilized with an intramedullary nail. Patient was discharged on pain management and a cast for the radius fracture.	ECG: Normal. Troponin T: 0.01 ng/mL. Creatinine: 0.9 mg/dL. Hemoglobin: 12 g/dL. Hematocrit: 38%.	Dr. Jones
3	Michael Brown	Medical	Open	2023-01-03	14:00	Room 103	Michael Brown, 38 years old, male, presented with a headache and vomiting. He was found by his wife at home. His wife reported that he had been drinking alcohol and had been vomiting several times. He was brought to the ER. Initial treatment with antiemetics and analgesics was administered. Patient was admitted to the medical ward for further evaluation.	ECG: Normal. Troponin T: 0.01 ng/mL. Creatinine: 1.0 mg/dL. Hemoglobin: 15 g/dL. Hematocrit: 45%.	Dr. White
4	Sarah Green	Medical	Closed	2023-01-04	16:00	Room 104	Sarah Green, 55 years old, female, presented with a fall from a height of 5 feet. She sustained a laceration on her left leg and a fracture of her left tibia. The laceration was repaired with 3-0 nylon sutures. The tibia fracture was stabilized with an intramedullary nail. Patient was discharged on pain management and a cast for the tibia fracture.	ECG: Normal. Troponin T: 0.01 ng/mL. Creatinine: 0.8 mg/dL. Hemoglobin: 13 g/dL. Hematocrit: 39%.	Dr. Black
5	David White	Medical	Open	2023-01-05	18:00	Room 105	David White, 70 years old, male, presented with a fall from a height of 3 feet. He sustained a laceration on his right hand and a fracture of his right wrist. The laceration was repaired with 3-0 nylon sutures. The wrist fracture was stabilized with a cast. Patient was discharged on pain management and a cast for the wrist fracture.	ECG: Normal. Troponin T: 0.01 ng/mL. Creatinine: 1.1 mg/dL. Hemoglobin: 14 g/dL. Hematocrit: 41%.	Dr. Grey
6	Emily Black	Medical	Closed	2023-01-06	19:00	Room 106	Emily Black, 40 years old, female, presented with a fall from a height of 8 feet. She sustained a laceration on her left arm and a fracture of her left radius. The laceration was repaired with 3-0 nylon sutures. The radius fracture was stabilized with an intramedullary nail. Patient was discharged on pain management and a cast for the radius fracture.	ECG: Normal. Troponin T: 0.01 ng/mL. Creatinine: 0.9 mg/dL. Hemoglobin: 12 g/dL. Hematocrit: 38%.	Dr. Brown
7	Robert Grey	Medical	Open	2023-01-07	20:00	Room 107	Robert Grey, 65 years old, male, presented with a fall from a height of 6 feet. He sustained a laceration on his right leg and a fracture of his right tibia. The laceration was repaired with 3-0 nylon sutures. The tibia fracture was stabilized with an intramedullary nail. Patient was discharged on pain management and a cast for the tibia fracture.	ECG: Normal. Troponin T: 0.01 ng/mL. Creatinine: 1.0 mg/dL. Hemoglobin: 13 g/dL. Hematocrit: 39%.	Dr. White
8	Laura White	Medical	Closed	2023-01-08	21:00	Room 108	Laura White, 50 years old, female, presented with a fall from a height of 4 feet. She sustained a laceration on her left arm and a fracture of her left radius. The laceration was repaired with 3-0 nylon sutures. The radius fracture was stabilized with an intramedullary nail. Patient was discharged on pain management and a cast for the radius fracture.	ECG: Normal. Troponin T: 0.01 ng/mL. Creatinine: 0.8 mg/dL. Hemoglobin: 12 g/dL. Hematocrit: 38%.	Dr. Black
9	James Black	Medical	Open	2023-01-09	22:00	Room 109	James Black, 75 years old, male, presented with a fall from a height of 2 feet. He sustained a laceration on his right hand and a fracture of his right wrist. The laceration was repaired with 3-0 nylon sutures. The wrist fracture was stabilized with a cast. Patient was discharged on pain management and a cast for the wrist fracture.	ECG: Normal. Troponin T: 0.01 ng/mL. Creatinine: 1.2 mg/dL. Hemoglobin: 14 g/dL. Hematocrit: 41%.	Dr. Grey
10	Michelle White	Medical	Closed	2023-01-10	23:00	Room 110	Michelle White, 60 years old, female, presented with a fall from a height of 7 feet. She sustained a laceration on her left leg and a fracture of her left tibia. The laceration was repaired with 3-0 nylon sutures. The tibia fracture was stabilized with an intramedullary nail. Patient was discharged on pain management and a cast for the tibia fracture.	ECG: Normal. Troponin T: 0.01 ng/mL. Creatinine: 0.9 mg/dL. Hemoglobin: 13 g/dL. Hematocrit: 39%.	Dr. Brown



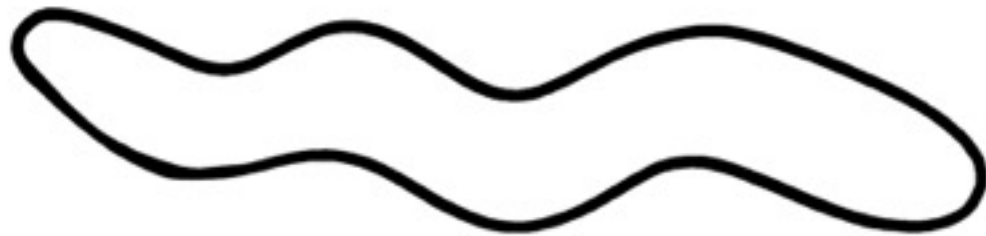Worm

I used these colors:

**I used this many
colors:**




Make a Bug




inchworm

I used these colors:

**I used this many
colors:**



Make a Bug



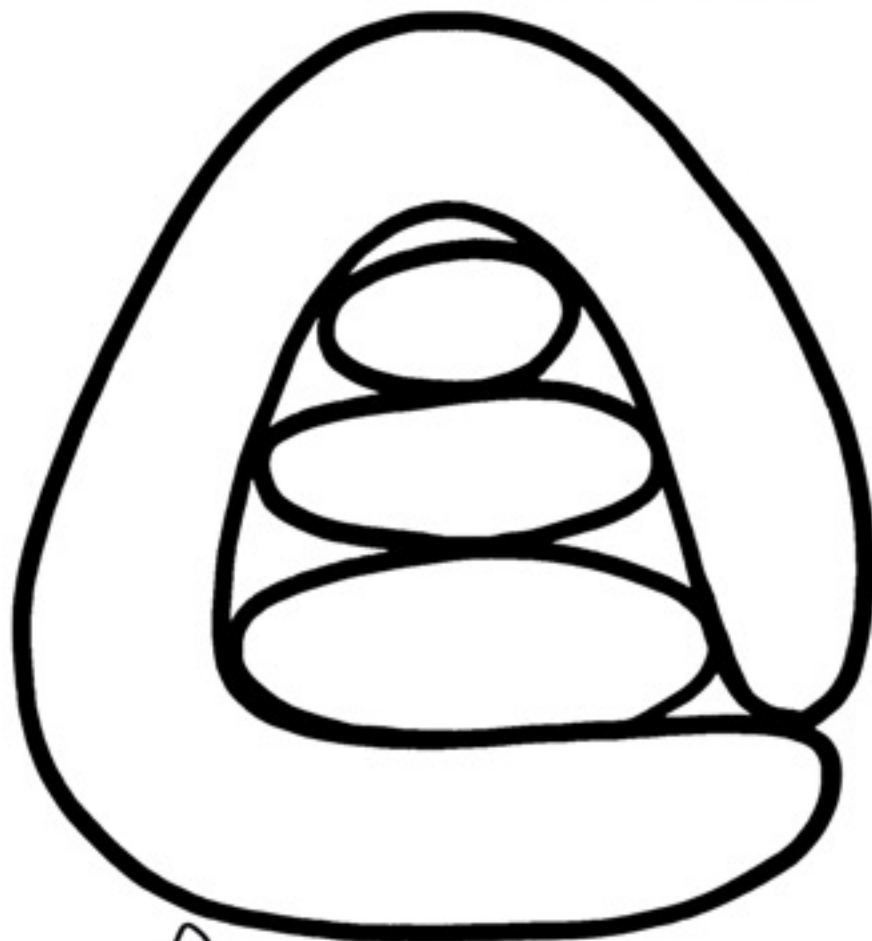
caterpillar

I used these colors:

**I used this many
colors:**



Make a Bug




hive

I used these colors:

**I used this many
colors:**

Date	Time	Location	Observations





Graphics credit:

©2ppaden2art

