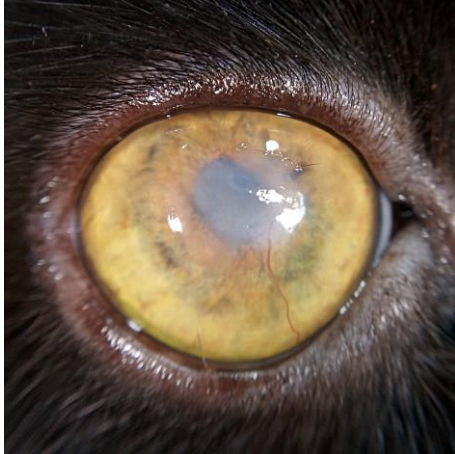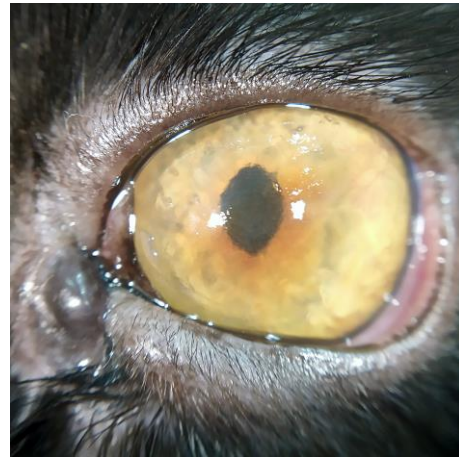


Vet Case Study for QuikVue

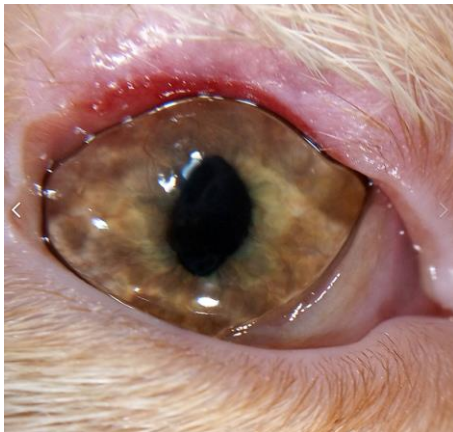
Dr. Ekaterina Vasilyeva is a vet ophthalmologist from Russia. She is glad to share some vet cases she captured with QuikVue®.



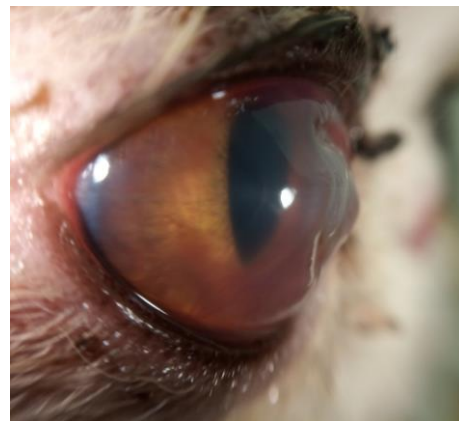Corneal Fibrosis



Corneal Sequestration



Vascular keratitis and the result of treatment of coloboma of the upper eyelid.



Corneal Ulcer

QuikVue® VPA-100

Smartphone Eye Imaging Adaptor

Eye Capture at Your Palm

- 10X magnification
- White/Cobalt blue illumination
- Fit on different phones
- Rechargeable with USB cable

