

# “Through the looking glass: Demystifying ophthalmoscopy”

The ocular examination is divided in to two parts:

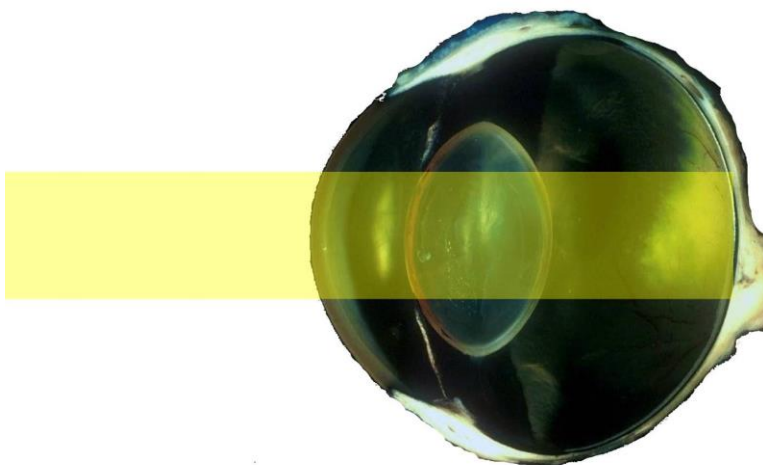
- Examination of the adnexa and anterior segment – possible without instrumentation but aided by a focal light source and magnification.
- Examination caudal to the pupil using the direct and the indirect ophthalmoscope i.e. ophthalmoscopy.

Examination past the pupil involves instrumentation, traditionally the direct ophthalmoscope. For many clinicians the apparent complexity of the direct ophthalmoscope (DO) is a barrier to examination of the eye. Whilst it has a number of limitations the DO is a very useful tool which when used systematically and especially used in conjunction with indirect ophthalmoscopy can enable us to thoroughly examine the majority of our patients eyes.

Examination of the adnexa and anterior segment will be covered separately.

## Concepts to help us “look past the pupil”

**“Visual axis.”:** A clear corridor of transparent tissue between the observer and the central retina of the patient. A clear optical axis requires a normal tear film, corneal epithelium, corneal stroma and endothelium, aqueous humour, lens and vitreous. Remember all of these structures need examining, not just the retina. Opacities within the visual axis will appear as shadows when reflected light from the retina is examined from a distance and the patient is directing its gaze at the observer. Thinning or absence of the retina will cause tapetal hyper-reflectivity where as decreased transparency of any of the structures within the visual axis will result in tapetal hypo-reflectivity.

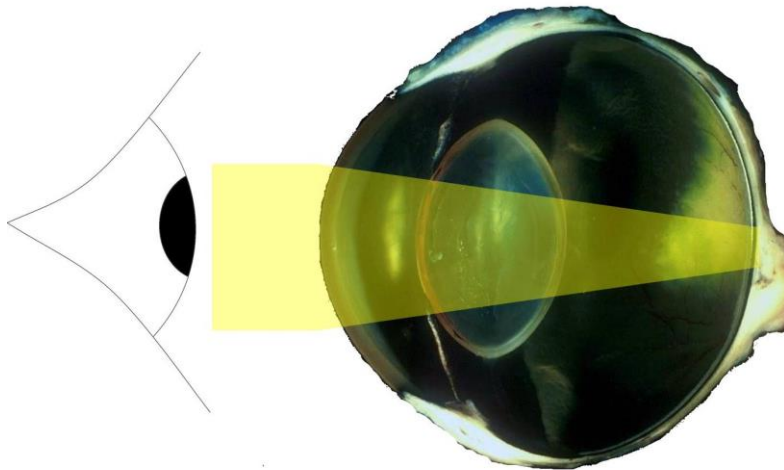


✦ / ✦ ✦

**Figure 1:** The Visual axis. The pathway light takes through the axial structures of the eye. Examination of the reflected light (the tapetal reflex or reflection) allows us to identify opacities in the ocular media and assess tapetal reflectivity.

**Converging lenses:** Positive, converging lenses, enable us to focus on objects closer than we would normally be able to.

**The refractive system of the eye:** Light enters the eye in parallel lines. The optical system of the patients eye, the cornea, aqueous and lens bends the light so that it comes in to focus on the retina. Light leaving the eye is bent once more bringing the image in to focus for a *close* observer. For this reason we do not need additional lenses to examine the retina- we just need to provide sufficient light and to get close enough to see.




**Figure 2:** The refractive system of the eye. If the observer can get sufficiently close to the patients pupil and introduce a light source a direct, magnified, examination of the retina is possible. This is the basis of close direct ophthalmoscopy.

### If it's that simple why can't we see the retina unaided?

- Light can only enter the eye via the pupil, the observer will tend to block light entering the eye.
- The size of the pupil limits the field of view, even when very close only a few mm of retina are visible.

### The first direct ophthalmoscope

The first direct ophthalmoscope was invented by Charles Babbage c. 1847 (right) more widely known for the invention of the first mechanical counting machine the precursor of the computer. His simple device was based on a small brass cylinder with a hole in the side to allow light to enter, striking a mirror at 90degrees to enter the patients pupil. The observer examined the illuminated fundus through a small hole in the mirror, the light being provided by a candle or lantern to one side of the instrument. It is reported that Babbage asked an eminent human ophthalmologist to try his new



device who being myopic was unable to see the patients fundus clearly declared the invention of no use. Thus the first ophthalmoscope was credited to a German inventor, Dr Helmholtz some years later. See box below.

The image shows a reconstruction of Babbage's ophthalmoscope, c. 1847. No actual example survives but this replica was made in 2003, based upon Wharton Jones' written description.



*"Dr. Helmholtz, of Königsberg, has the merit of specially inventing the ophthalmoscope. It is but justice that I should here state, however, that seven years ago Mr. Babbage showed me the model of an instrument which he had contrived for the purpose of looking into the interior of the eye. It consisted of a bit of plain mirror, with the silvering scraped off at two or three small spots in the middle, fixed within a tube at such an angle that the rays of light falling on it through an opening in the side of the tube, were reflected into the eye to be observed, and to which the one end of the tube was directed. The observer looked through the clear spots of the mirror from the other end. This ophthalmoscope of Mr Babbage, we shall see, is in principle essentially the same as those of Epkens and Donders, of Coccius and of Meyerstein, which themselves are modifications of Helmholtz's."*

Wharton-Jones, T., 1854, 'Report on the Ophthalmoscope', Chronicle of Medical Science (October 1854).

This story tells us 2 things:

- The direct ophthalmoscope is in essence a simple device to allow light to enter the patients pupil parallel to our visual axis.
- The clinician's (and the patient's) refractive error will affect the use of the direct ophthalmoscope and *should be corrected for by using the appropriate lens before performing close direct and distant direct ophthalmoscopy.*

### **The anatomy of the direct ophthalmoscope.**

**Rheostat:** Use lowest light level, increase as required. Bright light is painful and causes pupil constriction, being sympathetic to your patient will improve compliance.

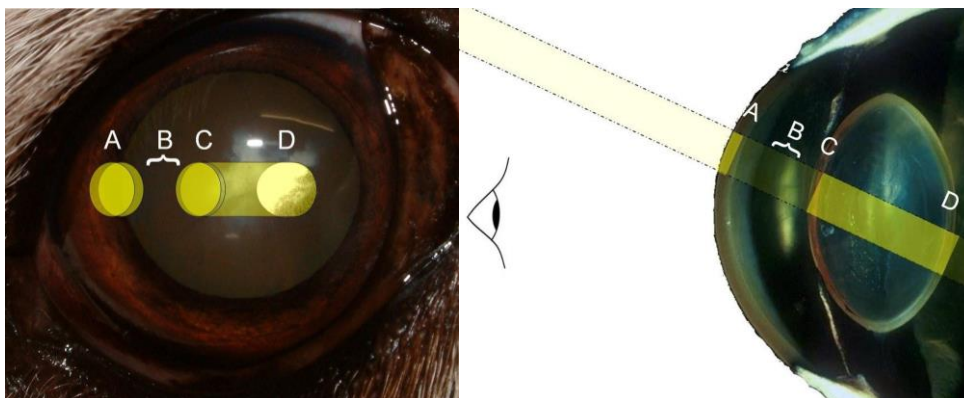
- Remember the inverse square law – increase rheostat brightness as increase distance from the patient. The brightness of a light source with no rheostat can be varied by moving it relative to the patients eye.
- Remember the cat has a very reflective tapetum.
- Small opacities in the visual axis and refractile changes in the optical media (e.g. nuclear sclerosis) are best seen with lower rheostat settings.

**Lens carousel:** The number in the display window is the power of the lens in the viewing window in dioptres, red numbers are positive (converging) lenses, green numbers are negative (diverging) lenses.

- Much of the information we gather with the DO is gained whilst there is NO LENS in the carousel (i.e. 0 dioptres).
- The simplest direct ophthalmoscopes (e.g. the Keeler Vetscope) have only 2 lenses, 12 and 20 dioptres. Many ophthalmoscopes in veterinary practices are designed for human use and will have as many as 30 different lenses with multiple colour and shaped filters.
- Where available the small dioptre lenses can be used to correct for the clinicians refractive error. Glasses should be removed and a distant object viewed through the ophthalmoscope, rotate the carousel until a distant object is in focus. This lens should approximate your refractive error and can then be considered as your “0” setting for that examination.

**Filters:** Start with the largest white circle, for distant and close direct ophthalmoscopy. Additional filters which are commonly used include:

- Cobalt blue filter – used to see fluroscein better
- Slit beam –
  - assessment of aqueous clarity (e.g. aqueous flare)
  - “search light technique” to aid in localisation of lens lesions (see figure 6)
  - identification of raised or irregular corneal, iridal, lens or retinal lesions (e.g. optic nerve head swelling, iris masses)
- Smallest circle –
  - assessment of aqueous clarity (e.g. aqueous flare)
  - “search light technique” to aid in localisation of lens lesions (see figure 6)



**Figure 4:** “search light technique” to aid in localisation of lens lesions. Using either the slit or the smallest circular filter light is shone obliquely through the pupil. The cornea (A), anterior chamber depth and aqueous humour clarity (B), anterior lens capsule (C), lens cortex and nucleus (C-D) and posterior lens capsule (D) can then be clearly identified. This patient’s posterior polar sub-capsular cataract can be seen highlighted at the end of the “searchlight” (D.)

#### Examination technique

Tim Knott MRCVS 0778 2219868 [www.rowereferrals.co.uk](http://www.rowereferrals.co.uk) [eyes@rowevetgroup.com](mailto:eyes@rowevetgroup.com)

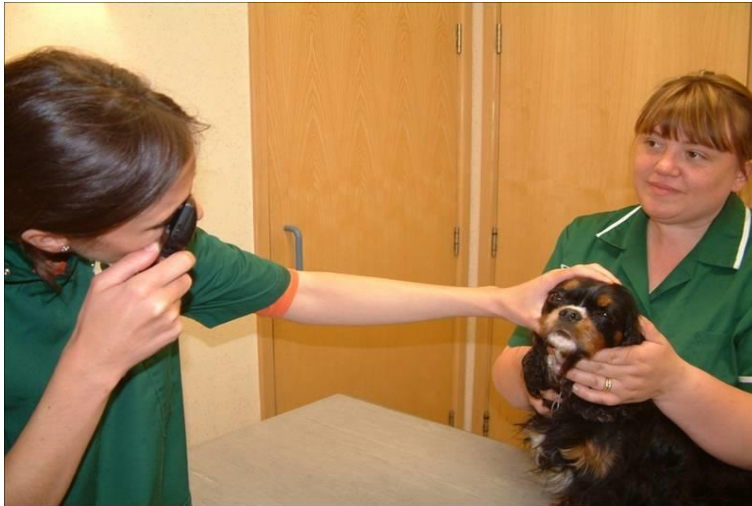A systematic technique is essential to avoid missing important lesions in the eye. A suggested examination protocol is given below.

1. (A focal light source for gross examination of the adnexa and anterior chamber)
2. Distant direct Ophthalmoscopy
  - a. Use as a “pupilometer” : assess pupil size, symmetry, shape and response to light.
  - b. Assess tapetal reflectivity & symmetry.
  - c. Assess opacities in the visual axis
  - d. Assess opacities outside the visual axis
  - e. Localisation of opacities using parallax
  - f. Localisation of opacities using oblique illumination “the search light technique” (figure 6). Note that lesions caudal to the anterior lens will require dilation of the pupil to use this technique.
3. Indirect ophthalmoscopy
4. Close direct ophthalmoscopic retinal examination of the optic nerve head, area centralis, superficial retinal vasculature and specific abnormalities seen with indirect ophthalmoscopy.
5. Then, if abnormalities detected: Direct examination of opacities caudal to the pupil
6. (Direct examination of abnormalities in front of the pupil)
7. (Direct examination of the cornea)

### **Distant direct Ophthalmoscopy**

This technique does not rely on the DO although the focused light source and coaxial illumination provided by the DO make this the preferred instrument. Any light source which can be placed close to the observers visual axis can be used e.g. a pen torch, head torch, auroscope or DO set to “0”.

At arms length the patient is encouraged to direct it’s gaze towards the observer aiming to observe reflected light form the retina – the “tapetal” or “fundic reflex” or reflection.



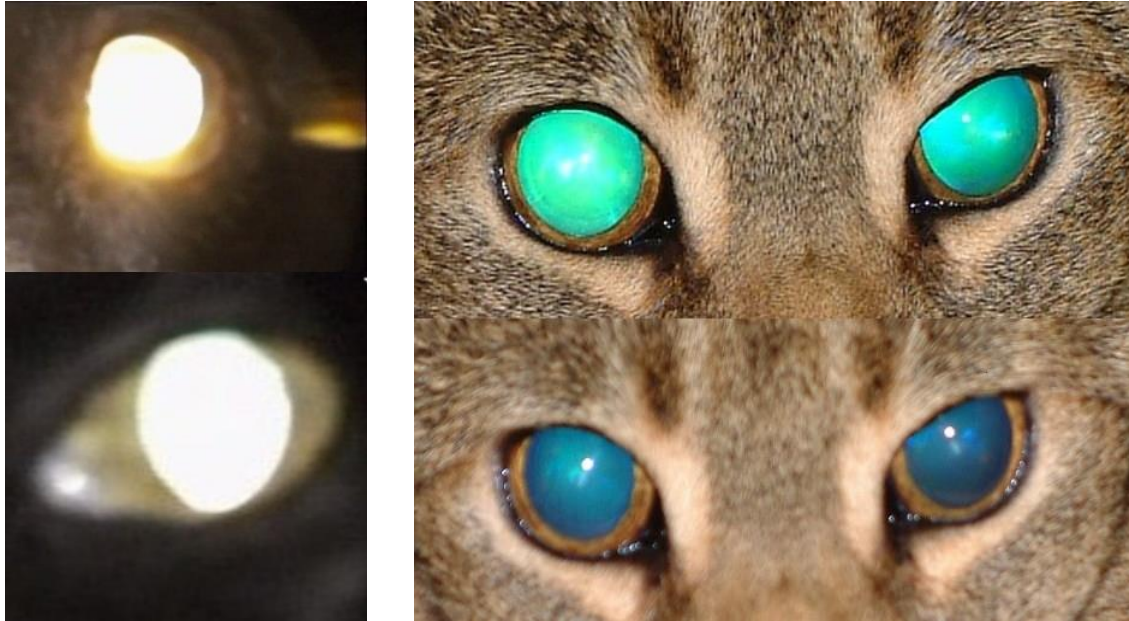
**Figure 5:** Distant direct ophthalmoscopy. This arm's length technique is quick to learn and perform, opacities in the visual axis, pupil abnormalities and changes in tapetal reflectivity are seen easily and quickly.

**Pupilometer:** Both pupils are illuminated at the same time, pupil size is easily compared with this technique and anisocoria and dyscoria clearly observed. Pupil light reflexes (PLR) are then elicited by swinging the light beam from one pupil to the next. This "swinging flash light test" can be used to observe both the direct and indirect PLR, a normal consensual response being observed as an initial dilation prior to constriction from direct illumination as the beam arrives at the tested eye.



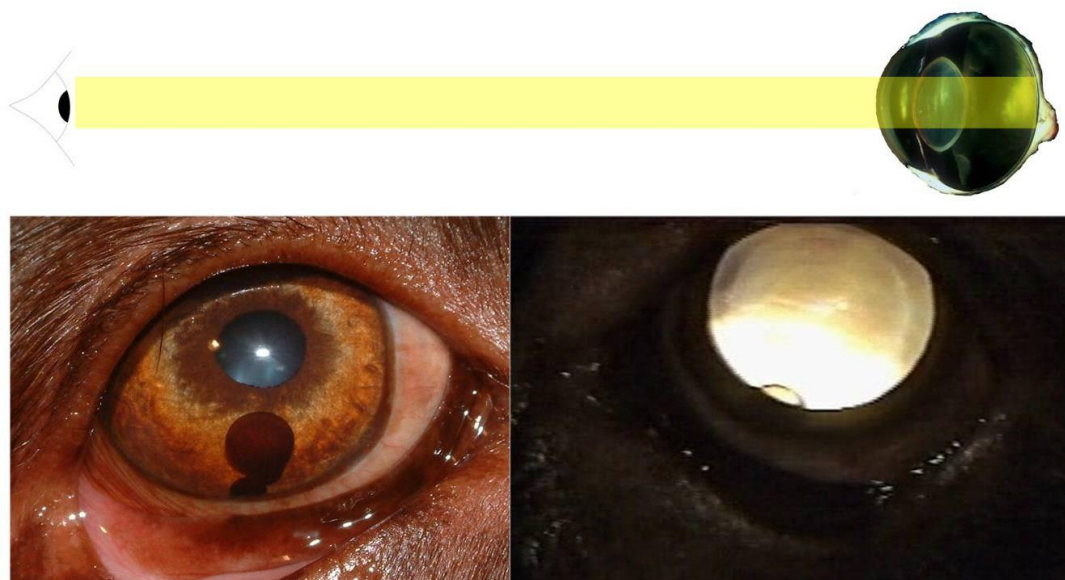
**Figure 6a:** Using distant direct ophthalmoscopy to assess pupil shape, size and symmetry as well as tapetal reflectivity (bottom right). Note the observer must be sufficiently far away that the beam of light covers both eyes (bottom left)

**Tapetal reflectivity:** Differences in tapetal reflectivity and colour are easily seen with this technique. Increased tapetal reflectivity generally reflects retinal thinning or absence such as seen in total retinal detachment. Decreased tapetal reflectivity can be caused by opacities in the visual axis at any level e.g. corneal oedema, ulceration, neovascularisation, pigmentation or scarring, severe aqueous flare, cataract, vitreal opacity or serous retinal detachment.

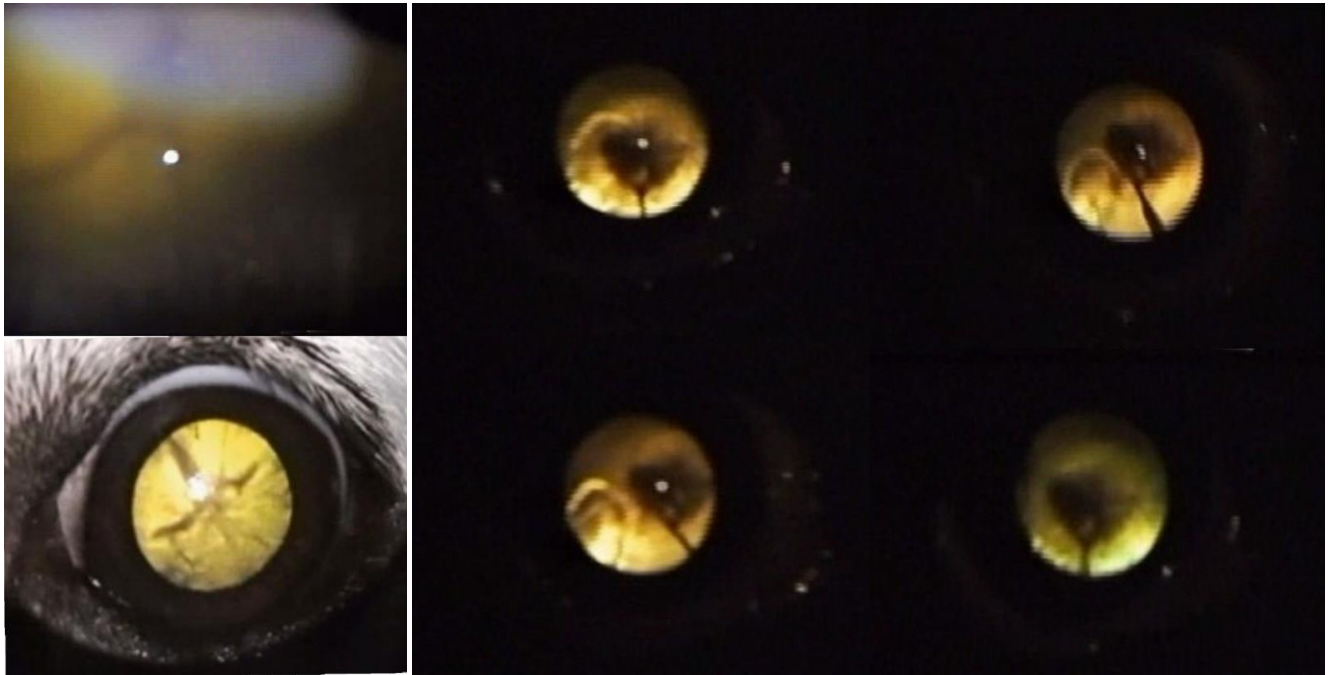


**Figure 6b (above left):** Distant direct view of a normal cat (below) note how bright the tapetal reflection is, and a dilated hyperreflective canine eye (above). This patient has end stage progressive atrophy. **Figure 6c (above right):** Distant direct view (above) of an Abyssinian cat with end stage generalised progressive retinal atrophy. View without benefit of tapetal reflection for comparison (below)

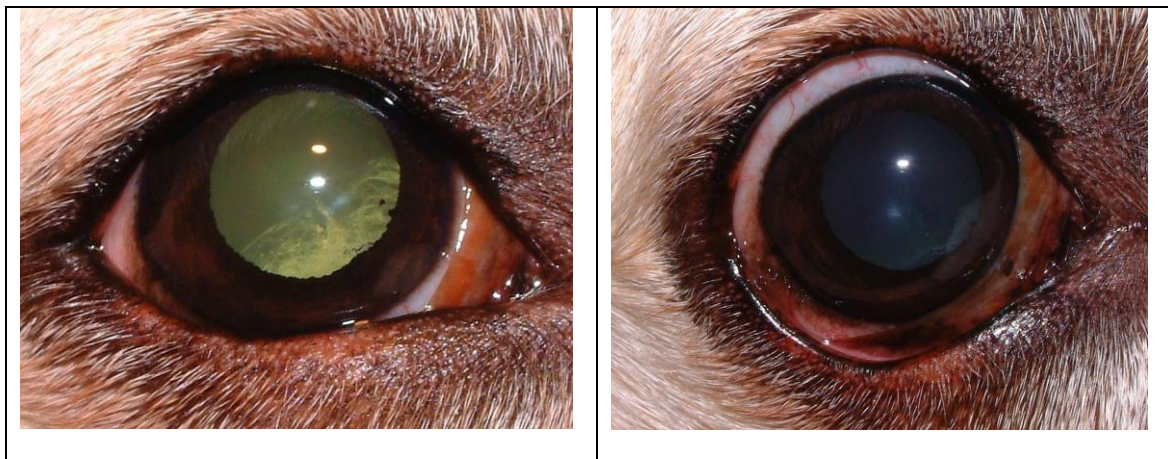
**Opacities in the visual axis:** when viewed against the reflected light from the tapetum form shadows thus appearing dark (figure 7a,b,c). If sufficient incident light then these opacities may also reflect light and appear lighter (figure 7d)



**Figure 7a:** Aged dog with a blue pupil and an anterior chamber iris cyst (bottom left). Distant direct ophthalmoscopy (above) transillumines the cyst at the pupil margin and clearly demonstrates lenticular nuclear sclerosis with concentric refractile rings visible (bottom right)



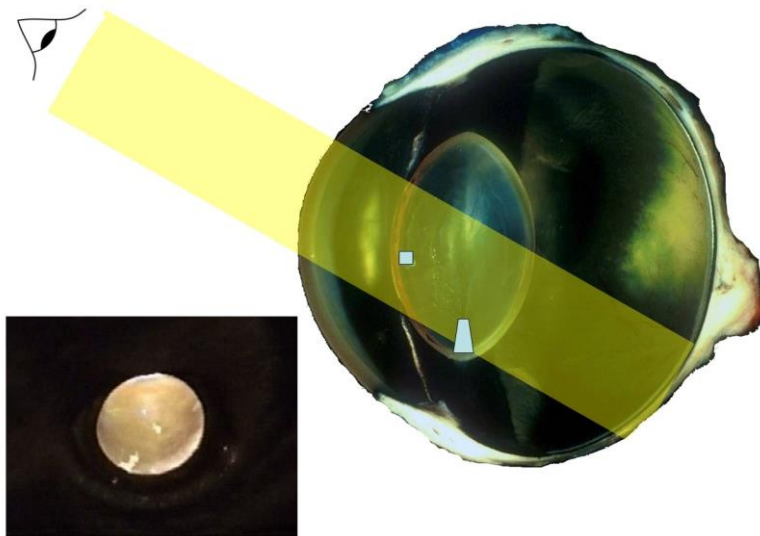
**Figure 7b (above left):** Distant direct ophthalmoscopic view of an immature cataract (below) note that the lens opacities appear black. Some fundic detail can be seen using indirect ophthalmoscopy (above), no retinal detail was visible with close direct ophthalmoscopy illustrating one of the limitations of this technique. **Figure 7c (above right):** Distant direct ophthalmoscopic view of a persistent hyperplastic vitreous and persistent hyaloid artery in a young boxer. Note how the opacities change position within the pupil as the observer uses different angles of illumination



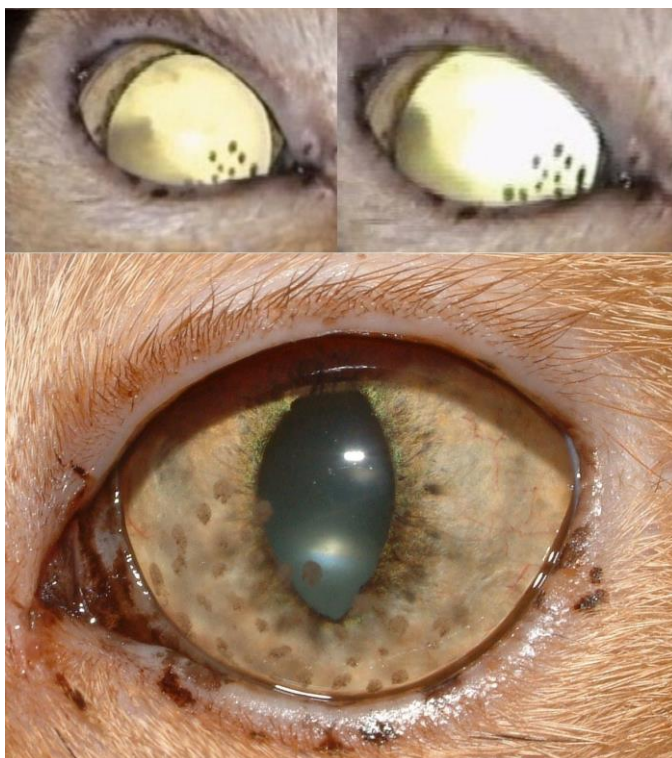
**Figure 7d:** Distant direct ophthalmoscopic view of a cortical cataract (above left) utilising light reflected from the tapetum to highlight the lens changes, note also that ventral posterior synechiae are also highlighted. View without benefit of tapetal reflection for comparison (above right).



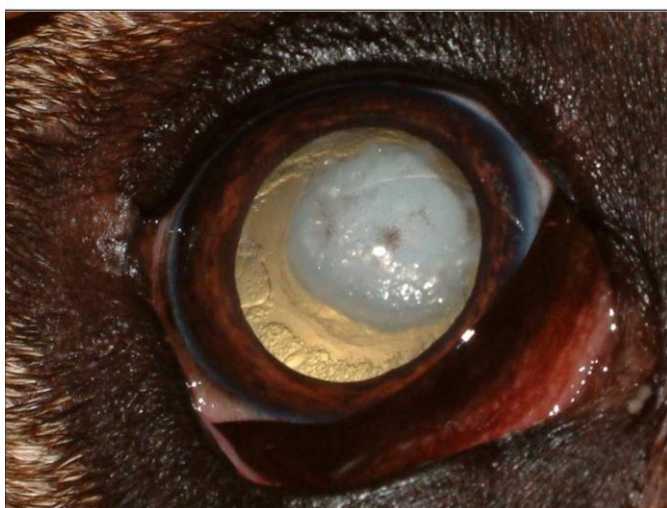
**Opacities outside the visual axis:** A deliberate effort should always be made to examine the tapetal reflex at oblique angles through the pupil aiming to identify equatorial lens and peripheral anterior vitreal opacities e.g. "snow banking" caused by the build up of inflammatory cells on the peripheral posterior lens capsules. See figures 8a and 8b. Examine all four quadrants. And note that the smaller the pupil the more oblique the angle required.



**Figure 8a :** An oblique viewing angle highlights a peripheral lens lesion. Note also the anterior subcapsular opacity remains in the centre of the lit pupil despite the oblique angle.



**Figure 8b :** Feline patient with chronic uveitis. Keratic precipitates are visible with ambient light (below) however the distant direct ophthalmoscopic view demonstrates the corneal changes much more readily whilst also highlighting equatorial posterior lenticular opacities (inflammatory exudate associated with pars plana inflammation also known as "snow banking" or pars planitis). Note that changing the angle of view results in movement of both opacities relative to the pupil (above)



**Figure 8c:** Distant direct ophthalmoscopy highlights the dense nuclear cataract and the peripheral lens vacuoles (below). In a similar way that the rings in a tree trunk can tell us the life story of the tree (above) lesions in the centre of the lens are generally congenital whilst opacities in the peripheral lens are recent.

**Localisation of opacities using parallax:** Opacities caudal to the pupil will move in the opposite direction to a moving observer of the tapetal reflex, opacities at the level of the pupil (i.e. the anterior lens capsule) will remain in the centre of the tapetal reflex regardless of the observers position whilst opacities anterior to the pupil will appear to move with an observer. See figures 8a and 8b.

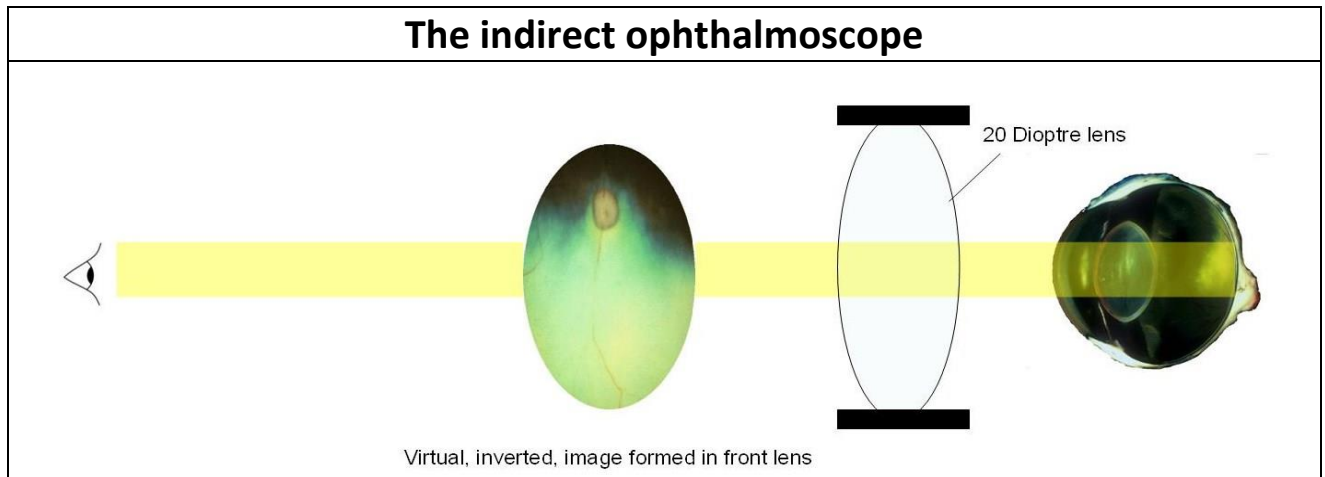
**Indirect ophthalmoscopy – the diagnostic converging lens. Your wide angle view of the retina.**

A 20 Dioptre lens is usually used for dogs, cats, rabbits, horses, sheep and cattle.

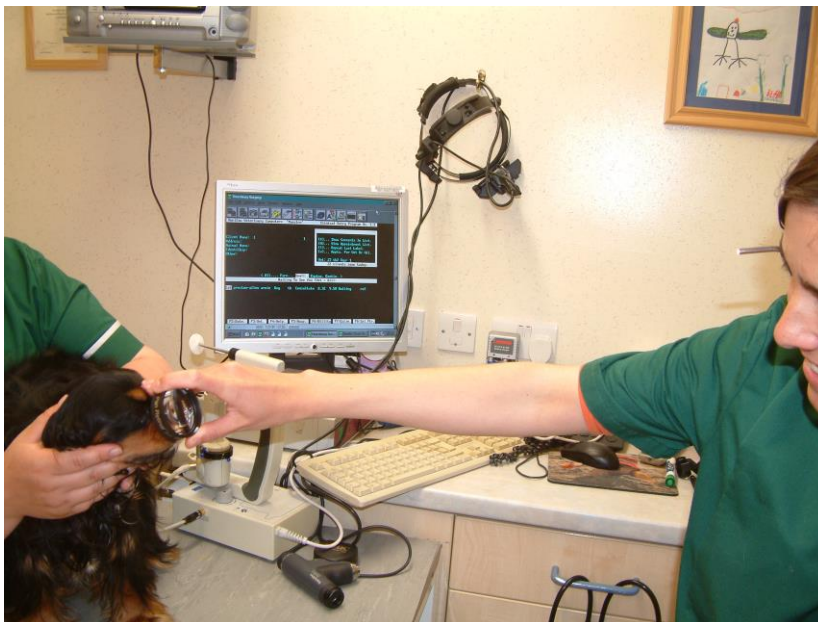**Key points in indirect ophthalmoscopy:**

- This technique will show you the central third (56-62degrees) of the retina in one view (compare 3-4degrees with a DO).
- The closer your light source is to your visual axis the easier it is to see a tapetal reflex and the easier it is to obtain a retinal image.
- Without a tapetal reflection no image can be formed, practice distant direct technique first.
- Flat surface of lens towards patient – use small dab of correction fluid on the flat side of the rim to remind you.

- Hold lens with thumb and forefinger, rest little finger on patients brow, practice swinging lens in and out of position.
- The lens must be at 90 degrees to the tapetal reflection, both horizontally and vertically.
- There is an optimum distance from the cornea where the retinal image will appear to fill the whole lens. This “sweet spot” can be found with a little practice by moving the lens backwards and forwards, it should be somewhere between 3 and 5 cm from the cornea.



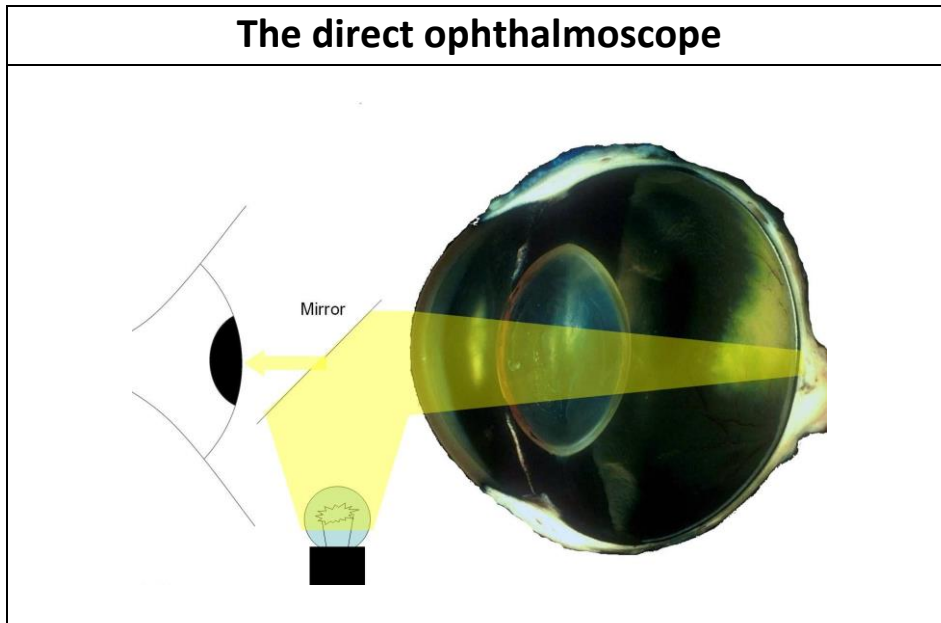
**Figure 9a:** A converging lens, usually 20Dioptres in Veterinary ophthalmology, is held at arms length and placed 2-3 cms in front of the patients eye once a tapetal reflection is seen. Note that the lens must remain perpendicular to the reflected light from the tapetum. The main advantage of this technique is the large field of view seen.



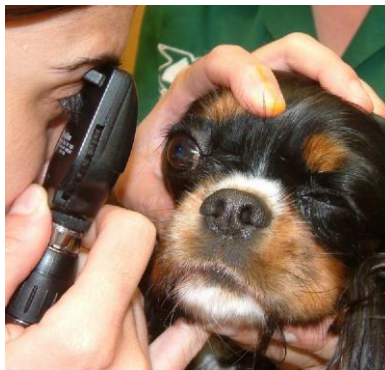**Figure 9b:** Performing monocular indirect ophthalmoscopy. A light source is held as close to the observers visual axis as possible. The lens is held between index finger and thumb with two fingers resting on the patients forehead. Once a tapetal reflection is seen the lens is placed perpendicular to the observers view some 2-3 cms

in front of the patient's eye. If the image is lost the lens is moved to one side keeping contact with the patient's forehead until the tapetal reflection is regained and the lens returned to the viewing position.

### Close direct ophthalmoscopy – “looking at the retina in detail”



**Figure 10a:** the direct ophthalmoscope aligns illumination with the observers viewing axis. The fundus is directly examined through a hole in a mirror. A magnified view (approximately 15x ) of a small area (3-4degrees) of the retina is seen.



**Figure 10b:** Close direct ophthalmoscopy. Maintain two points of contact with the patients head where possible. Using your left eye for the patients left eye and your right for the patients right takes a little practice but reduces the risk of accident.

#### Key points in direct ophthalmoscopy:

- This technique provides significant magnification of the retina (15x) coupled with a smaller field of view.
- Start with the lowest light level available and increase as required- this will reduce pupil constriction and keep the patient comfortable.

- The DO should touch your brow, this maximises your view whilst minimising the risk of injury should the patient knock the instrument.
- It is less threatening to position the DO adjacent to the patient's eye before bringing your eye to the instrument.
- Bridge the patient's eye with two fingers which can be used to open the eye lids if required. Rest the DO on your other hand to form a steady position.
- Retinal examination requires no lenses (i.e. 0) providing:
  - The patients globe is the correct size
  - The retina is in the correct place.
  - The clinician's refraction is normal.
  - The patients refraction is normal- NB refractive errors large enough to affect the retinal view with a direct ophthalmoscope are exceedingly rare in veterinary species (contrast man). The exception to this is lens luxation or subluxation where in the dog a refractive error of approximately 14dioptries is seen when the lens is removed from the visual axis.

If the retina is not clearly in focus when viewed with a "0" setting ask the following questions:

- Is my refraction normal? Have I corrected for my refraction after taking my glasses off? Remove glasses, look through the ophthalmoscope at text at least 2 metres away – rotate the lens carousel until the text is clearly in focus – the lens selected should approximate your glasses prescription.
- Is my patient's refraction normal? Is the lens in the correct place (e.g. posterior lens luxation)?
- Is the globe enlarged?
- Is the globe smaller?
- Is the retina detached?
- Is the visual axis transparent?

If the optic nerve head is not clearly in focus with a "0" setting ask the following questions:

- Is the optic nerve head swollen? i.e. in front of the retina
- Is the optic nerve head cupped? i.e. behind the retina

Rotating the carousel of lenses until the retina or optic nerve head comes in to focus can help us to decide the answers to these questions (see figure 11 below).

If the addition of positive lenses (red) brings the retina or optic nerve head in to focus then these structures are closer to us than they should be or the patient's lens is in the wrong place

If the addition of negative (usually green) lenses brings the retina or optic nerve head in to focus then these structures are farther away than they should be.

## Direct examination of opacities

If opacities or abnormalities are identified using the distant direct technique they should be localised using parallax as described above. Once the approximate position within the globe has been found the DO can be used to directly examine lesions by the addition of converging (red) lenses. Figure 17.

The table below gives guidelines for settings for direct examination of different parts of the eye, remember that the distance from the cornea will also affect the focal distance of the ophthalmoscope significantly.

Lens (red=positive or converging lenses)	Structure in focus
0	Retina
12	Posterior lens capsule, anterior vitreous
15	Anterior lens capsule, iris face
20	Cornea , conjunctiva & eye lids

**Figure 11:** Direct examination of opacities within the eye can be performed by using the direct ophthalmoscope's lens carousel to focus through the eye. Starting at the retina (0 setting, no lens, upper left) rotating the carousel through the positive dioptre lens will focus the instrument towards the cornea where the highest dioptre lens (usually 20, lower right) can be used for close examination of the ocular surface.

# *Pre-Course instructions: “Using the smart phone to image the eye”*

You're usually asked to turn your smart phones off during CPD however this course is the exception. During the day we will be using training models to practice smart phone photography techniques. To get the most out of the day please follow the instructions below ideally before the course. Any questions before or after the course please WhatsApp, message or ring Tim on +44 7782219868 or email at [timknott@rowevetgoup.com](mailto:timknott@rowevetgoup.com). **Check out [www.TheEyePhone.com](http://www.TheEyePhone.com) for more hints and tips.**

**STEP1: CHARGE YOUR PHONE, BRING YOUR CHARGER (& A POWER PACK IF YOU HAVE ONE).**

**STEP 2: WHATSAPP TIM (WITH YOUR NAME) SO WE CAN ADD YOU TO THE COURSE DISCUSSION GROUP (+447782219868)**

**STEP 3: DOWNLOAD A CAMERA APP FOR IMAGING THE EYE: WHICH IS THE BEST CHANGES REGULARLY, I TRY TO KEEP MY FAVOURITES LISTED ON THE WEBSITE [WWW.THEEYEPHONE.COM](http://WWW.THEEYEPHONE.COM) HOWEVER MY CURRENT TOP APPS ARE:**

**Android:**

1. ***OpenCamera\* (Free, Mark Harman, [www.opencamera.org](http://www.opencamera.org)) . PREFERRED***
2. Camera MX (free)
3. Camera FV-5 lite (free)
4. “A better camera” (free)

**iOS**

1. ***Procamera\* -adjustable LED intensity coupled with manual focus and exposure and an excellent focus assist mode make this app the best app I've found so far. PREFERRED***

2. Camera+2 - the updated version of the original 3. Camera+ legacy - an old favourite, still the easiest app to use but as cannot adjust the LED brightness diffusing the LED with tape or paper is required.

NB if you have an Android then the camera app which comes with your phone may already be able to take pictures in “torch mode” (this allows you to take photos whilst the LED is continuously on which is the key feature in allowing you to use your phone like a digital ophthalmoscope. For all phones your video mode will normally also allow you to have the LED on continuously, try and learn how to turn this on – this is your simplest tool for smart phone photography and the easiest to show clients.

**STEP 4 OPTIMISE APP SETTINGS. AVAILABLE CUSTOMISATION SETTINGS VARY BETWEEN APPS HOWEVER THE FOLLOWING ARE USEFUL TO CONSIDER:**

- File format - JPG (100%) and RAW or DNG if available

Tim Knott MRCVS 0778 2219868 [www.rowereferrals.co.uk](http://www.rowereferrals.co.uk) [eyes@rowevetgroup.com](mailto:eyes@rowevetgroup.com)

- Set maximum image capture resolution
- Save location - save to camera roll and not to app
- Manual focus - turn on, this will allow you to set your focus at infinity(for fundus) or at the MFD (for distant direct cornea and lens photography). This setting will stop the camera “hunting” for the right focal point.
- “touch/tap to focus” and “touch/tap to set exposure” - turn on
- “Volume snap” –turn on, this allows you to press the volume buttons to take images.
- “live exposure” – turn on, this will display your ISO and shutter speed and help you decide if your LED illumination needs to be altered
- Focus peaking - turn on
- Geotagging - turn on, always remember where you were when you took the image – a real help when trying to locate images if you work at different locations
- EXIF and social tags - turn on and put your name / clinic
- Shutter sound - turn off

#### STEP 5: UNDERSTAND YOUR APP. LEARN HOW TO:

**Control the light:** Turn on the LED continuously using the “torch mode” also labelled as continuous flash mode in the open camera app. With ProCamera on iPhones you can also change LED intensity

#### **Control focus :**

- manual vs tap to focus vs autofocus
- force the minimum focal distance, - this helps with “distant direct photography “ of lens and corneal lesions and usually can be selected using the “macro” setting indicated by a flower icon
- force focussing at infinity - this helps with fundus photography and is usually indicated either by a mountain or an infinity icon ( $\infty$ )
- adjust and lock focus manually - this helps with difficult image lesions such as KPs, small cataracts etc

**Measure and alter sensitivity to light & amount of light entering camera:** As most smartphone cameras have a fixed aperture (or f stop) they can only alter exposure by changing shutter speed and/or altering the sensors sensitivity to light (ISO). Forcing your camera app to display both shutter speed and ISO will help you to get the very best images by helping you understanding why an image is suboptimal. High ISO settings will allow image capture in low light conditions e.g. when imaging a slit beam with your macro lens but will add grain and loss of fine detail. Low shutter speeds will lead to camera shake affecting your all-important focus. In general aim for:

- the lowest possible ISO (usually 25) and try and avoid using ISO >400.
- a shutter speed of 1/50th second or faster

Tim Knott MRCVS 0778 2219868 [www.rowereferrals.co.uk](http://www.rowereferrals.co.uk) [eyes@rowevetgroup.com](mailto:eyes@rowevetgroup.com)