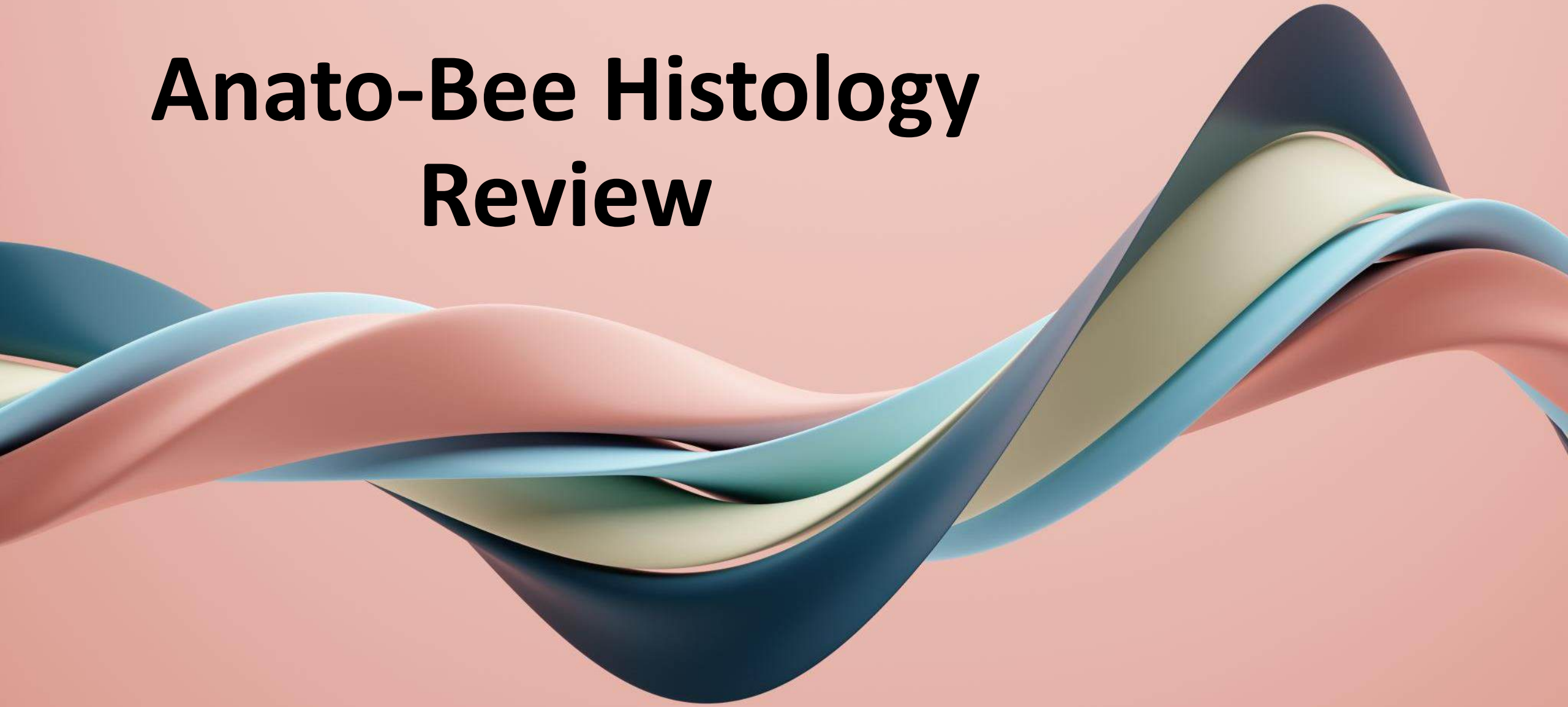

Anato-Bee Histology Review



This atlas is meant to assist in student preparation for the Anato-Bee competitions. This atlas utilizes open-source images from a variety of electronically accessed resources, which can be found cited with our references at the end of the slide deck.

Atlas compiled by:

Anish Sethi, BS

Anish was born & raised in the suburbs of Minneapolis, Minnesota and graduated from the University of Minnesota, Twin Cities. He is currently a second-year medical student at Drexel University College of Medicine and is interested in neurology. In his free time, Anish enjoys working out, training for flight school, and cooking!

Atlas edited by:

Dana Peterson, PhD

Mary Piscura, PhD

Jenna Hagerty, MS, PhD

Last updated: October 2024

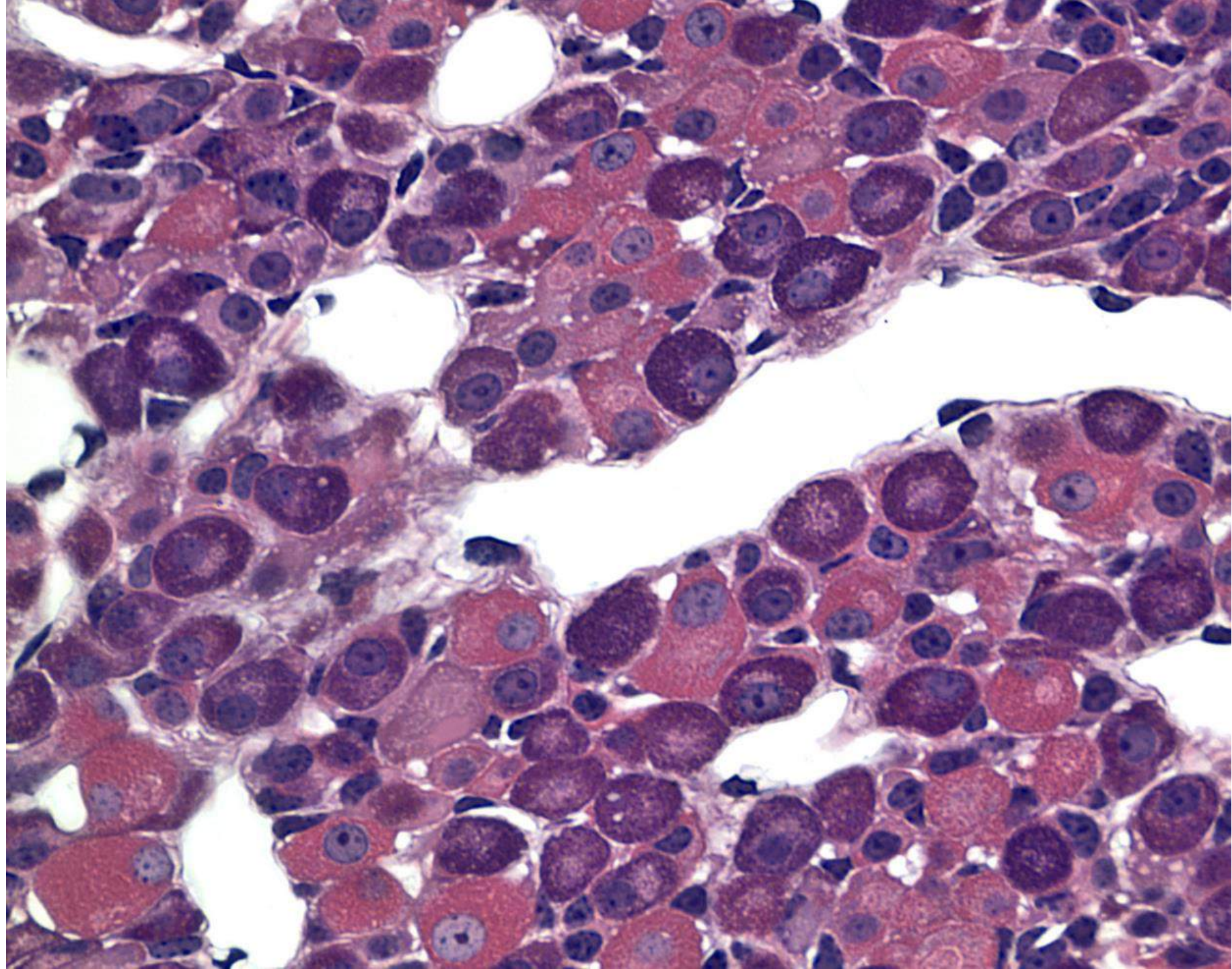


ANATO-BEE



Pictured: Anish Sethi, student creator of the Anato-Bee Histology Review atlas.

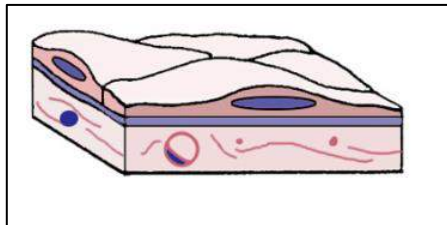
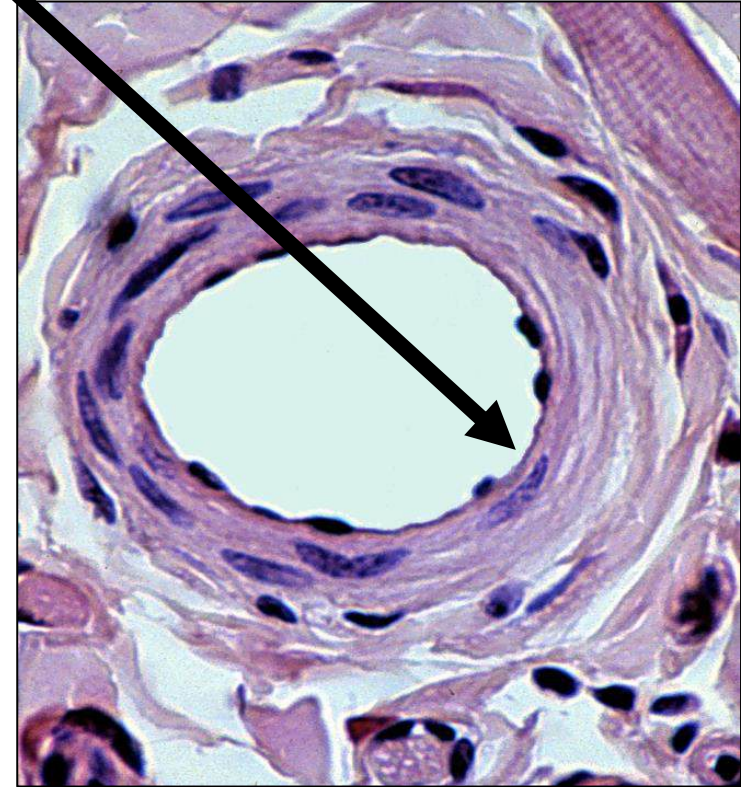
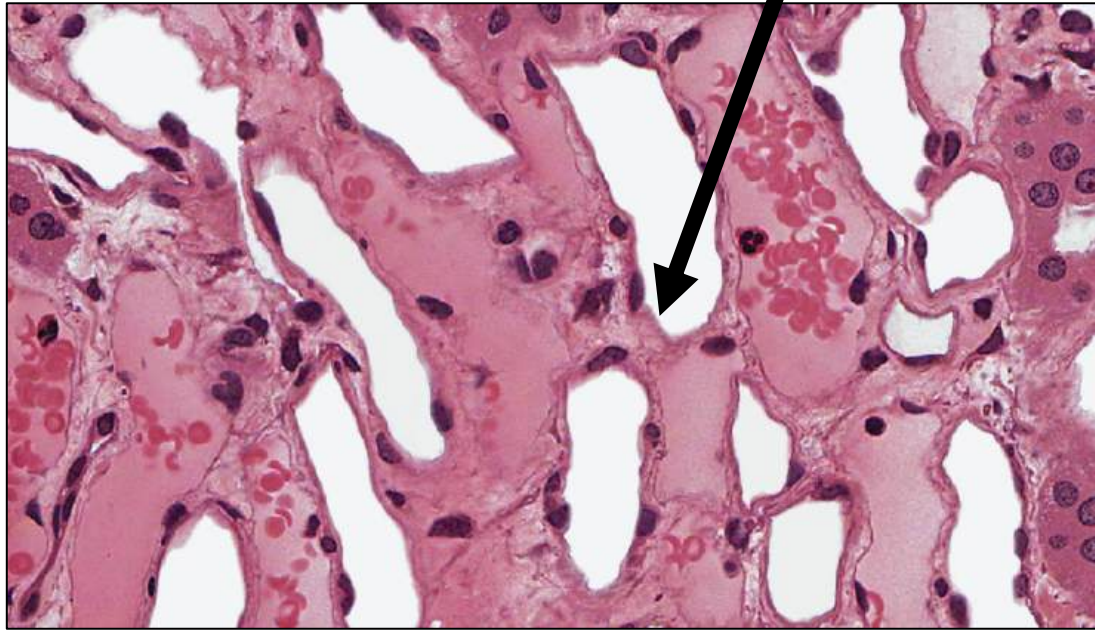
Epithelium & Glands



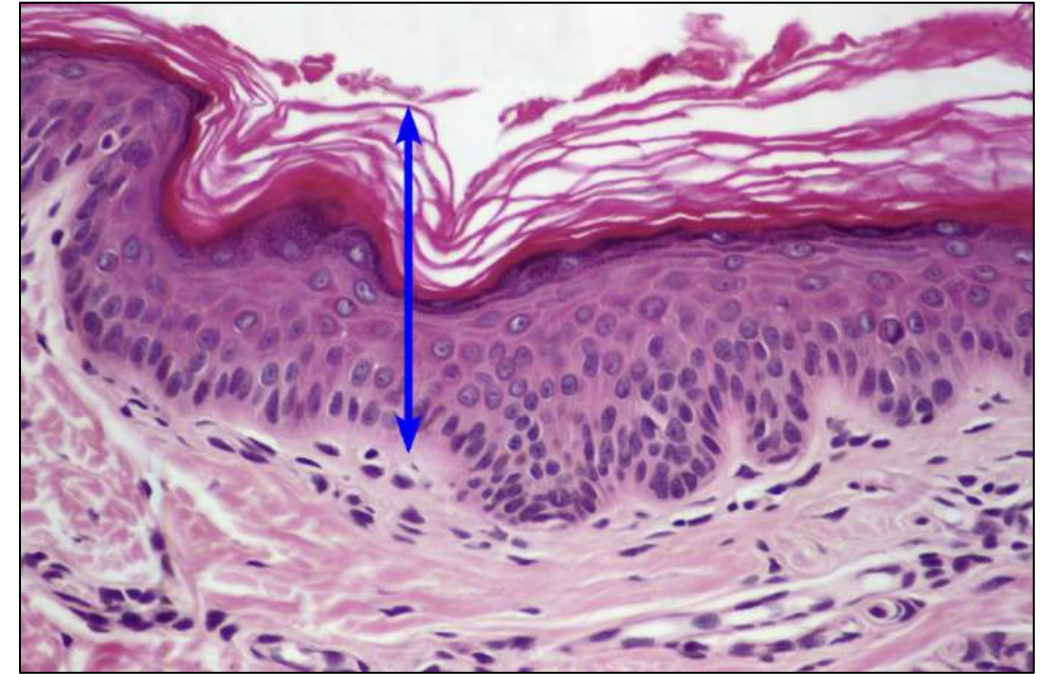
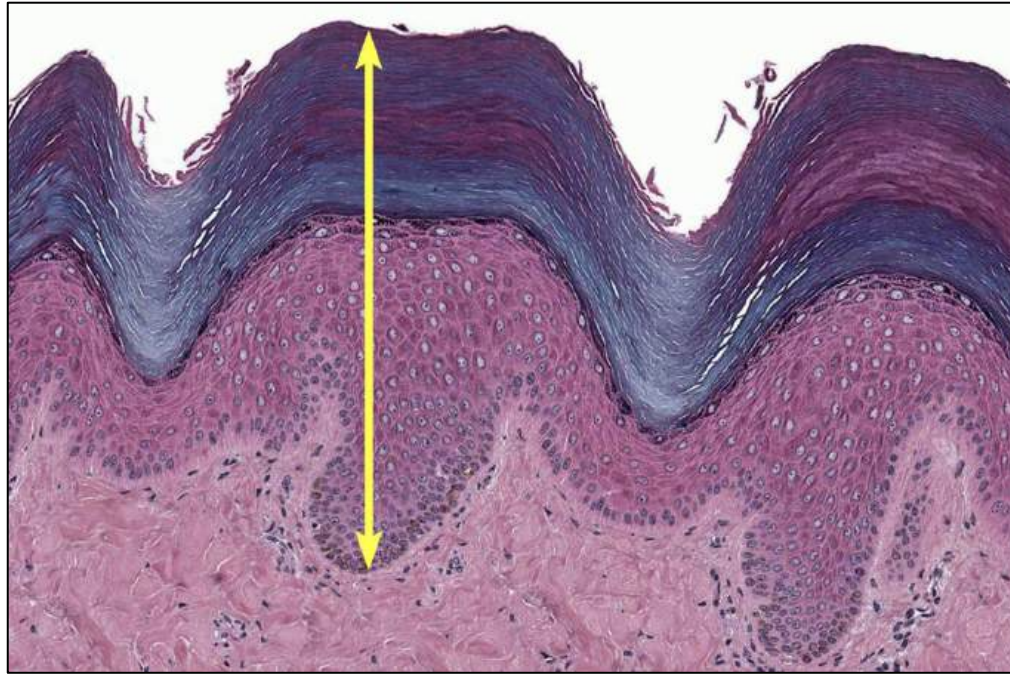
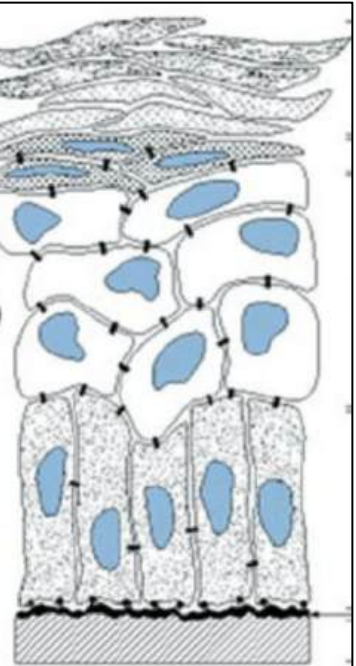
Types of Epithelia

- Simple squamous epithelium
- Stratified squamous epithelium
 - Keratinized
 - Non-keratinized
- Simple cuboidal epithelium
- Simple columnar epithelium
- Pseudostratified ciliated columnar epithelium
- Transitional epithelium/Urothelium

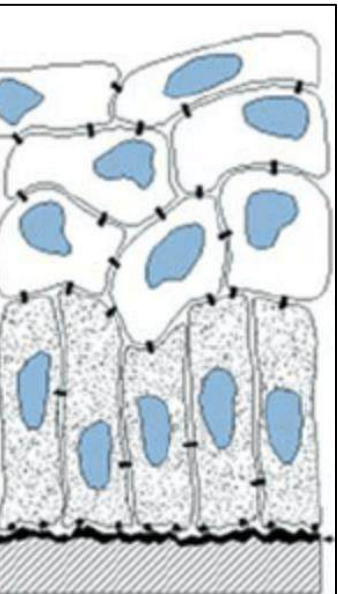
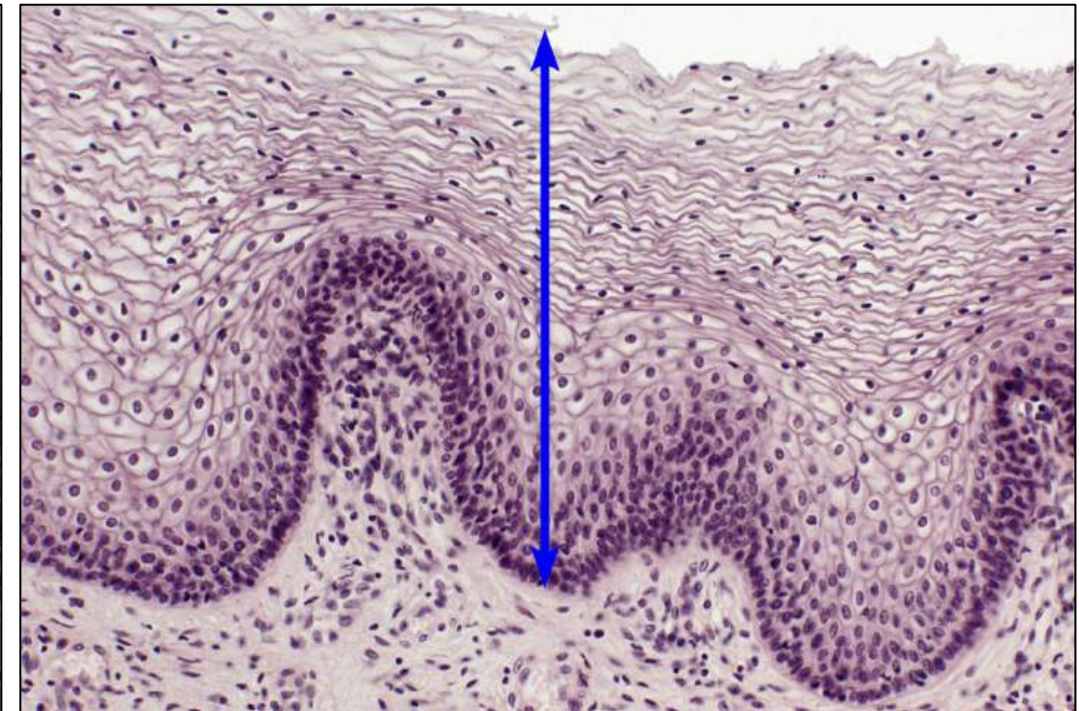
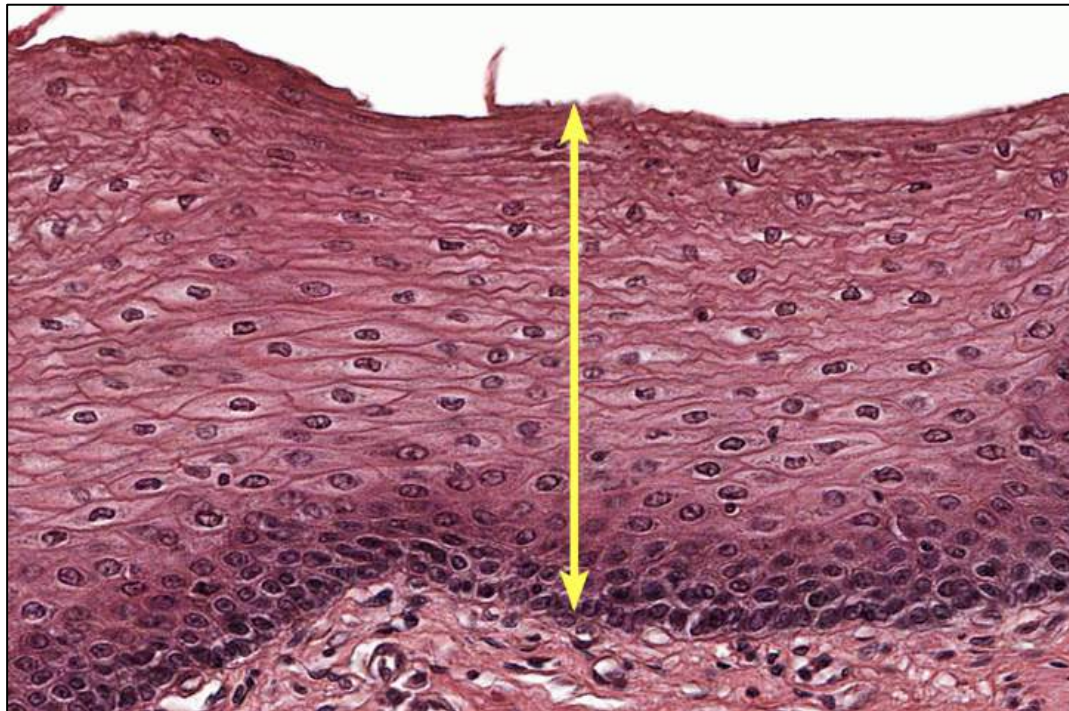
Simple Squamous Epithelium



Keratinized Stratified Squamous Epithelium

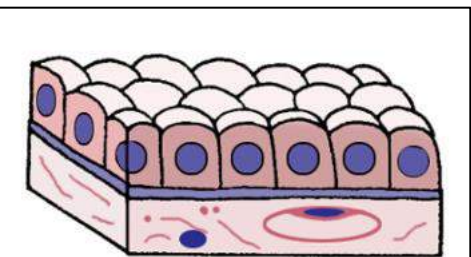
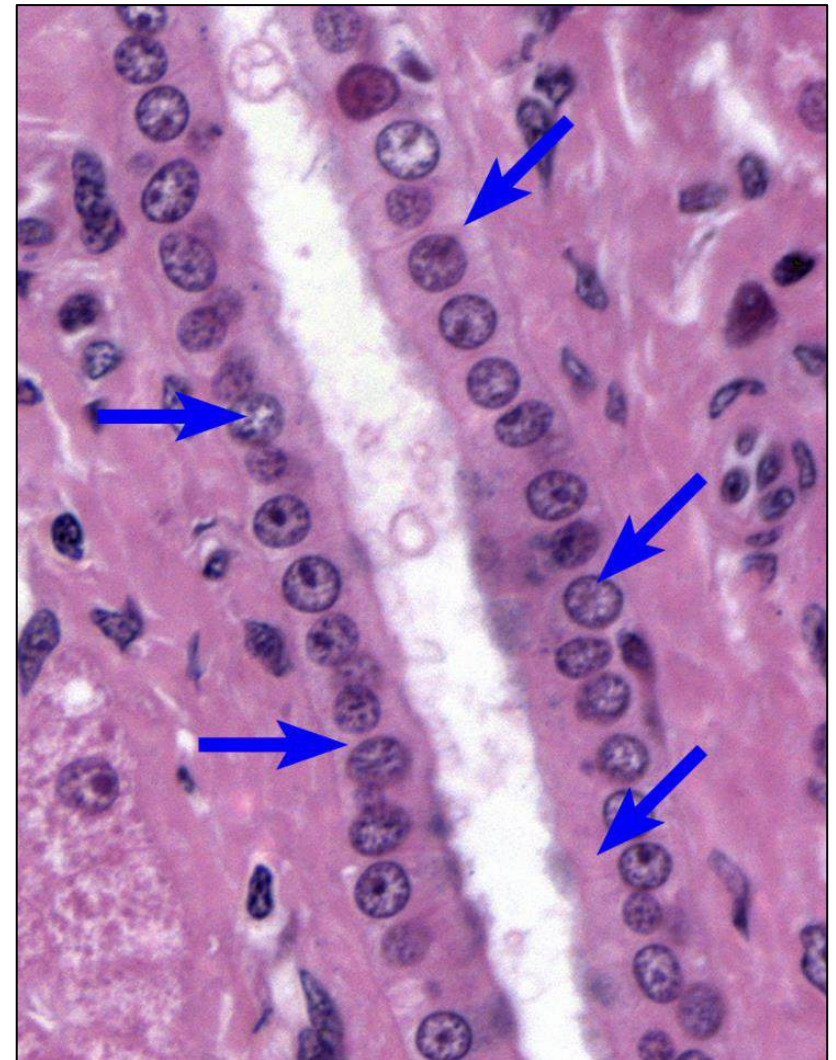
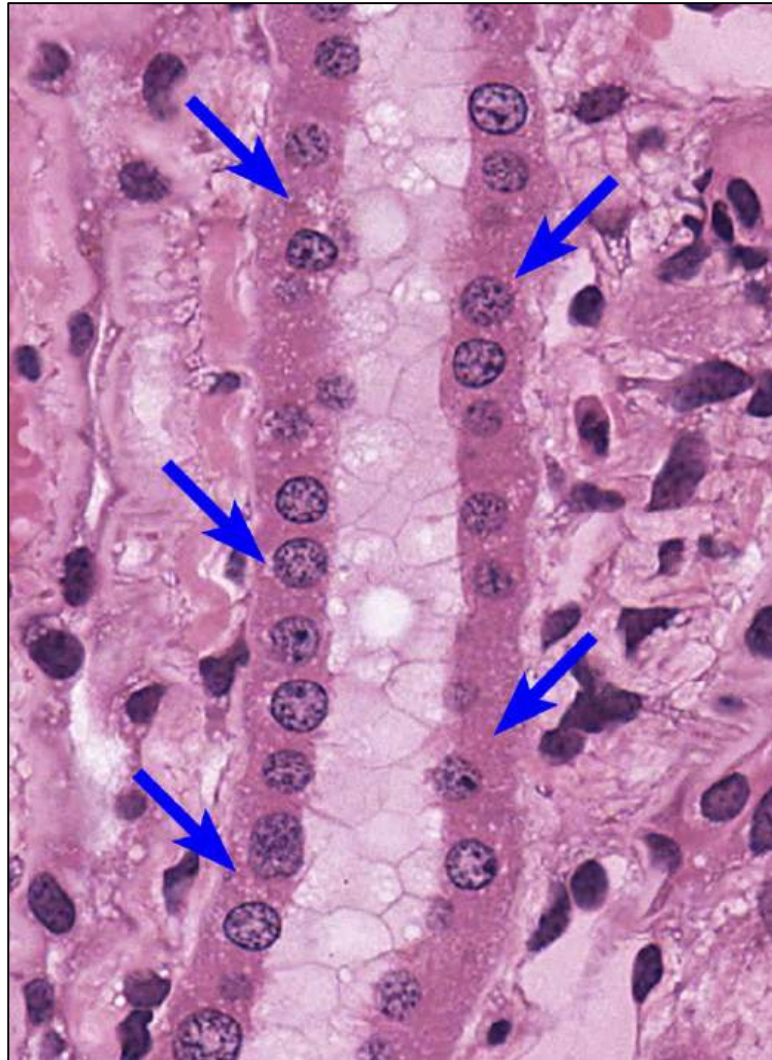


Non-Keratinized Stratified Squamous Epithelium

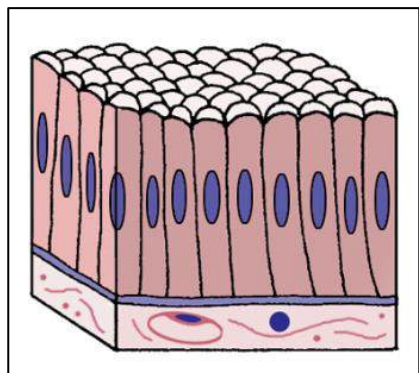
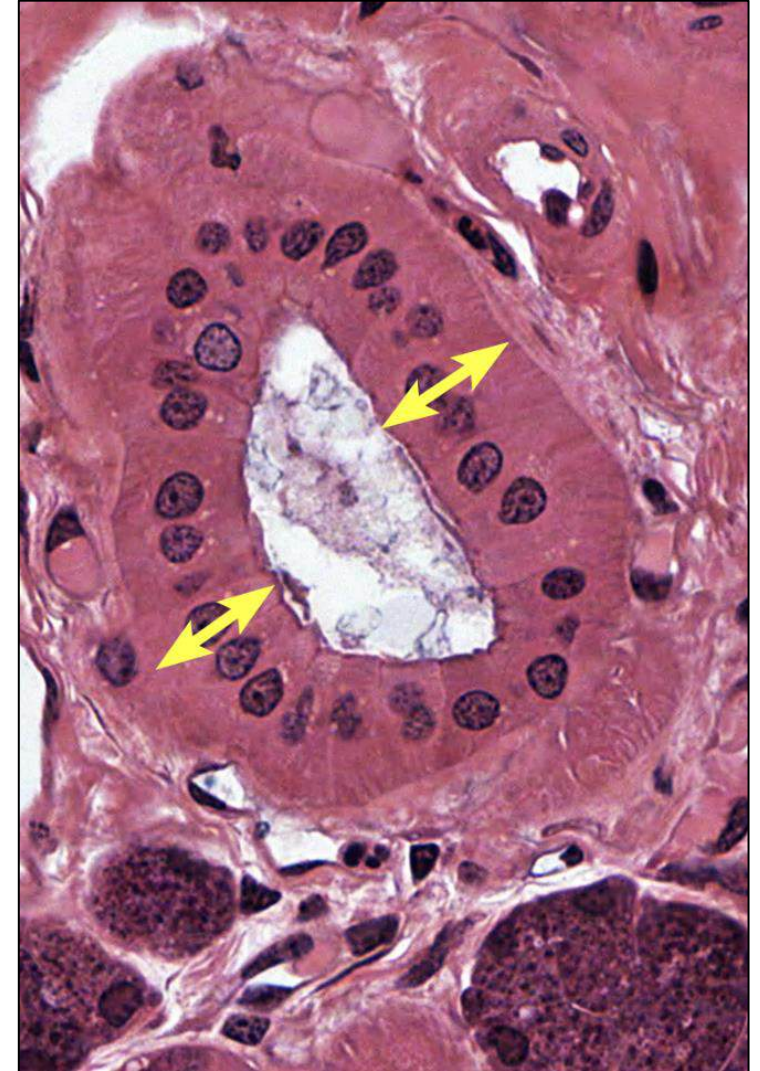
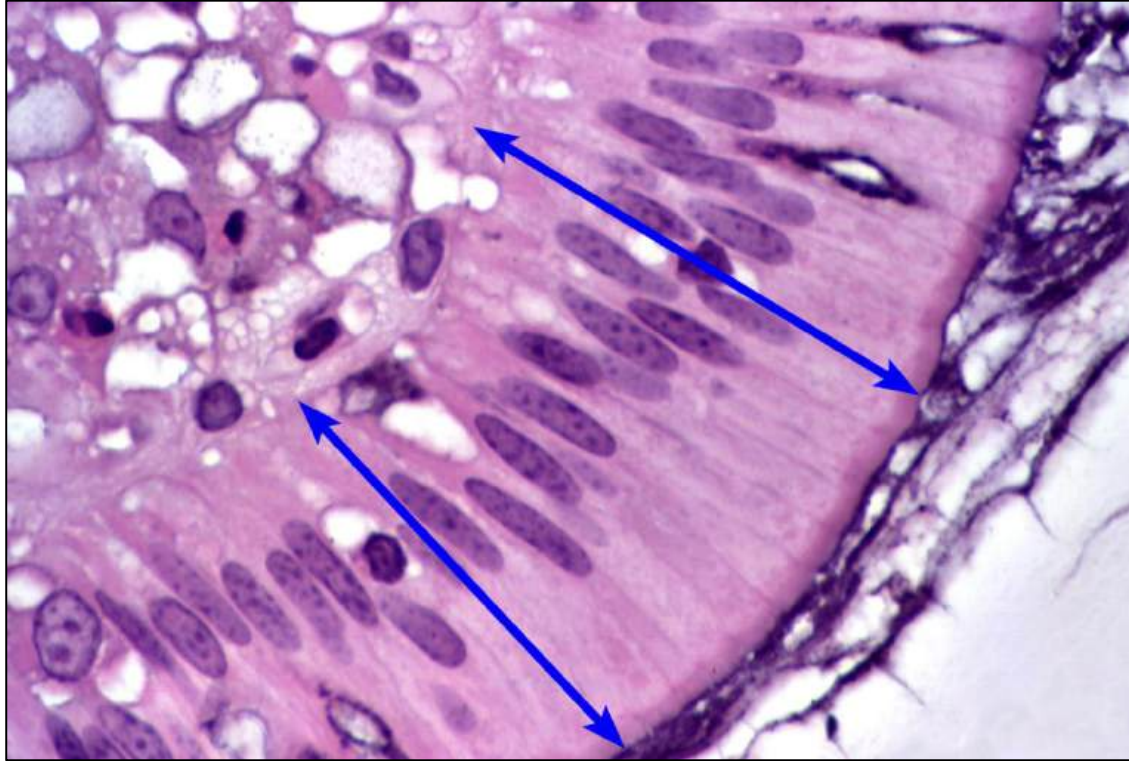


Ref. 1

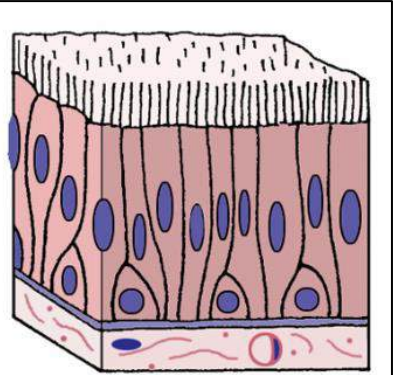
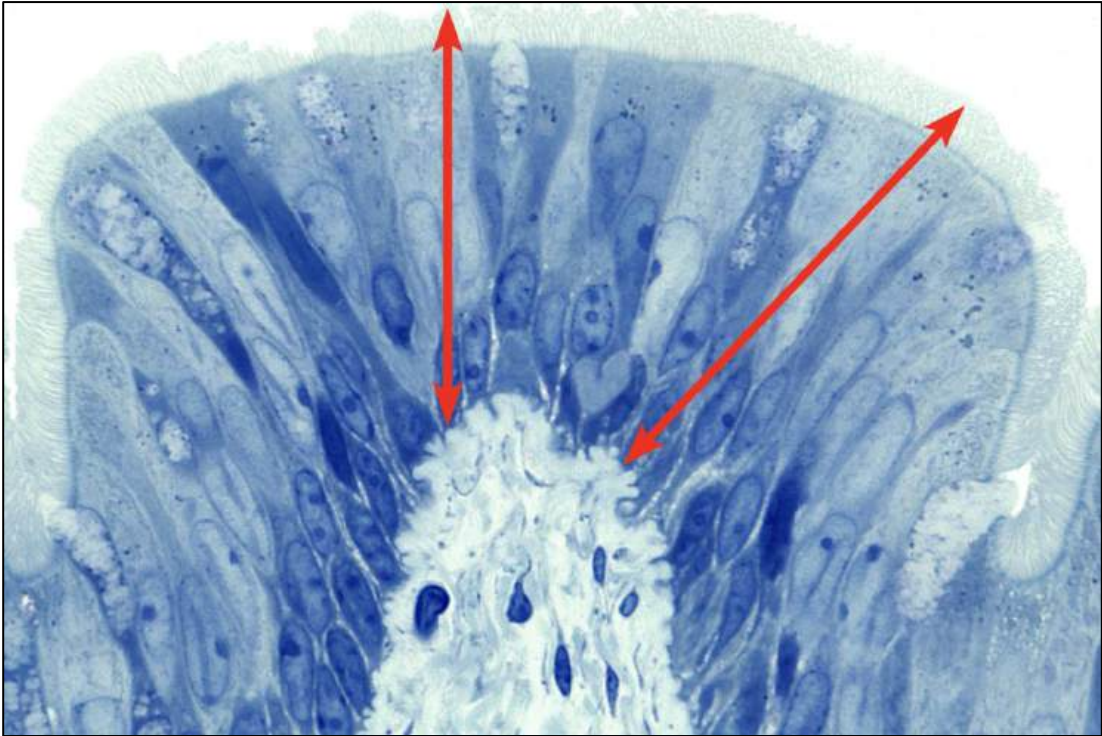
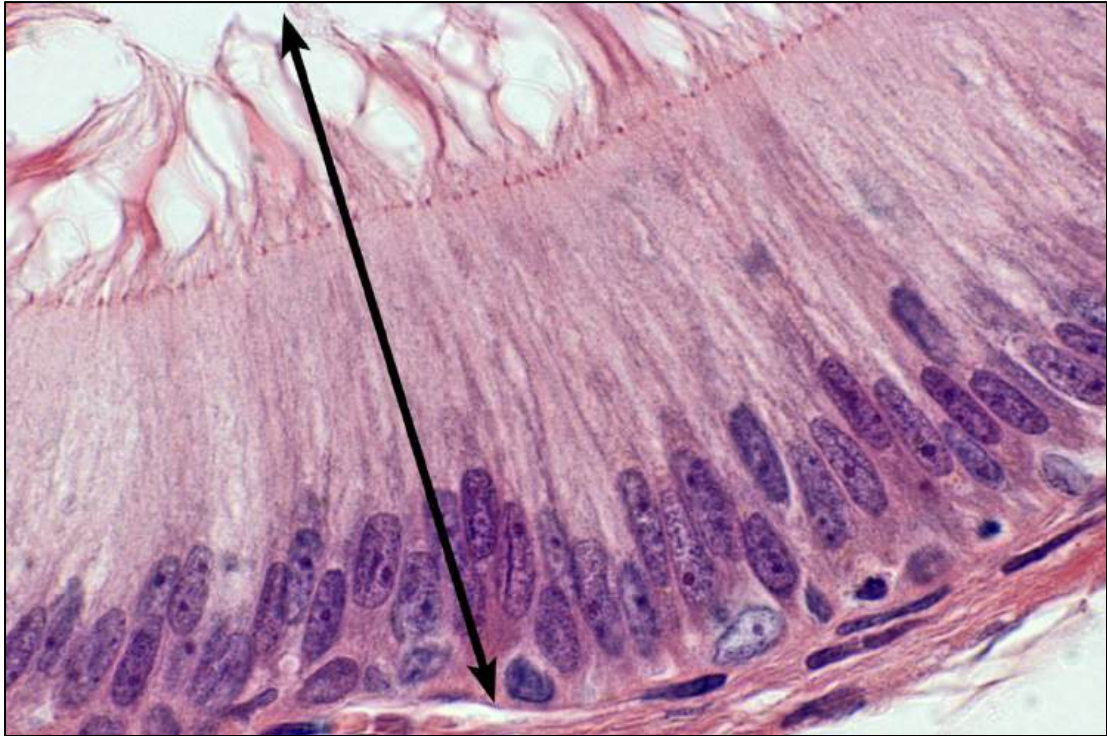
Simple Cuboidal Epithelium



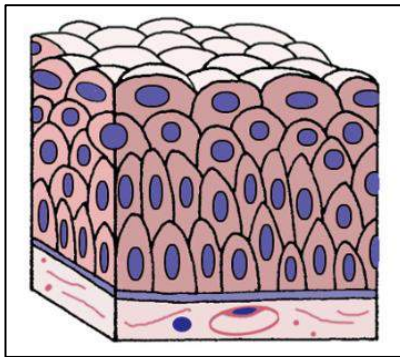
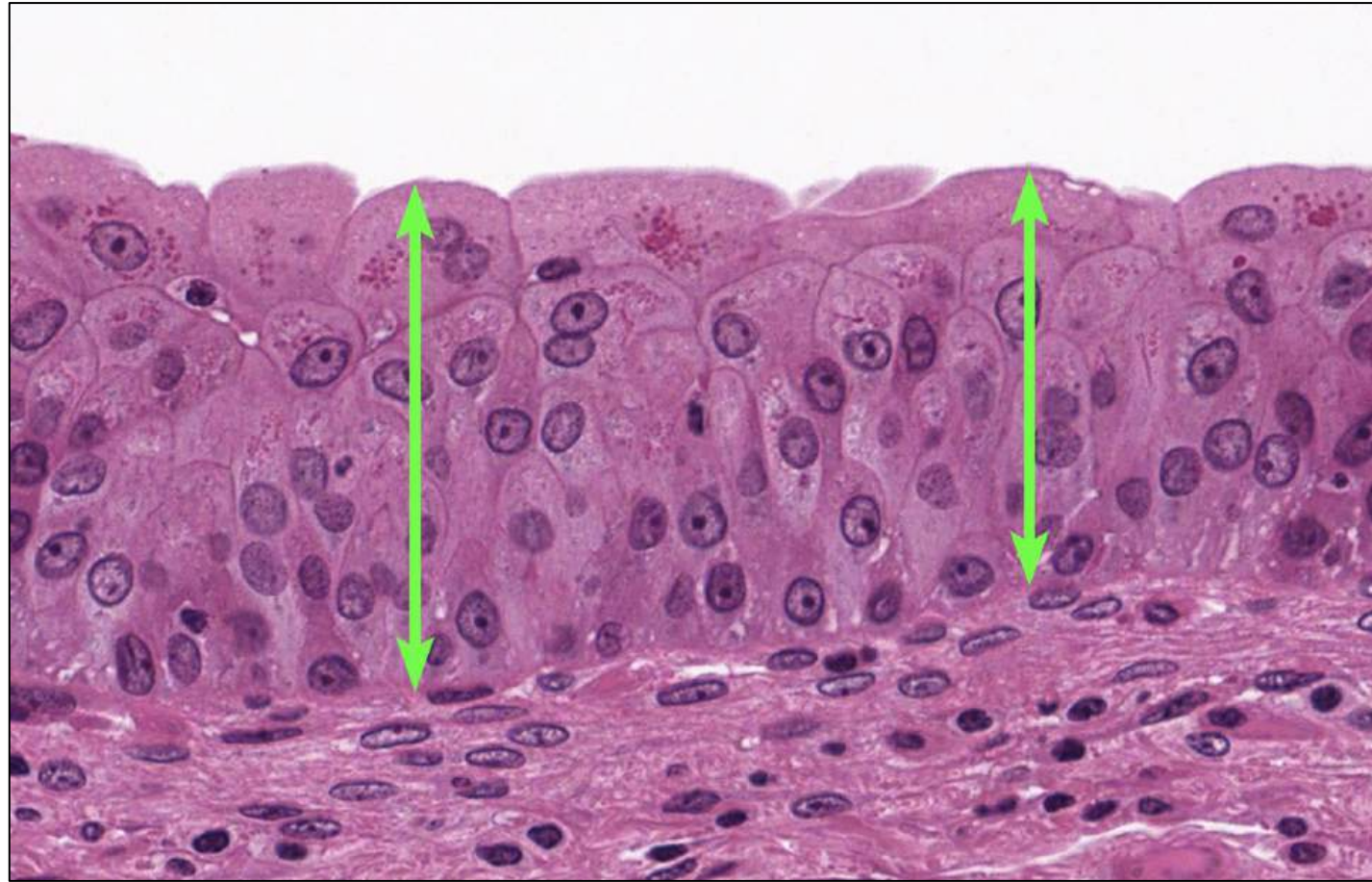
Simple Columnar Epithelium



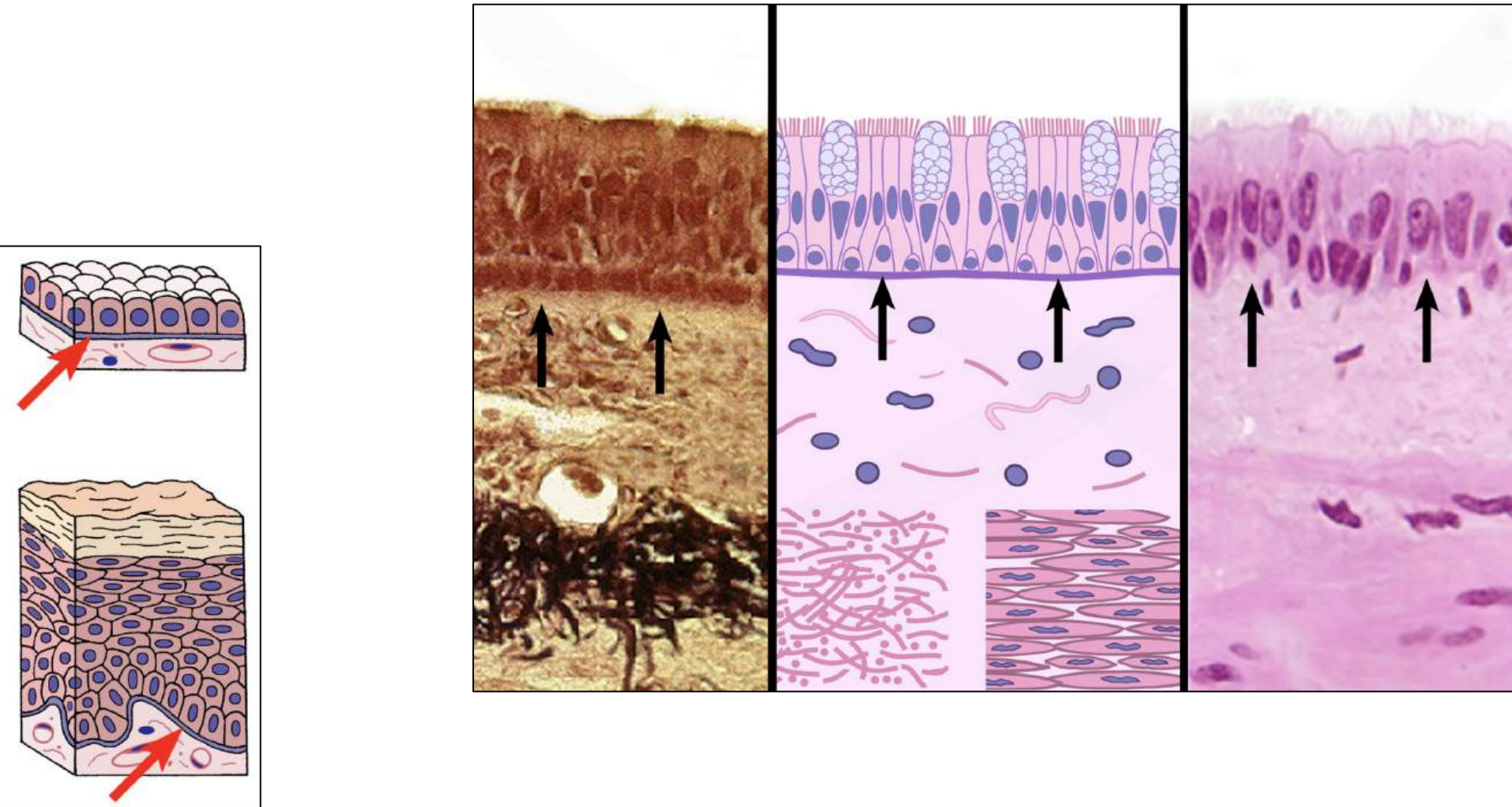
Pseudostratified Ciliated Columnar Epithelium



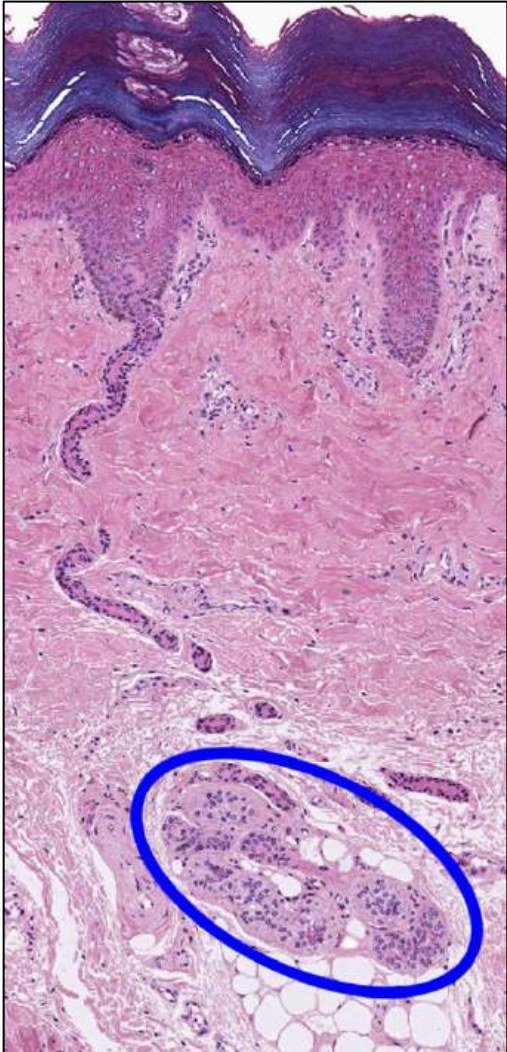
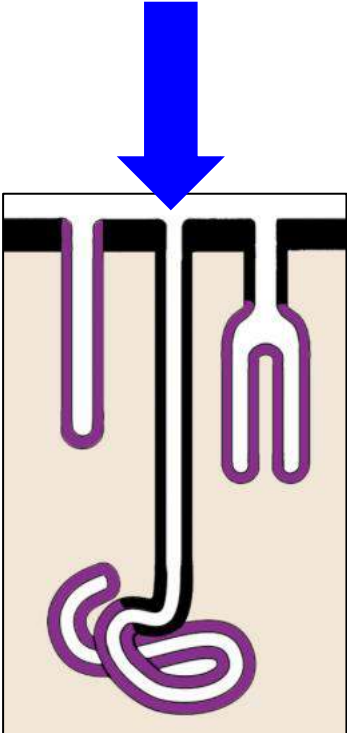
Transitional epithelium/Urothelium



Basement Membrane (PAS Stained – on far right image)



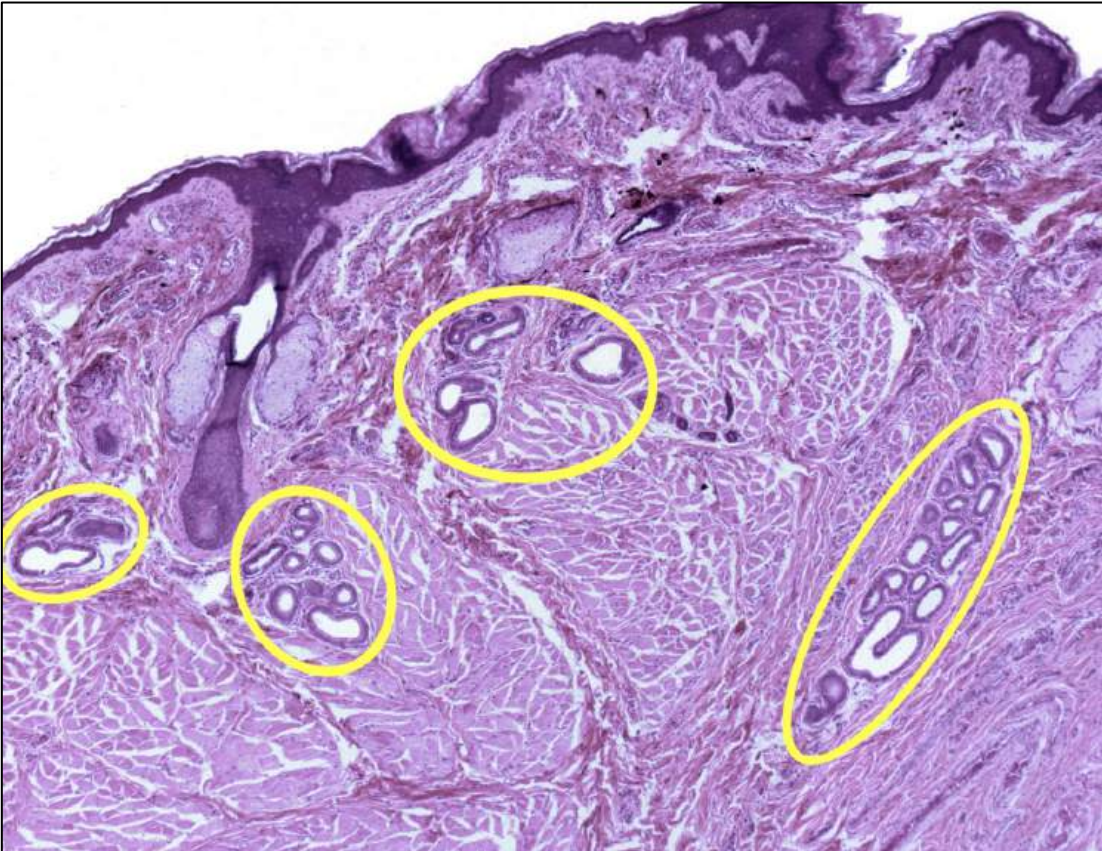
Exocrine Gland Example: Sudoriferous Sweat Gland



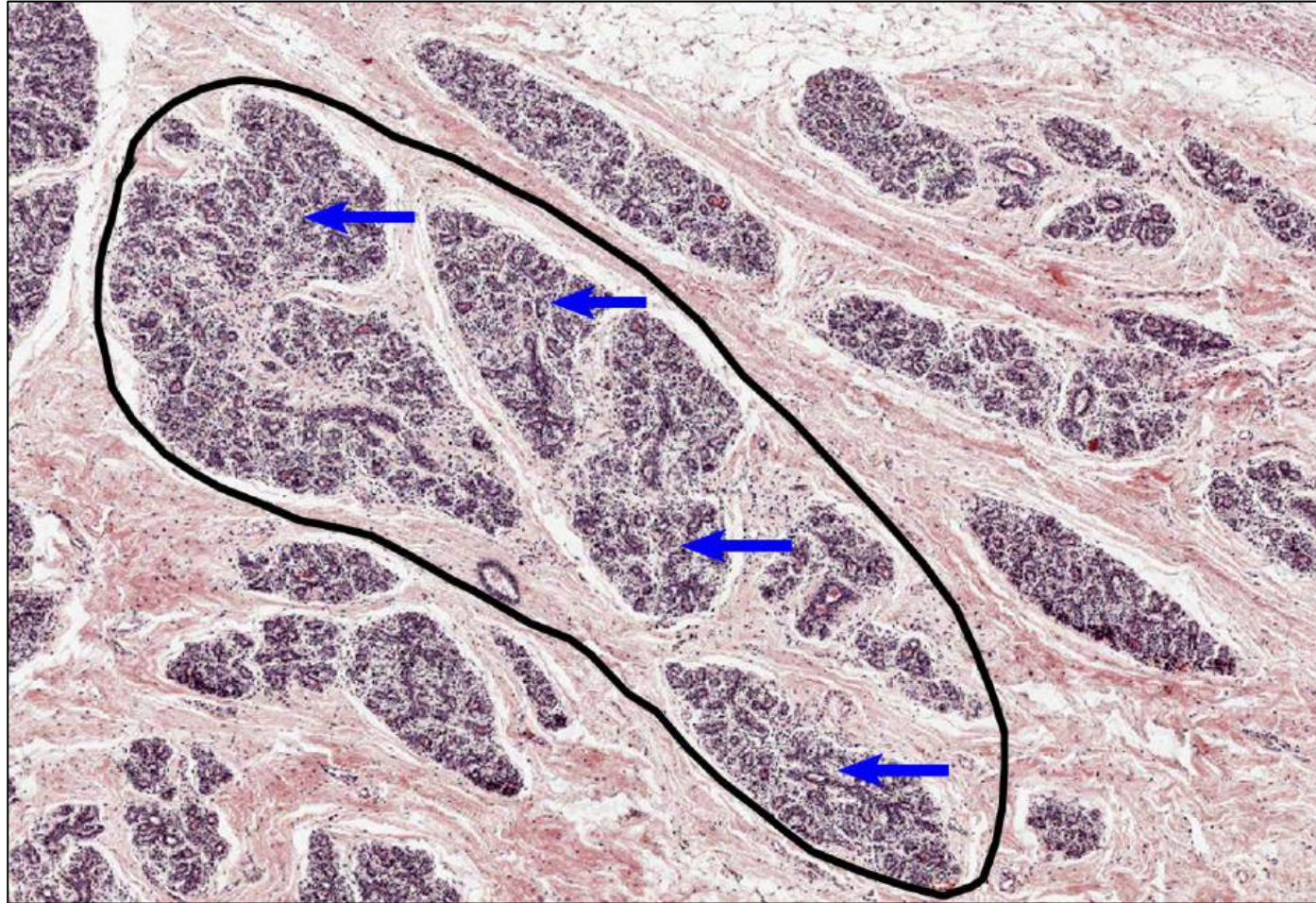
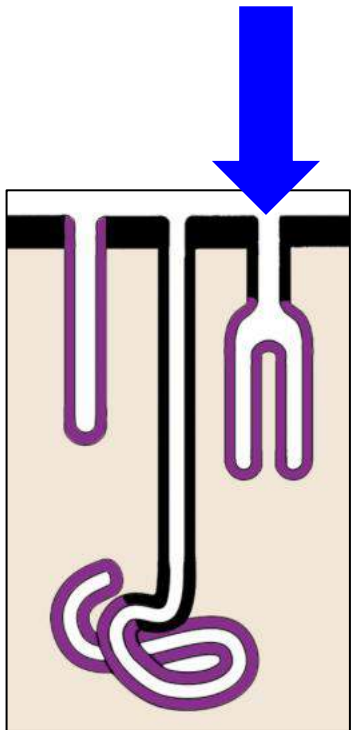
Eccrine
Sweat
Gland

Note: Do not
need to
distinguish
between the two

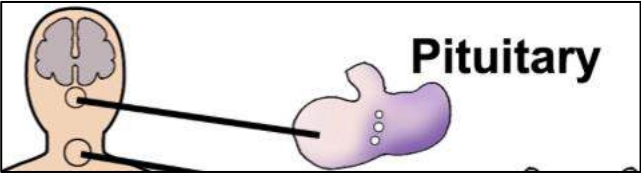
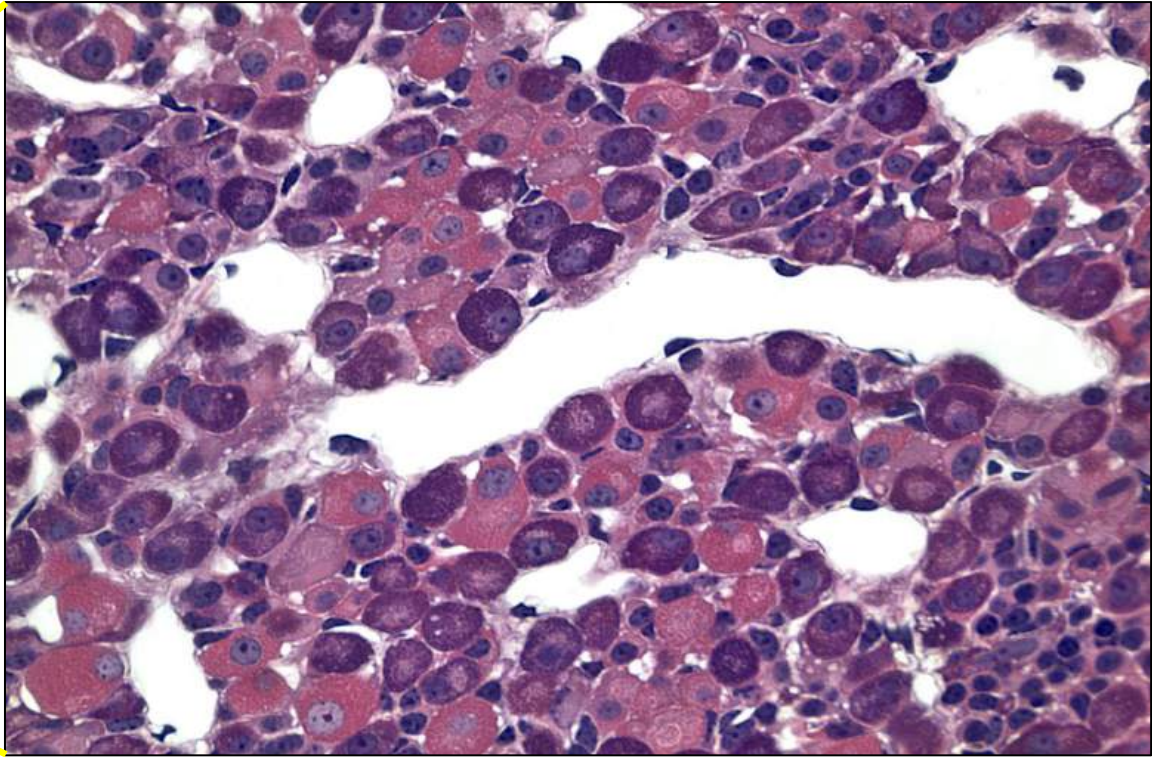
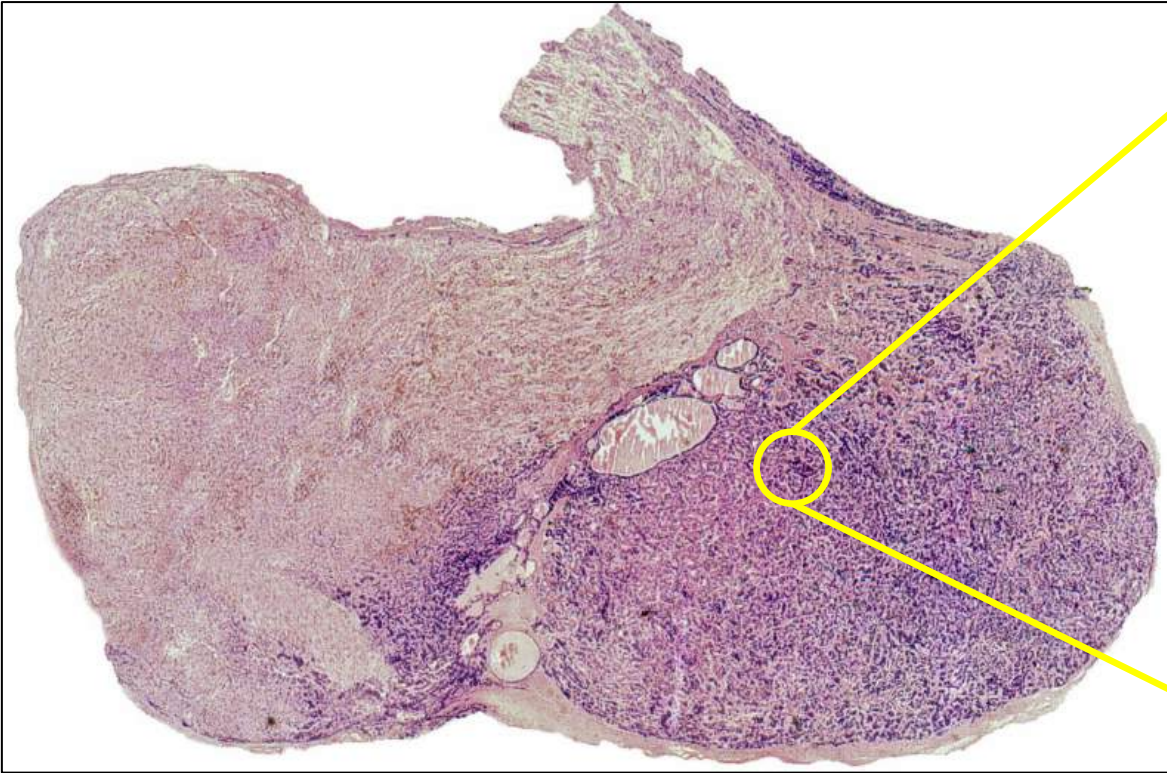
Apocrine Sweat Gland



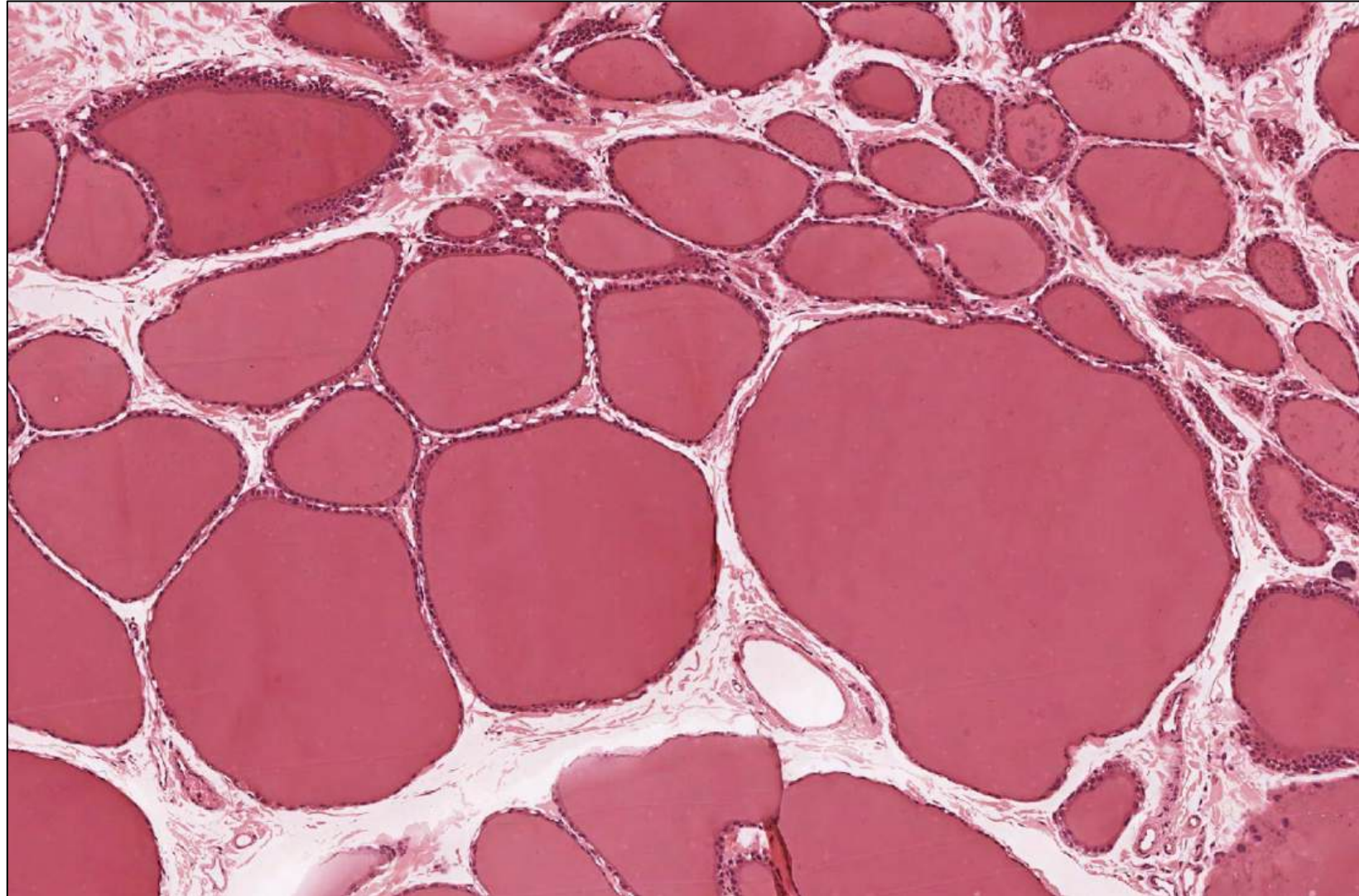
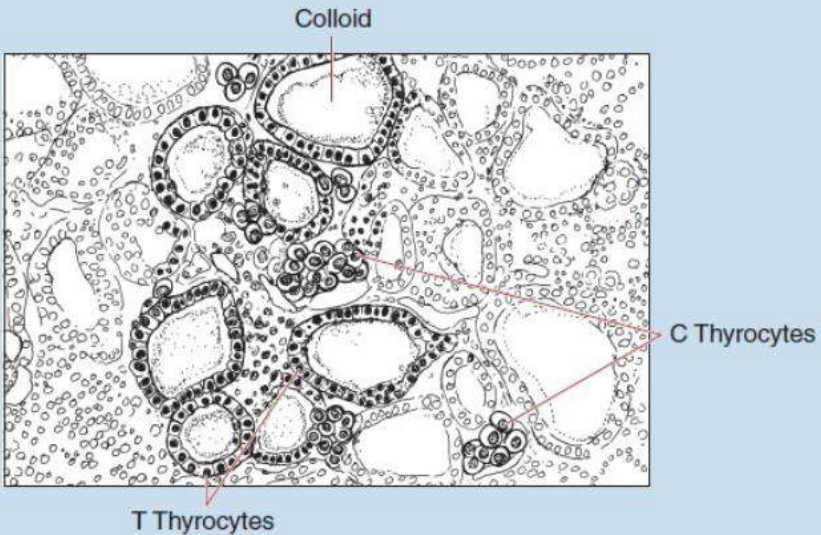
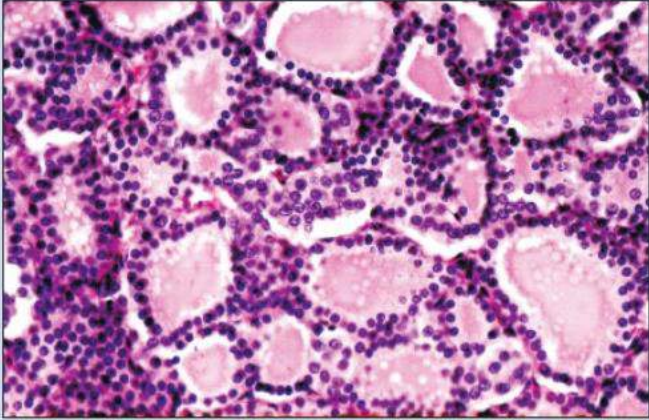
Exocrine Gland Example: Mammary Gland (in Breast)



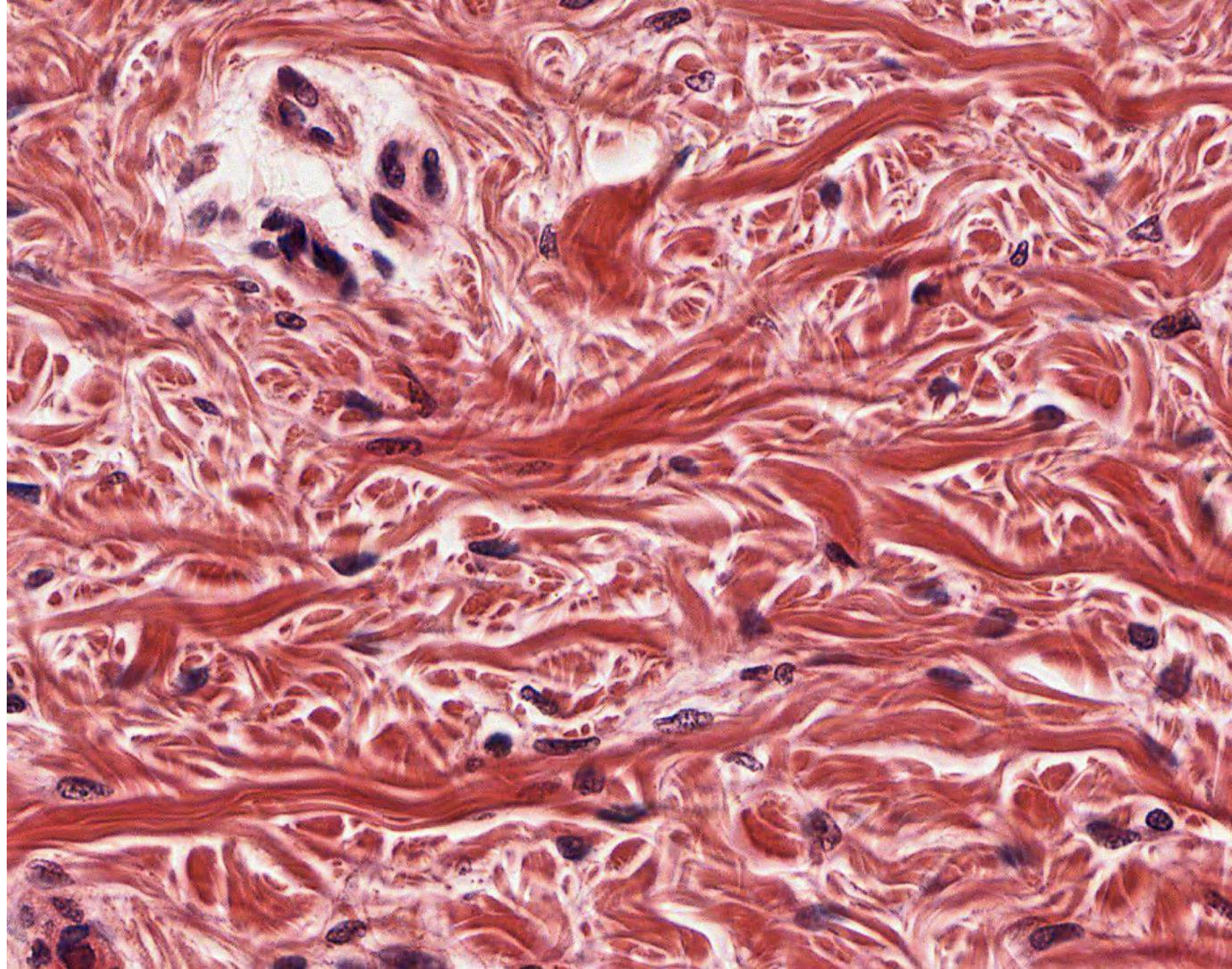
Endocrine Gland Example: Pituitary Gland



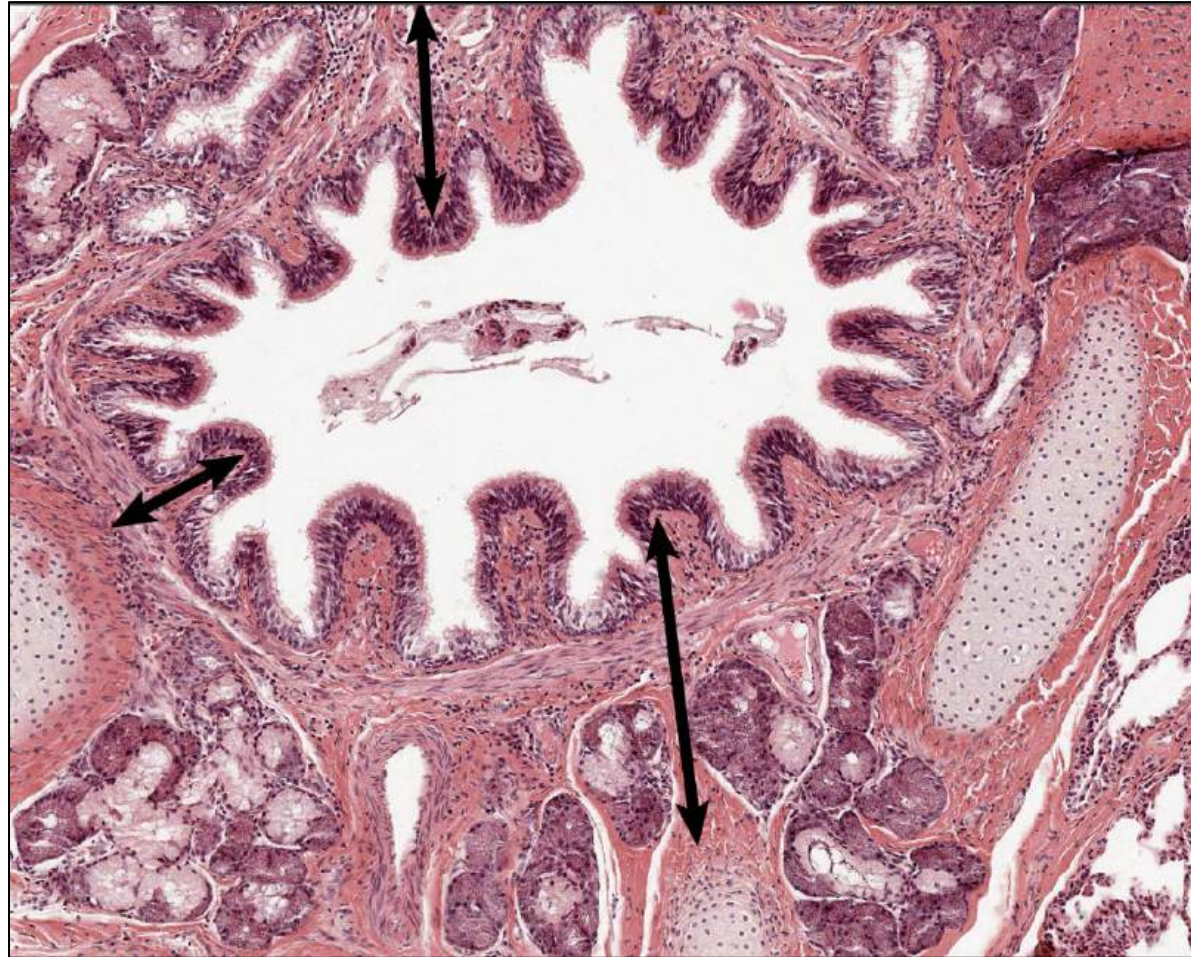
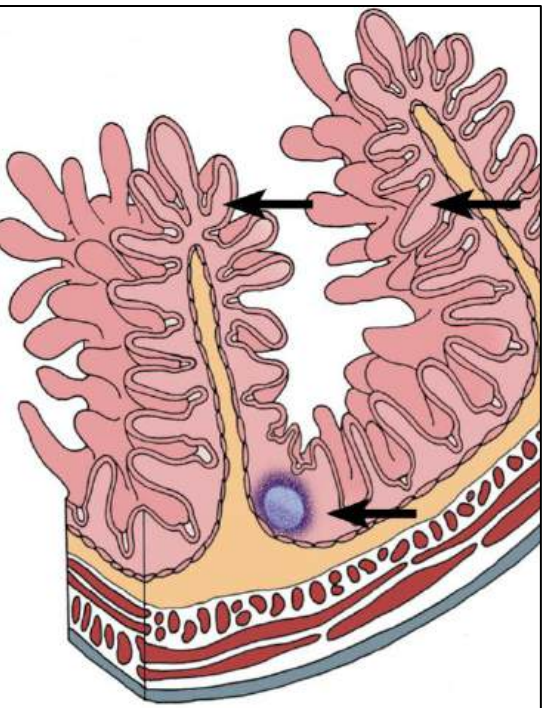
Endocrine Gland Example: Thyroid Gland



Connective Tissue Proper



Lamina Propria (Lung Shown)

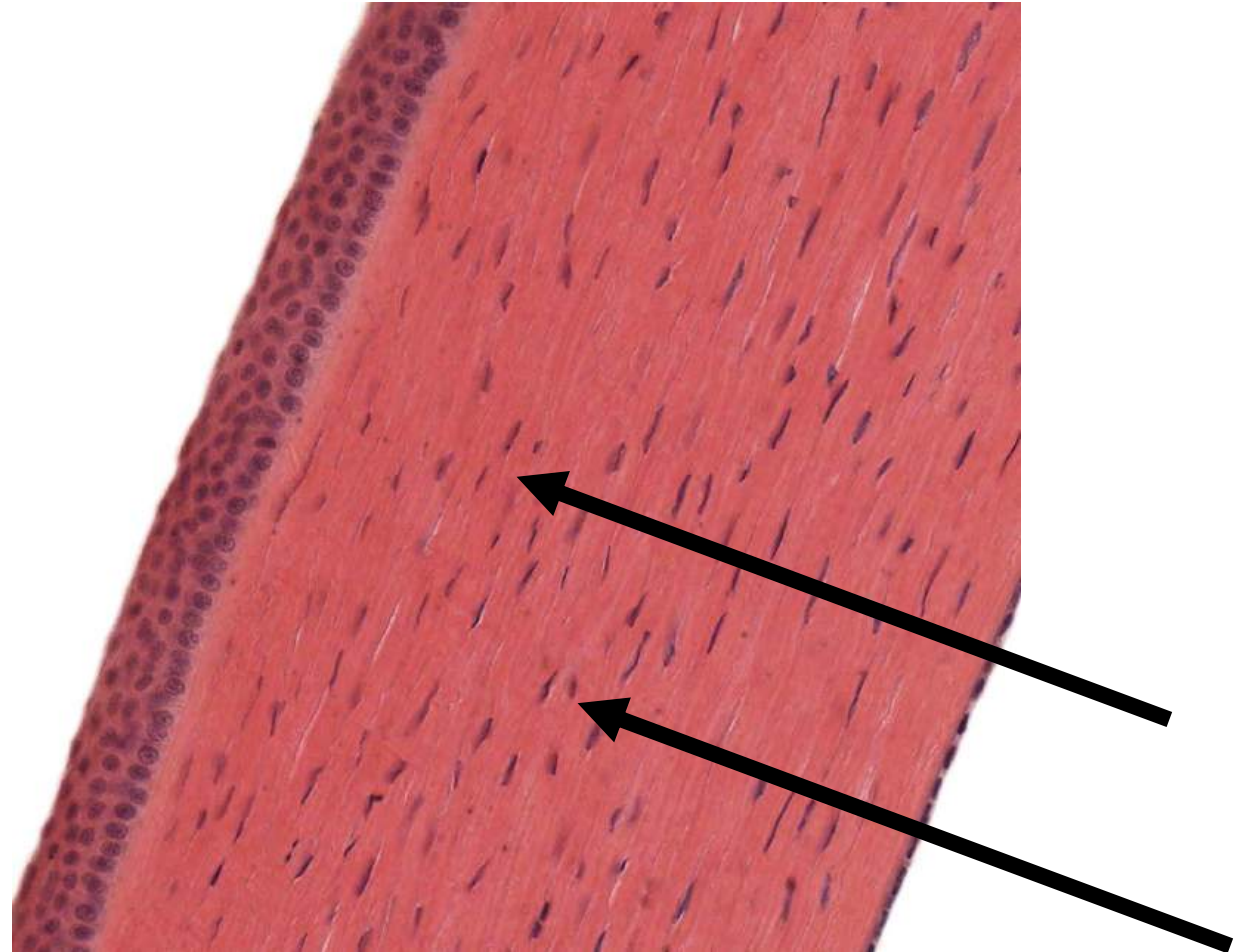
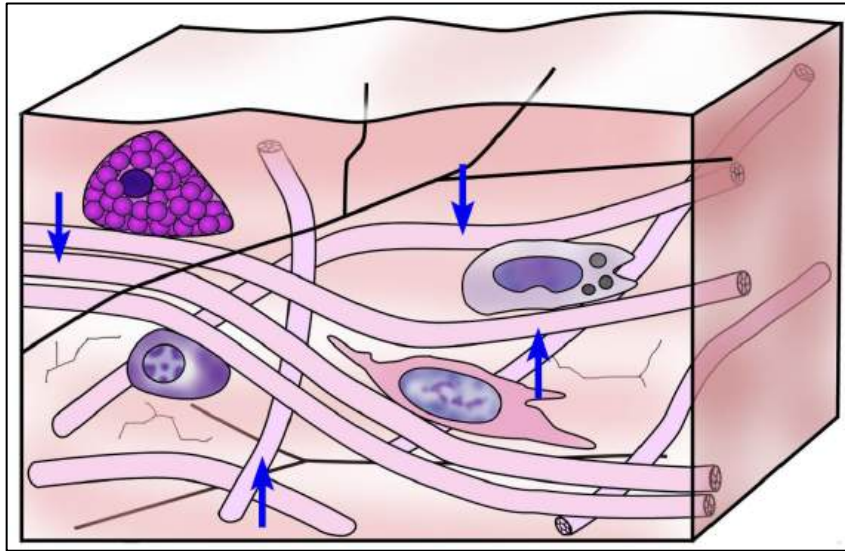


Types of Fibers

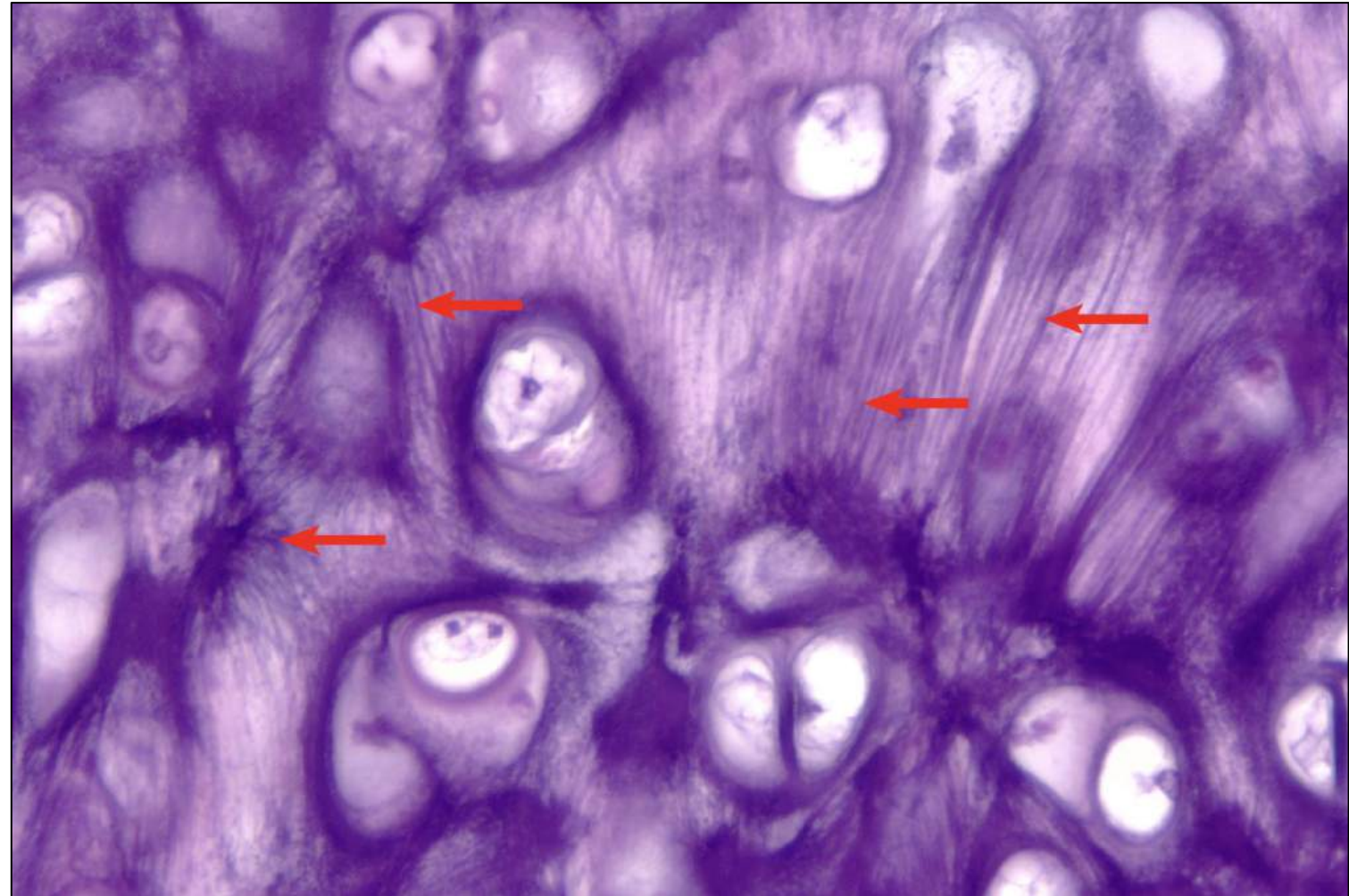
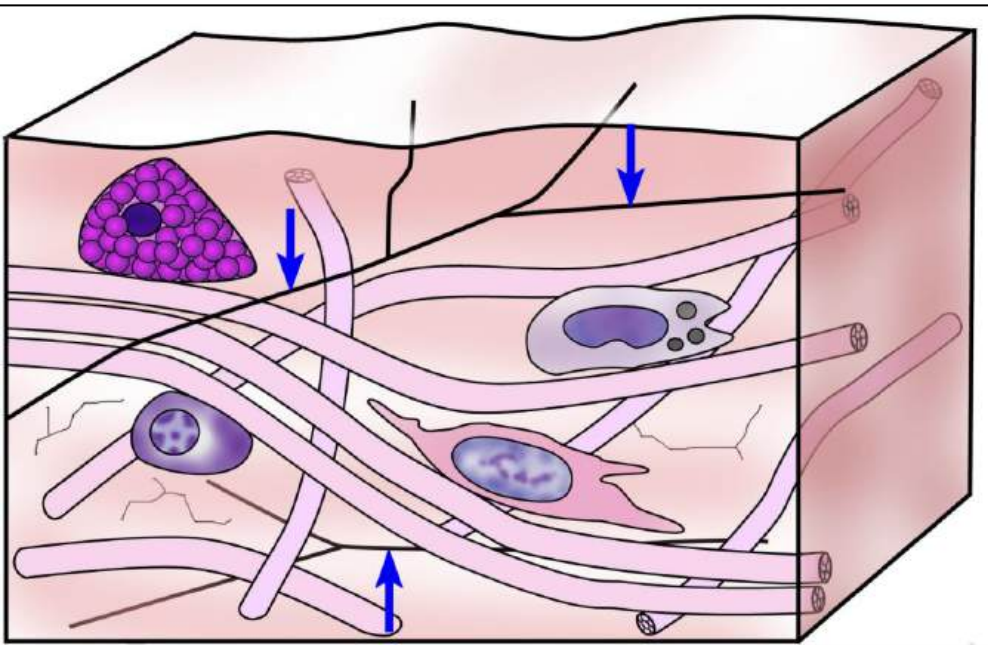
- Collagen (focus on type I collagen)
- Elastic
- Reticular (composed of type III collagen)

Fiber Types – Collagen (Type I)

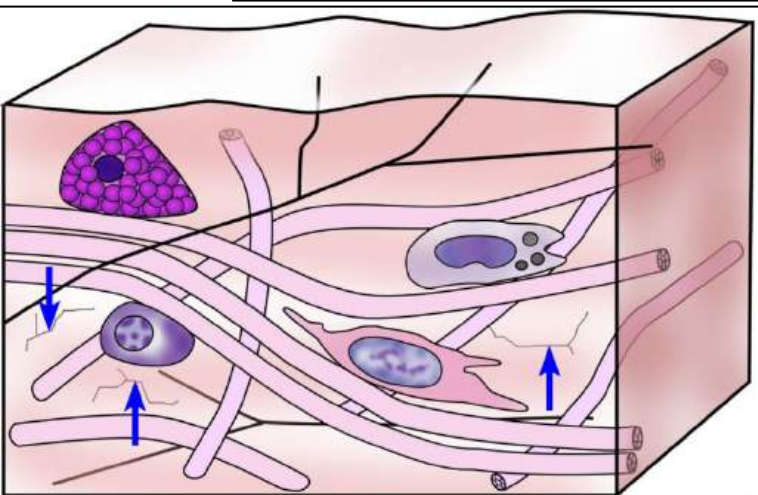
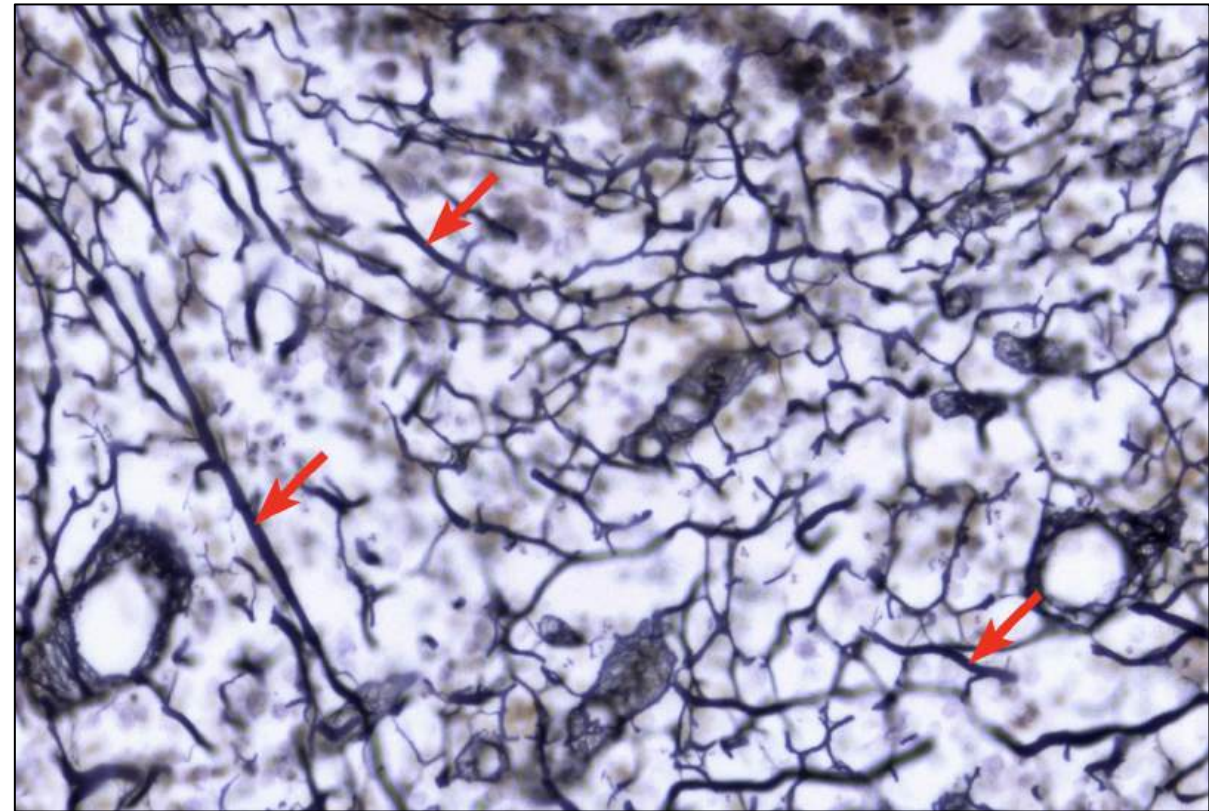
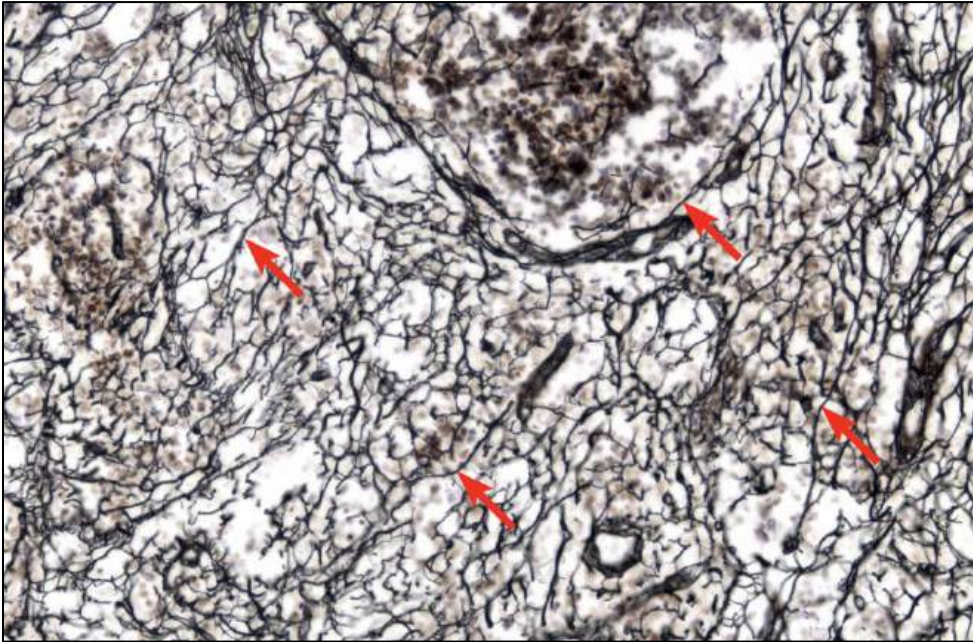
Example Below: Cornea



Fiber Types – Elastic



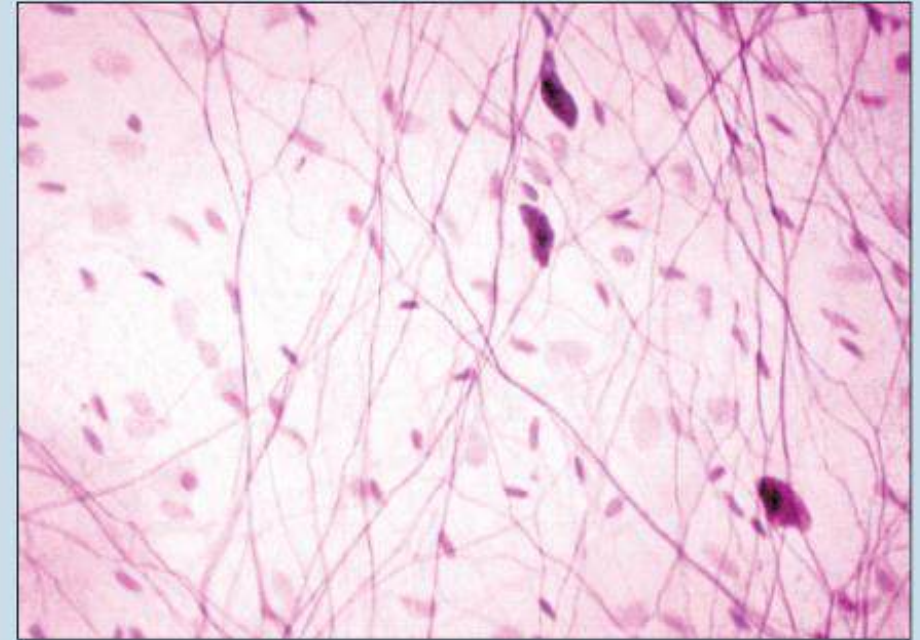
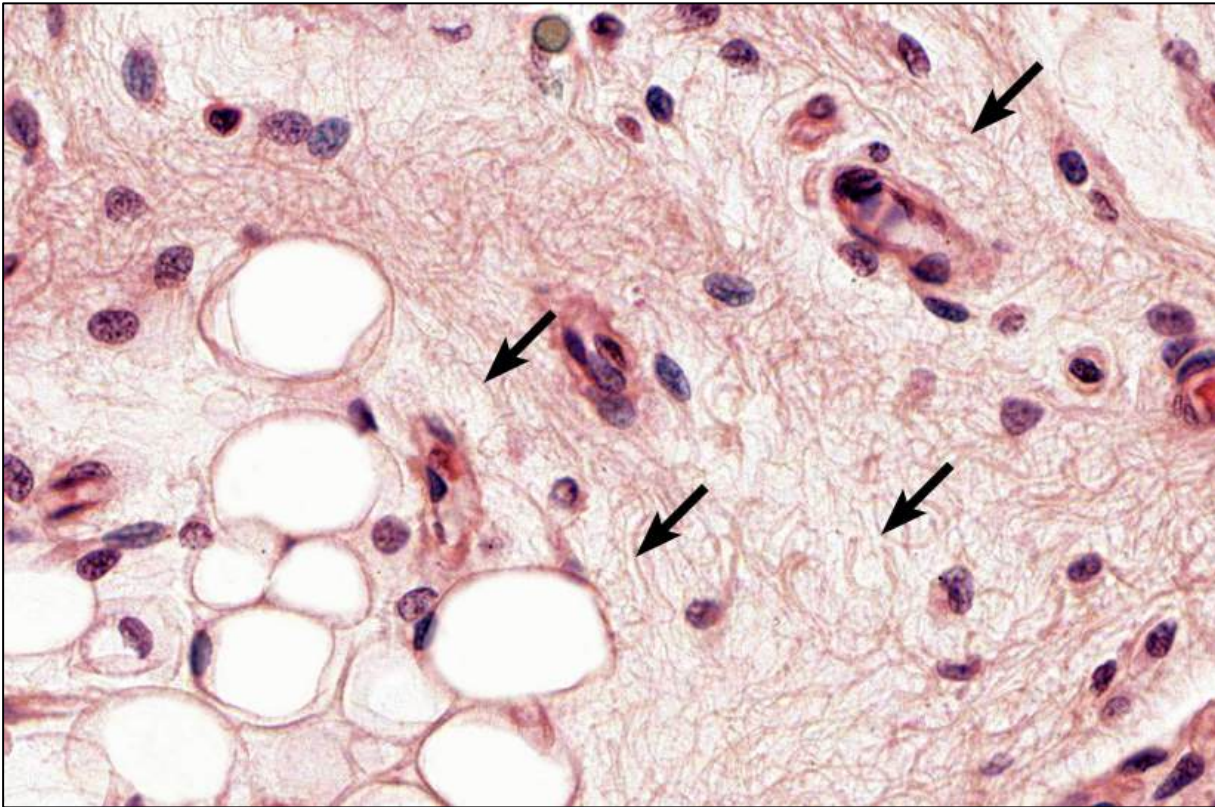
Fiber Types – Reticular (Type III Collagen)



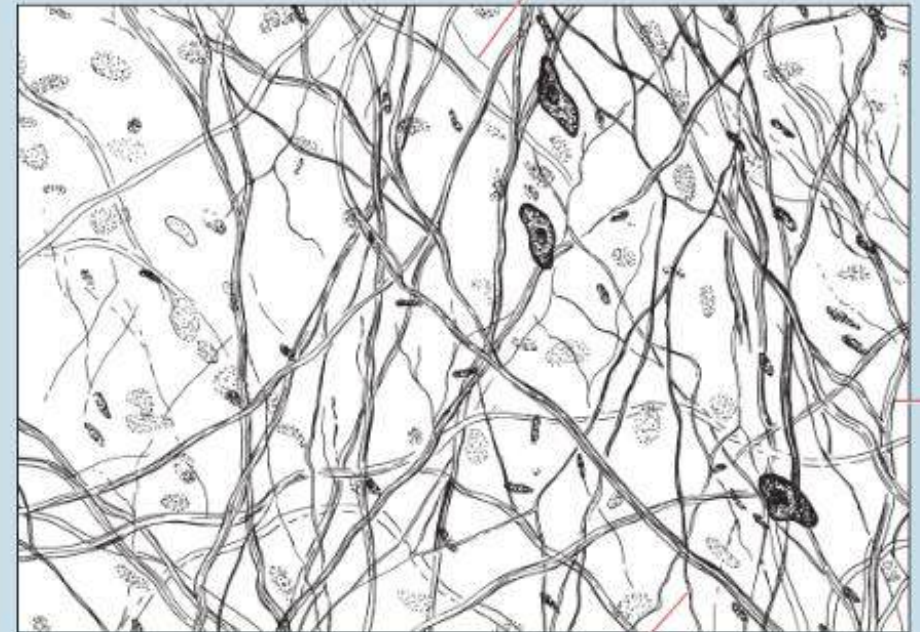Types of Collagenous Tissue

- Loose/Areolar connective tissue
- Dense regular connective tissue
- Dense irregular connective tissue

Connective Tissue Types – Loose/Areolar

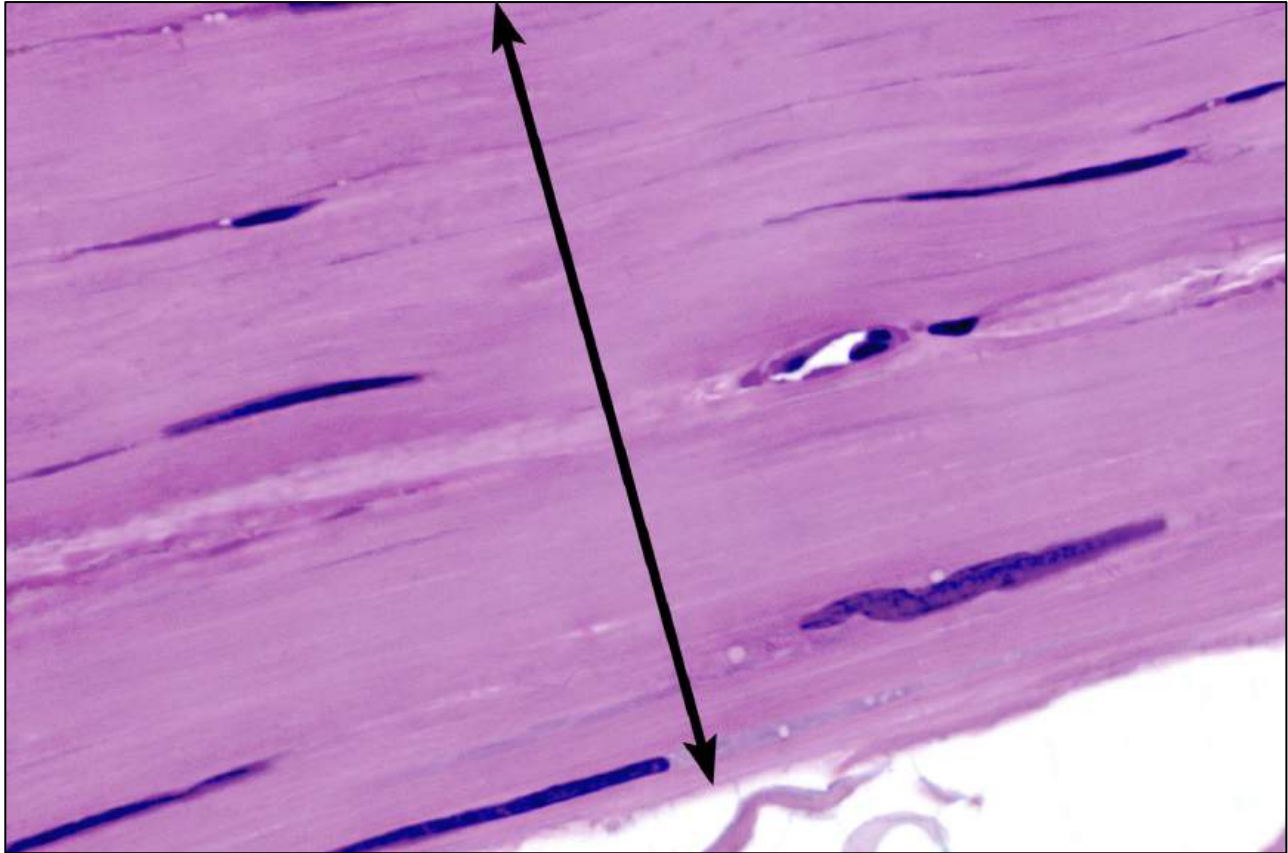
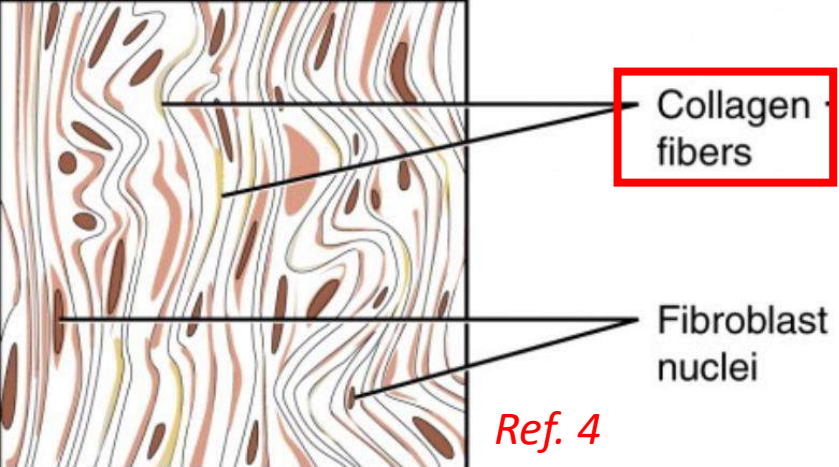
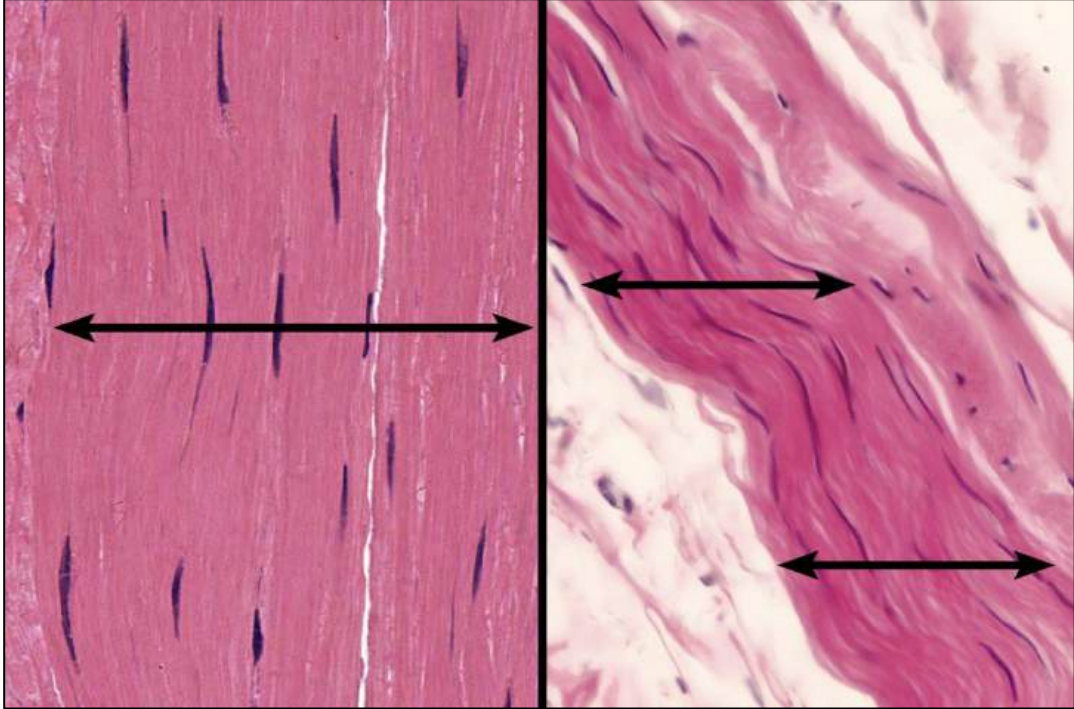


Reticular fiber

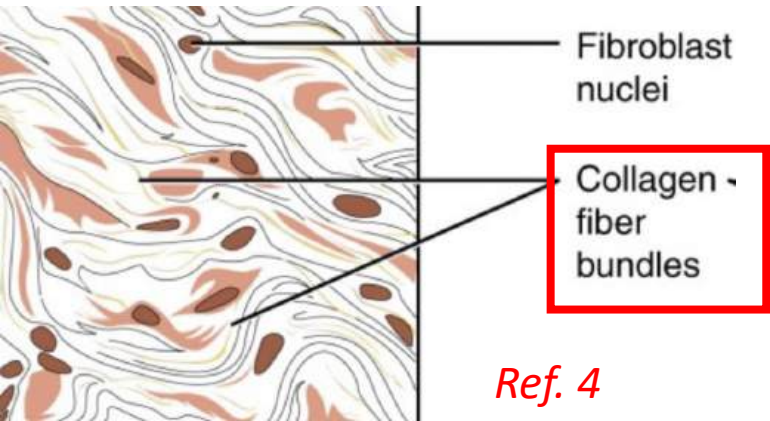
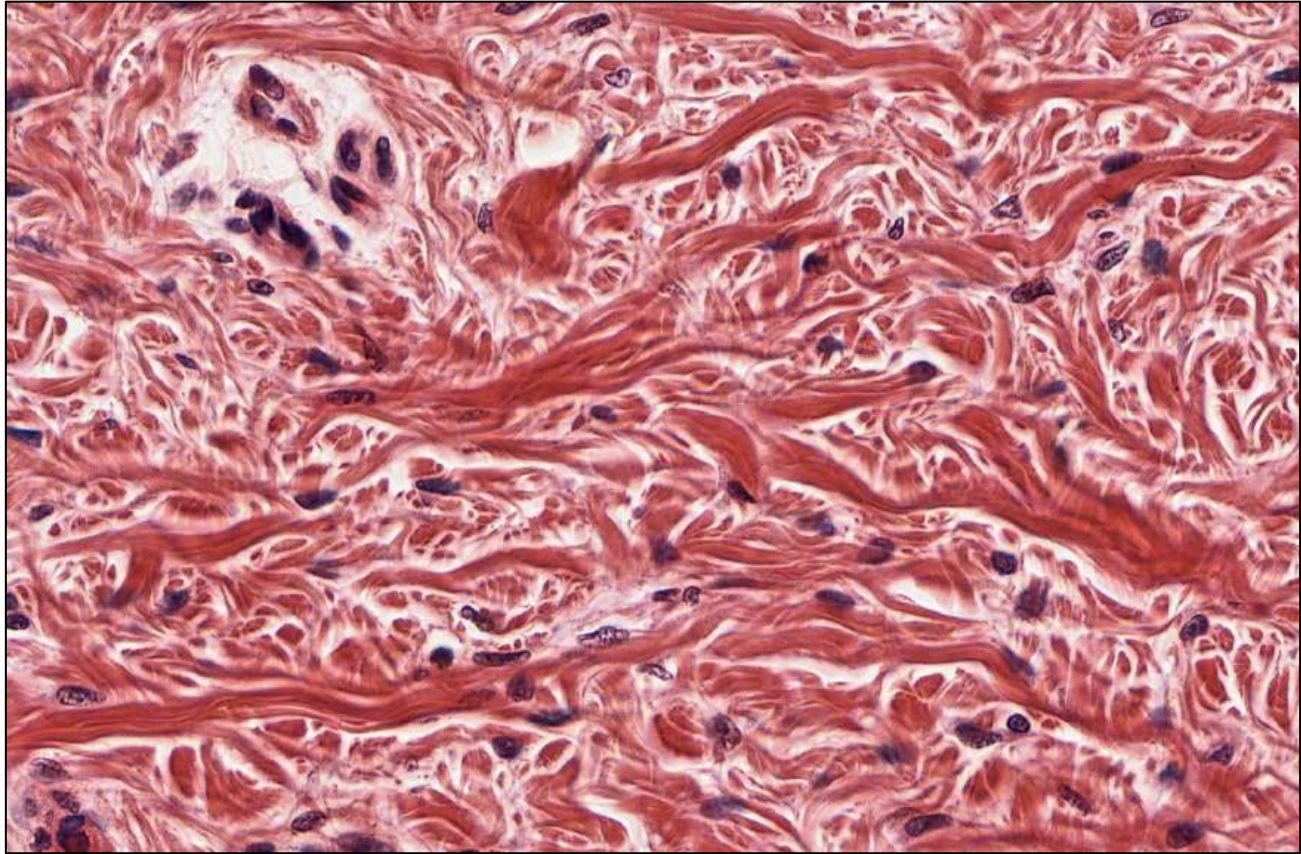
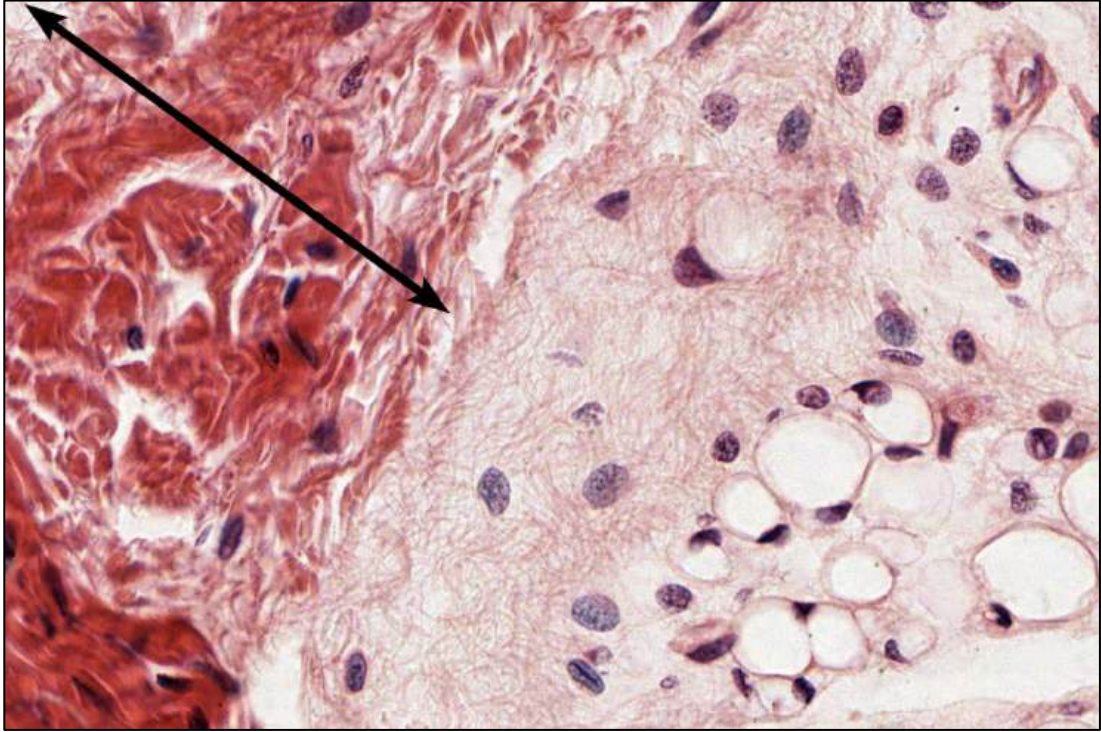


Collagen fiber

Connective Tissue Types – Dense Regular



Connective Tissue Types – Dense Irregular

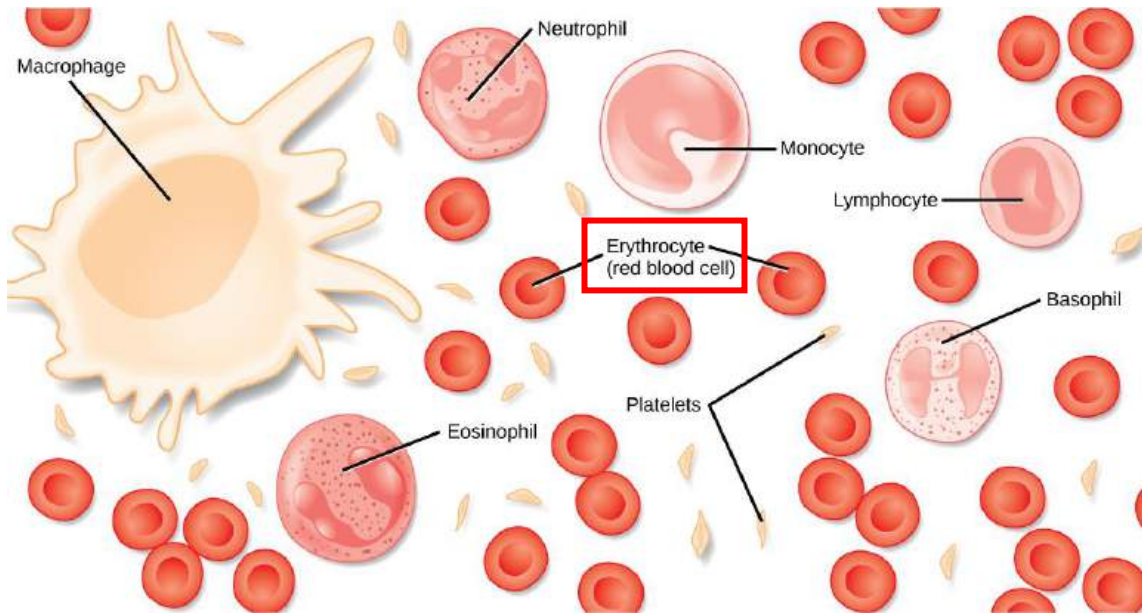


Ref. 4

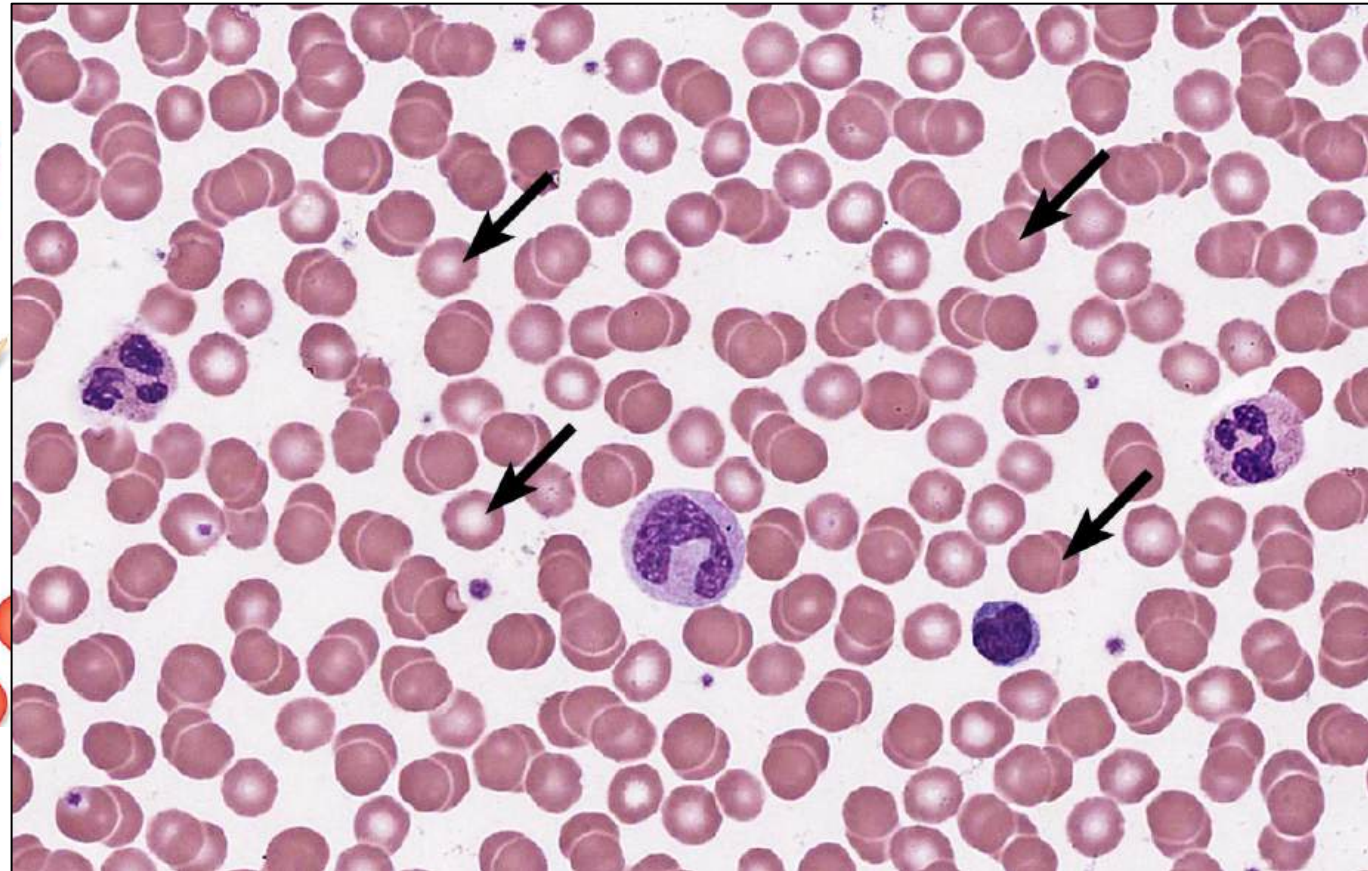
Cells in a Peripheral Blood Smear

- Red blood cells
- White blood cells
- Platelets

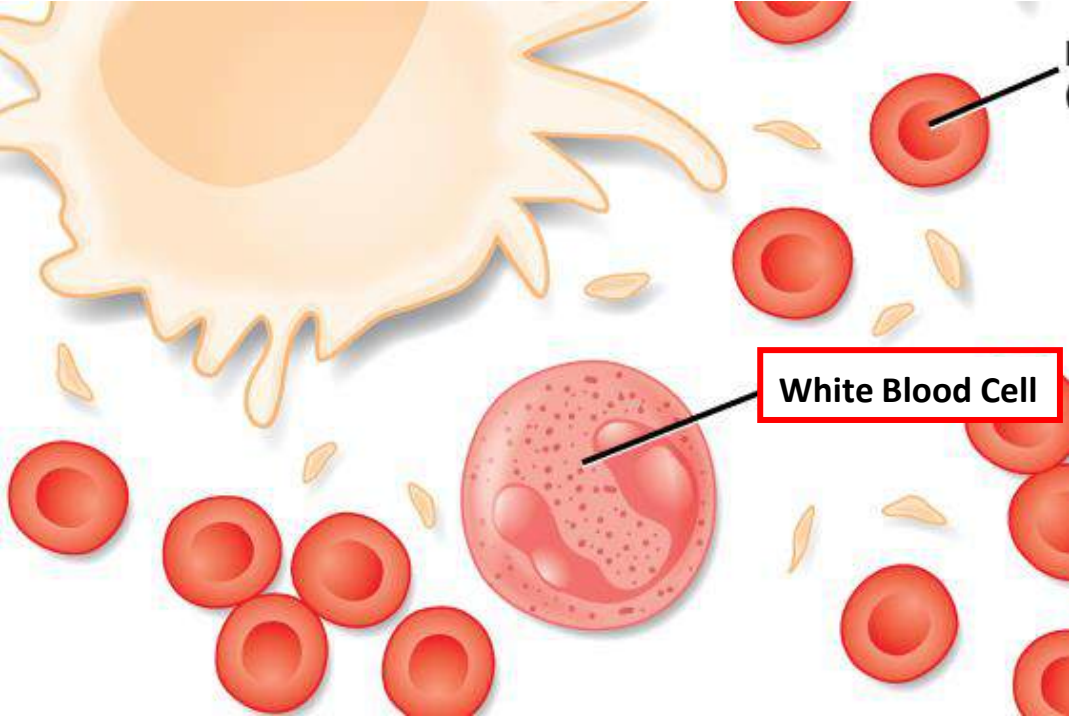
Cell Types in Peripheral Blood Smear – Red Blood Cells



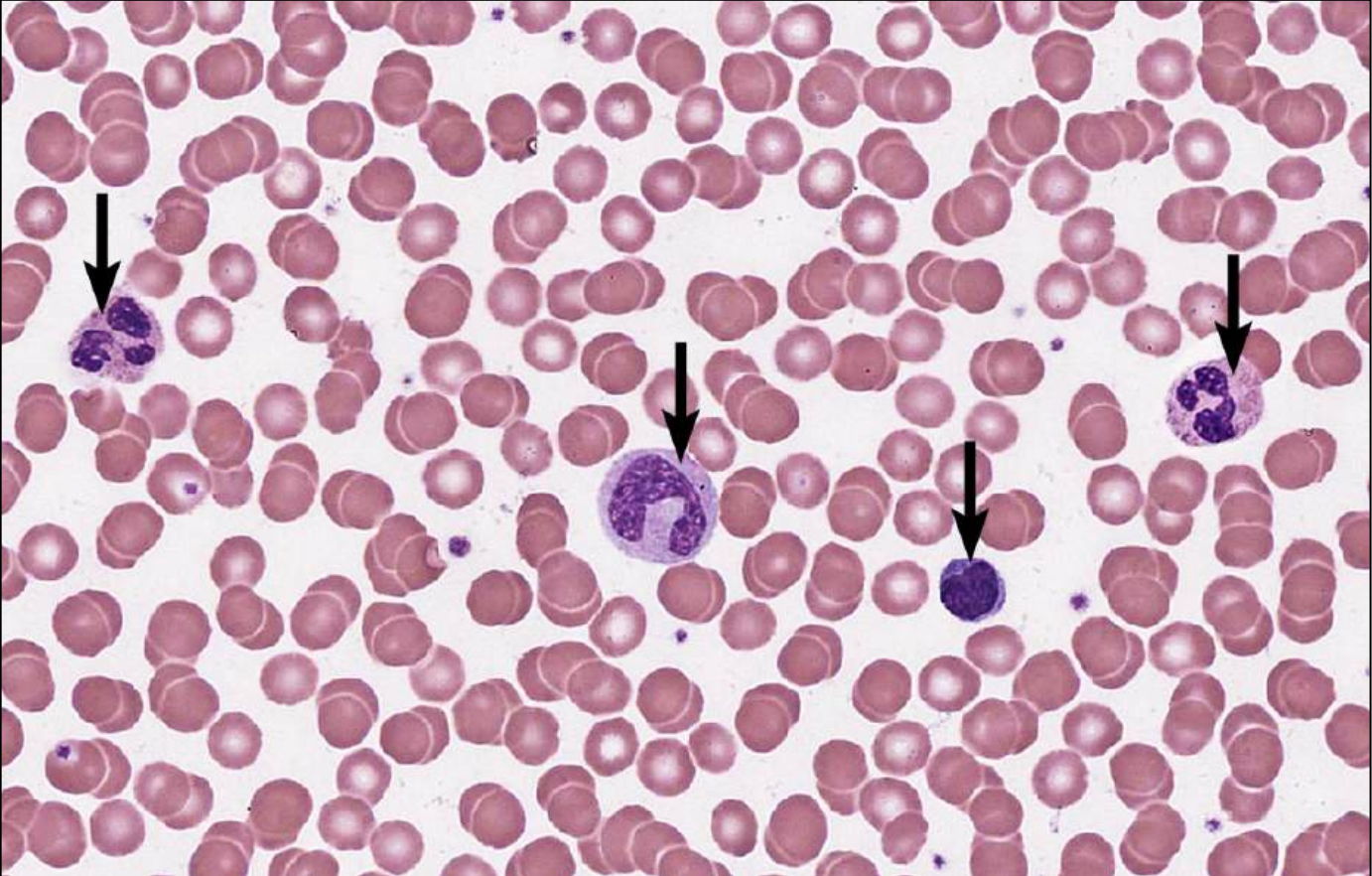
Ref. 5



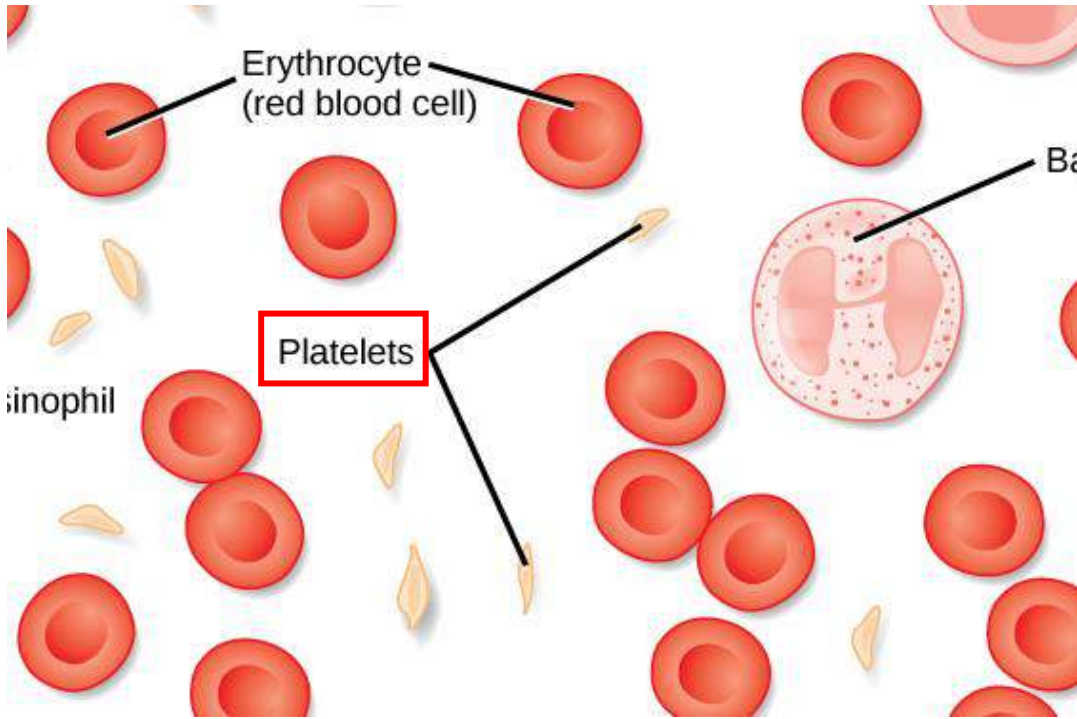
Cell Types in Peripheral Blood Smear – White Blood Cells



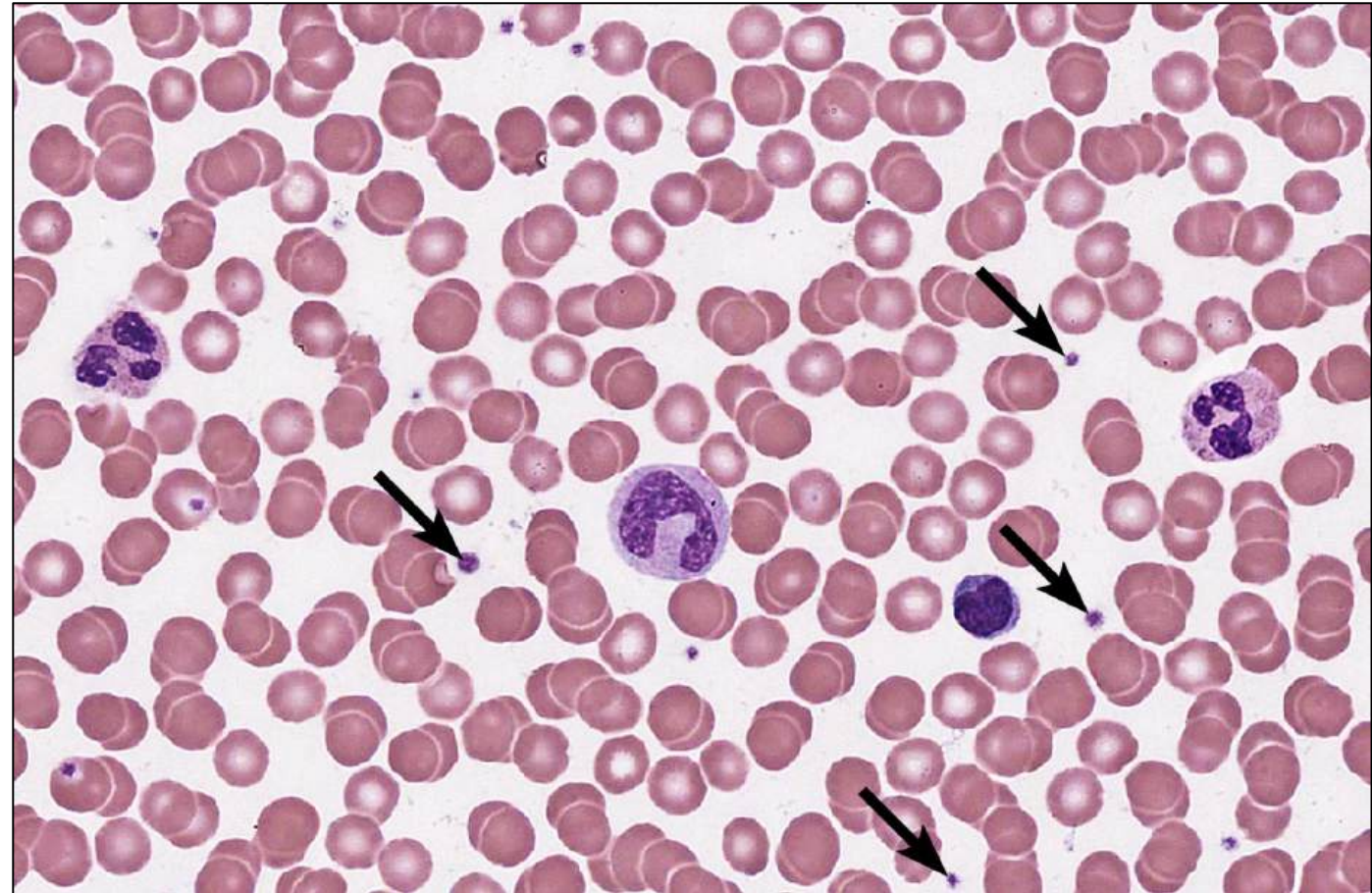
Ref. 5



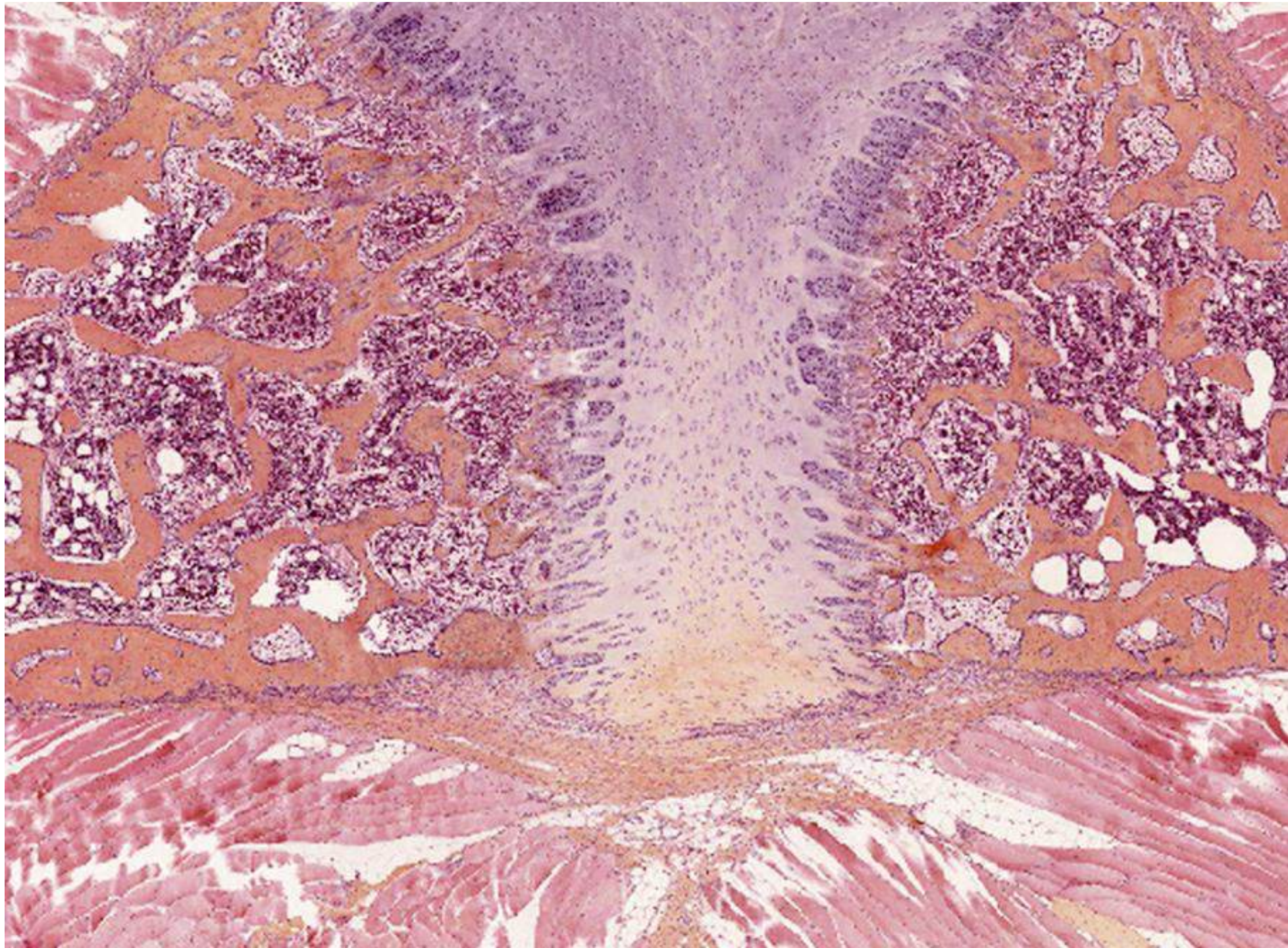
Cell Types in Peripheral Blood Smear - Platelets



Ref. 5



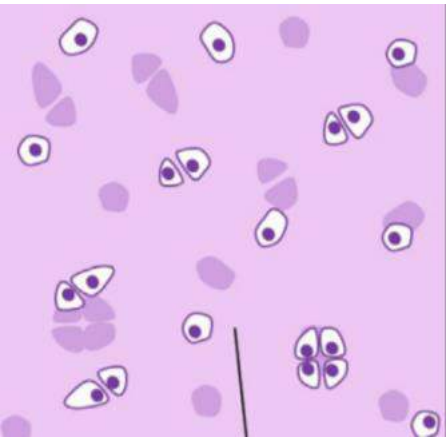
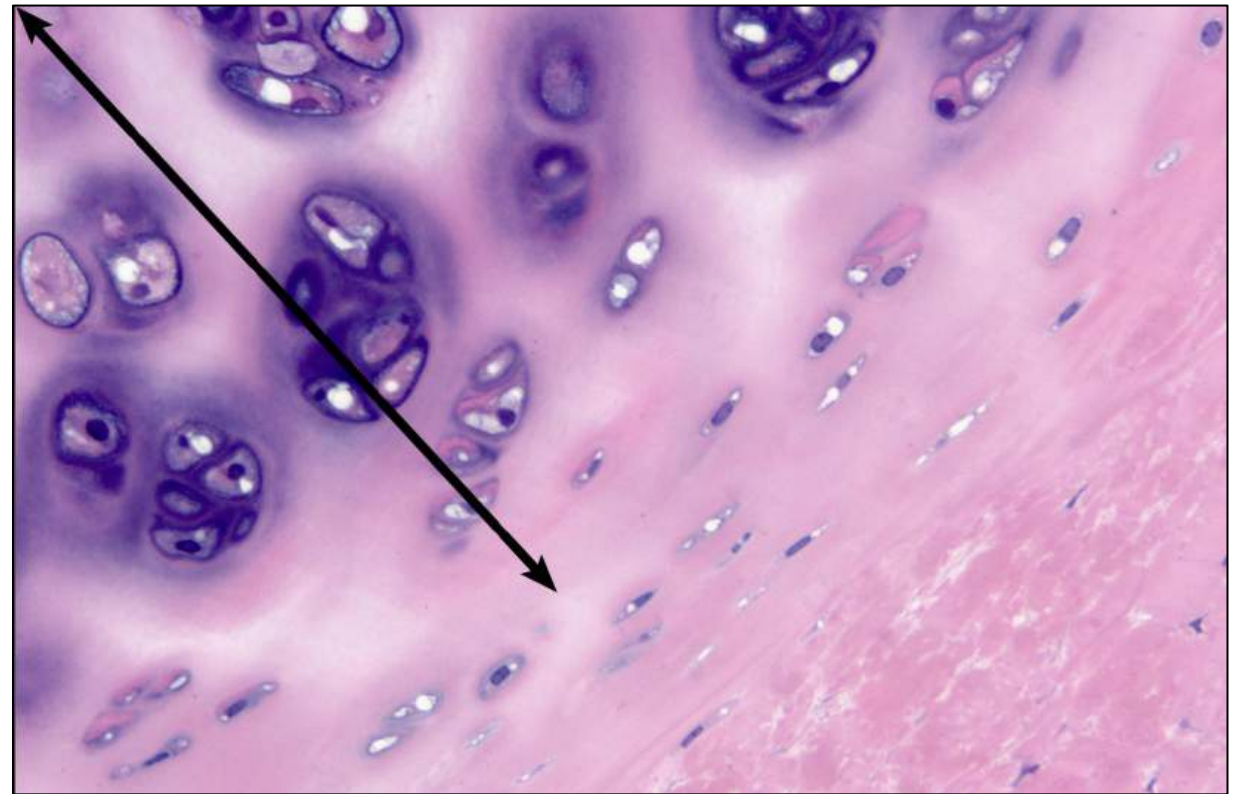
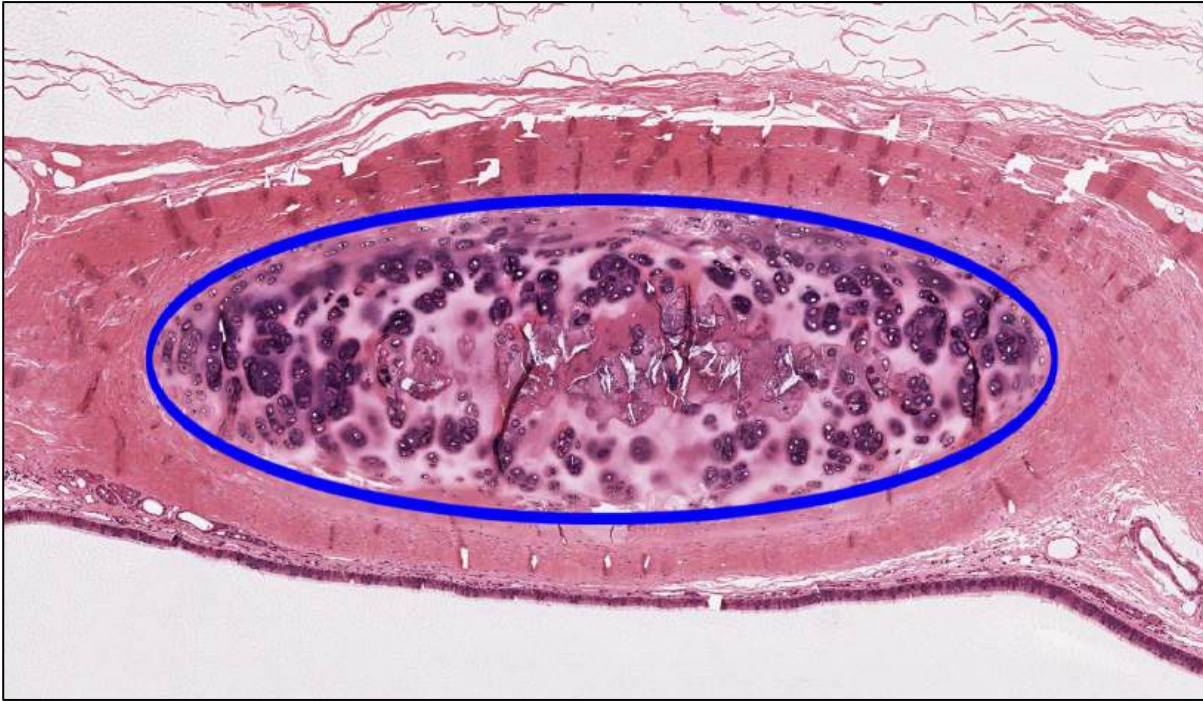Cartilage & Bone



Types of Cartilage

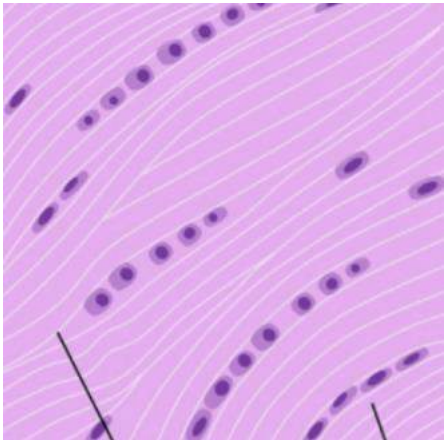
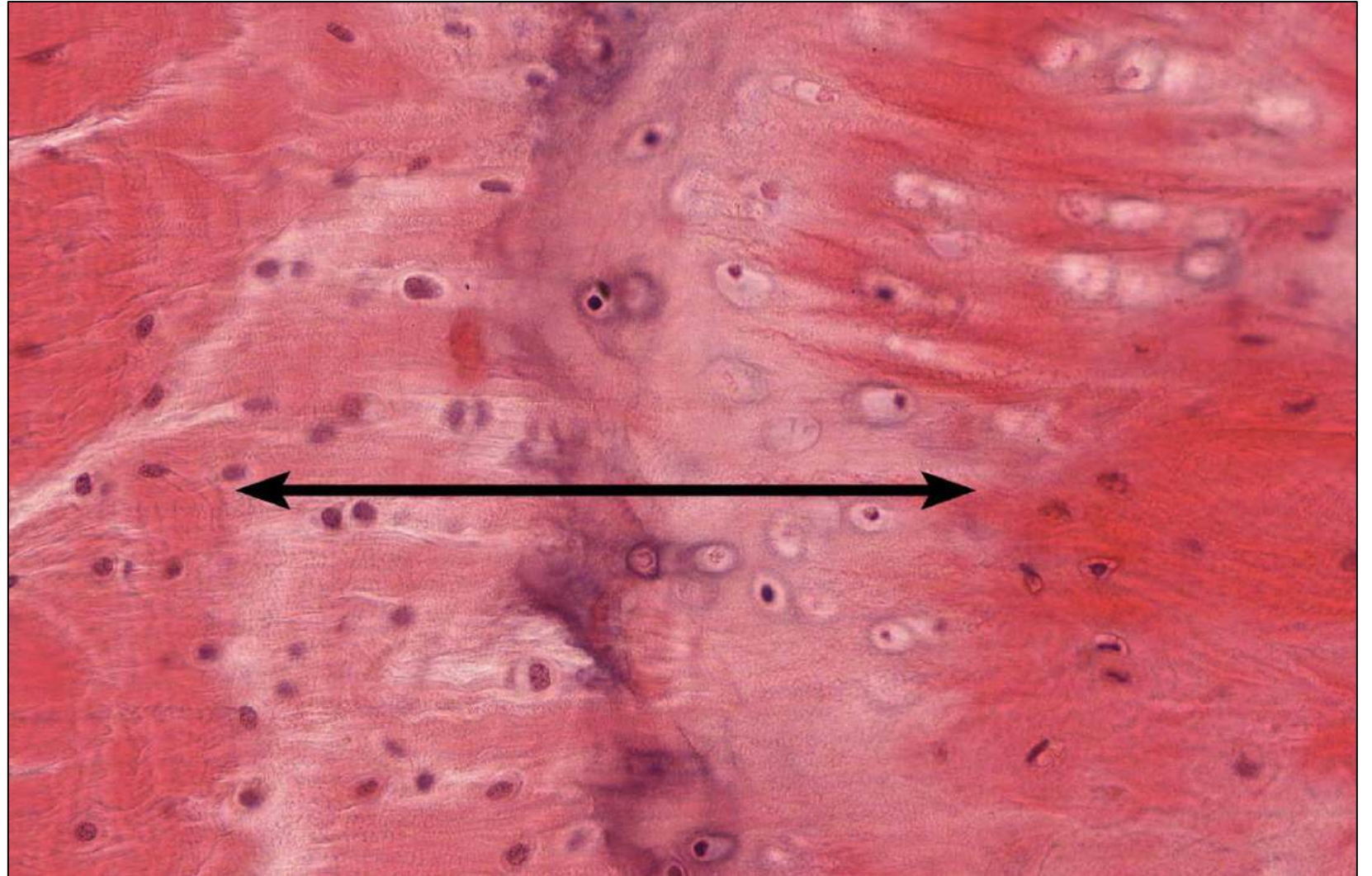
- Hyaline
- Fibrocartilage
- Elastic

Cartilage Types - Hyaline



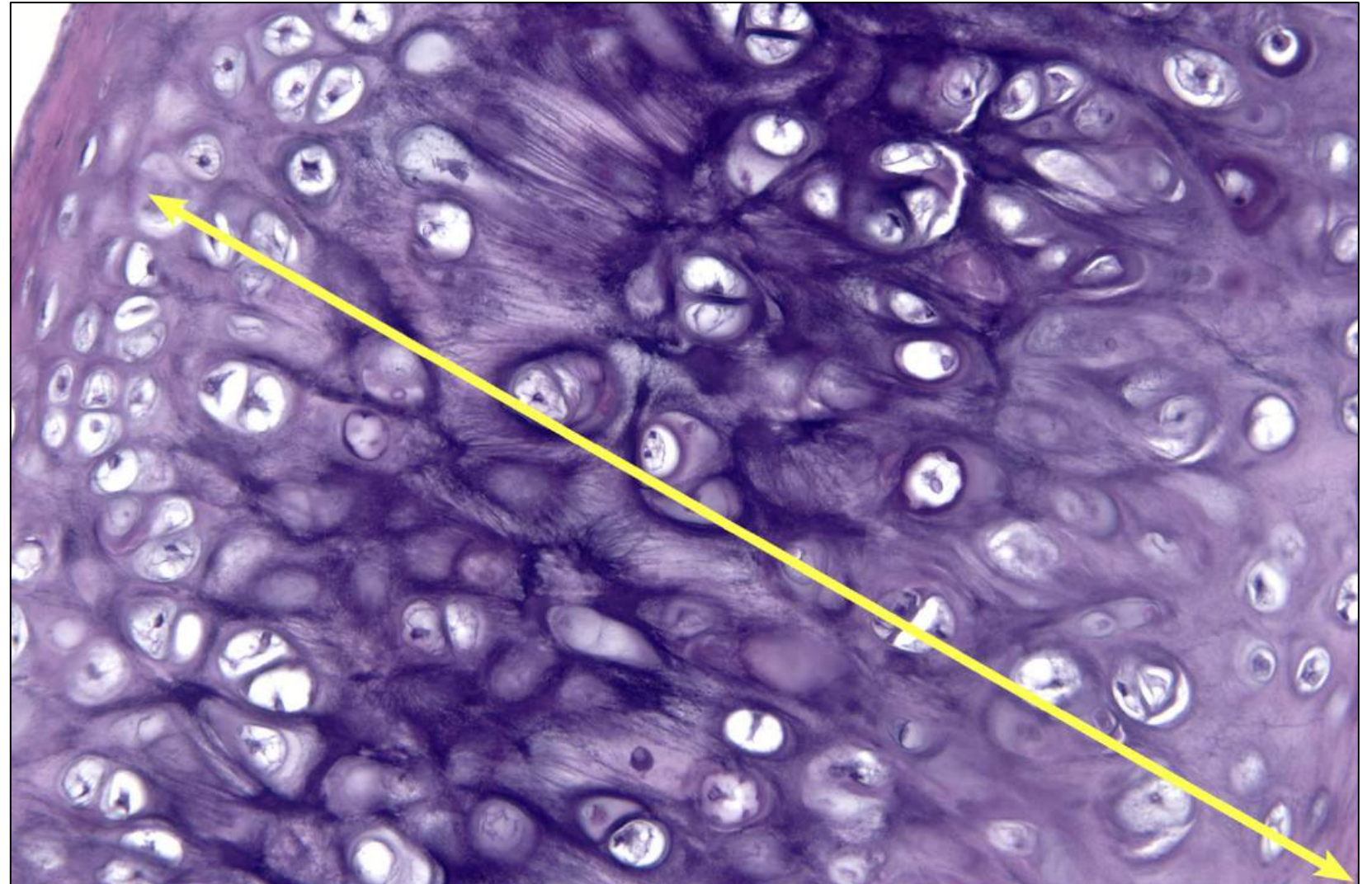

Ref. 6

Cartilage Types - Fibrocartilage



Ref. 6

Cartilage Types - Elastic

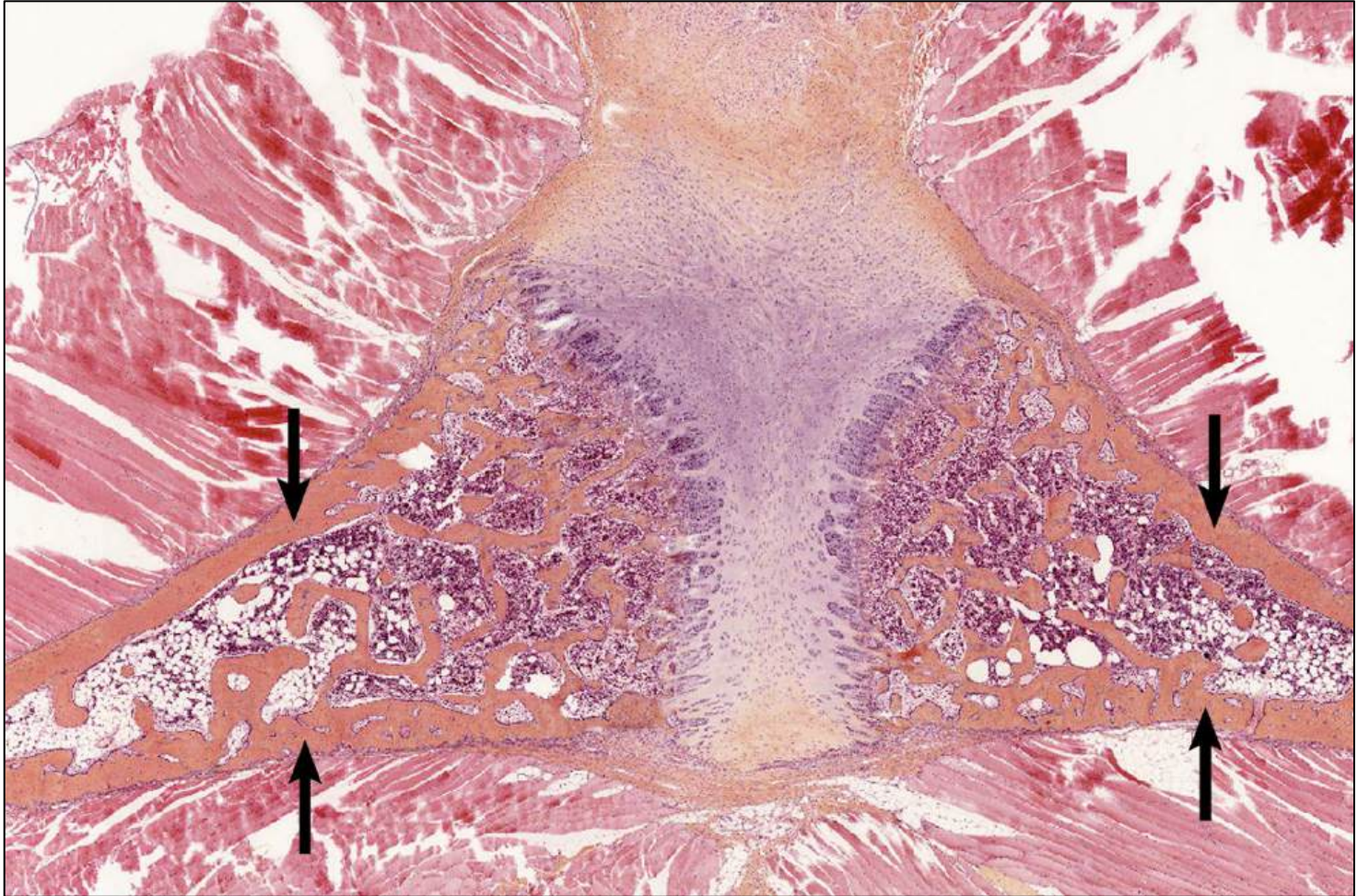
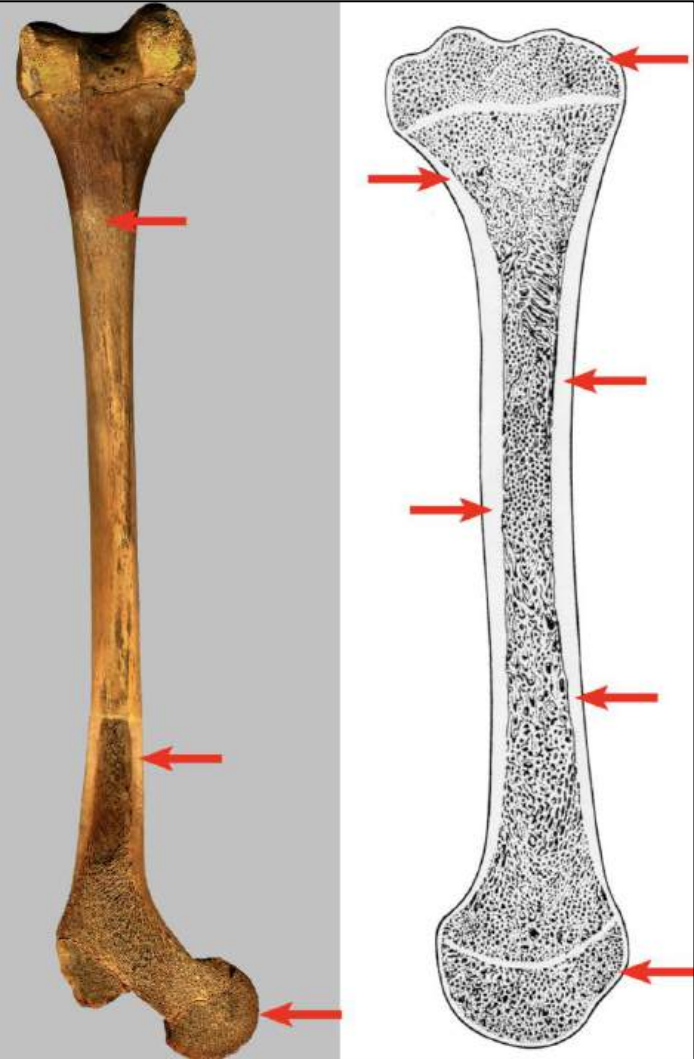


Ref. 6

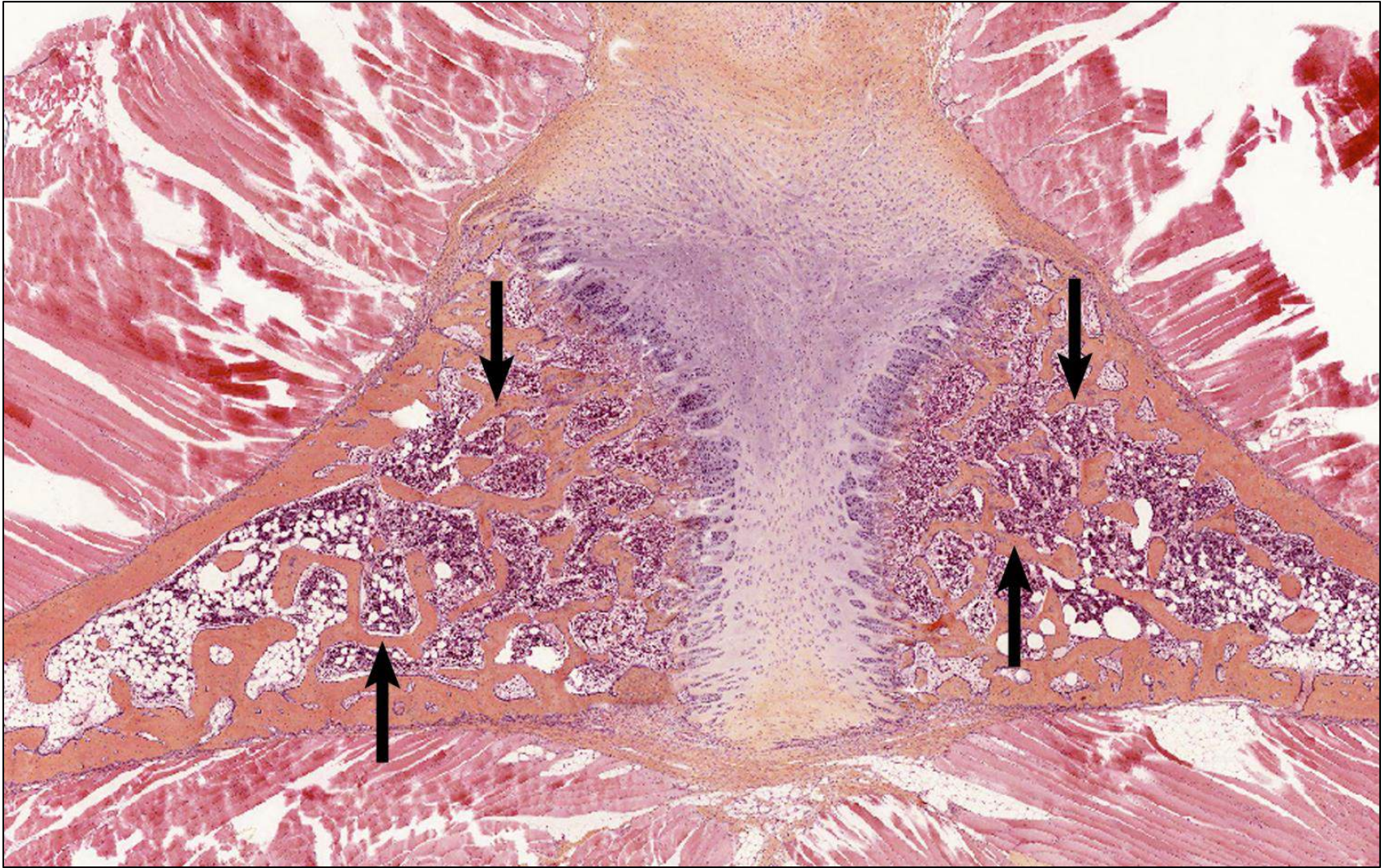
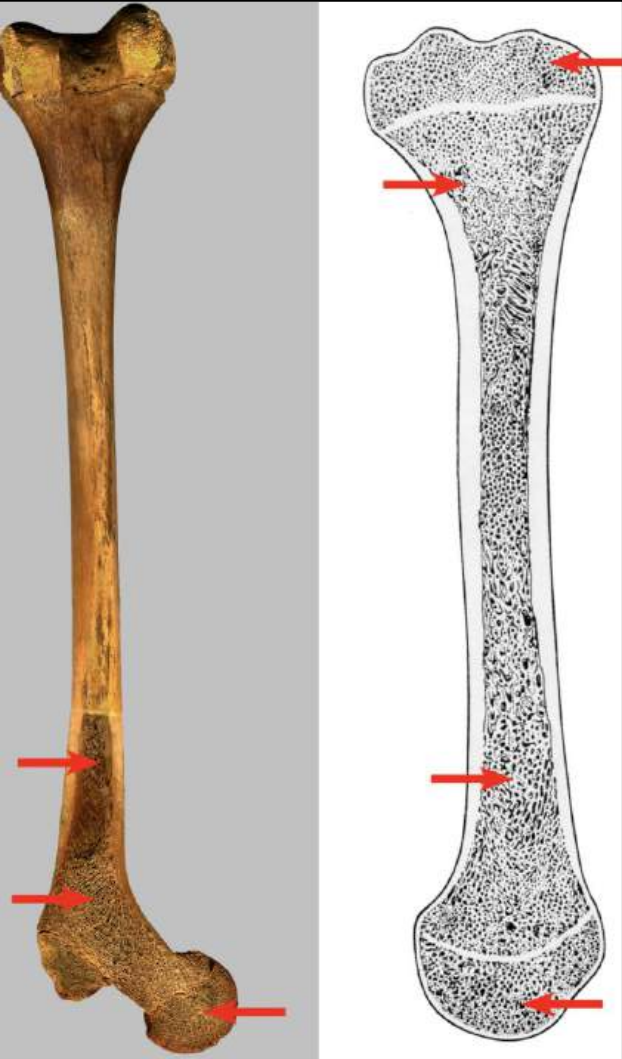
Types of Bone

- Compact or cortical bone
- Spongy or trabecular bone

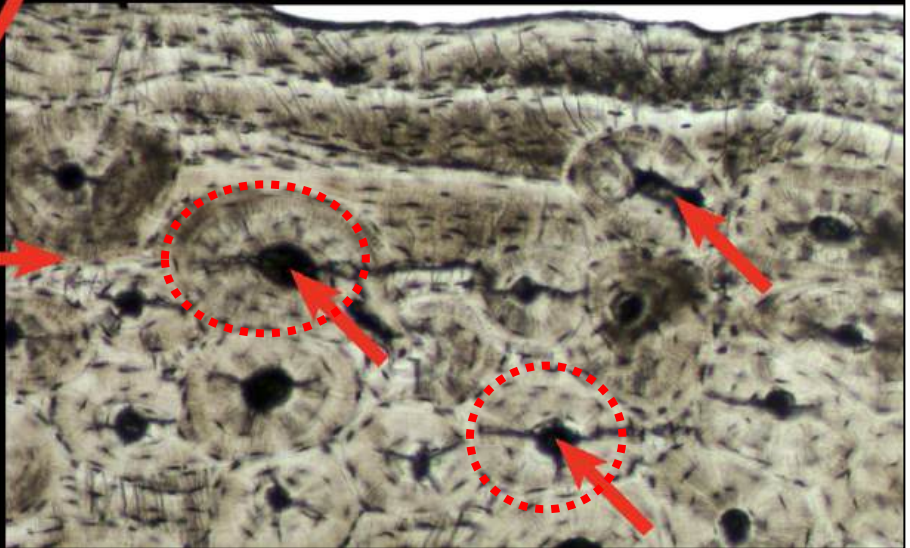
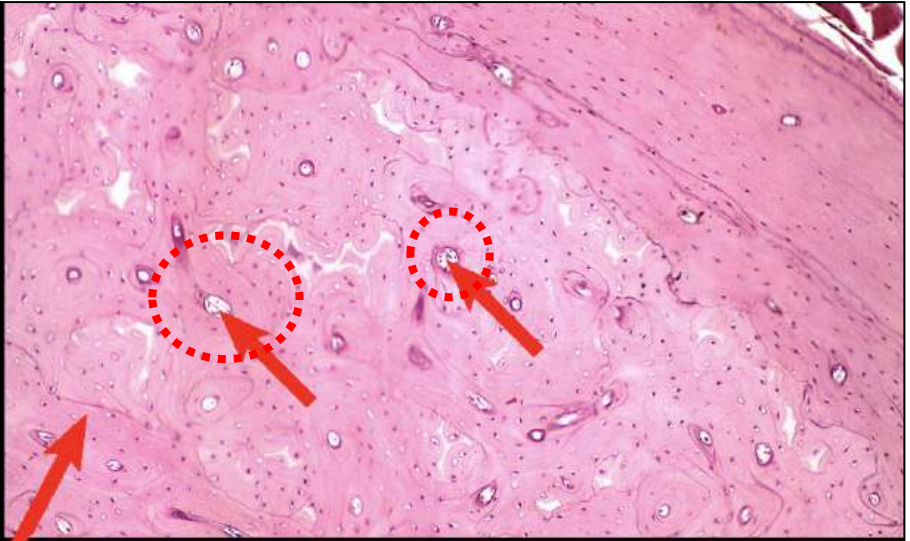
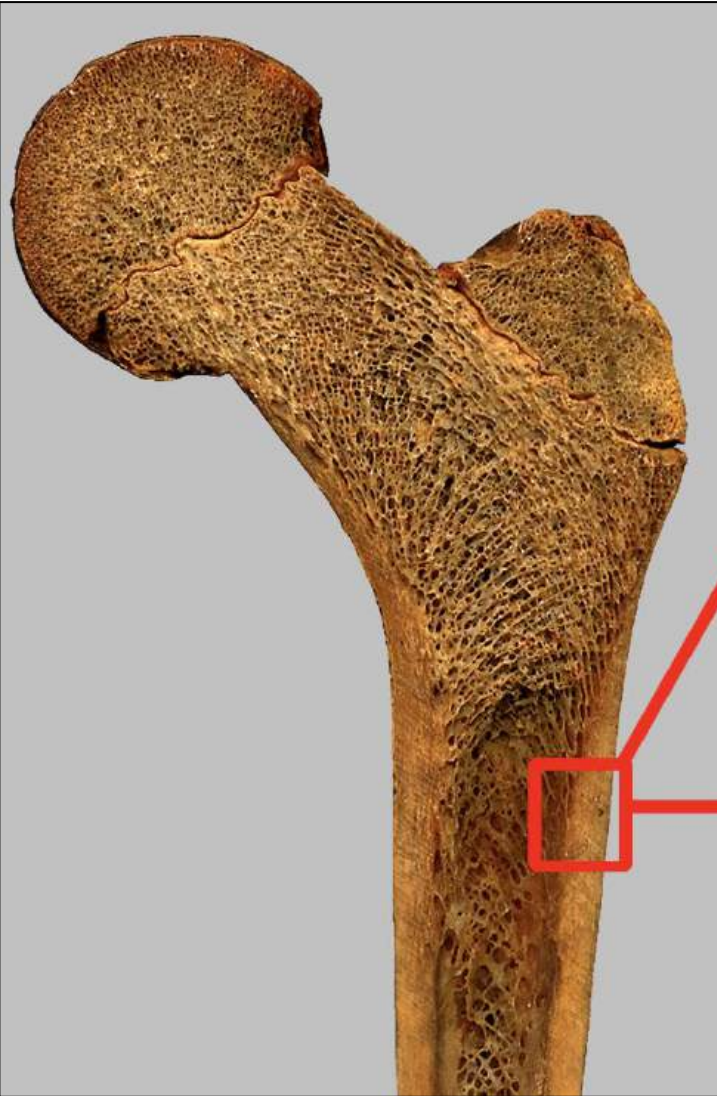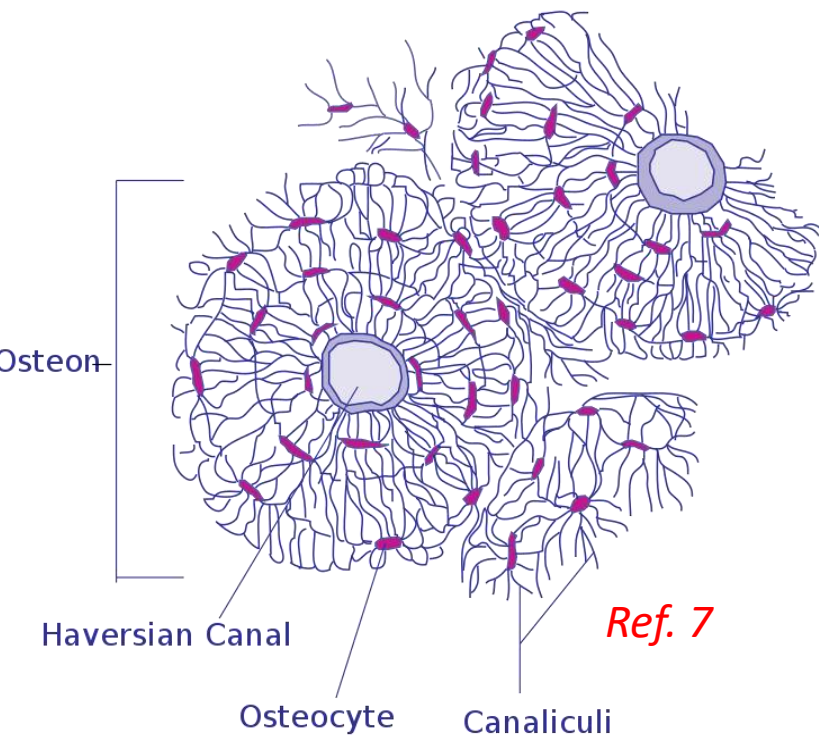
Bone Types – Compact/Cortical Bone



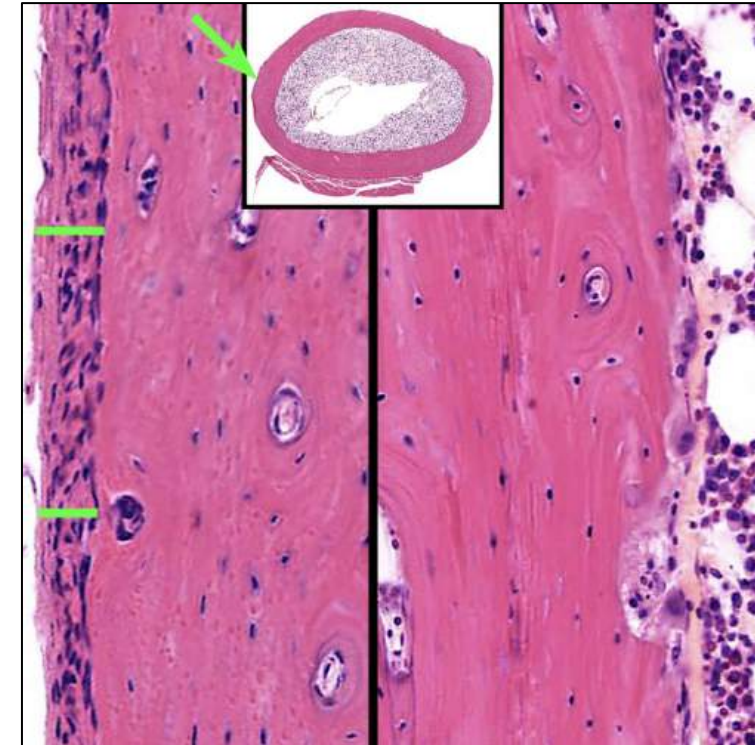
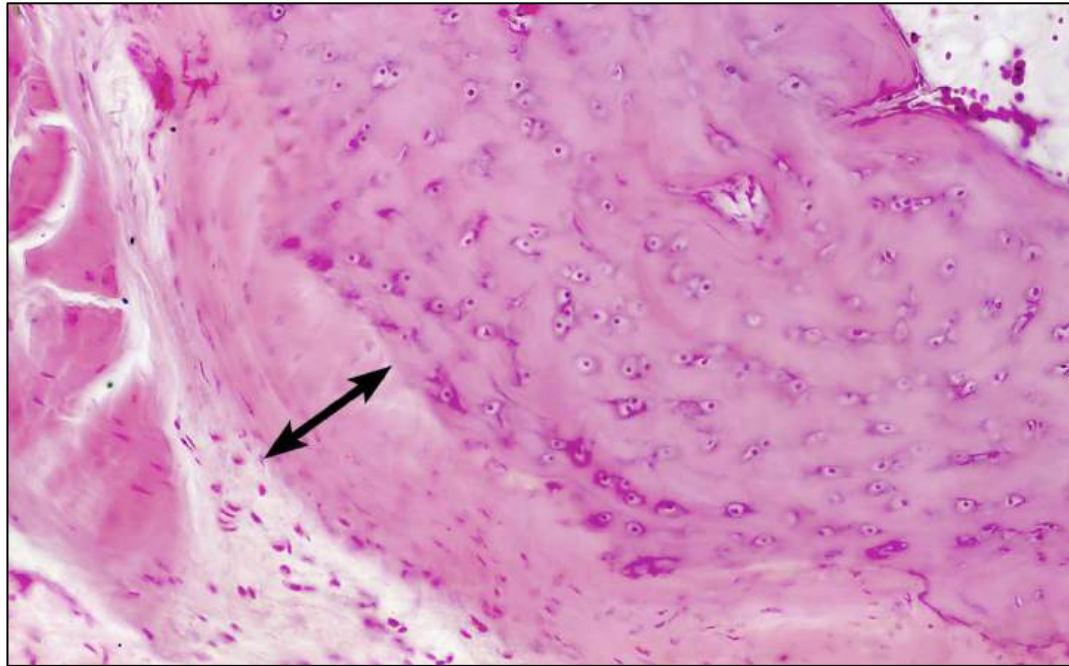
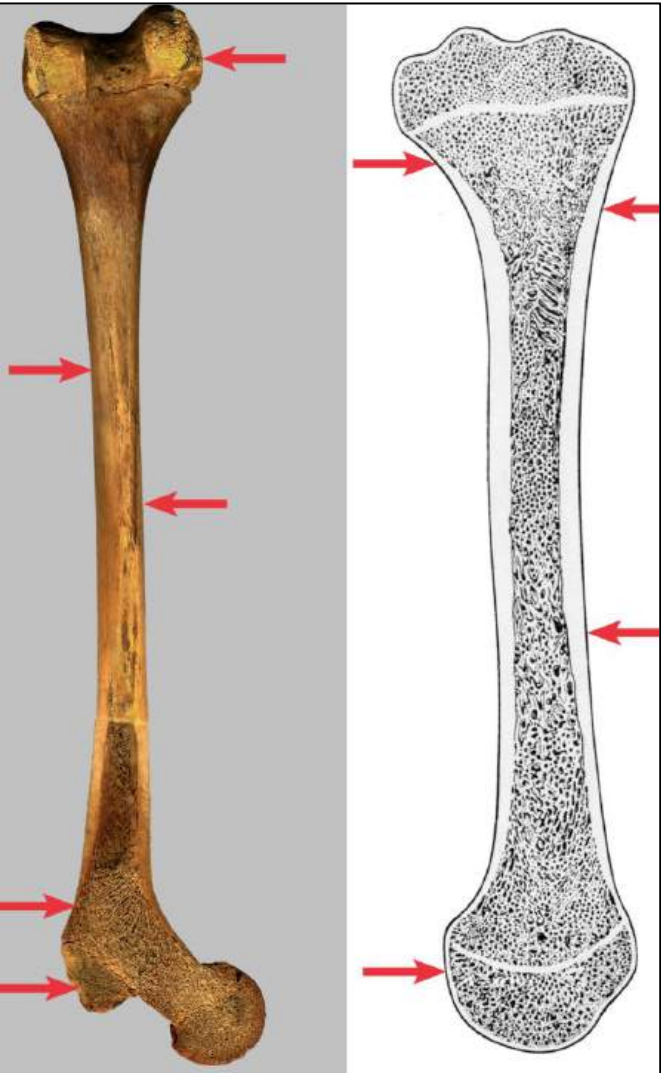
Bone Types – Spongy/Trabecular Bone



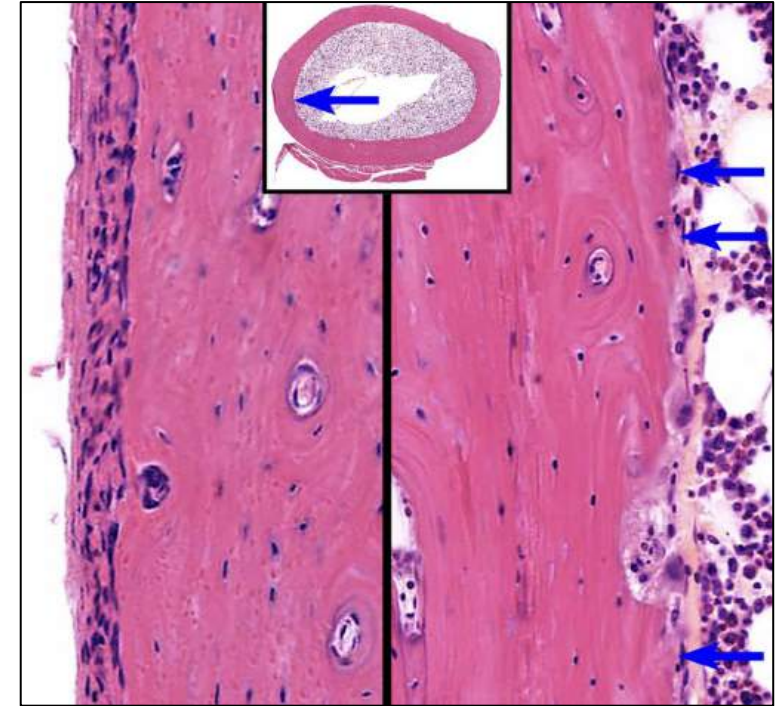
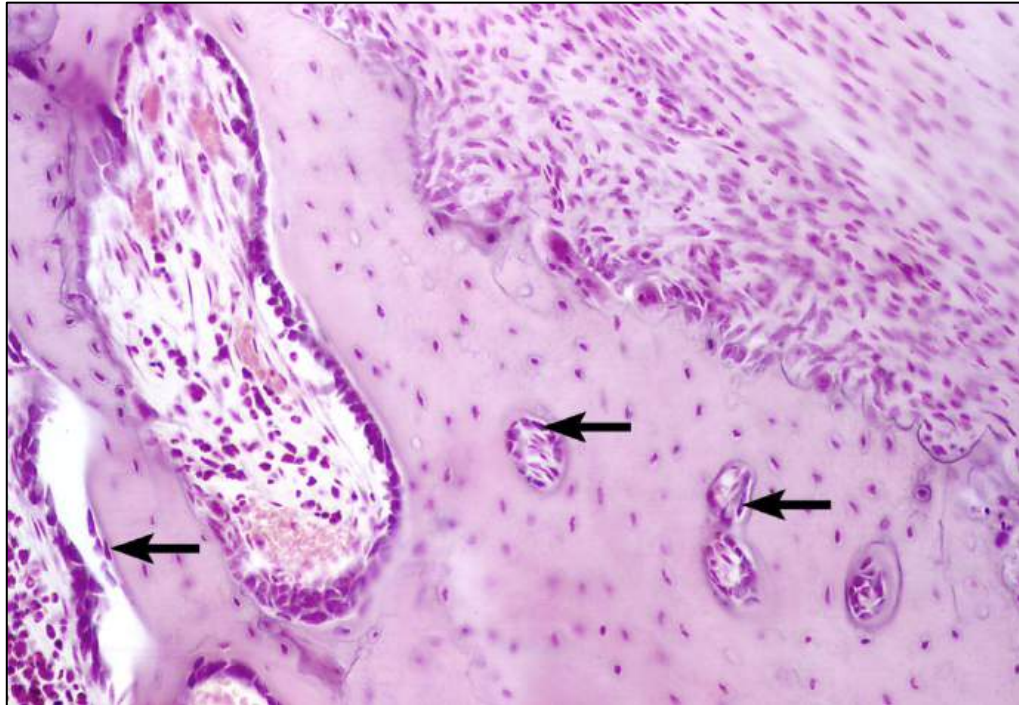
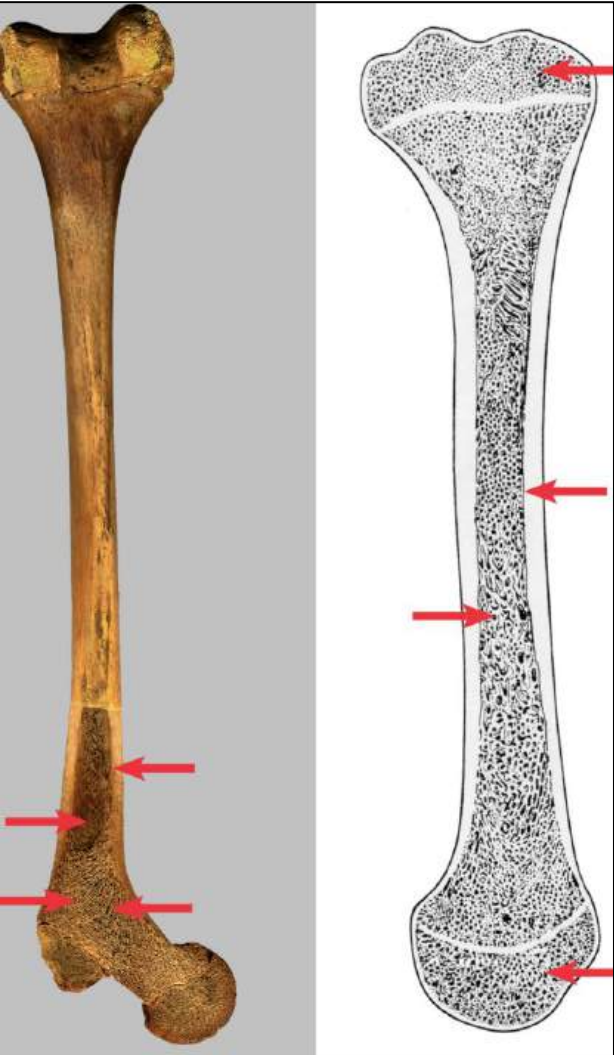
Osteon/Haversian System



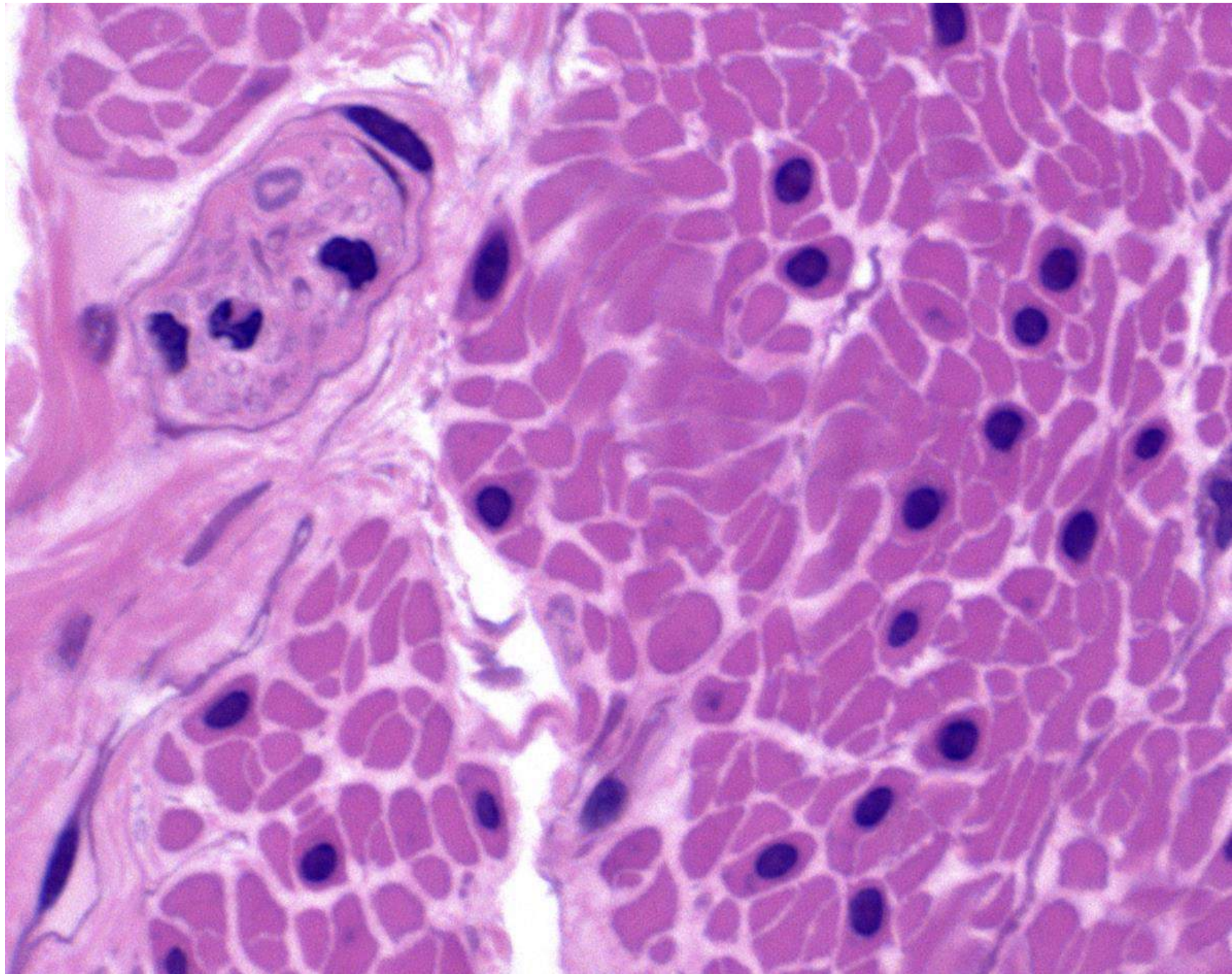
Connective Tissue in Bone - Periosteum



Connective Tissue in Bone - Endosteum



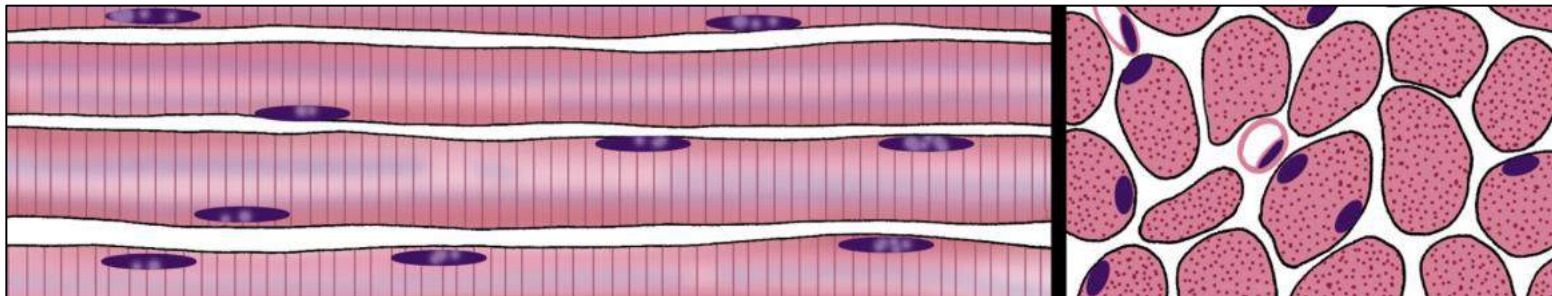
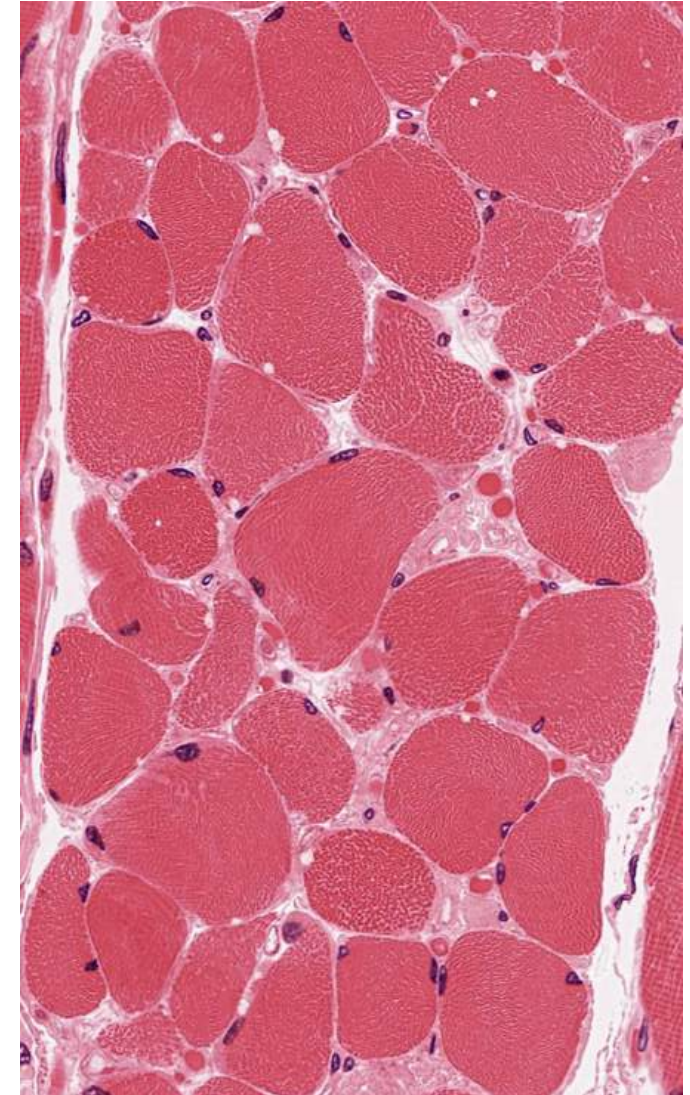

Muscle Tissue



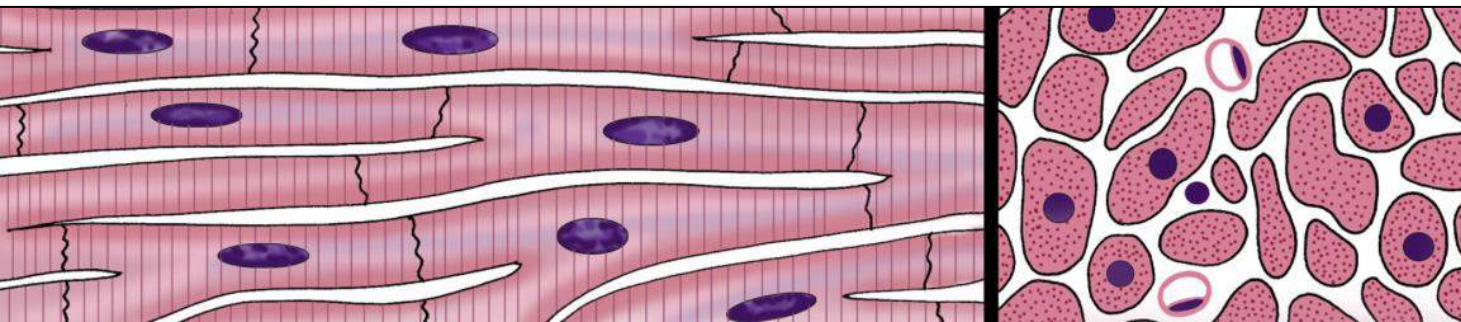
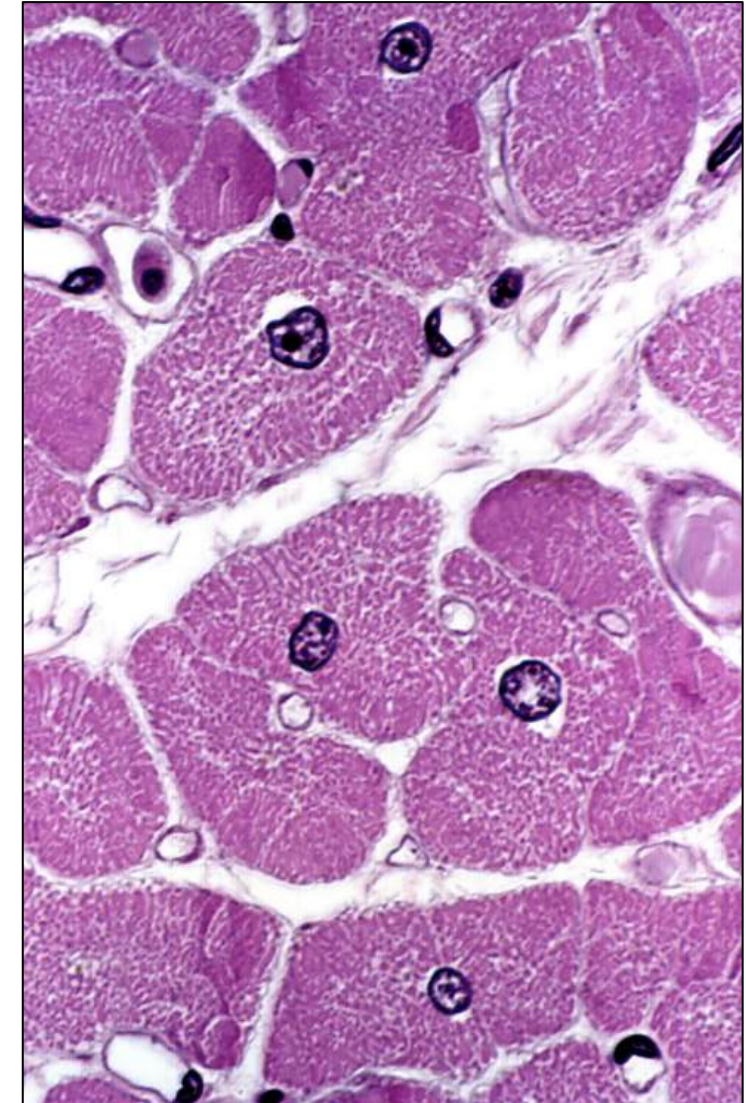
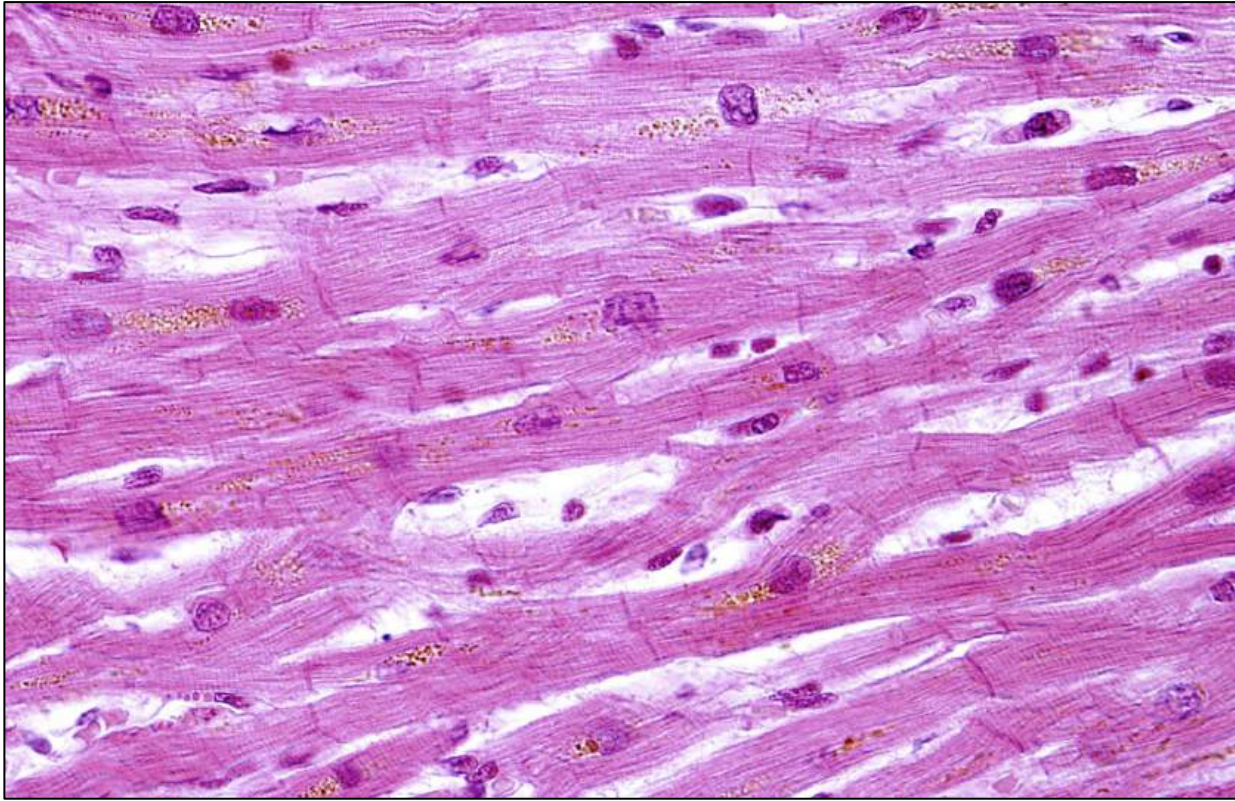
Types of Muscle

- Skeletal (e.g. biceps)
- Cardiac (heart)
- Smooth (e.g. stomach)


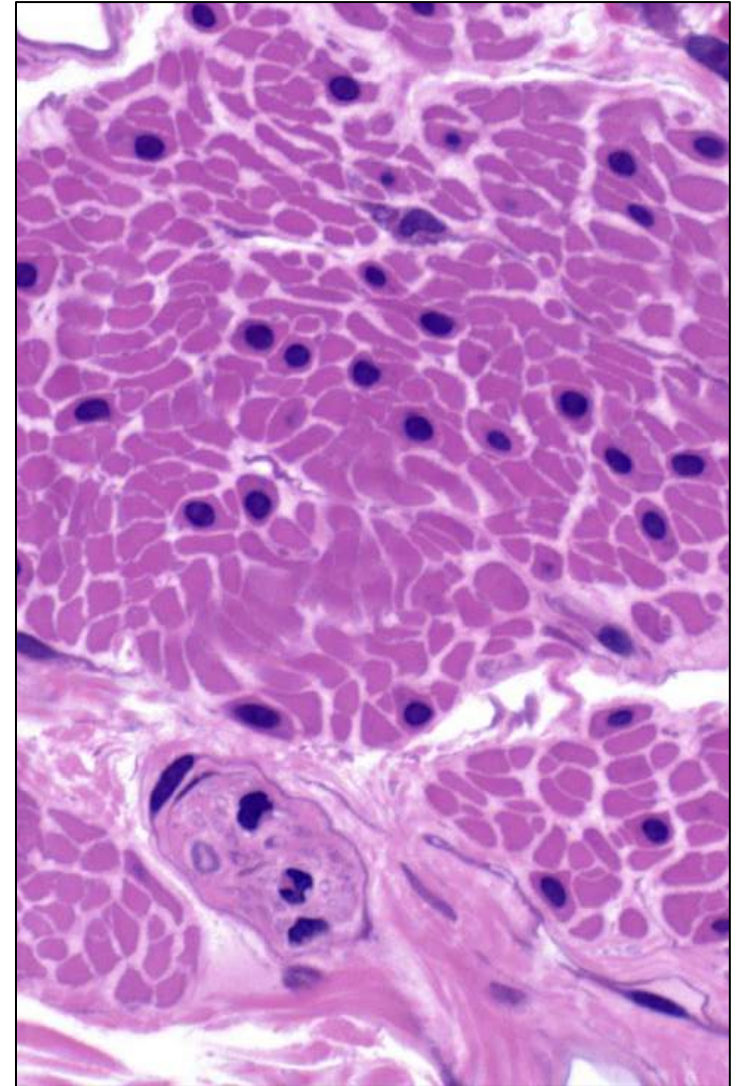
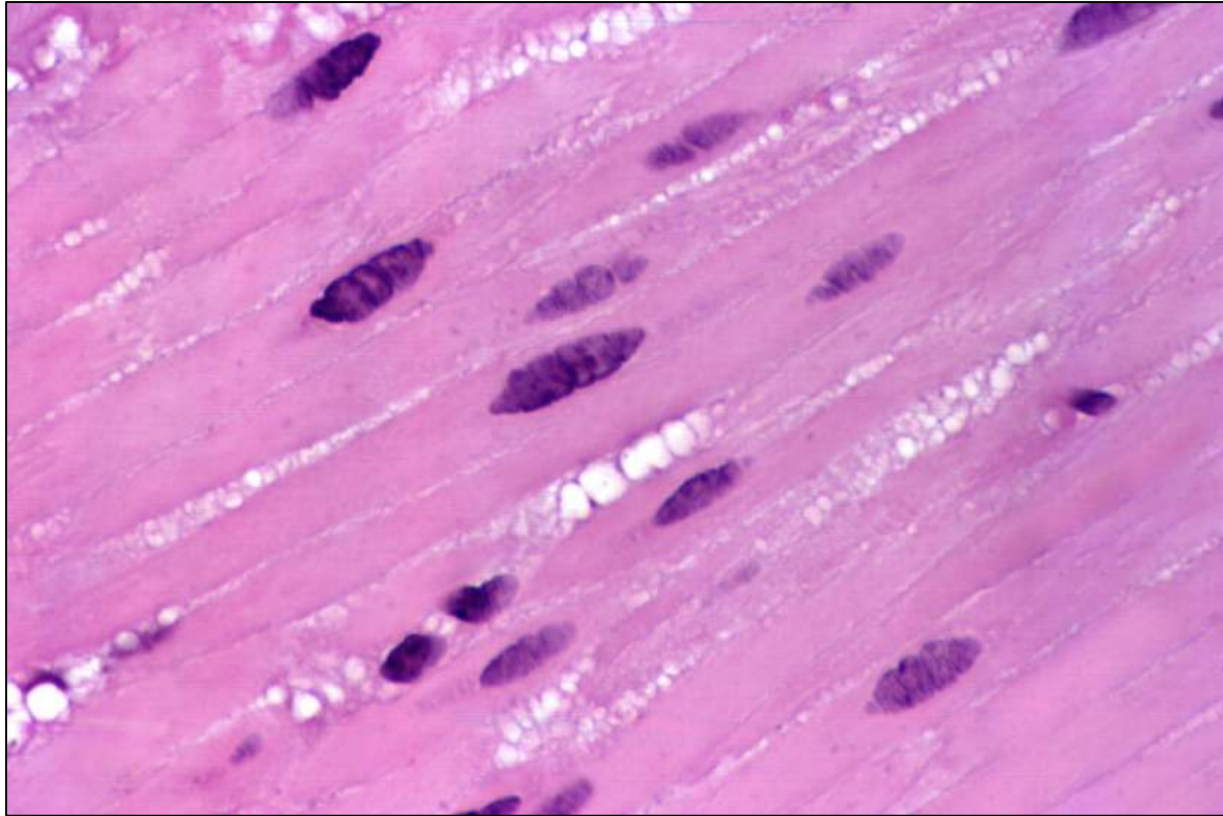
Muscle Types - Skeletal



Muscle Types - Cardiac




Muscle Types - Smooth



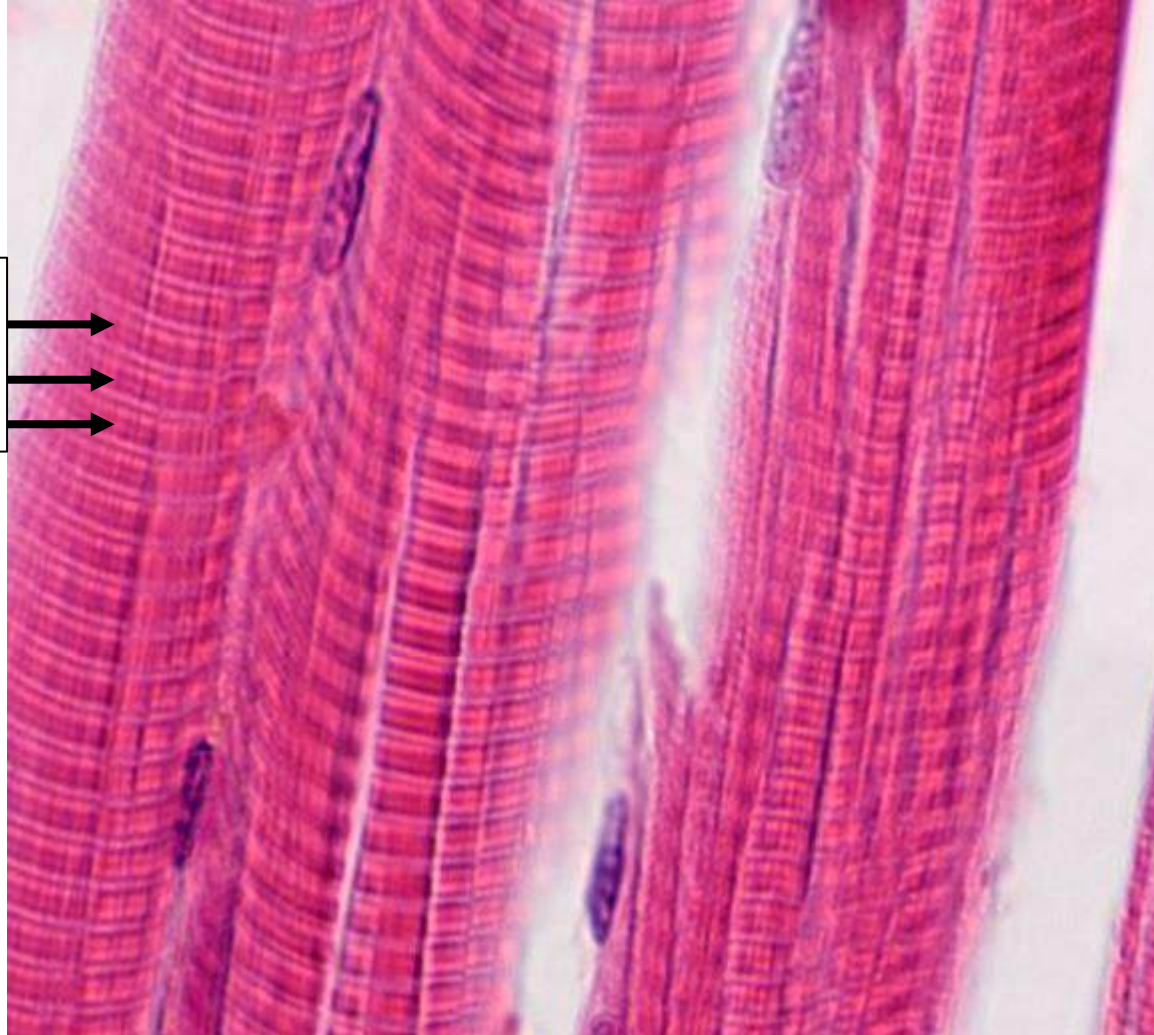
Skeletal Muscle Sarcomere on Light Microscopy

Sarcomere =
fundamental unit of
muscle contraction.
Spans the distance
between Z-lines.



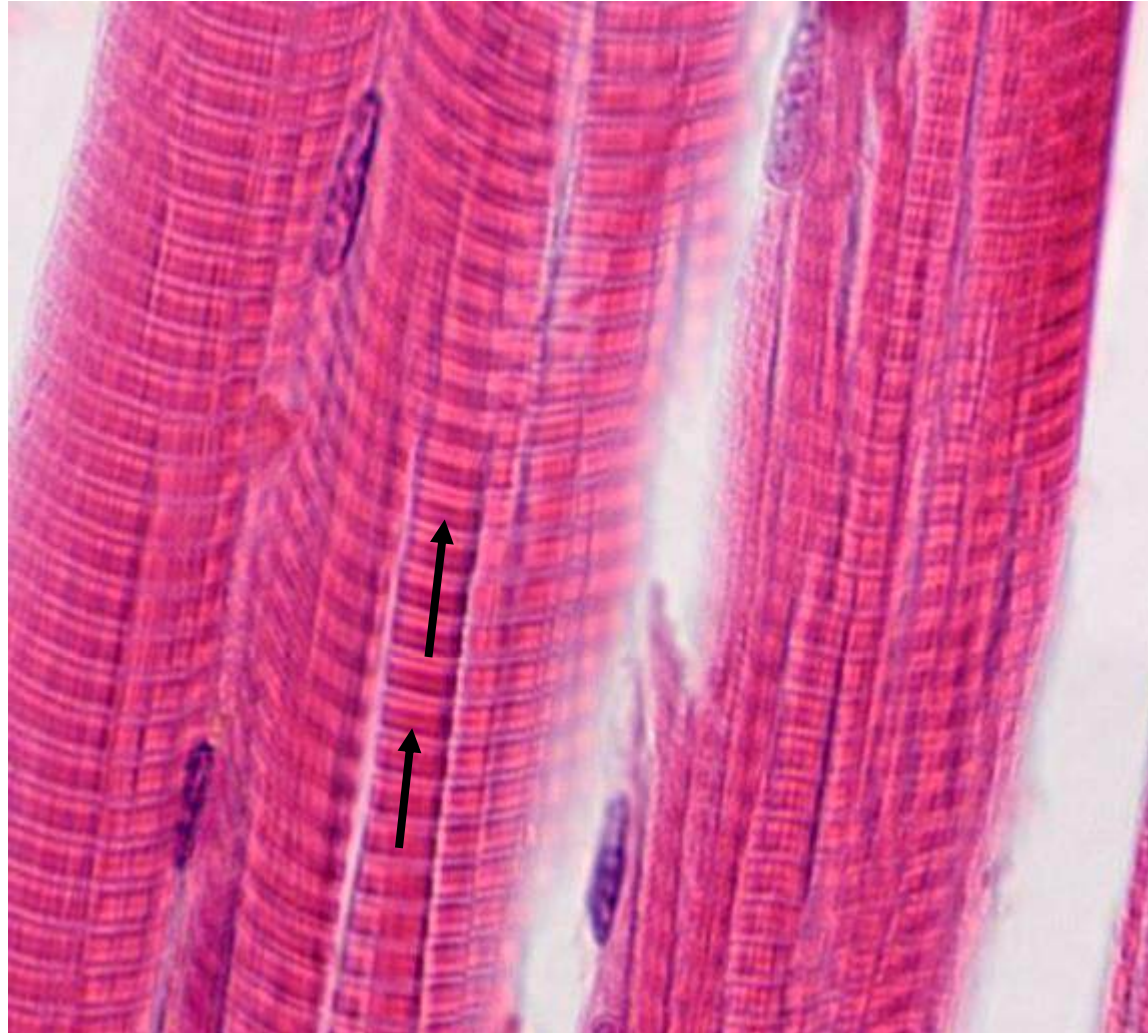
A Bands (Skeletal Muscle Sarcomere) on Light Microscopy

A bands – are the wide, dark bands.



H Bands (Skeletal Muscle Sarcomere) on Light Microscopy

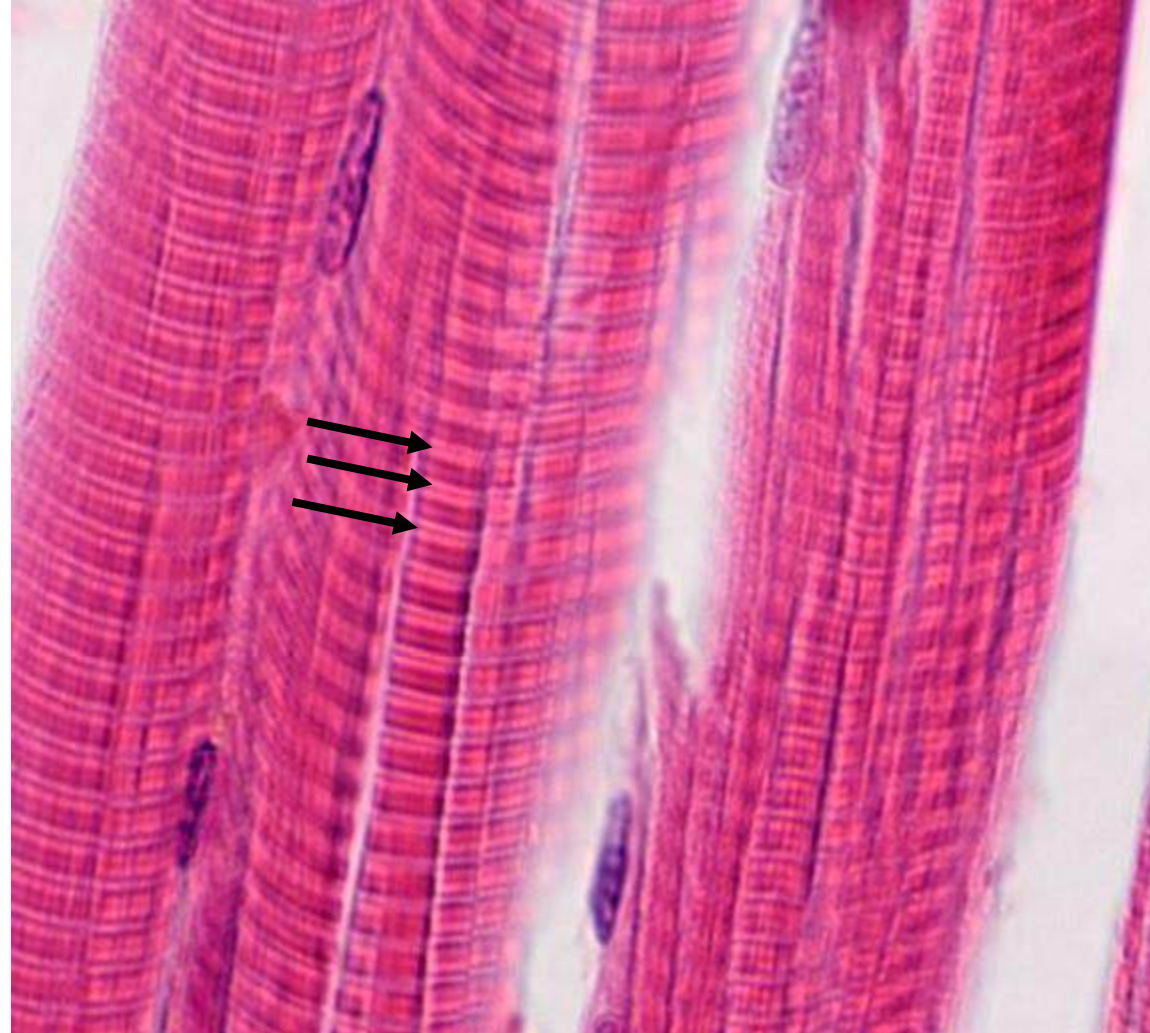
H-band is the pale pink/white line down the center of the A-band.



I Bands (Skeletal Muscle Sarcomere) on Light Microscopy

I bands are the lighter pink staining bands on either side of the darker A-band.

The I band is bisected by the **Z-line**.




Cardiac Muscle Sarcomere on Transmission Electron Microscopy



A Bands (Cardiac Muscle Sarcomere) on Transmission Electron Microscopy




H Bands (Cardiac Muscle Sarcomere) on Transmission Electron Microscopy




I Bands (Cardiac Muscle Sarcomere) on Transmission Electron Microscopy



M Line (Cardiac Muscle Sarcomere) on Transmission Electron Microscopy



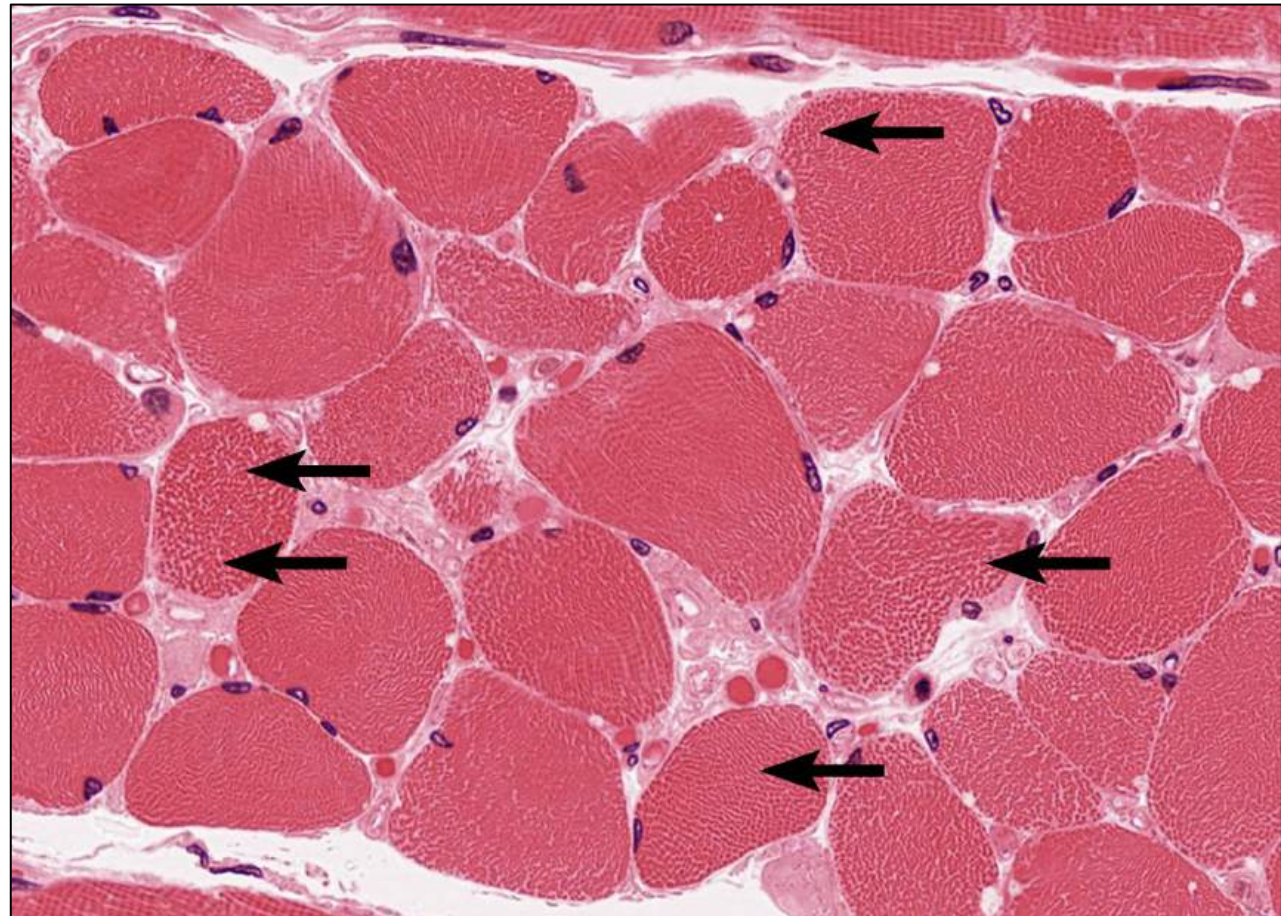
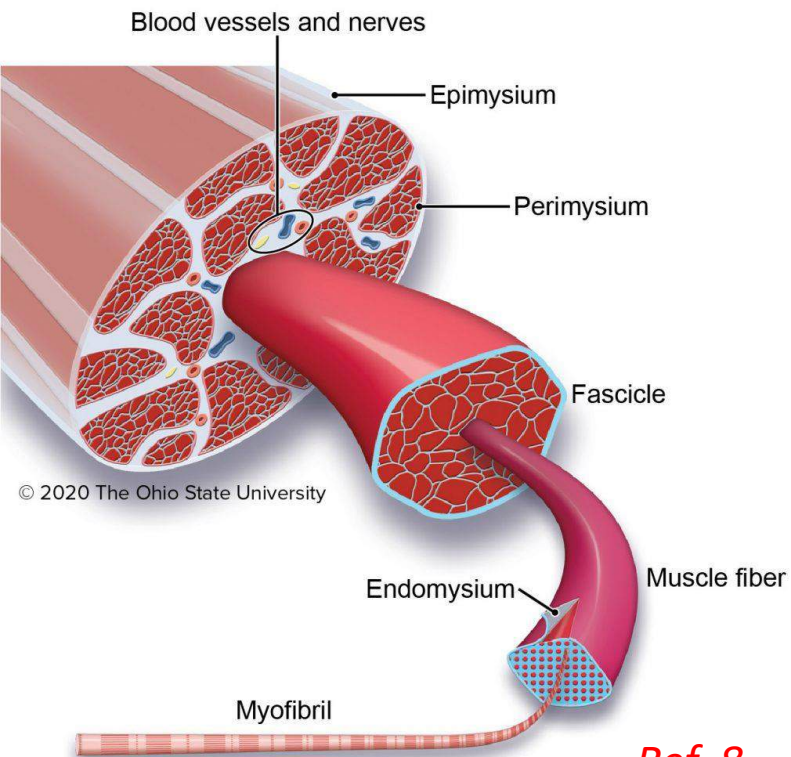
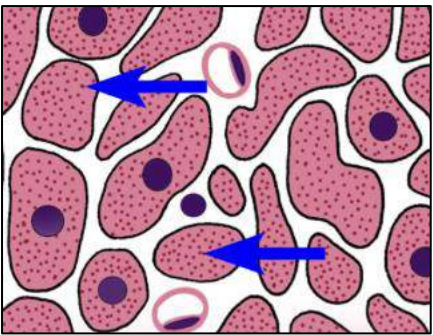
Z Line (Cardiac Muscle Sarcomere) on Transmission Electron Microscopy



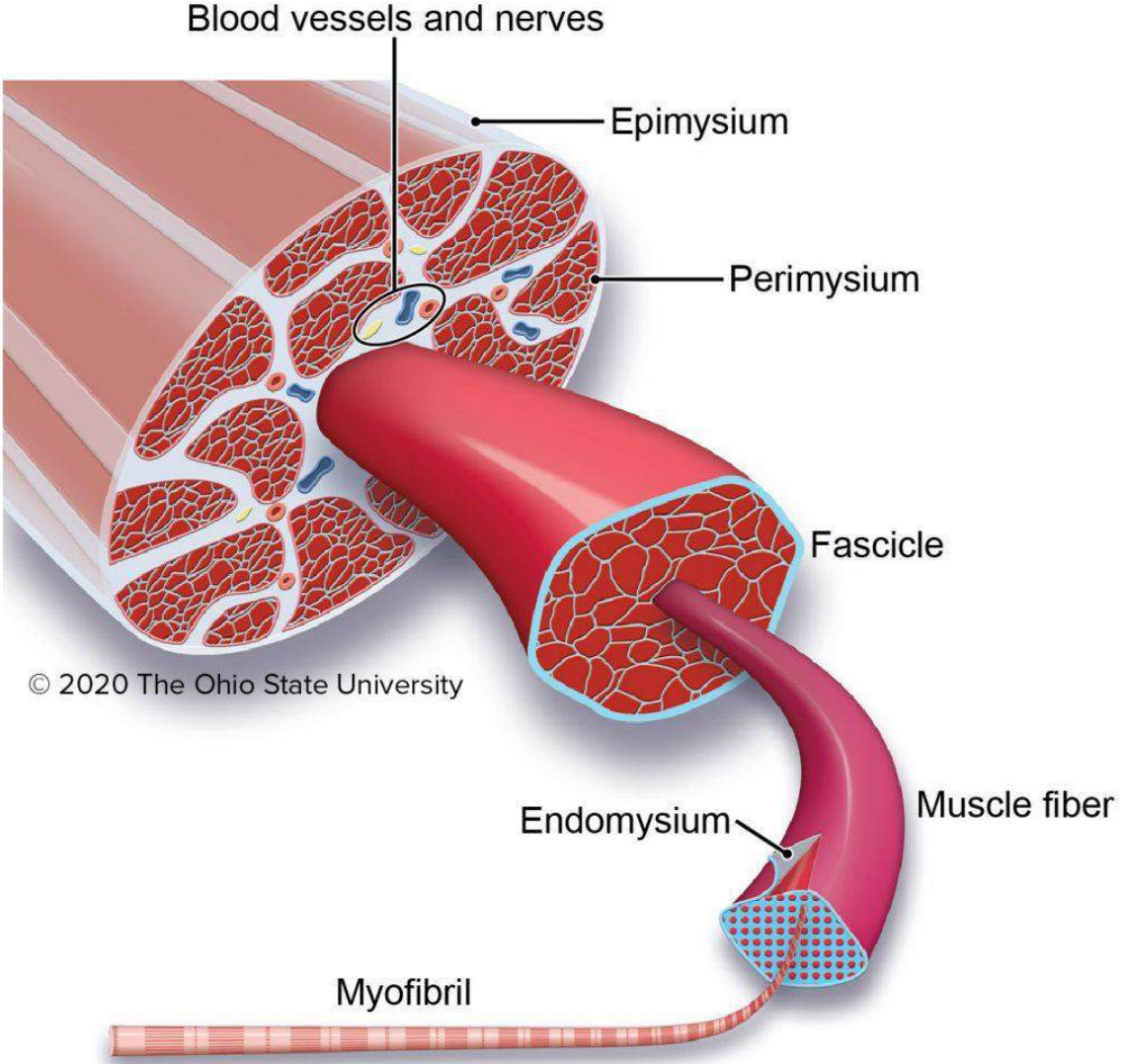
Organization of Skeletal Muscle

- Myofibril
- Myofilament
- Myofiber
- Fascicle
- Muscle


Skeletal Muscle Organization – Myofiber = Single muscle fiber/muscle cell



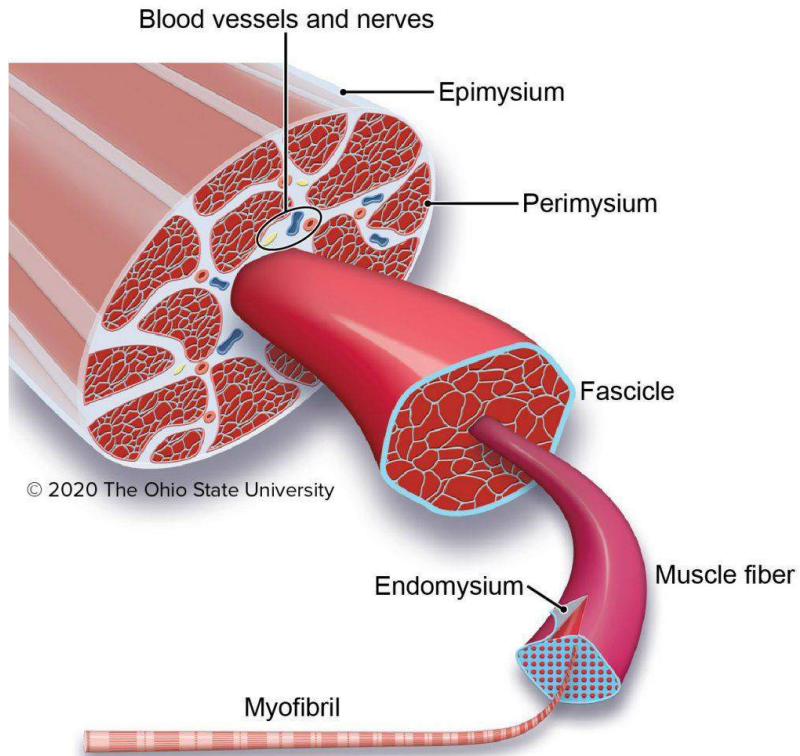
Skeletal Muscle Organization - Myofibril



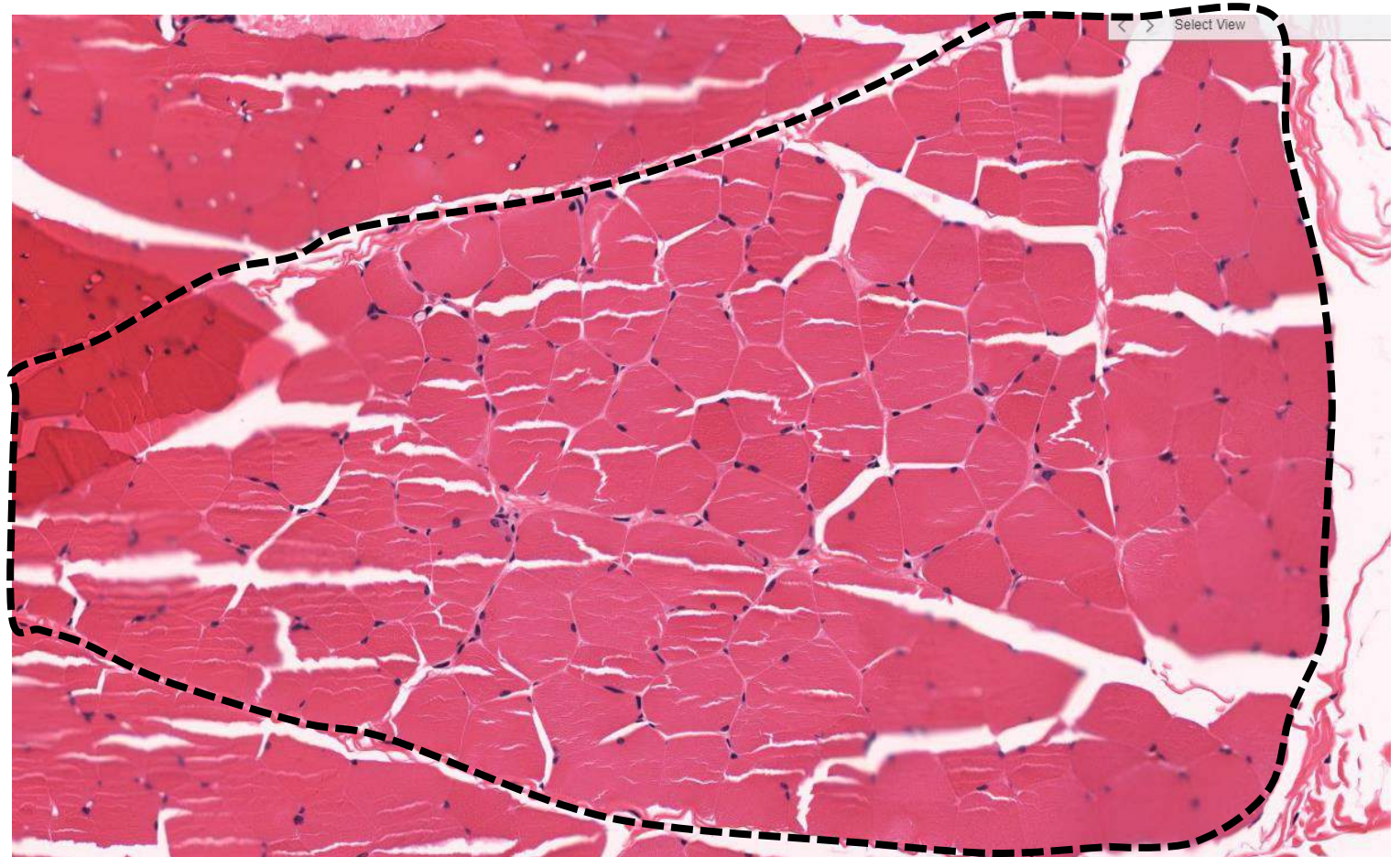
Ref. 8



Skeletal Muscle Organization - Fascicle



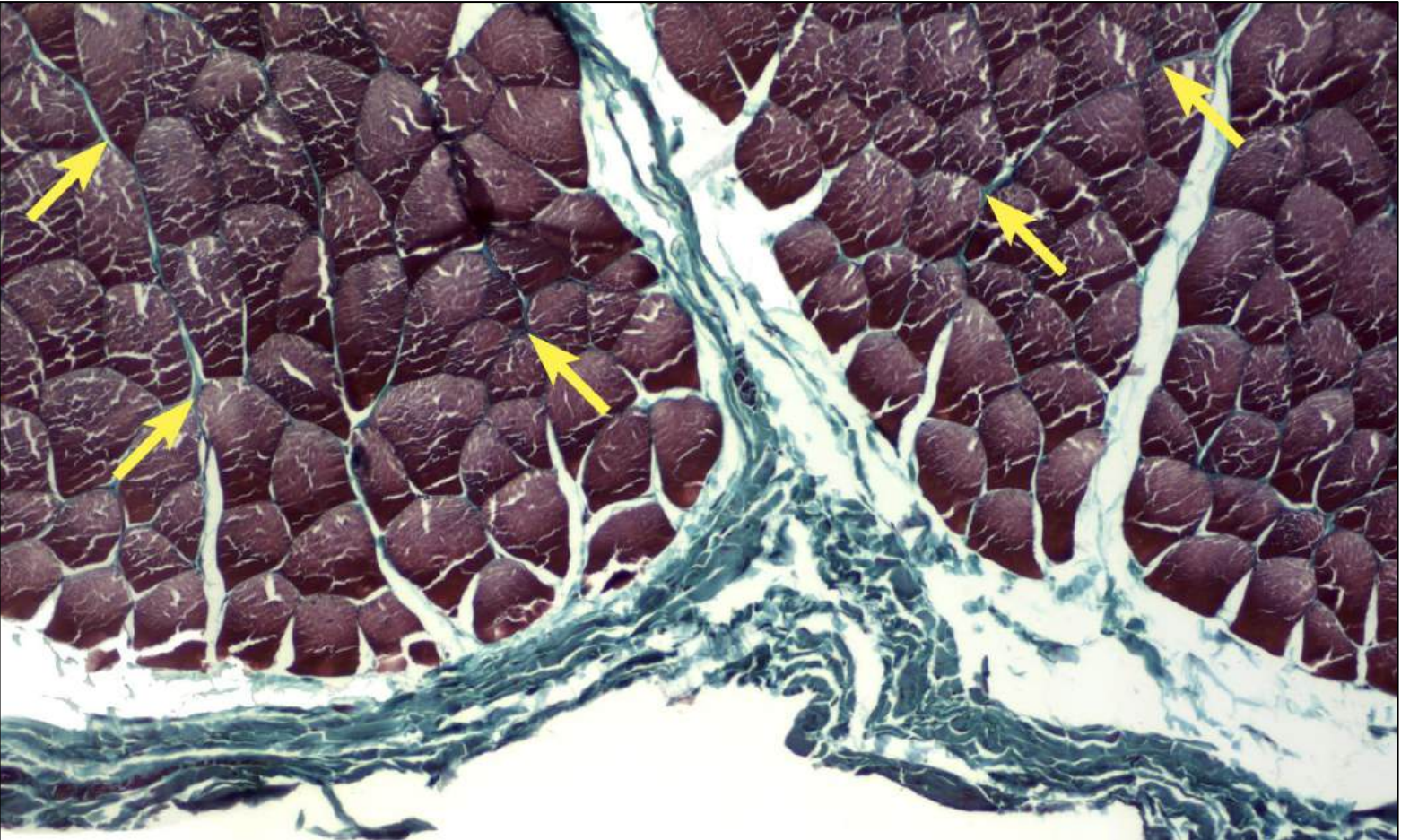
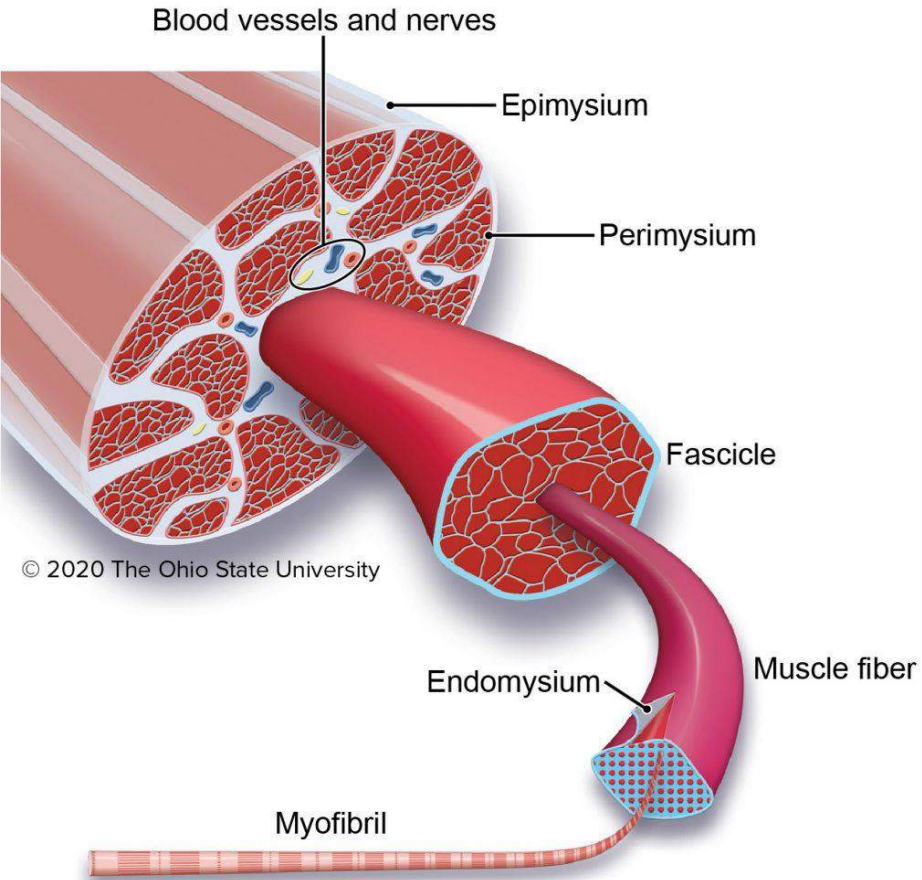
Ref. 8



Connective Tissue of Muscle

- Endomysium
- Perimysium
- Epimysium

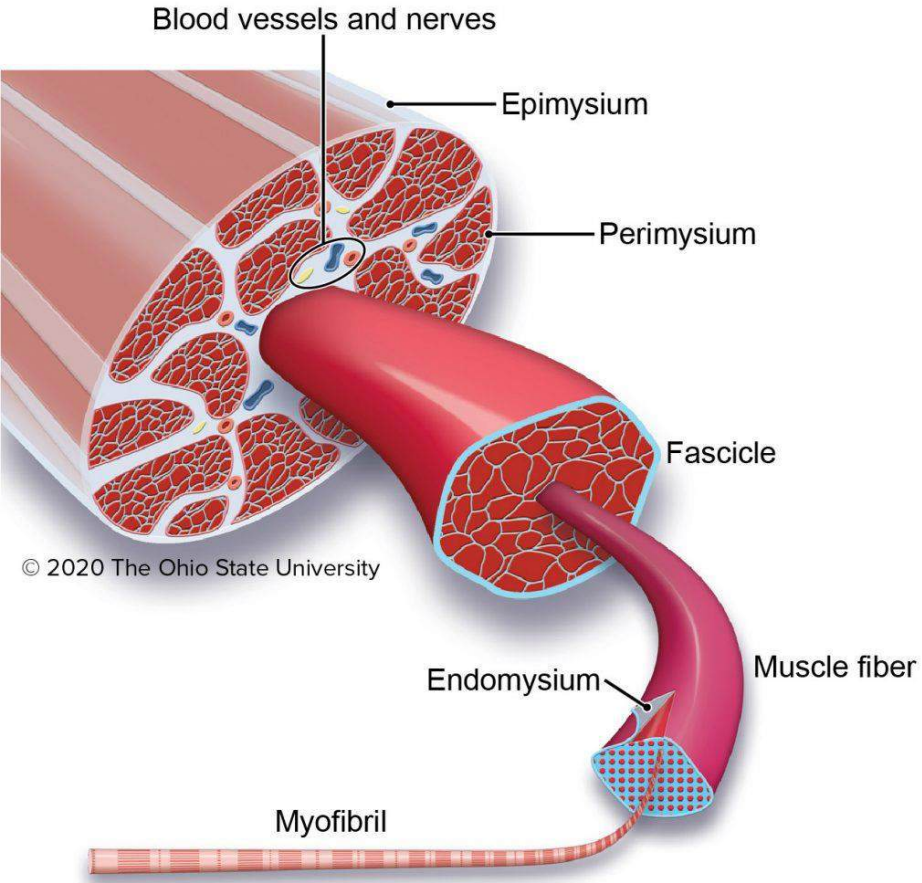
Connective Tissue of Muscle - Endomysium



© 2020 The Ohio State University

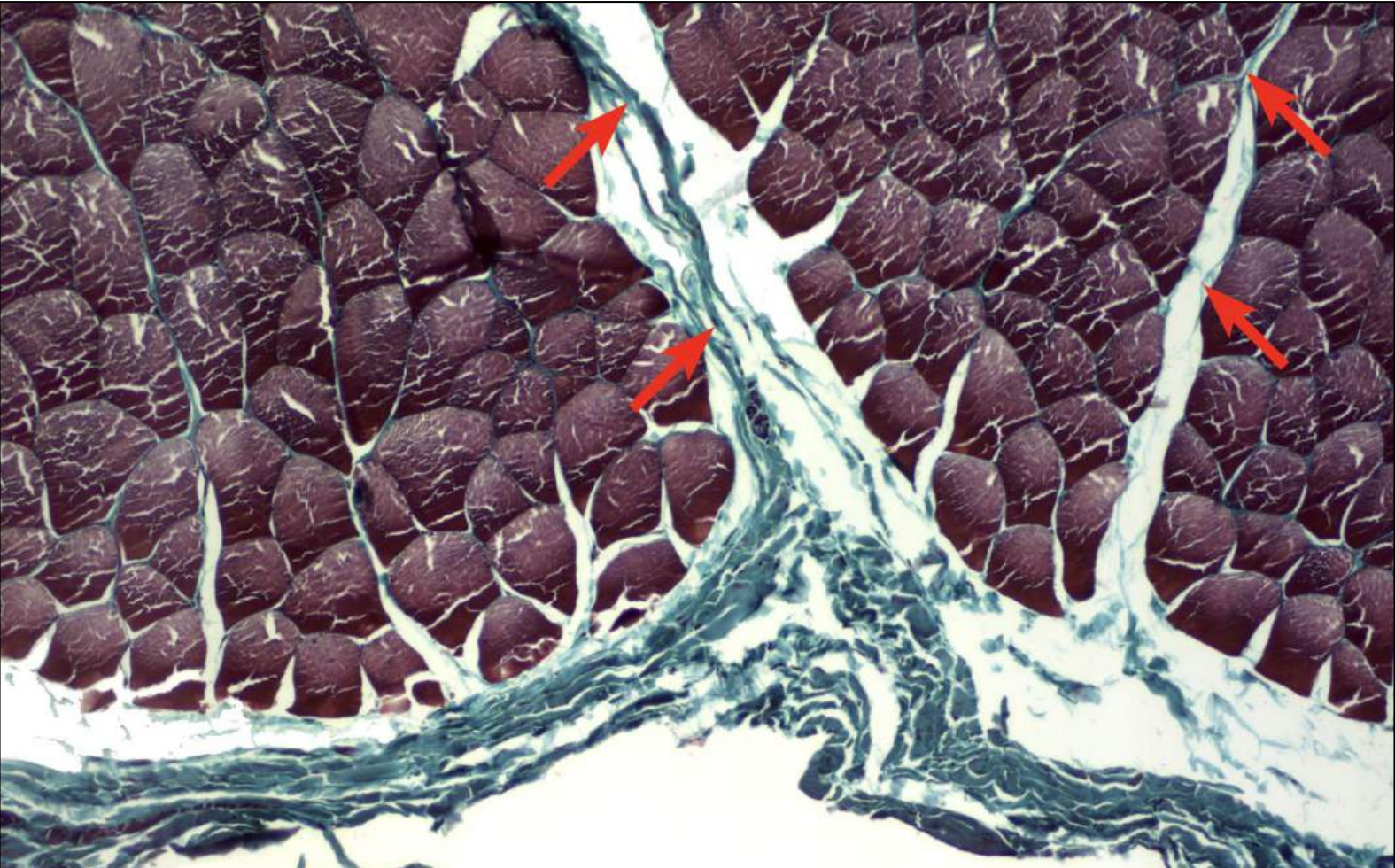
Ref. 8

Connective Tissue of Muscle - Perimysium

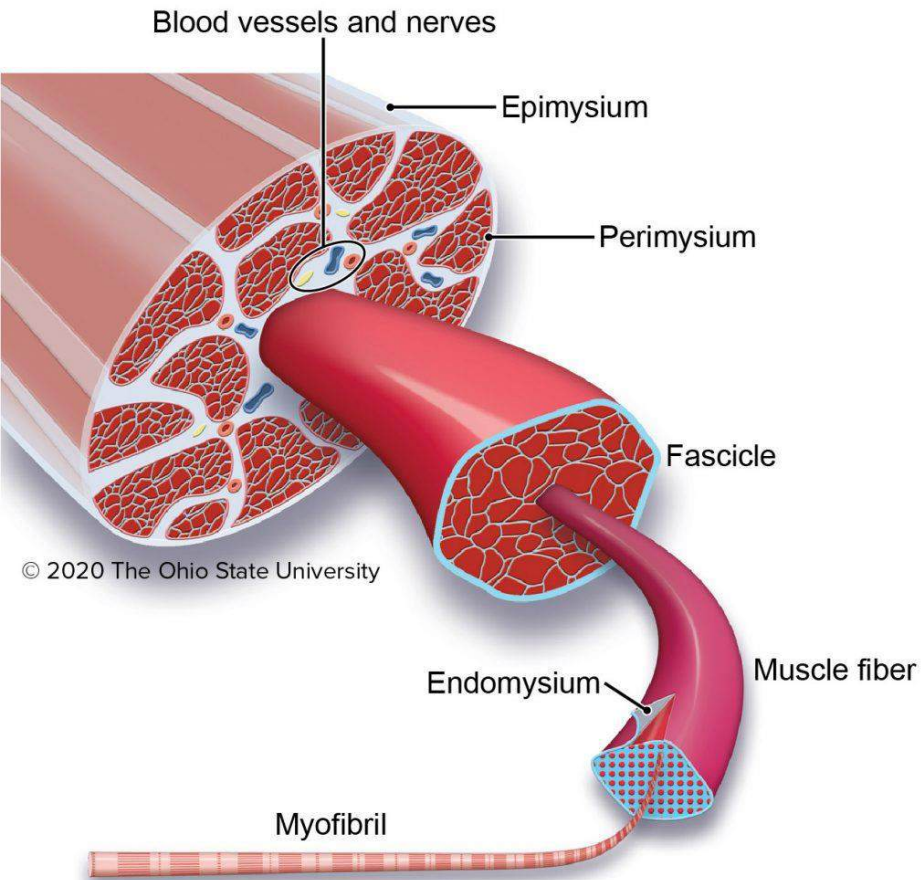


© 2020 The Ohio State University

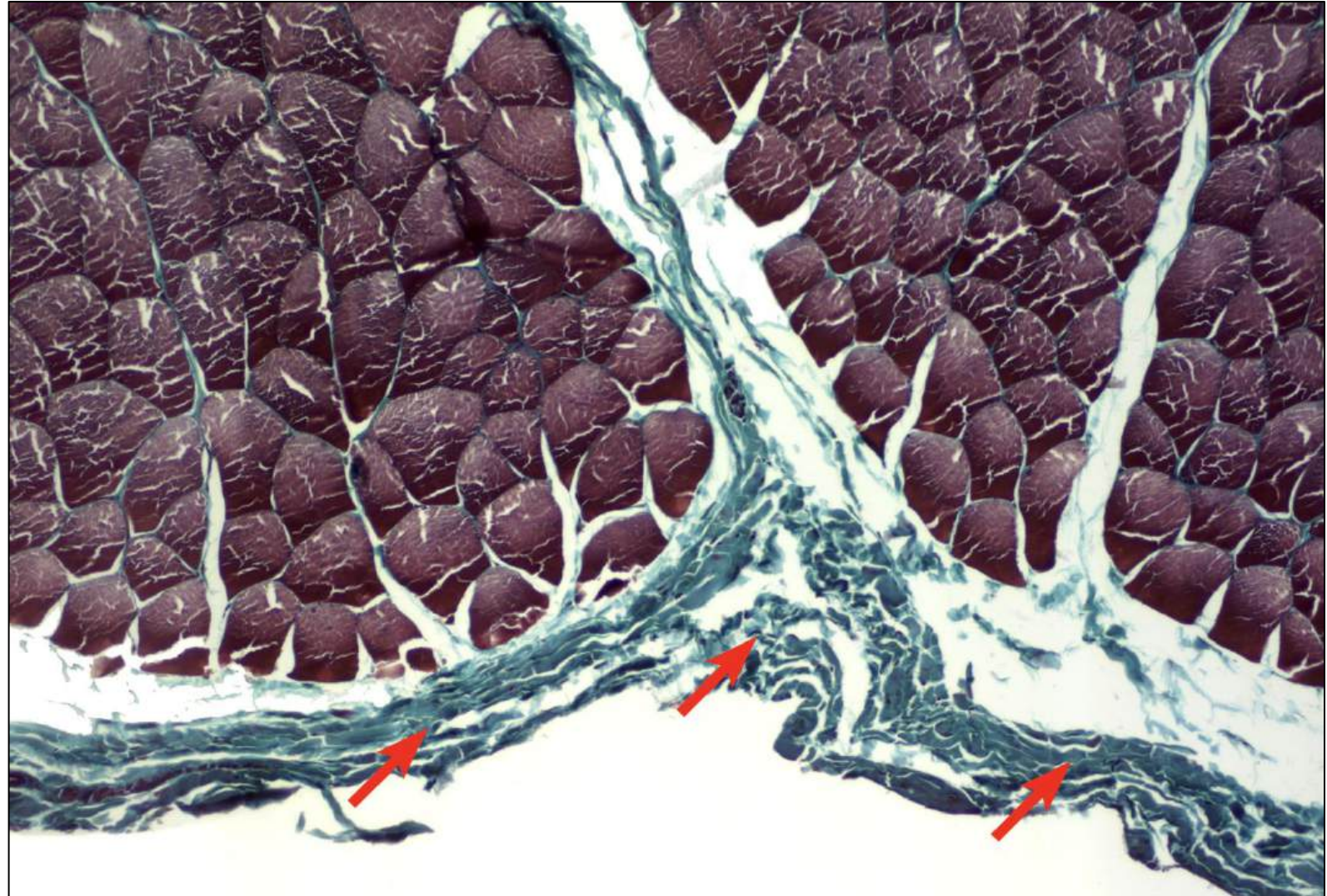
Ref. 8



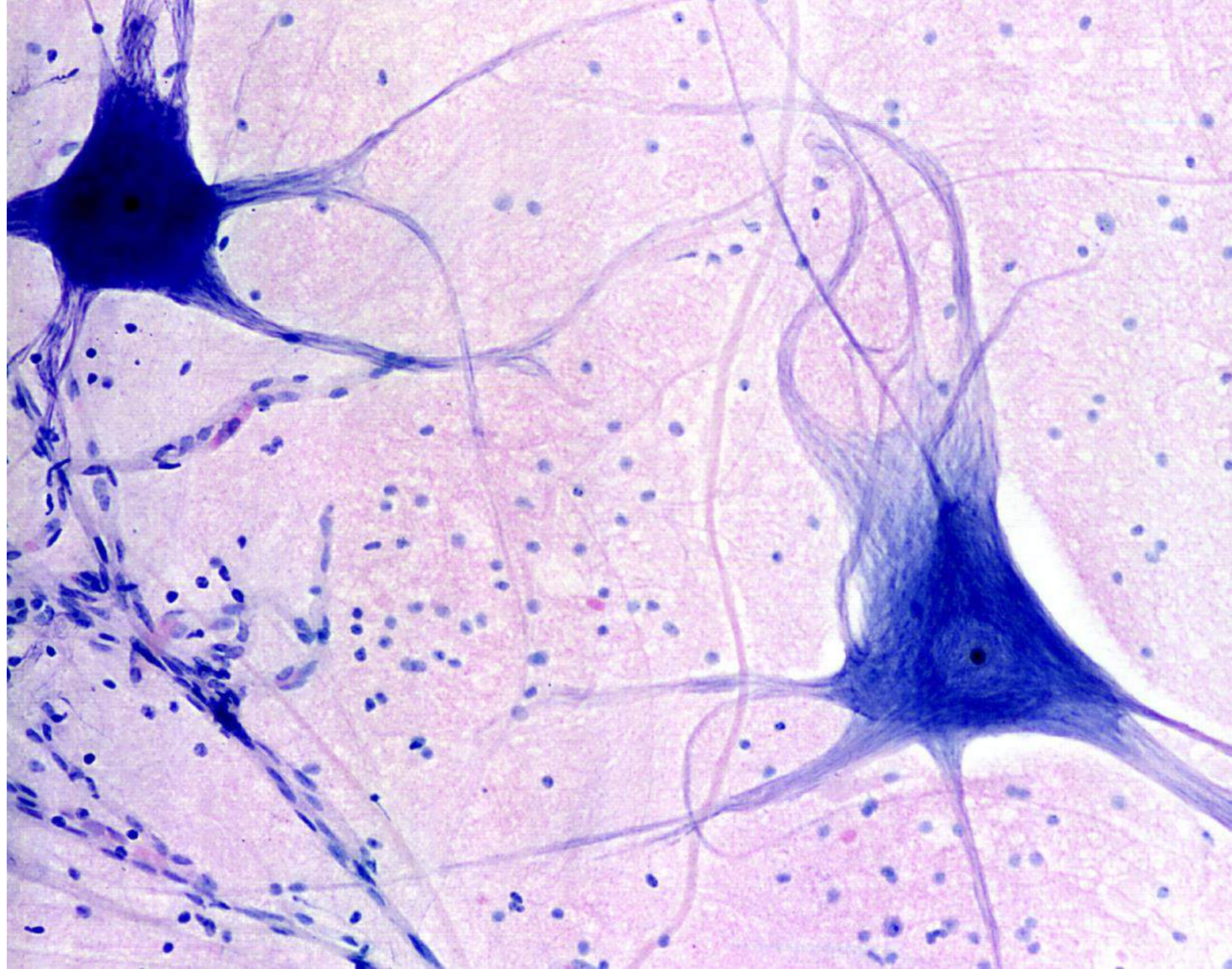
Connective Tissue of Muscle - Epimysium



Ref. 8

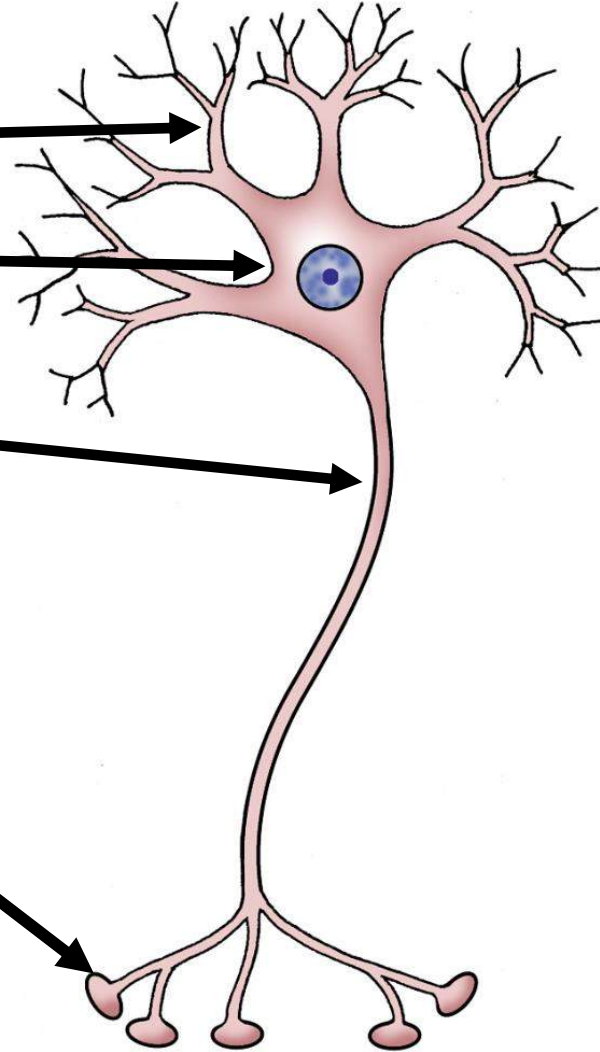


Nervous Tissue

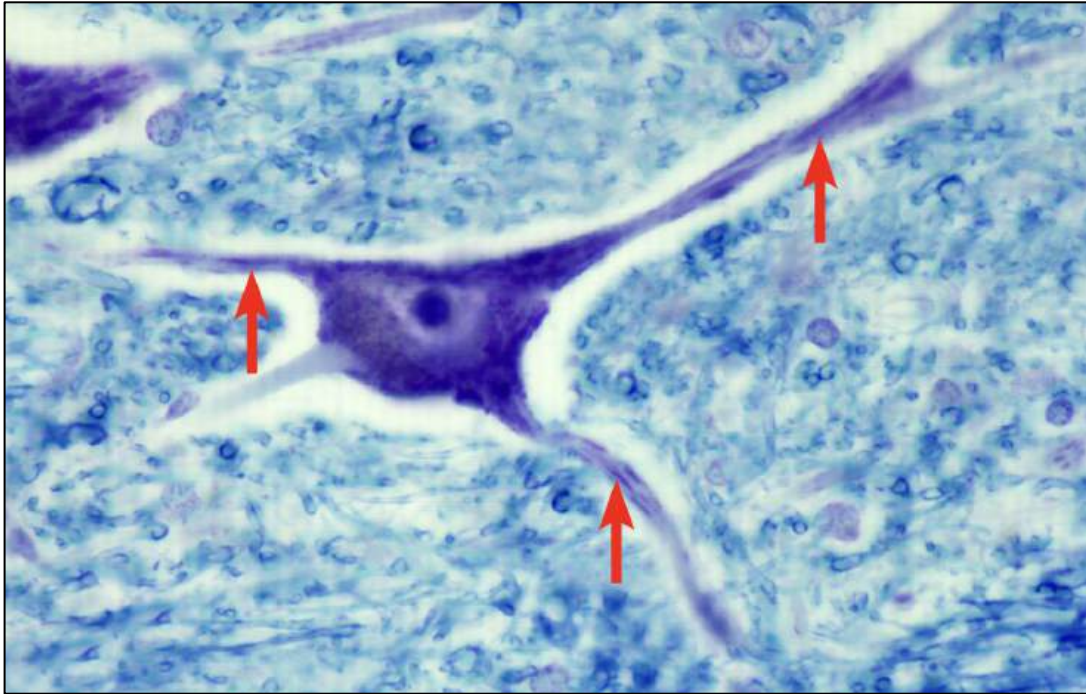


Parts of a Nerve

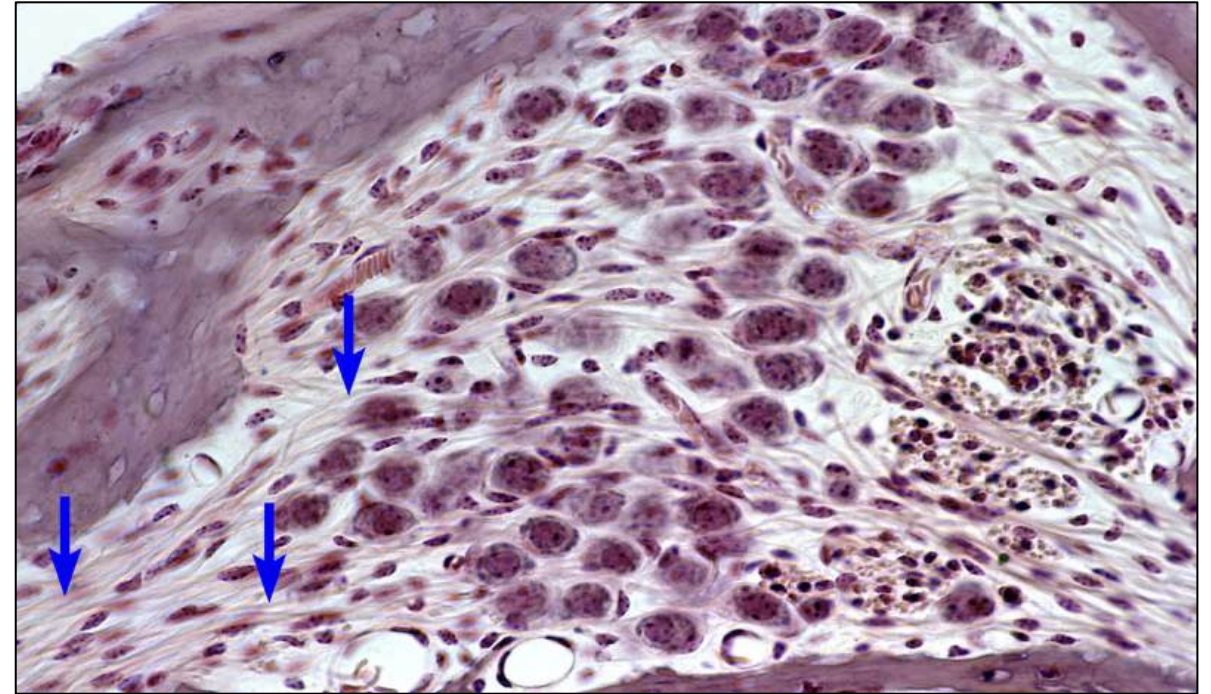
- Dendrite
- Cell Body
- Axon
- Axon Terminal Bulb



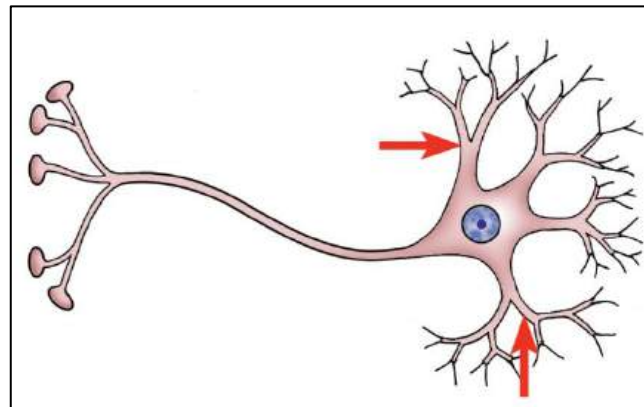
Parts of a Nerve - Dendrite



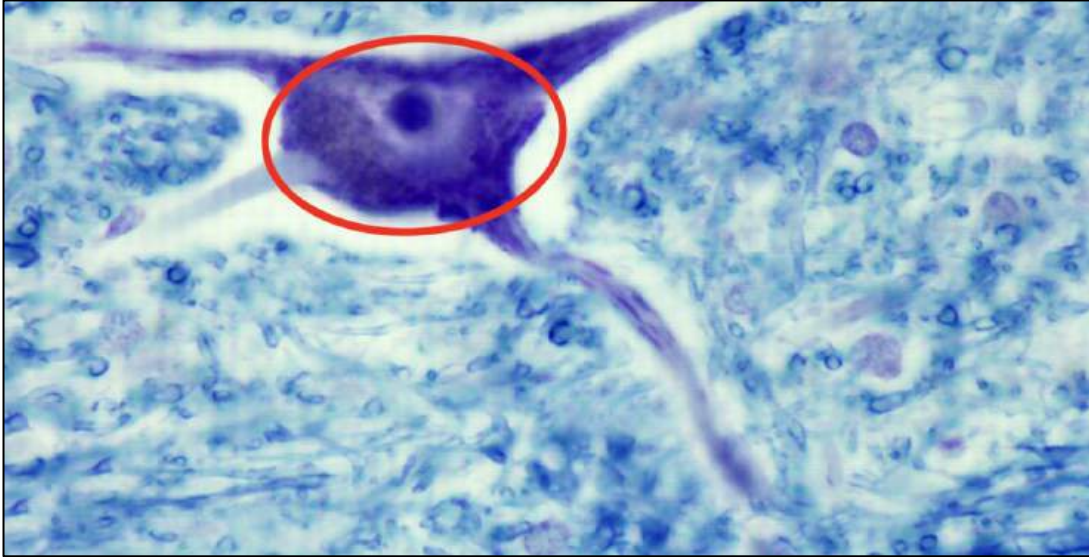
Multipolar Neuron



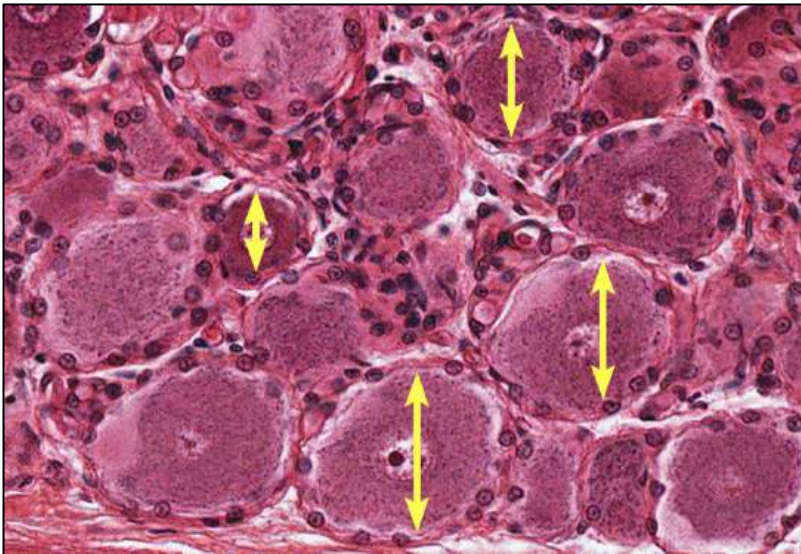
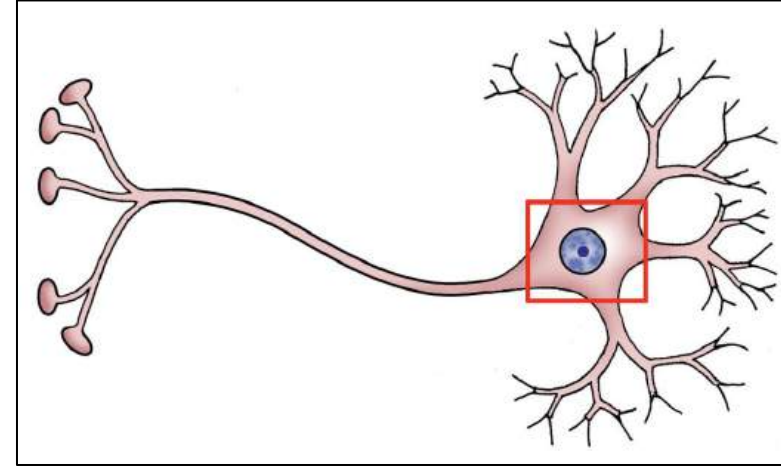
Bipolar Neuron



Parts of a Nerve – Cell Body

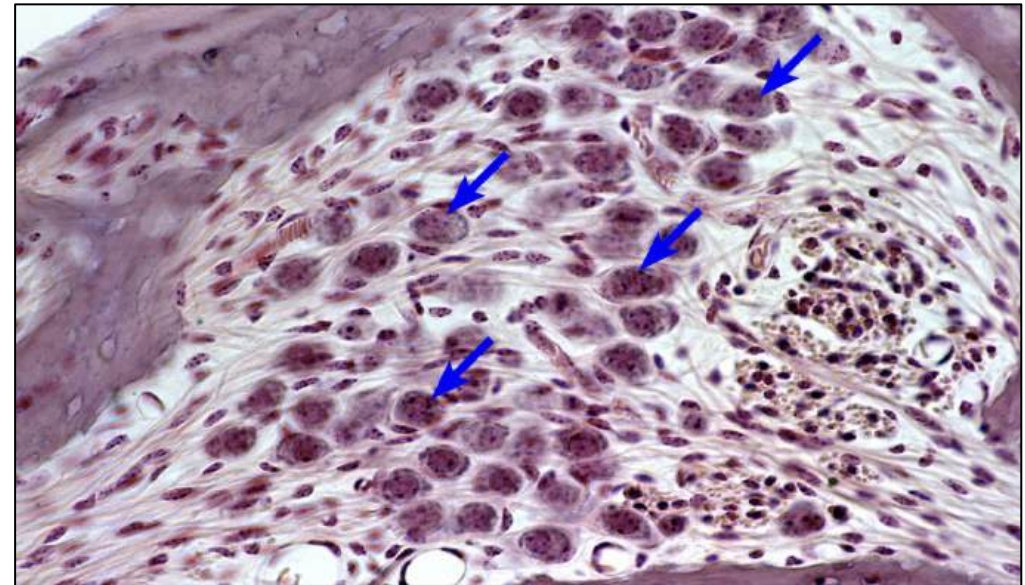


Multipolar Neuron

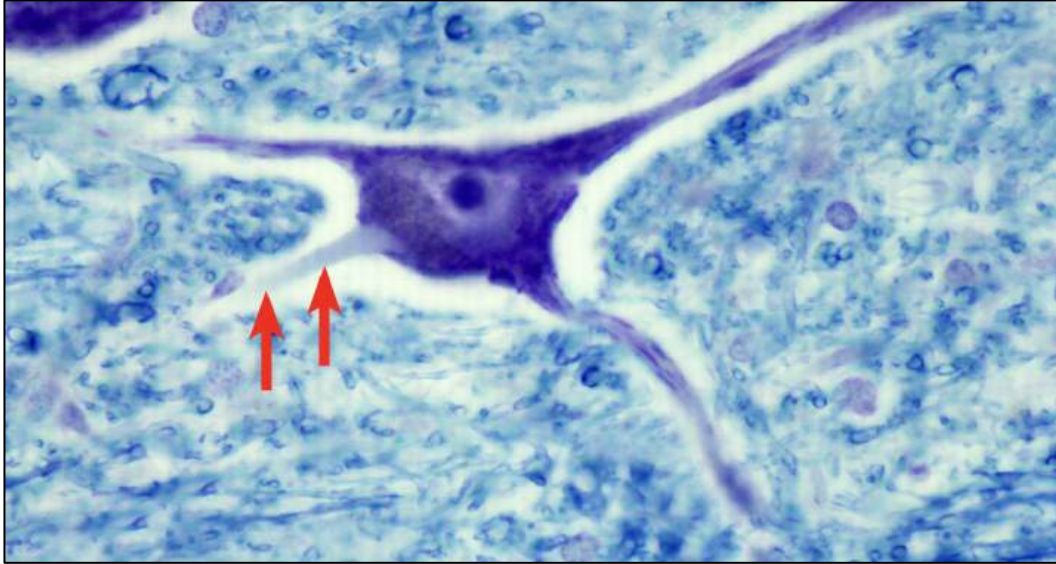


Pseudounipolar Neuron

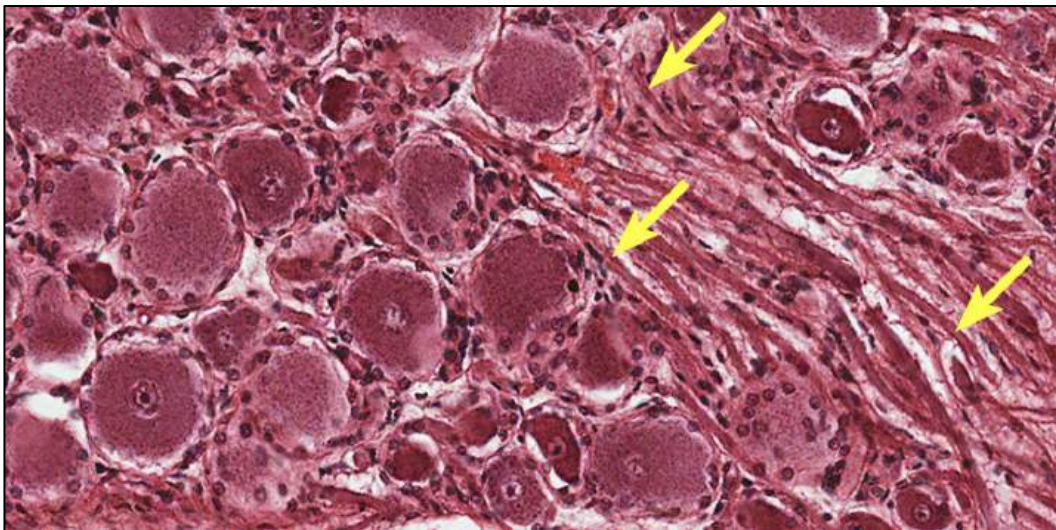
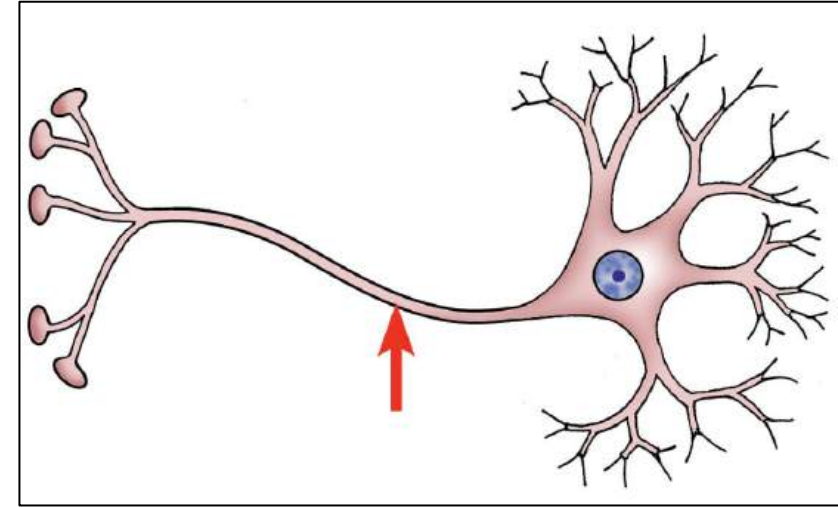
Bipolar Neuron



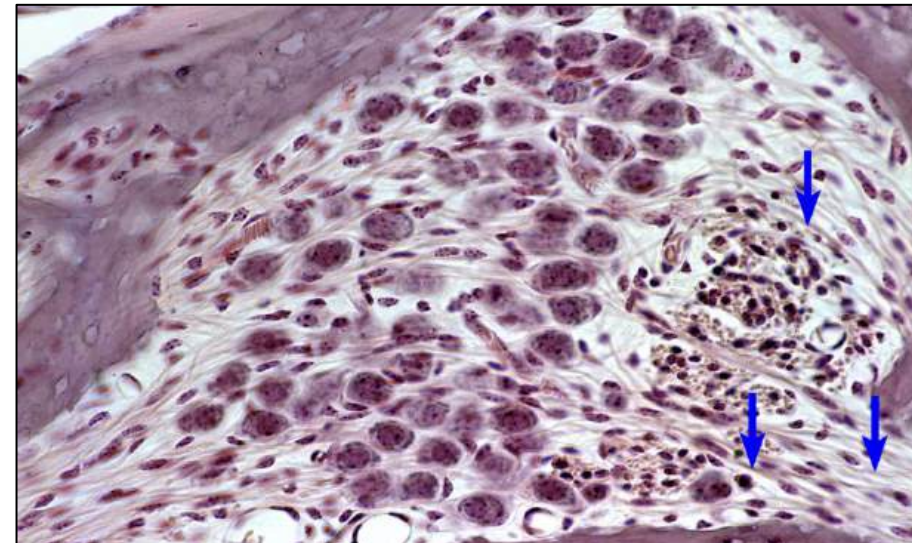
Parts of a Nerve - Axon



Multipolar Neuron



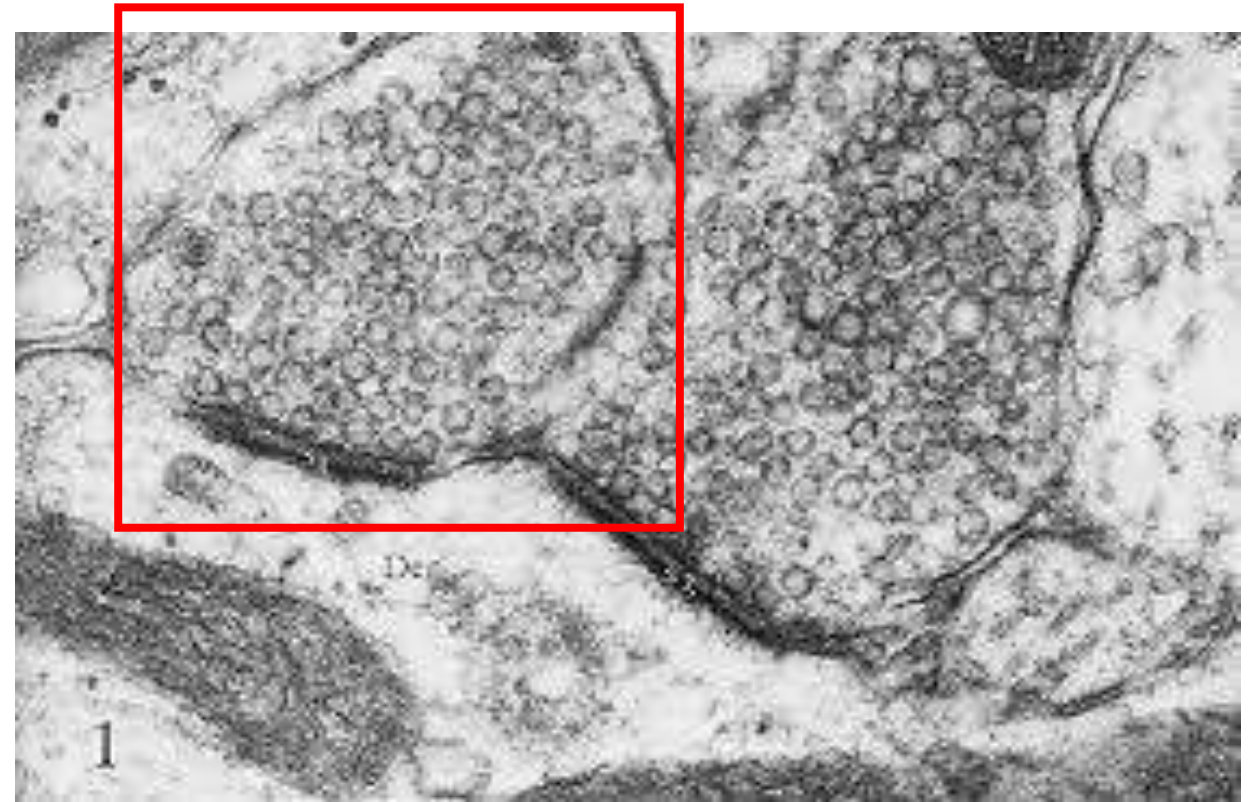
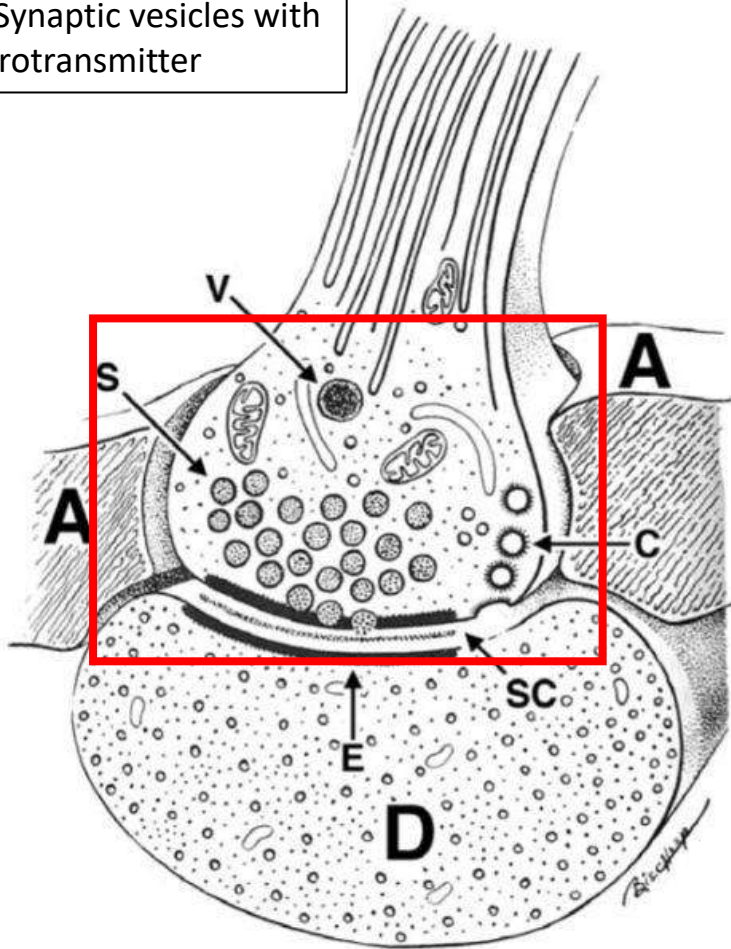
Pseudounipolar Neuron



Bipolar Neuron

Parts of a Nerve – Axon Terminal Bulb

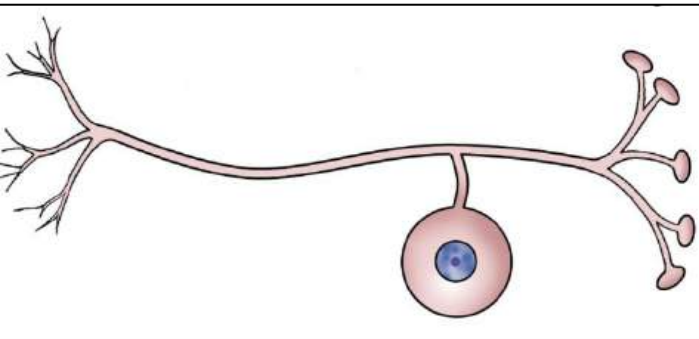
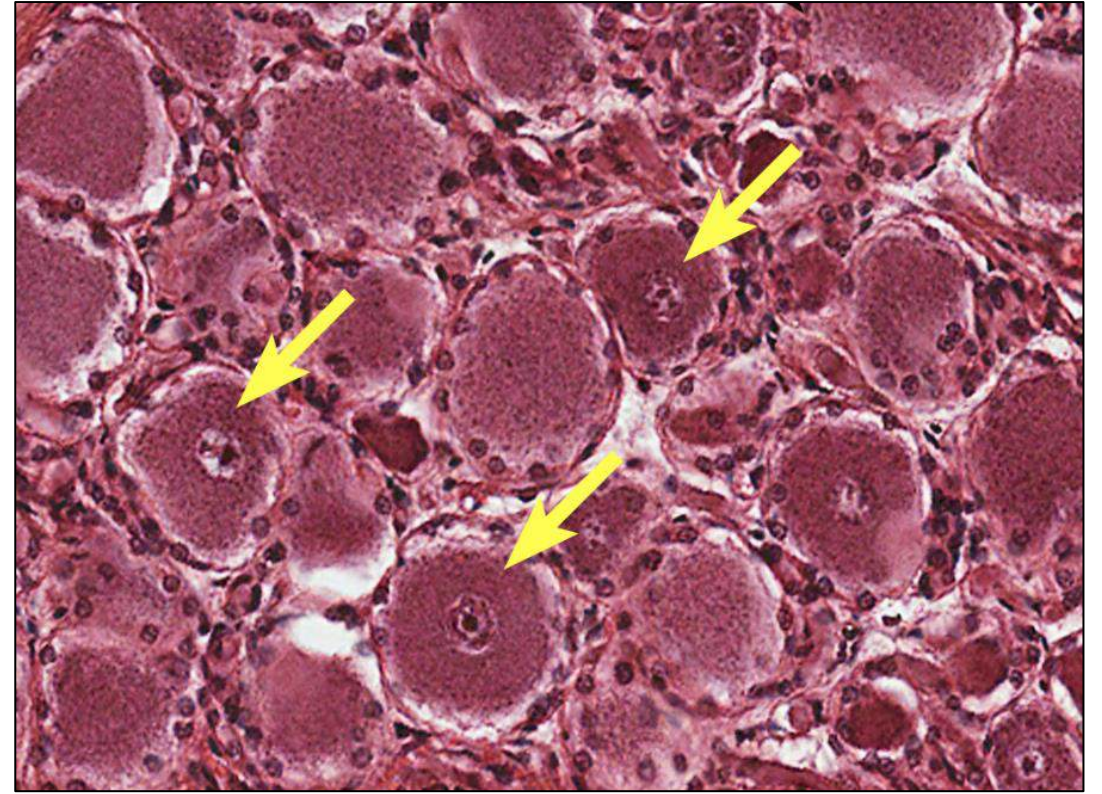
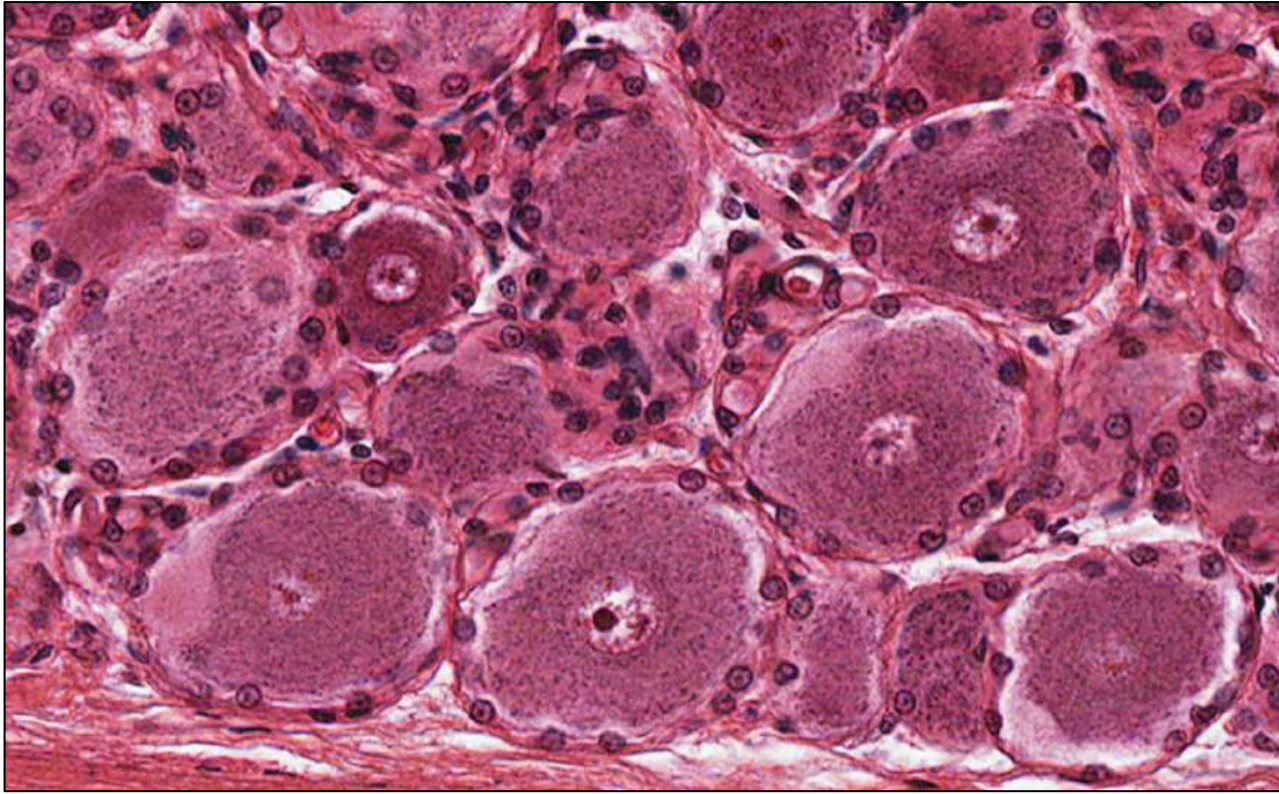
S = Synaptic vesicles with neurotransmitter



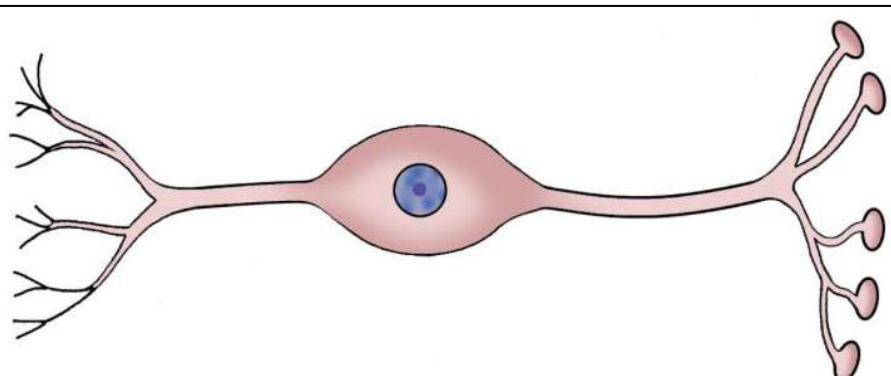
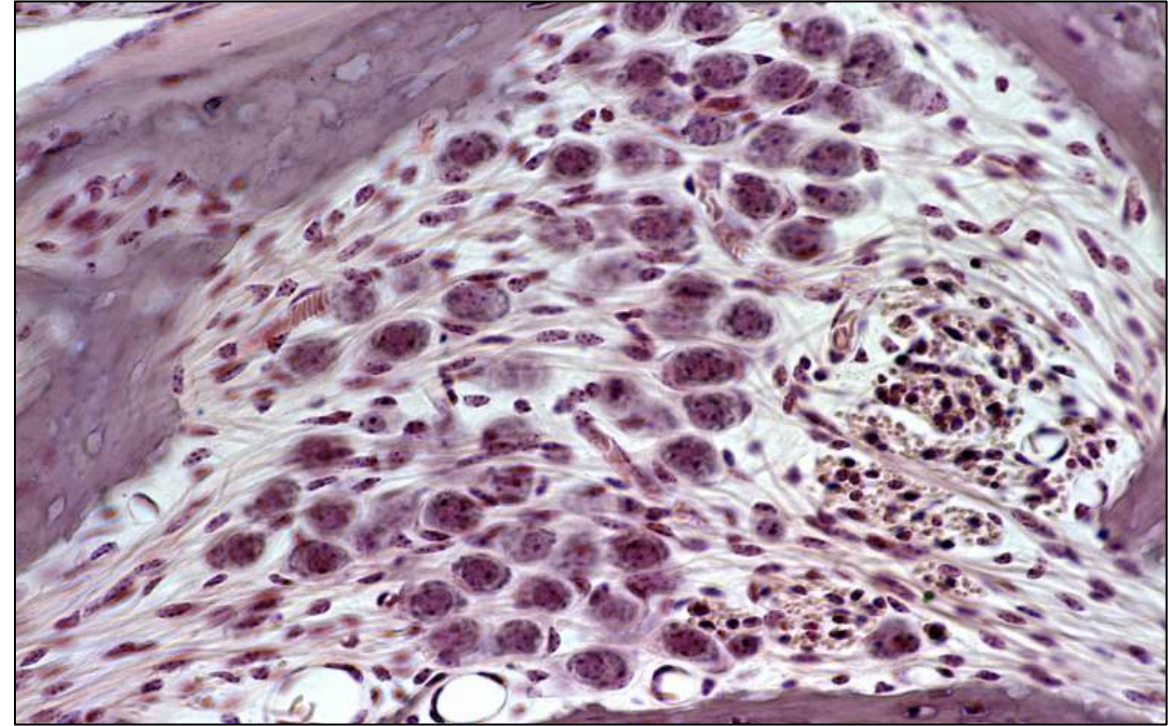
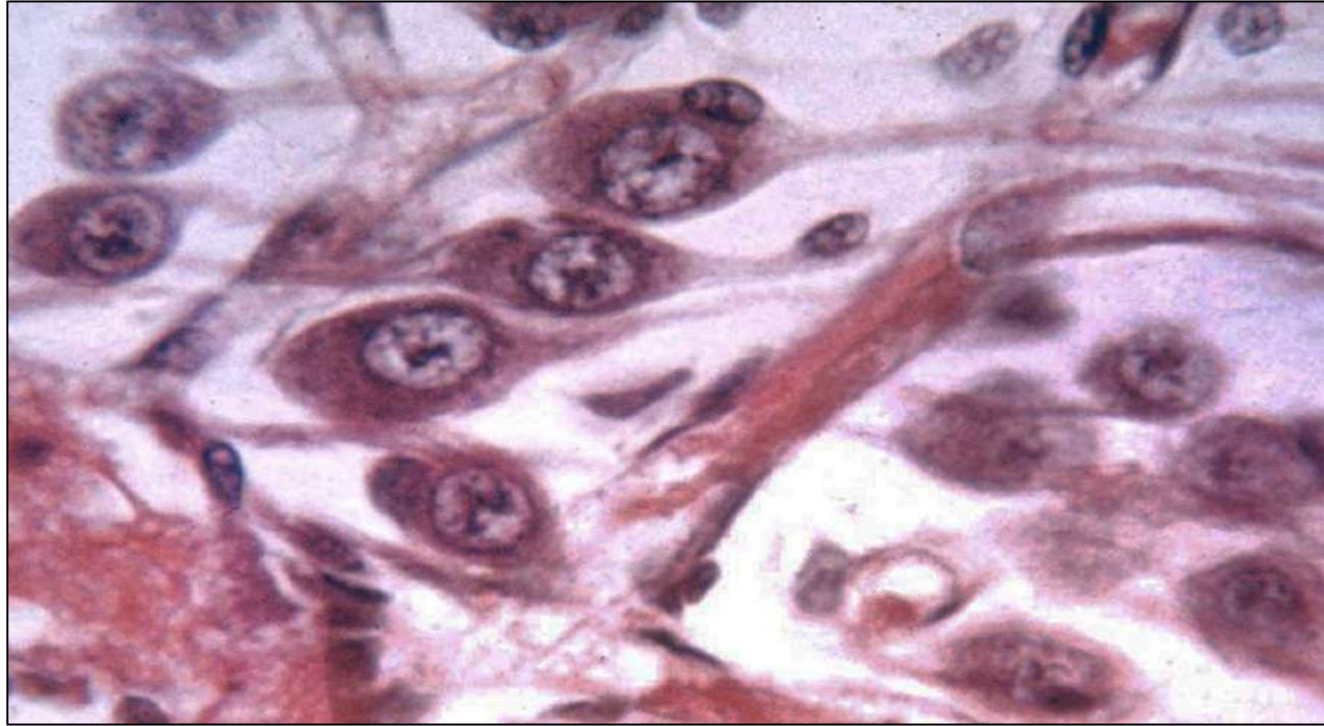
Types of Neurons

- Pseudounipolar
- Bipolar
- Multipolar

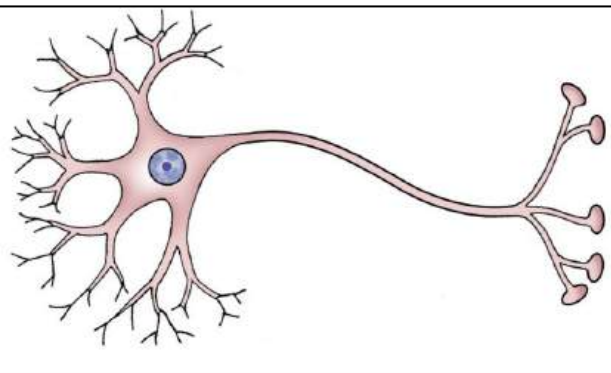
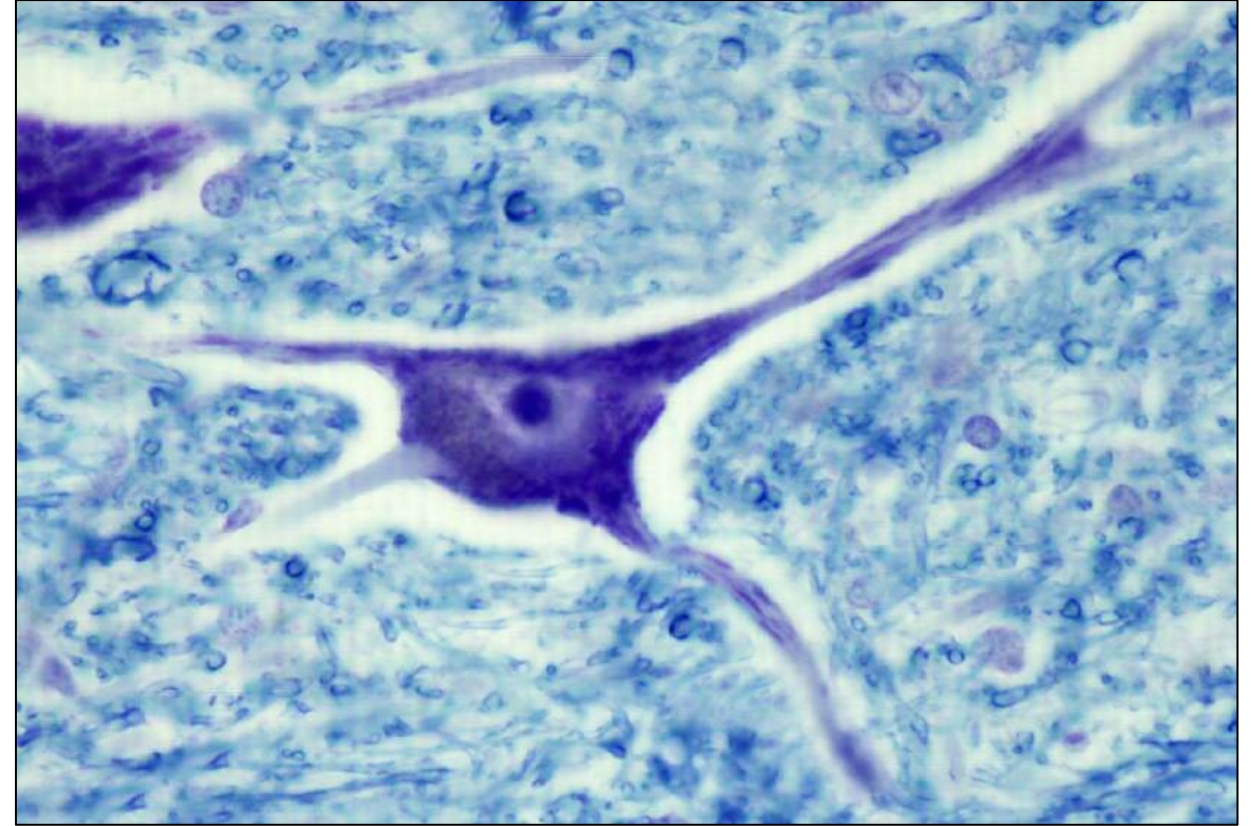
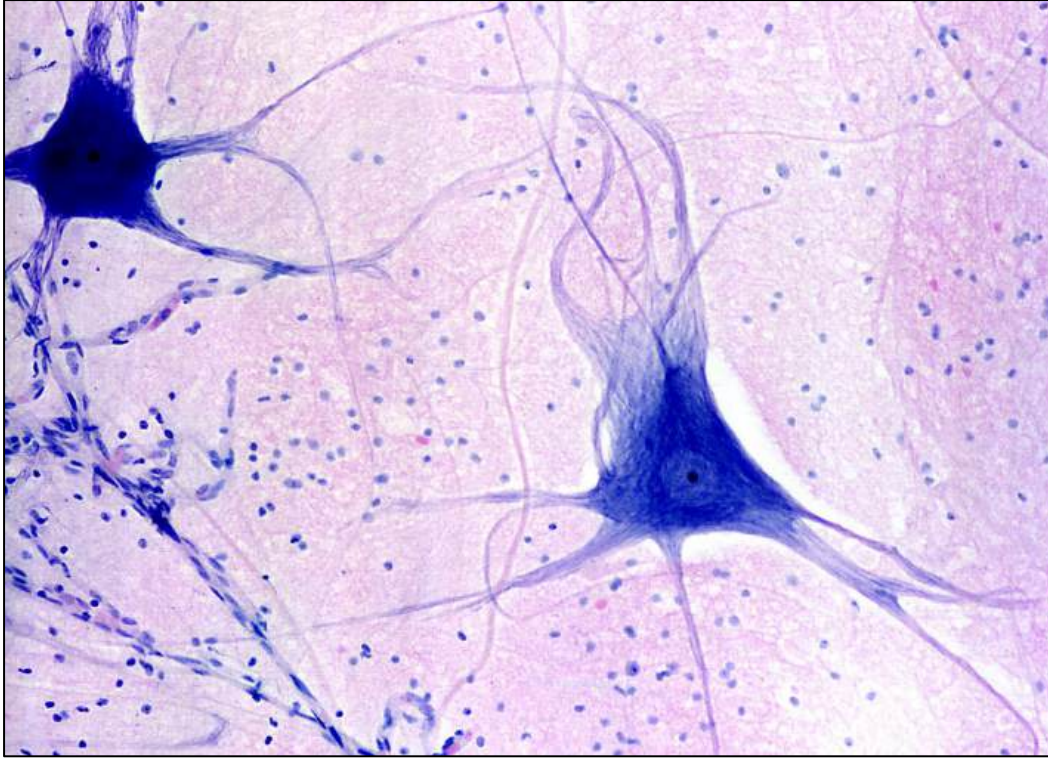
Types of Neurons - Pseudounipolar



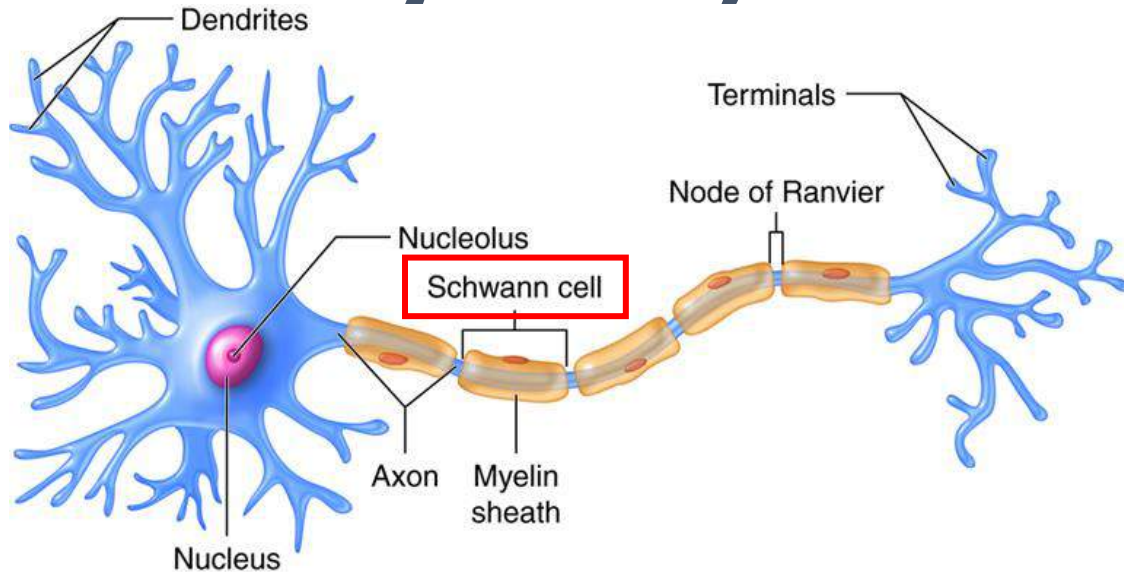
Types of Neurons - Bipolar



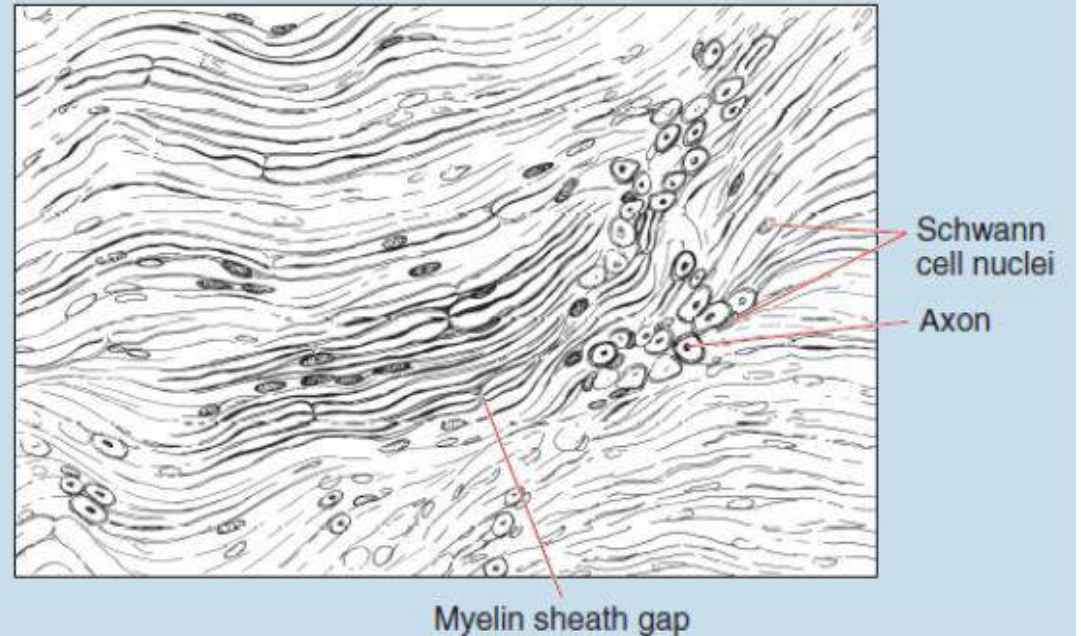
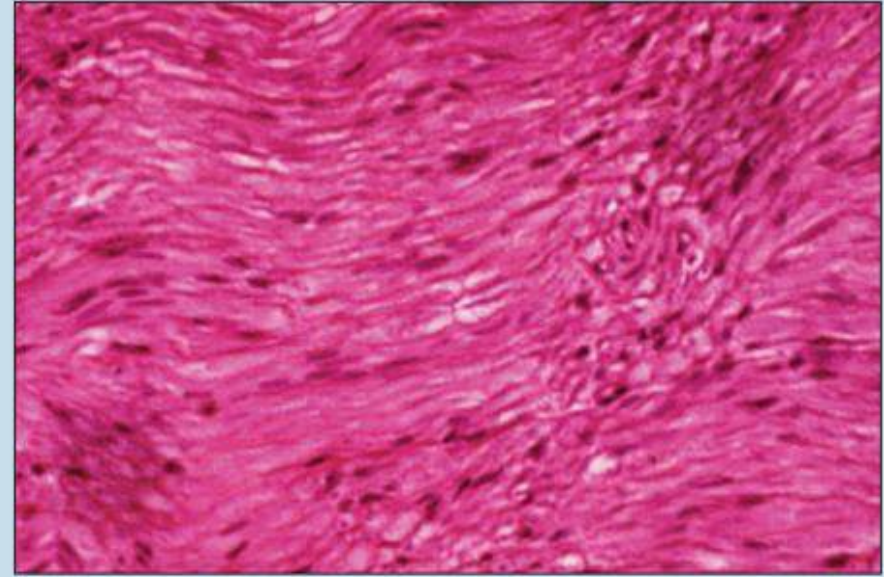
Types of Neurons - Multipolar



Myelin-Producing Cell Types – Schwann Cells (found in the Peripheral Nervous System)

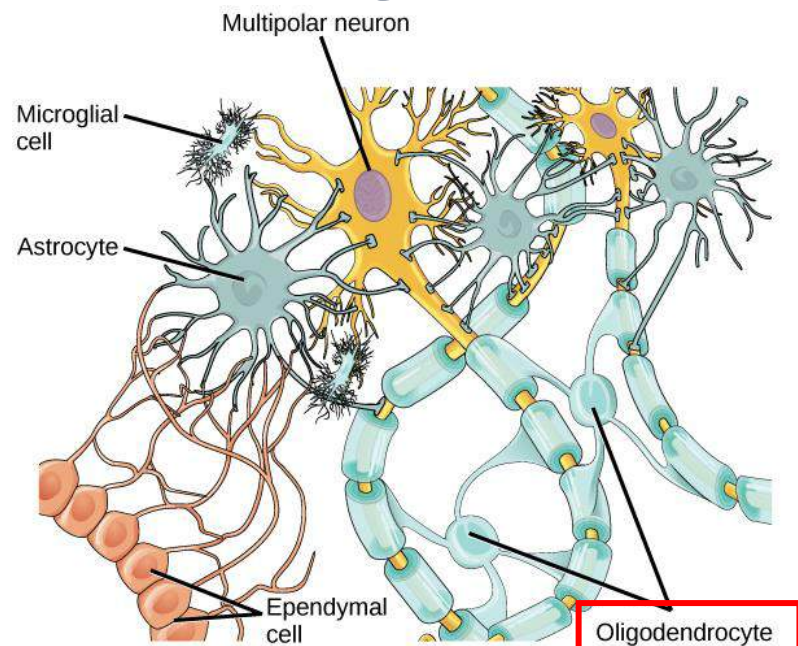


Ref. 9



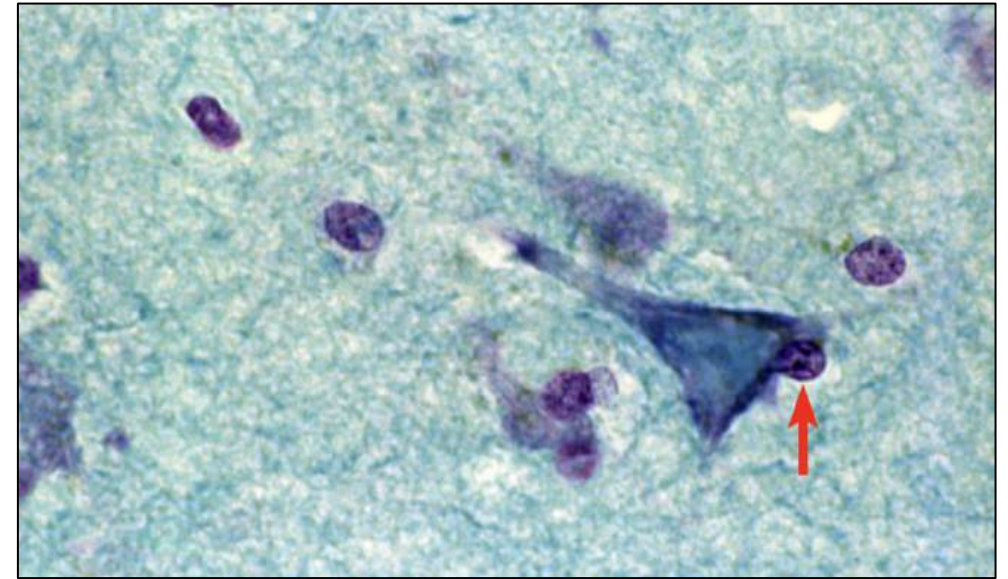
Ref. 10

Myelin-Producing Cell Types – Oligodendrocytes (found in the Central Nervous System)

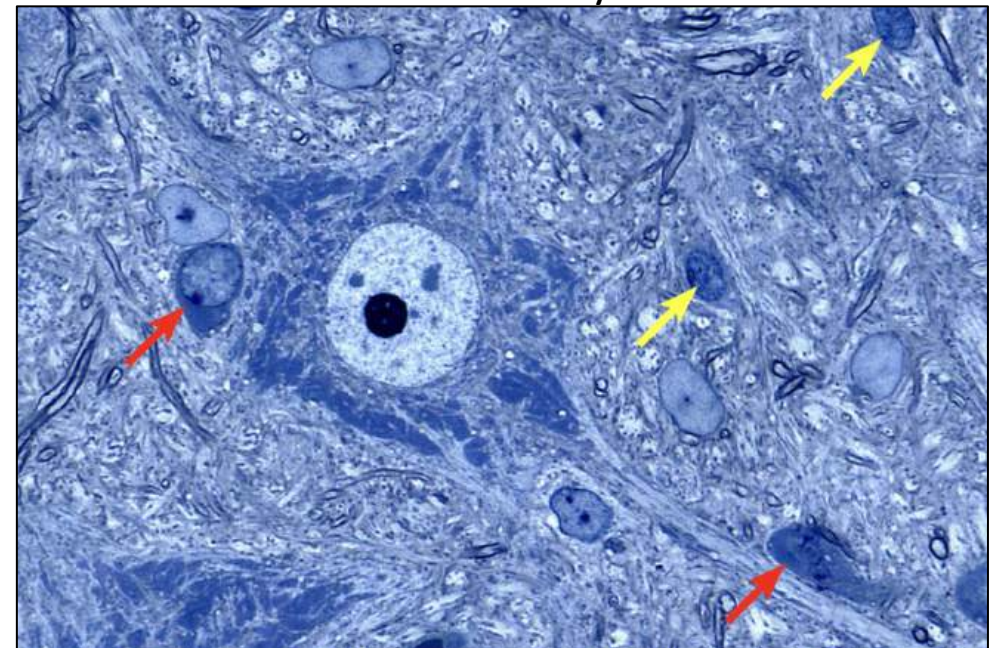


(a) Central nervous system

Ref. 11



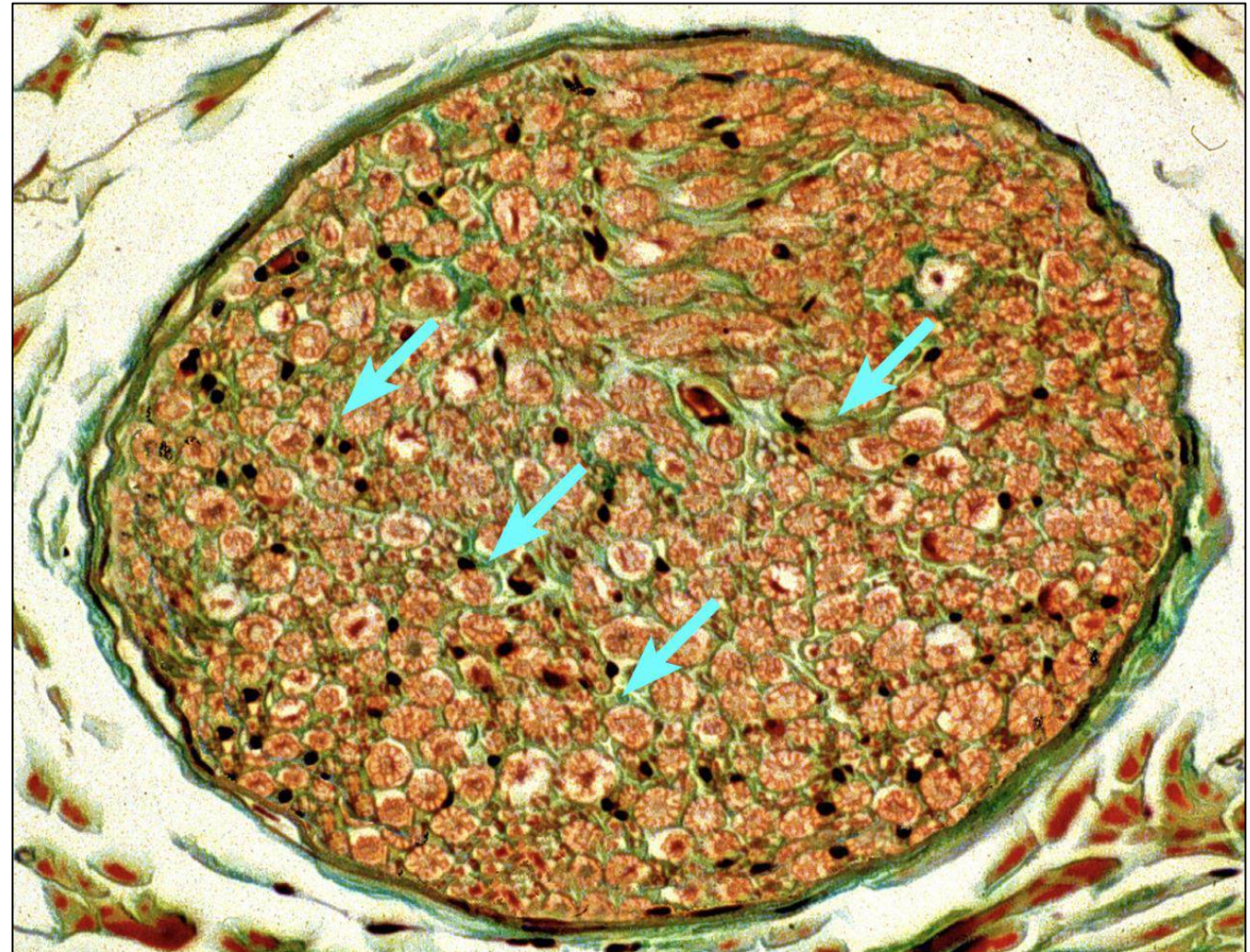
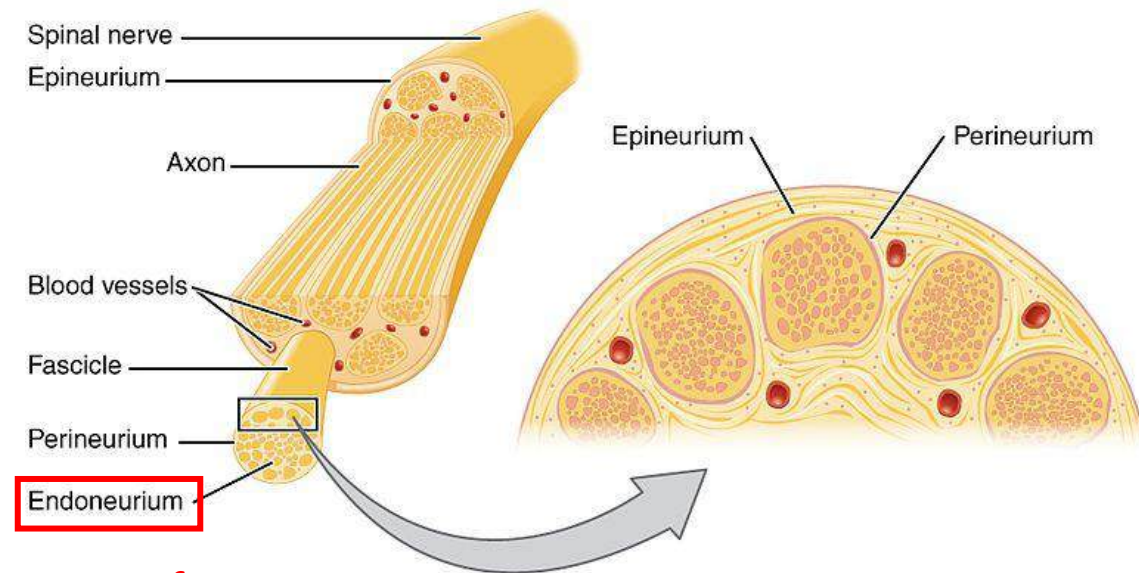
Do not worry about arrow color



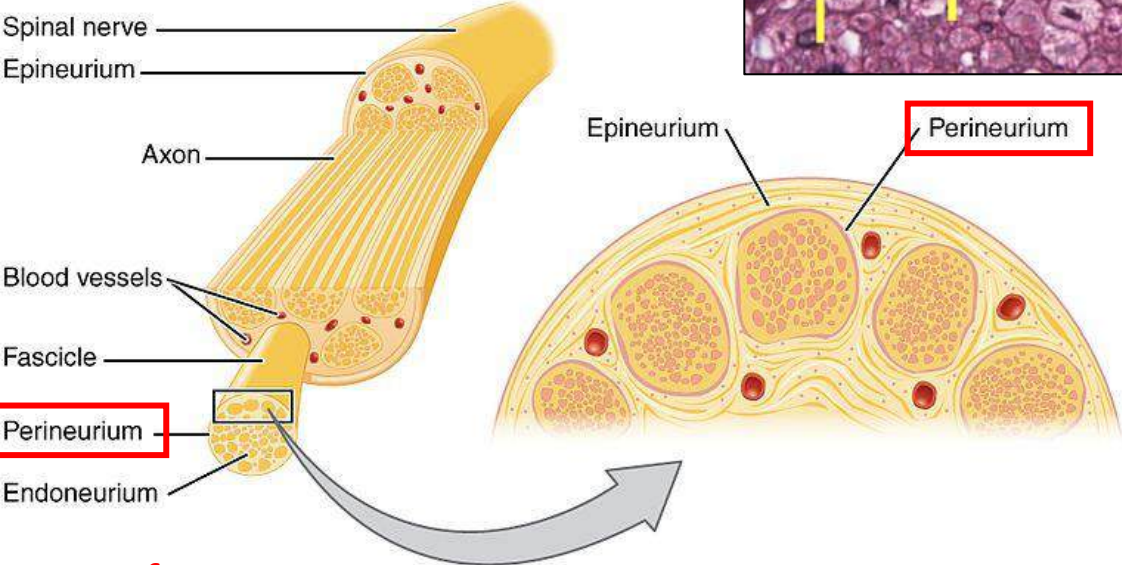
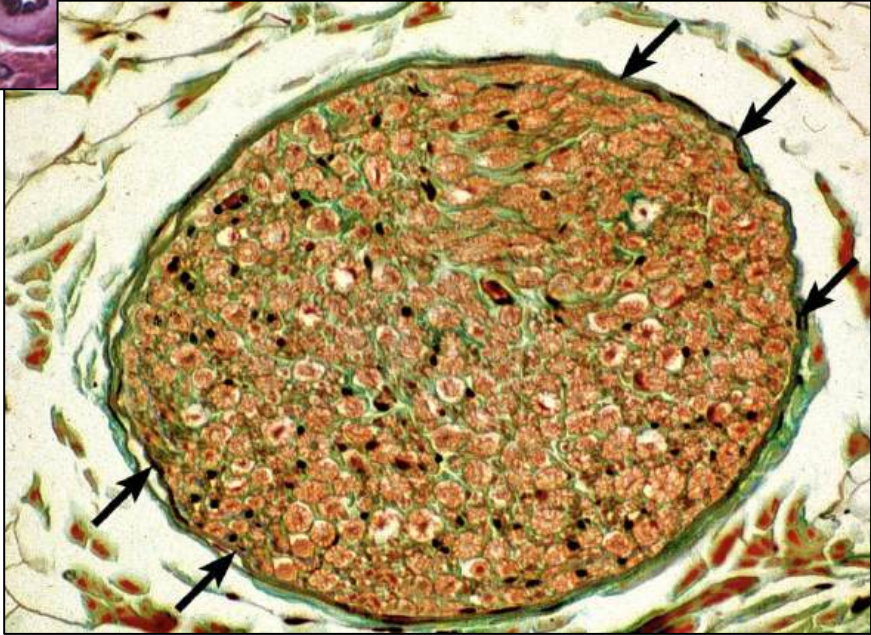
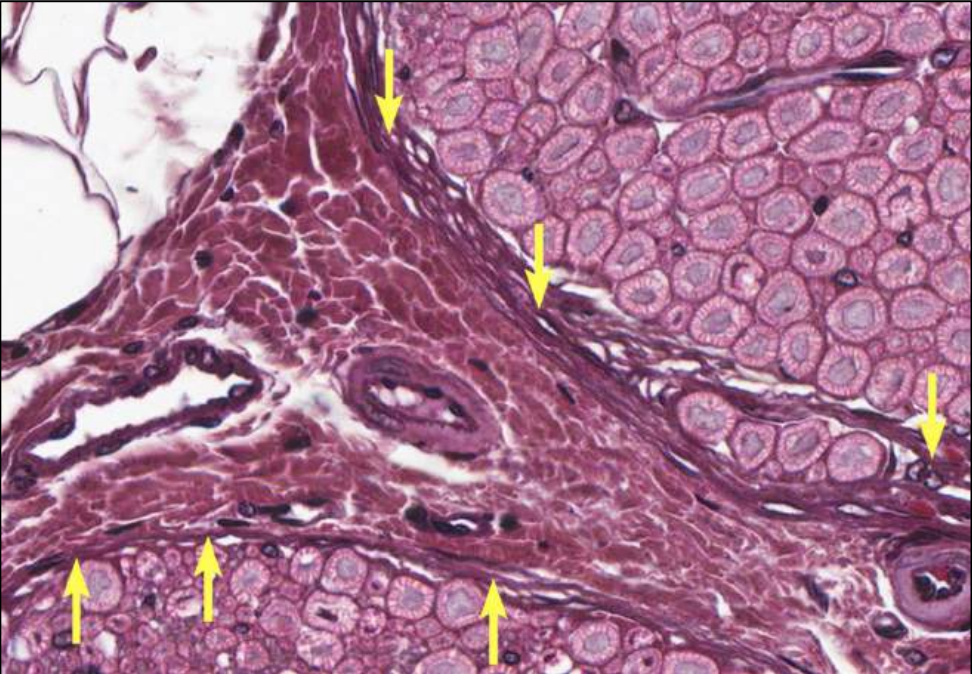
Connective Tissue of Nerves

- Endoneurium – covers an axon
- Perineurium – covers a nerve fascicle
- Epineurium – covers a nerve

Connective Tissue of Nerves - Endoneurium

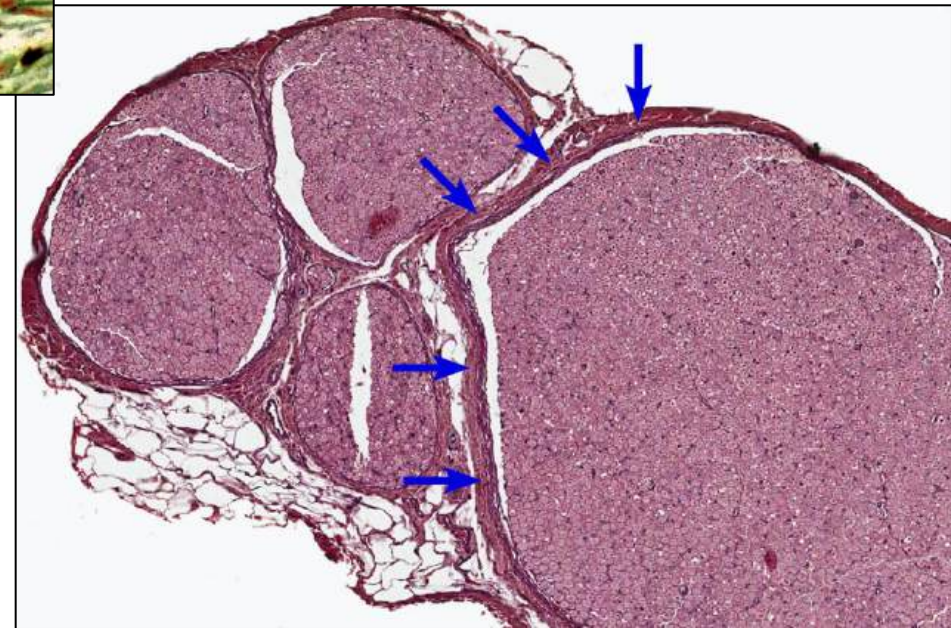
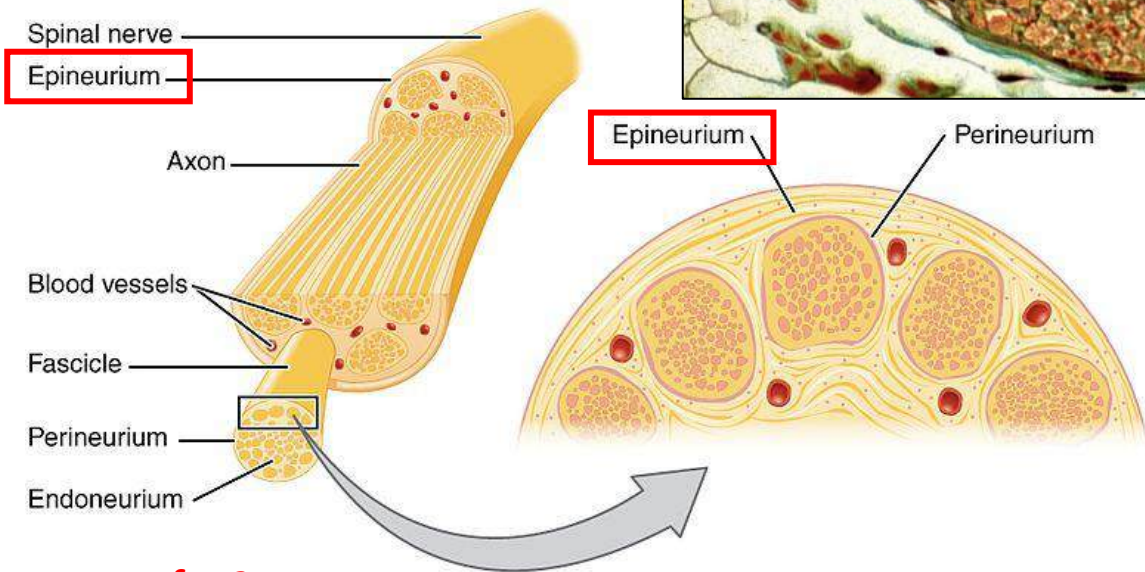
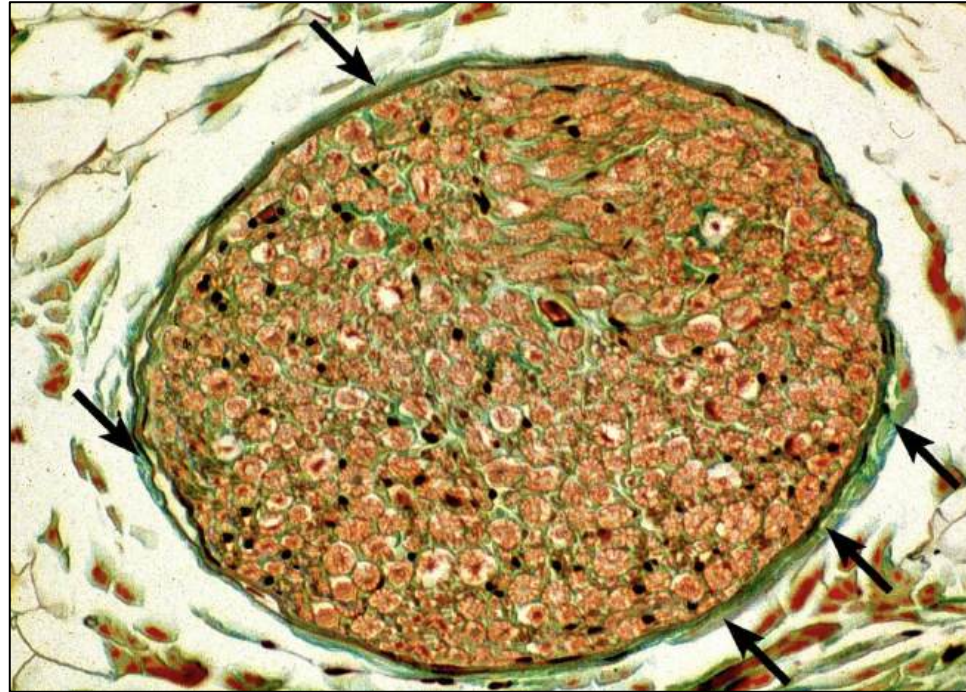


Connective Tissue of Nerves - Perineurium



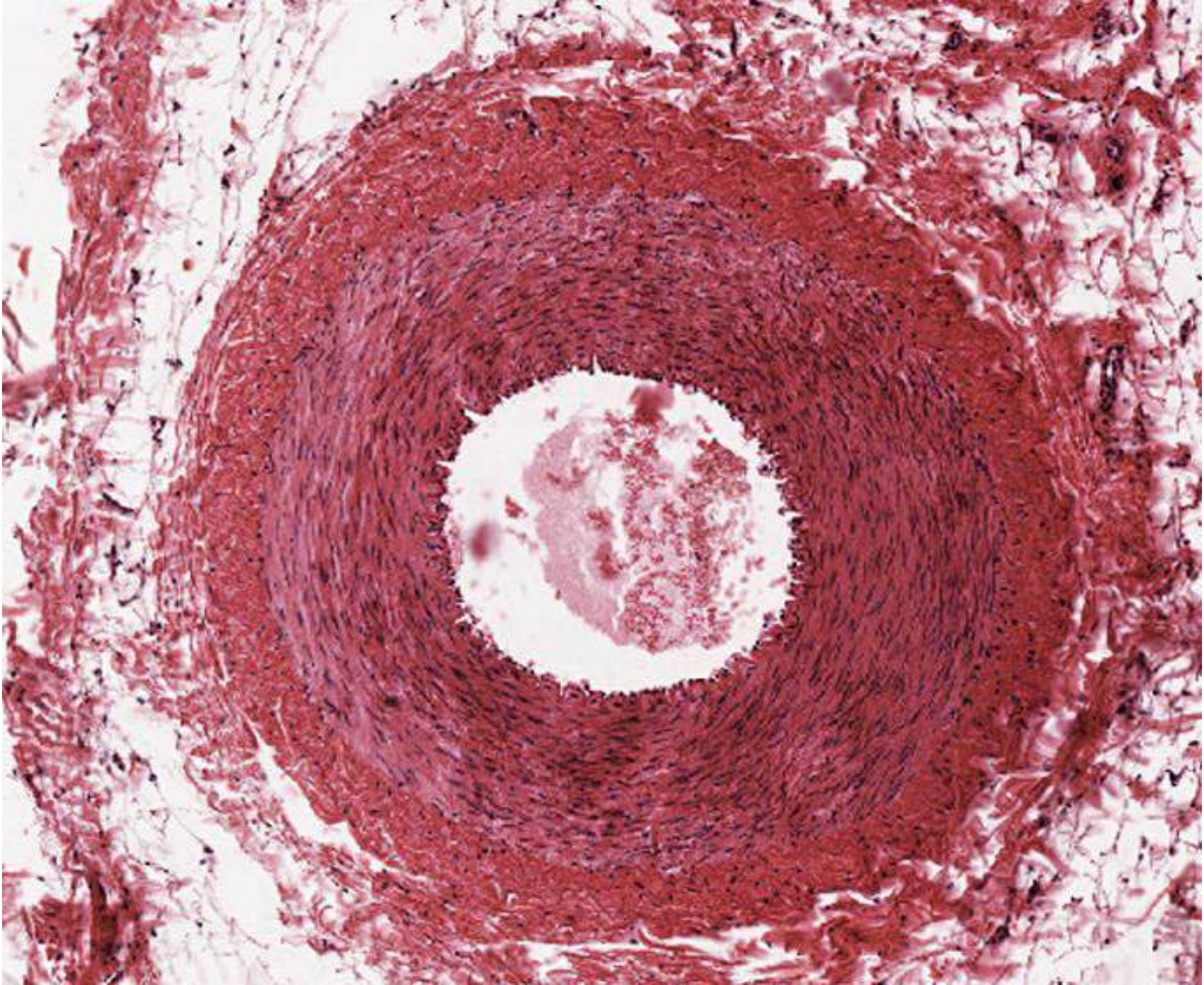
Ref. 12

Connective Tissue of Nerves - Epineurium



Ref. 12

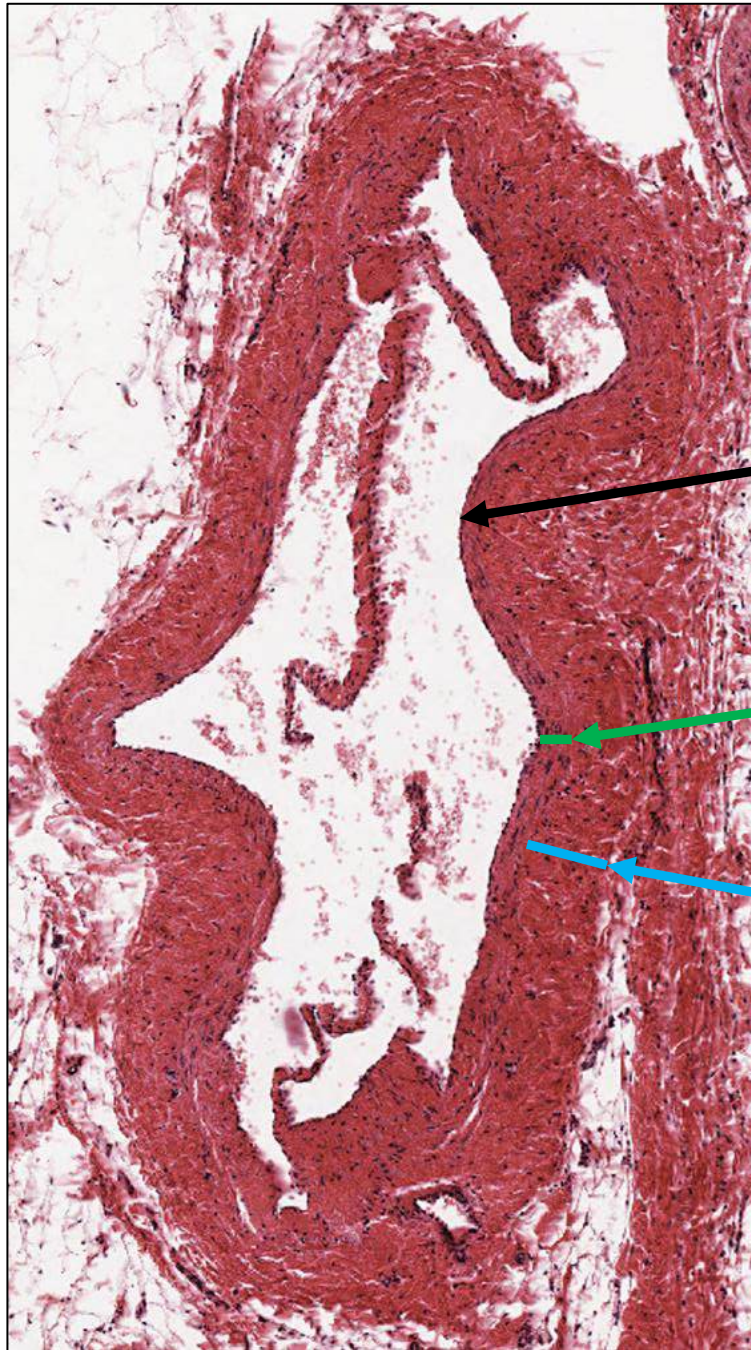
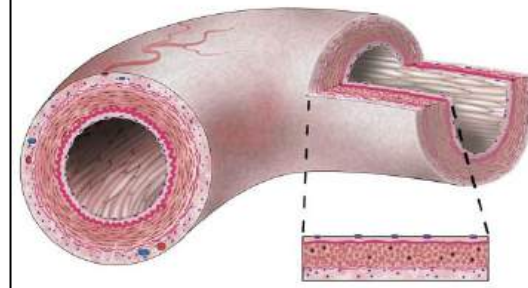
Cardiac & Circulatory System



Layers of a Blood Vessel Wall

- Tunica Externa
- Tunica Media
- Tunica Intima

Blood Vessels

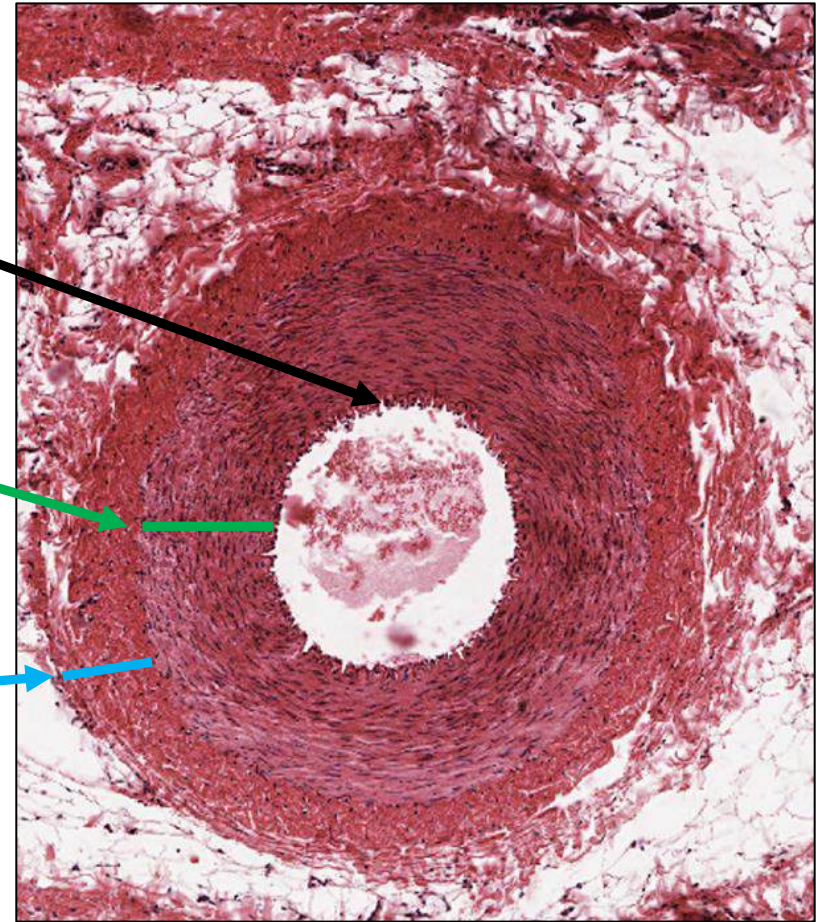


Vein

Tunica Intima

Tunica Media

Tunica Externa

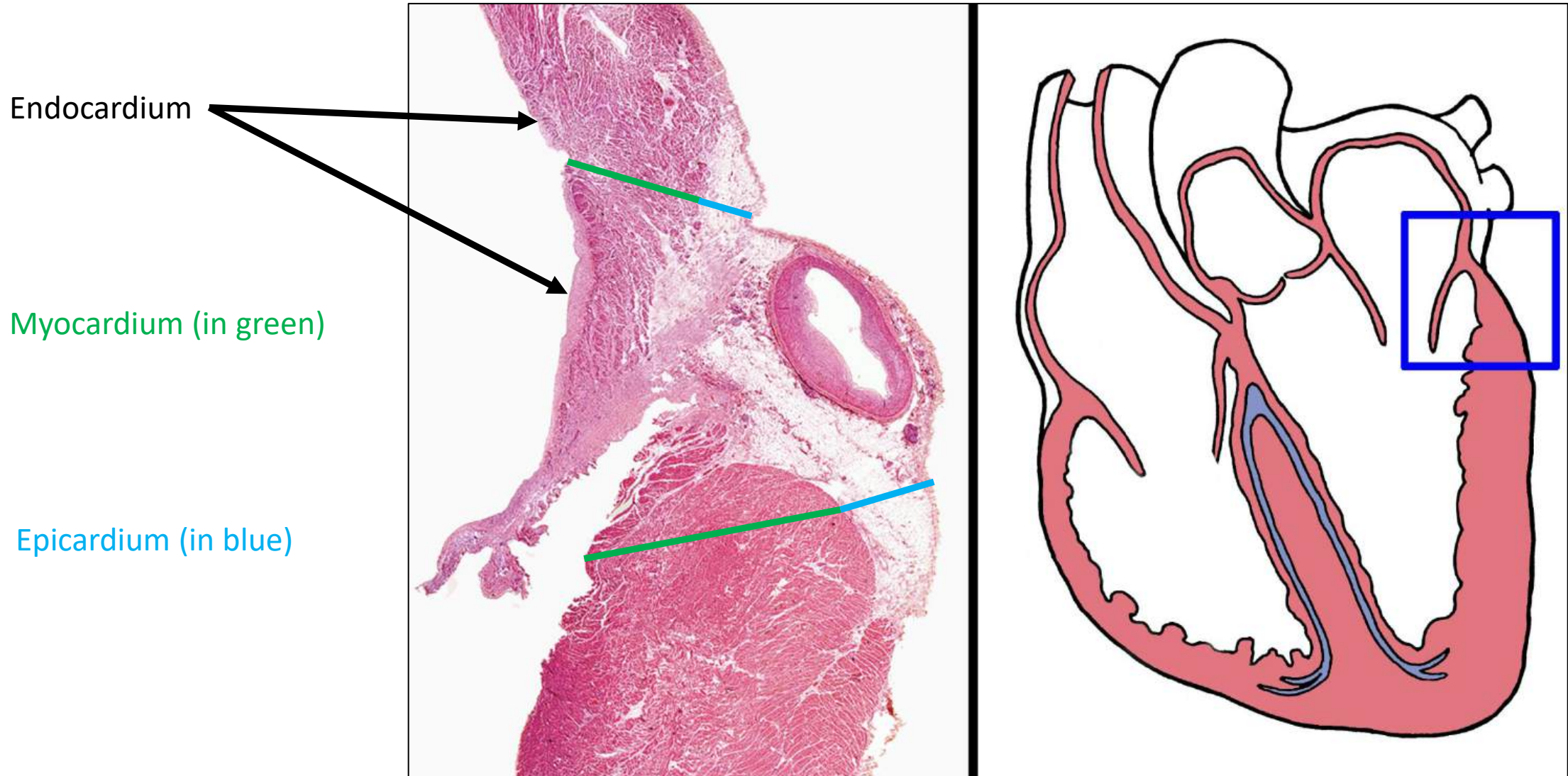


Artery

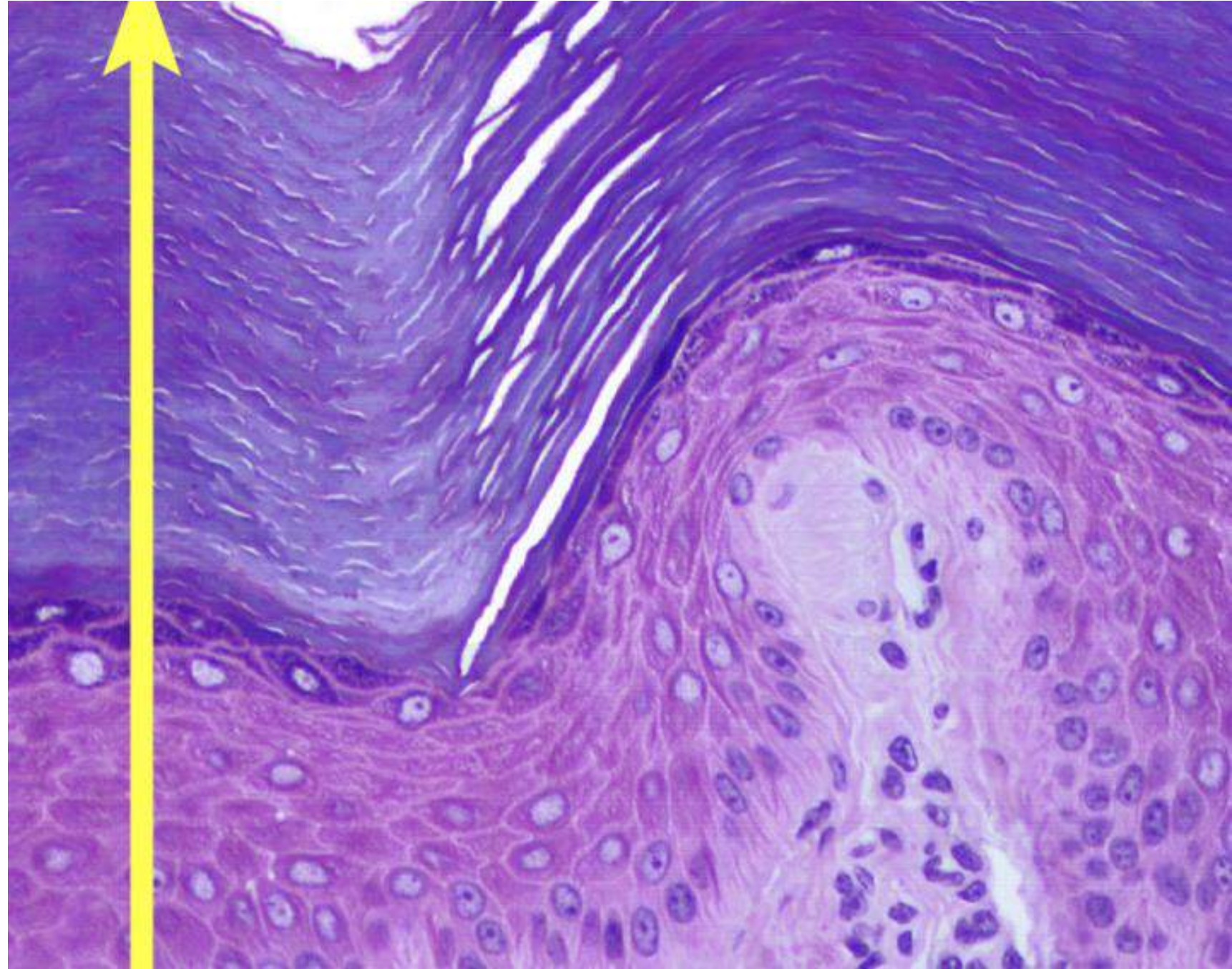
Layers of the Heart

- Epicardium/Visceral Layer of Pericardium
- Myocardium
- Endocardium

Layers of the Heart



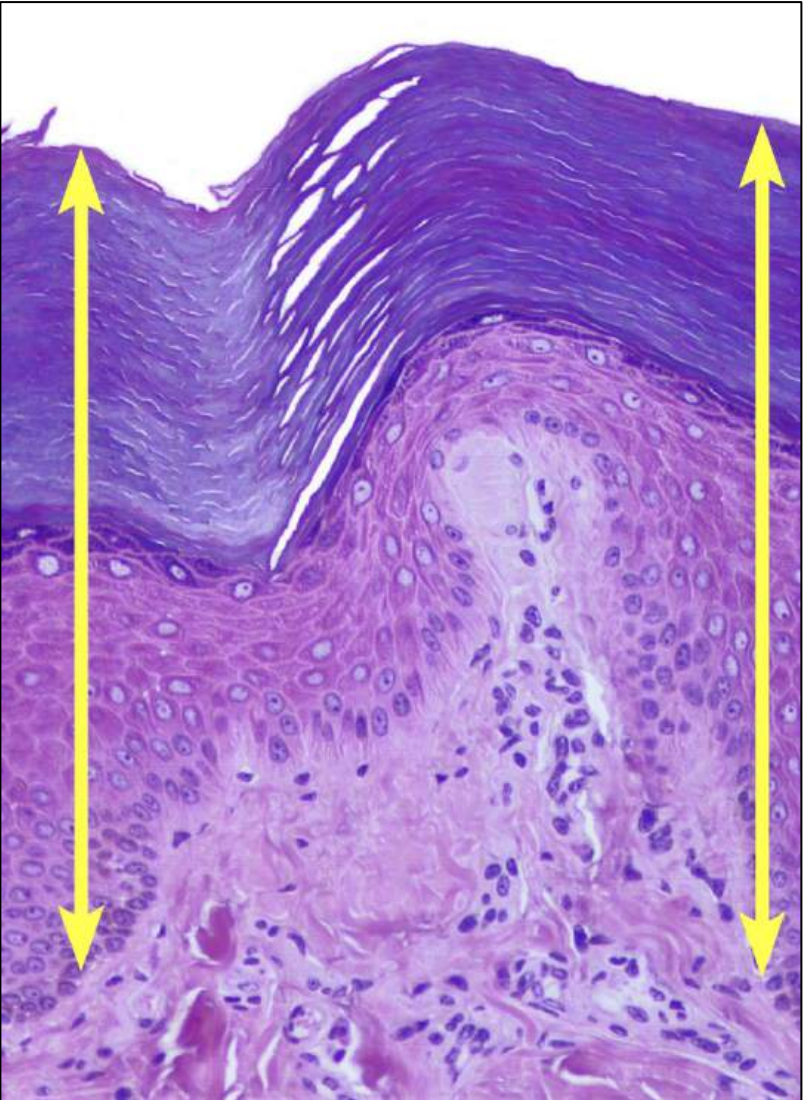
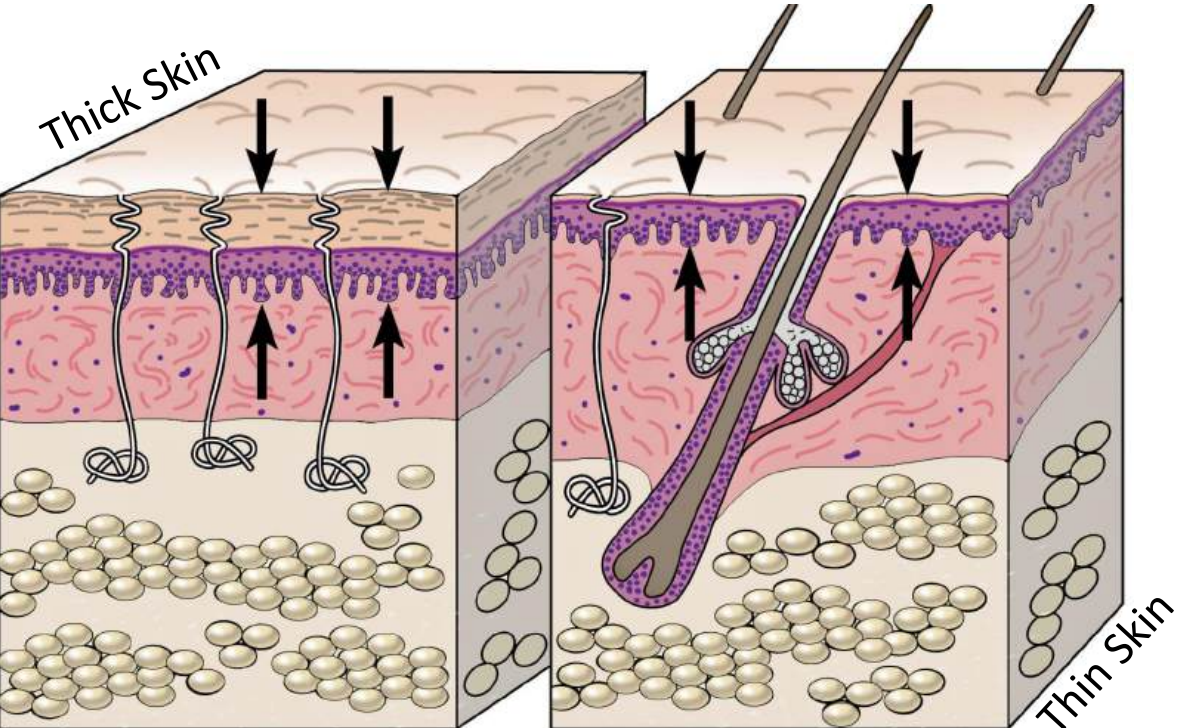
Integumentary System



Layers of the Skin

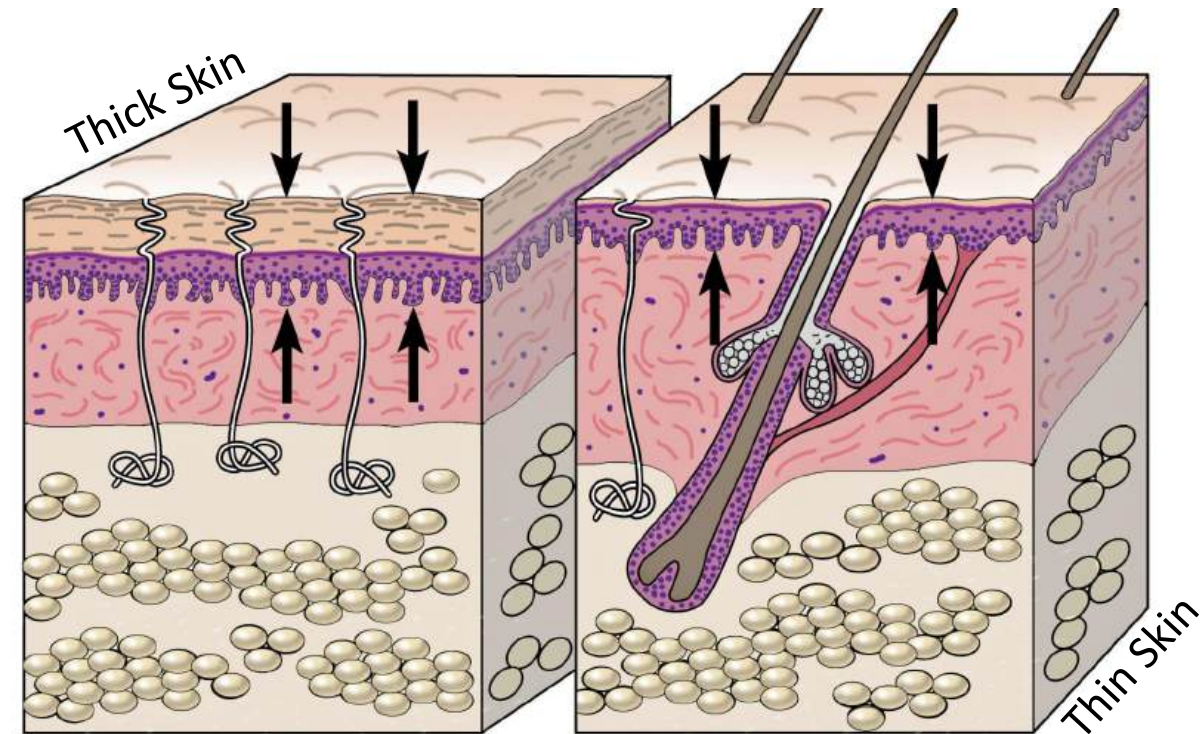
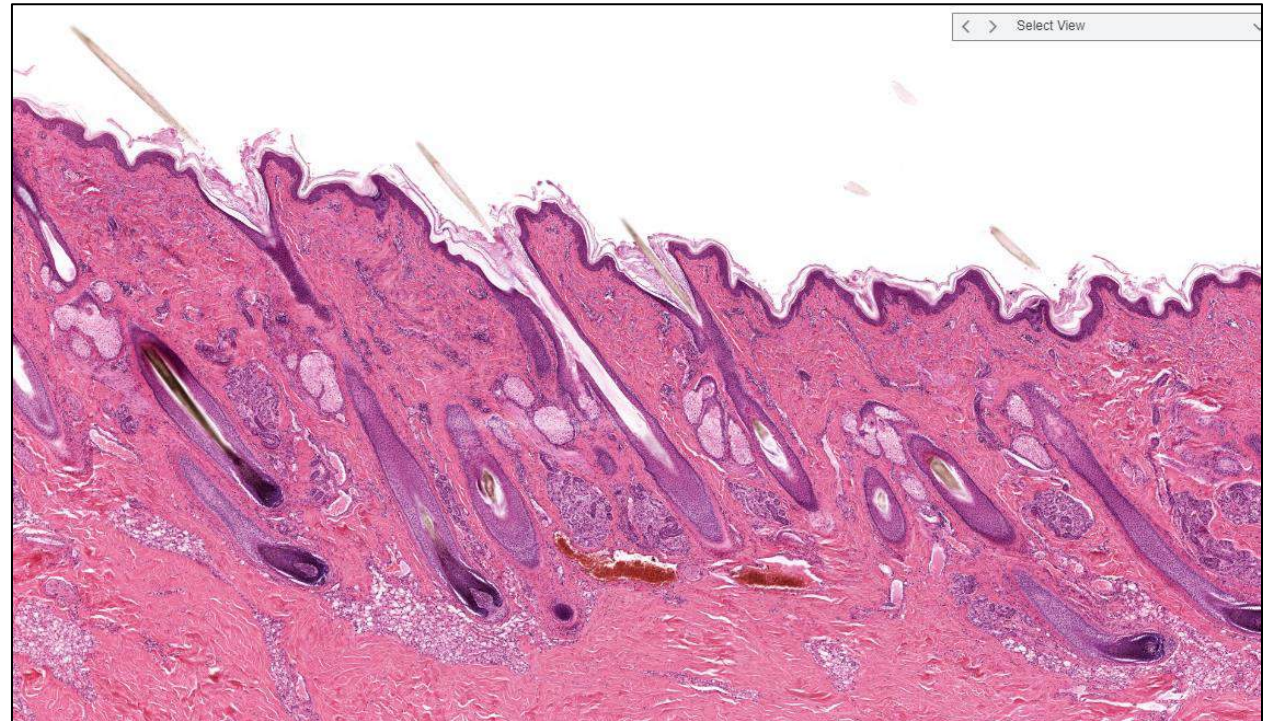
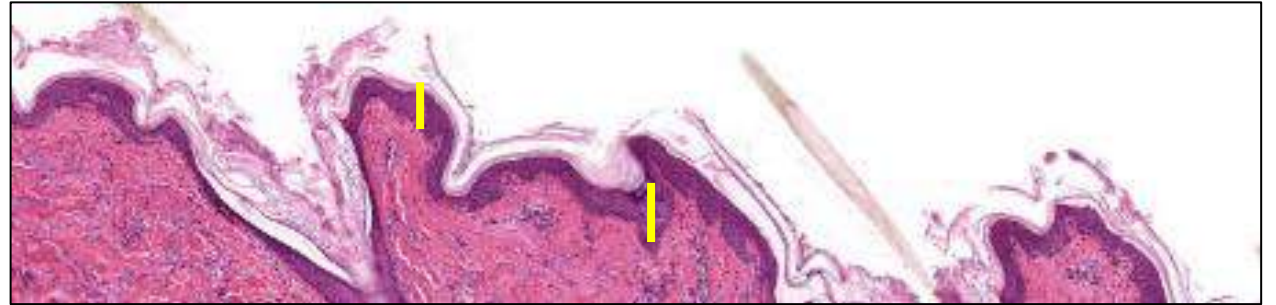- Epidermis
- Dermis
- Hypodermis/subcutaneous layer

Skin Layers – Epidermis (Thick Skin)

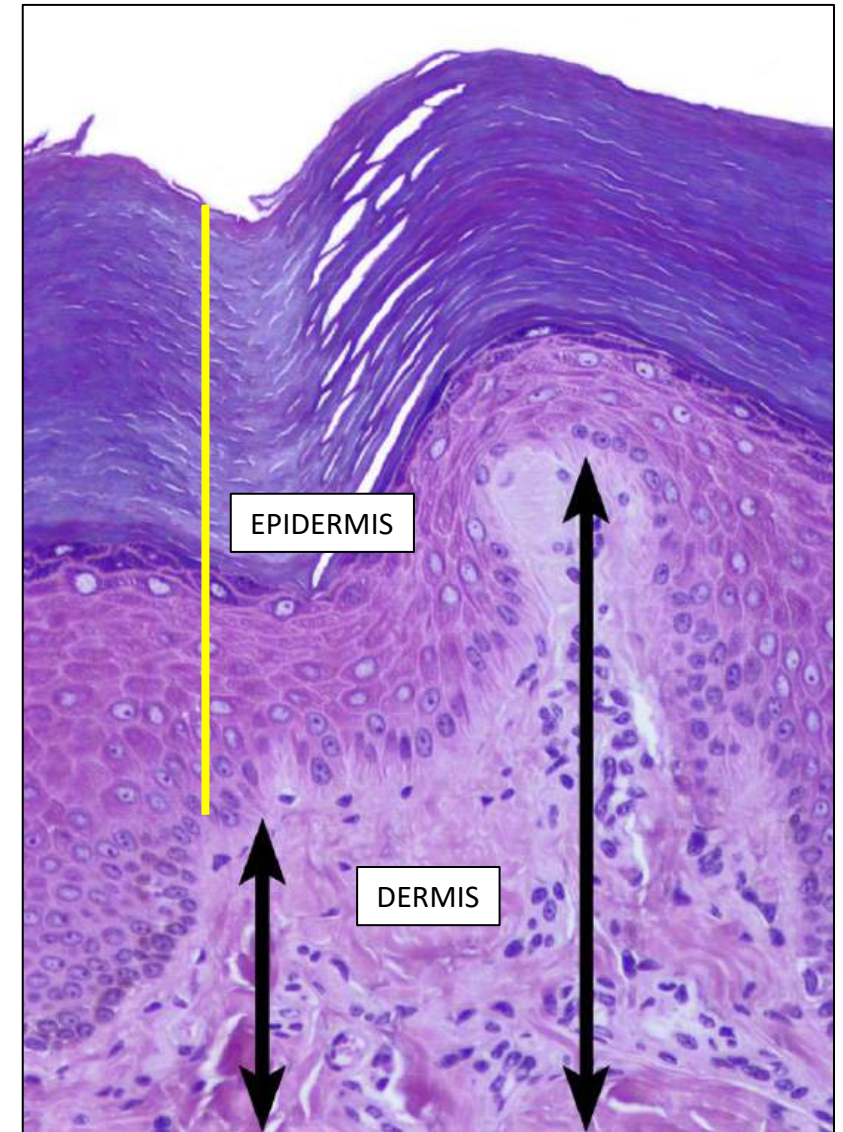
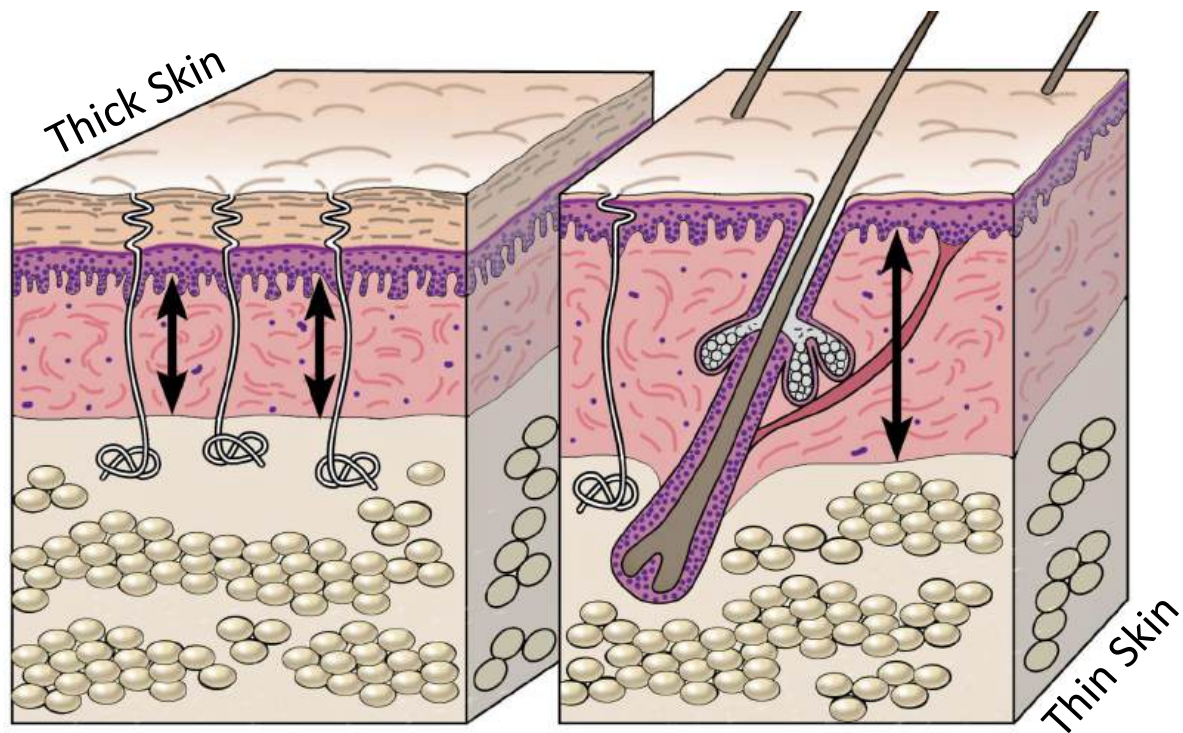


Skin Layers – Epidermis (Thin Skin)

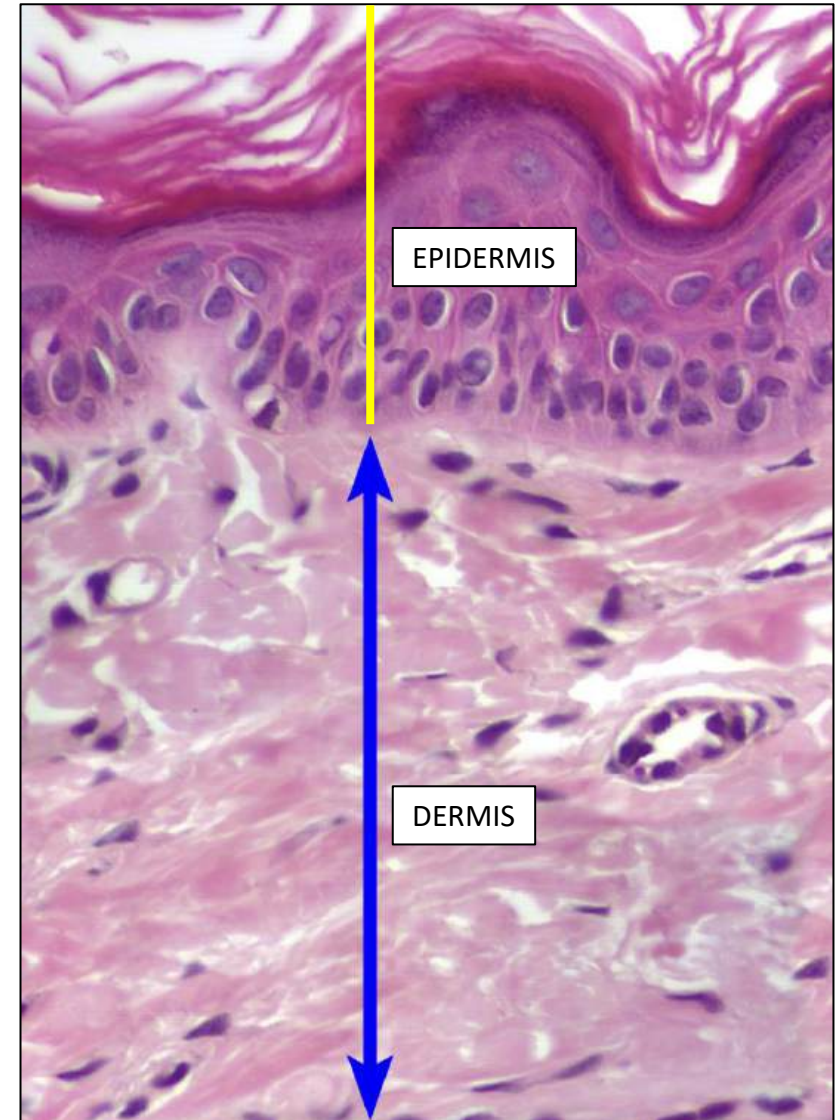
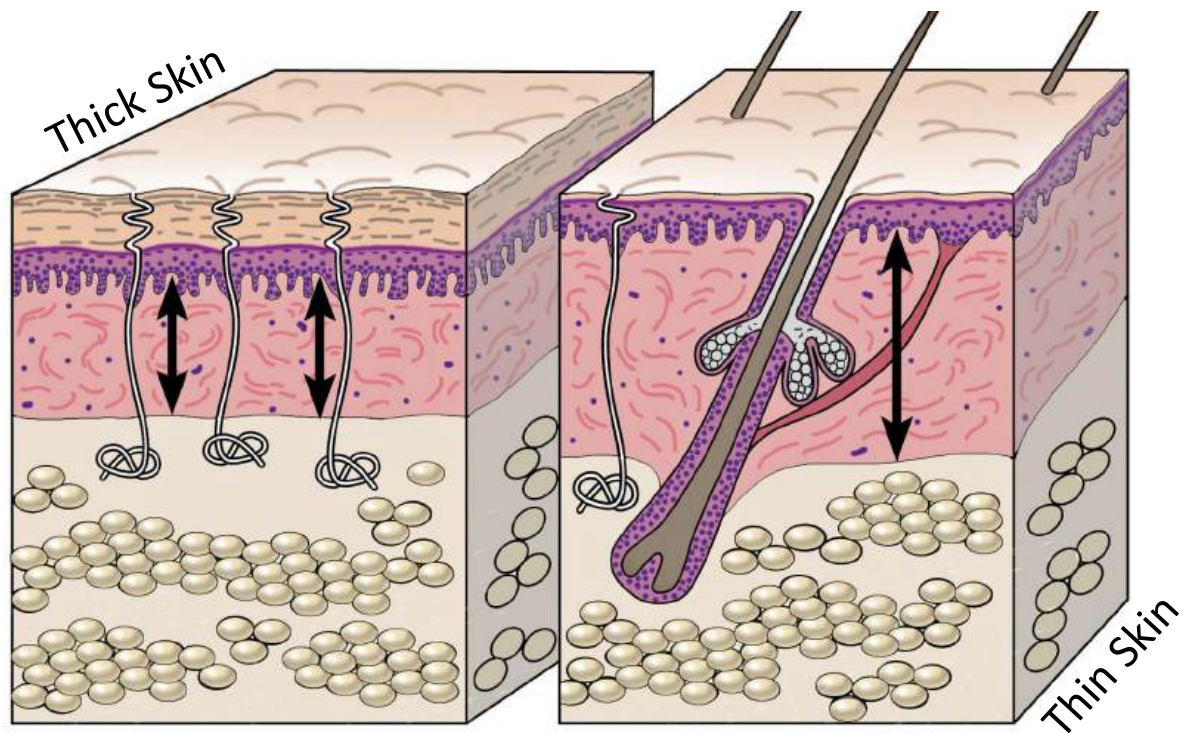
Thick skin does NOT have hair/hair follicles...found on the soles of the feet and palms of the hands



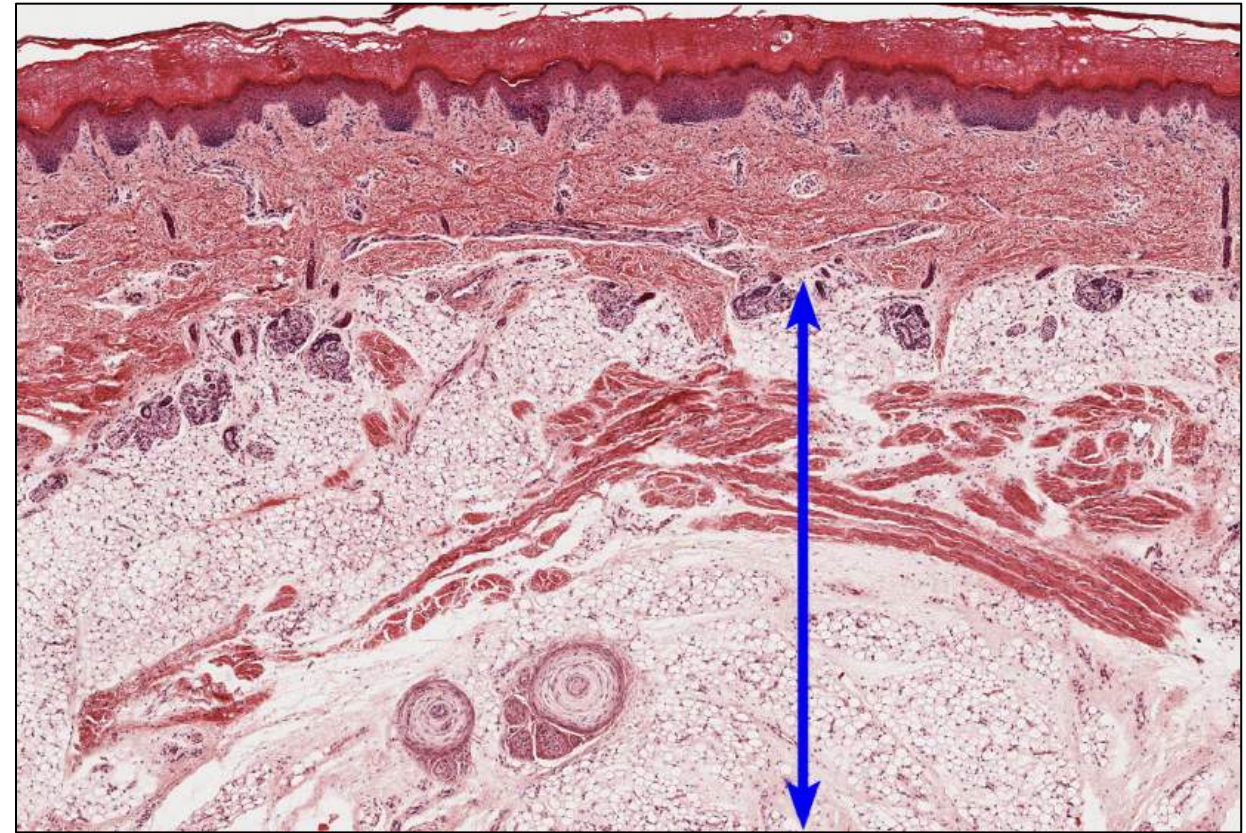
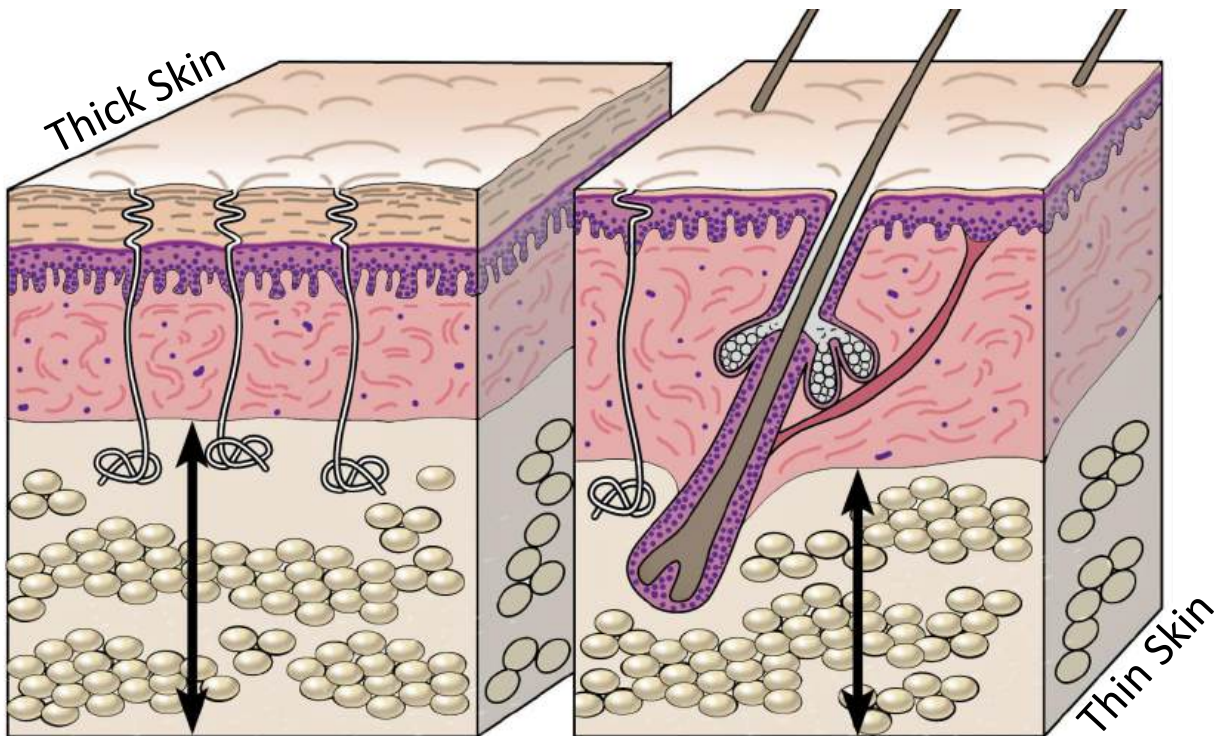
Skin Layers – Dermis (Thick Skin)



Skin Layers – Dermis (Thin Skin)

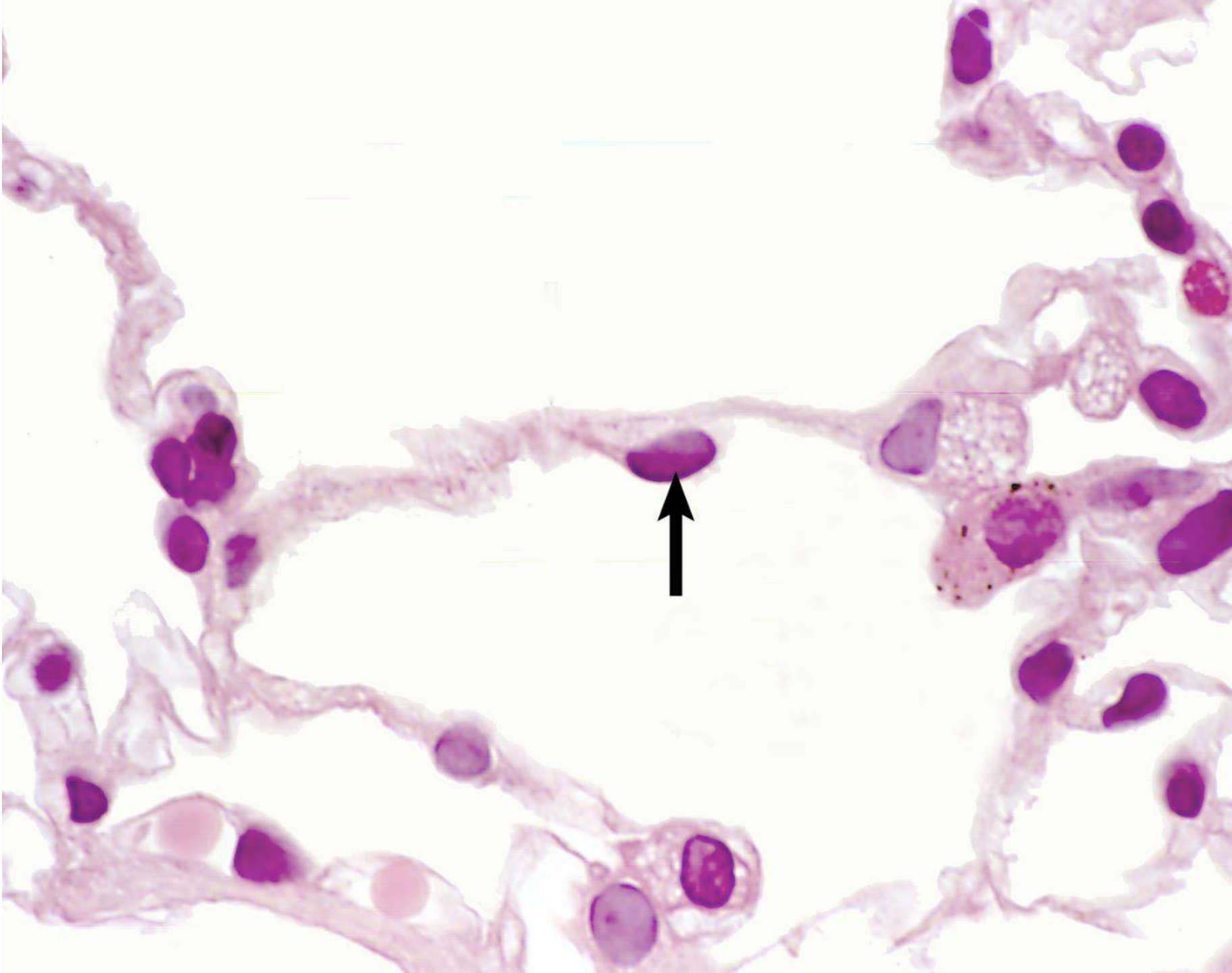


Skin Layers – Hypodermis = Subcutaneous Layer = Superficial Fascia



Do not need to distinguish between thick & thin skin

Respiratory System

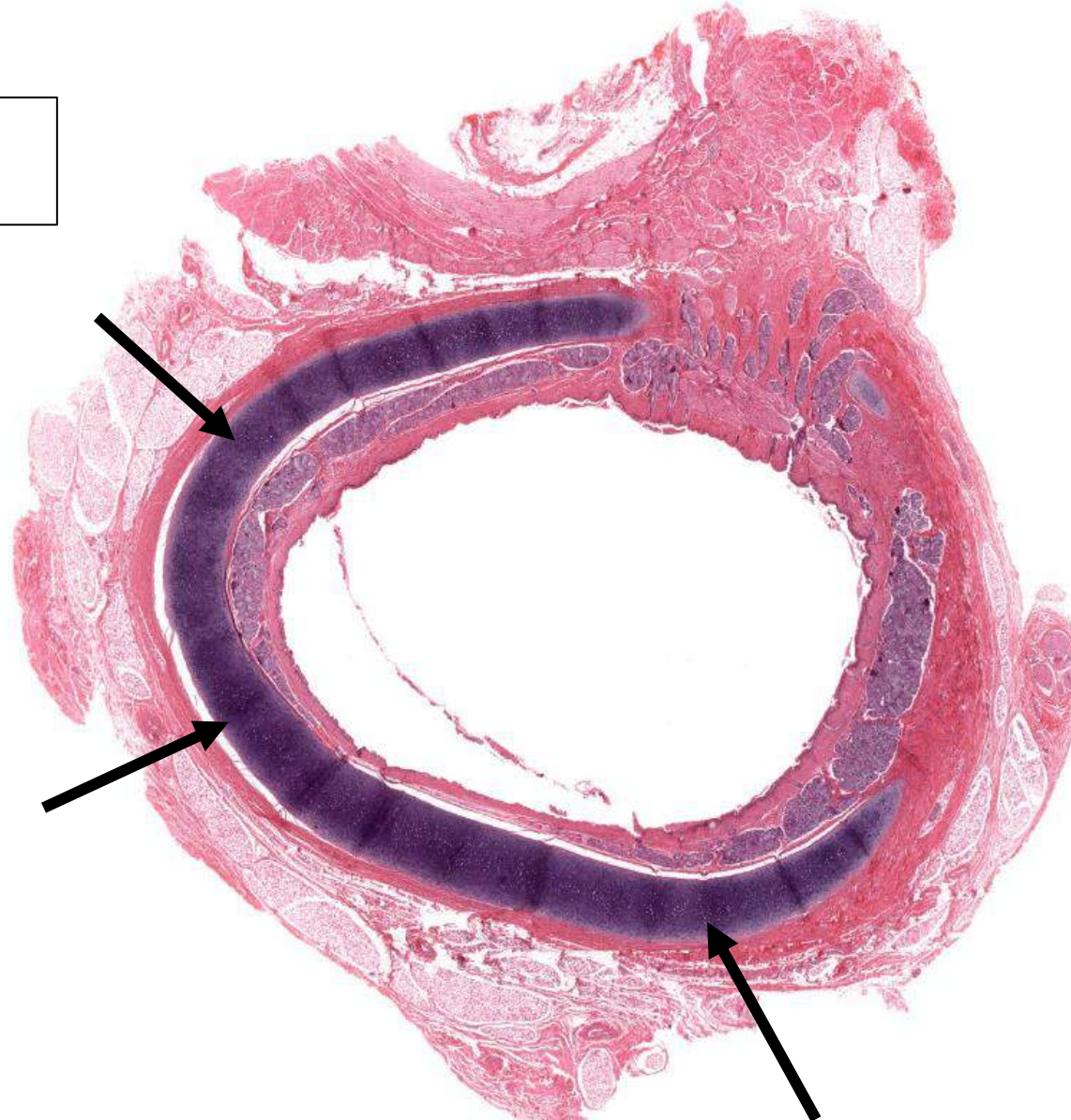


Conducting Airways

- Trachea
- Bronchi (Primary, Secondary and Tertiary)
- Bronchioles
- Alveolar sacs/Alveoli

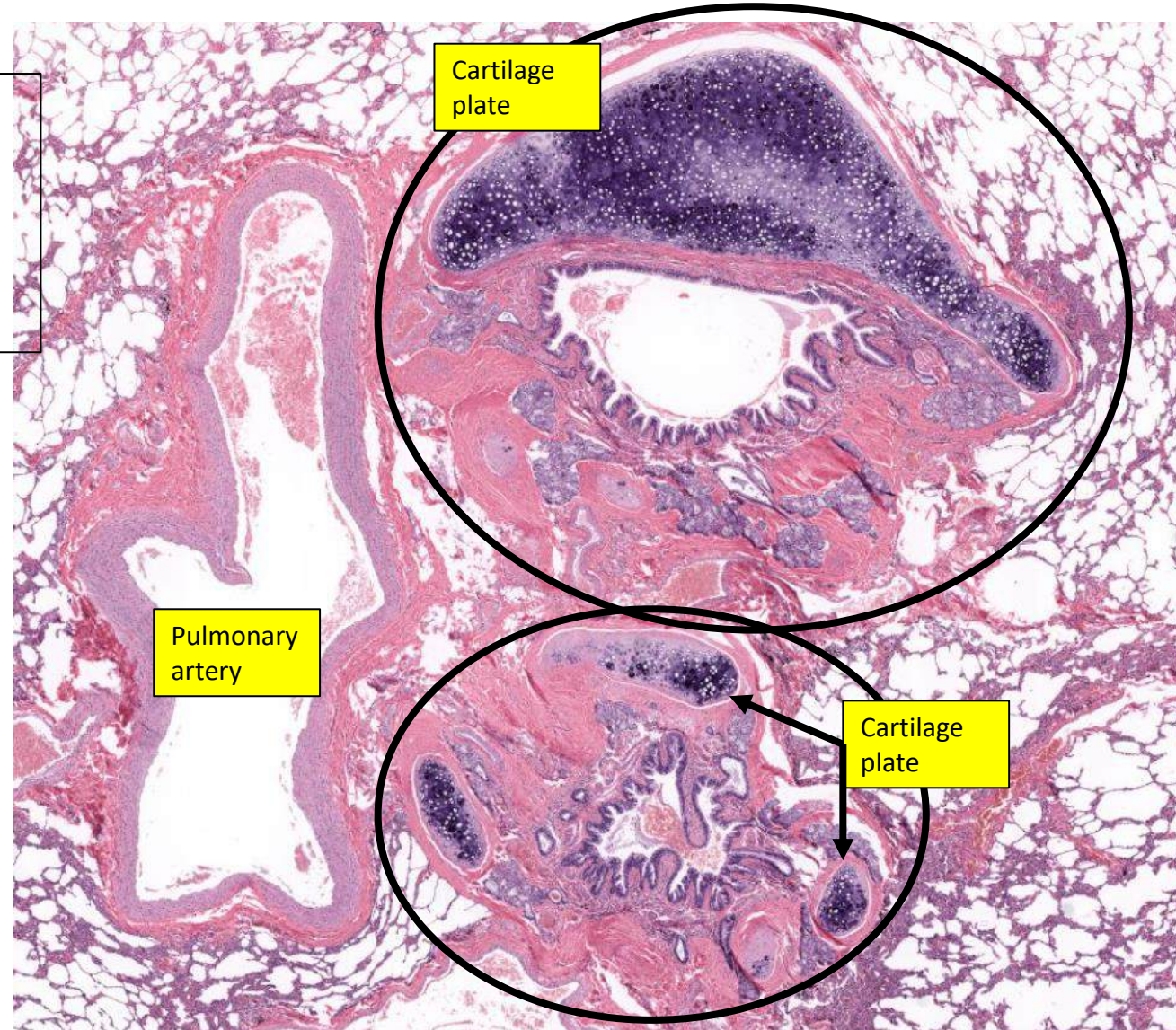
Conducting Airway Trachea

Trachea has dark staining
RINGS of Hyaline cartilage



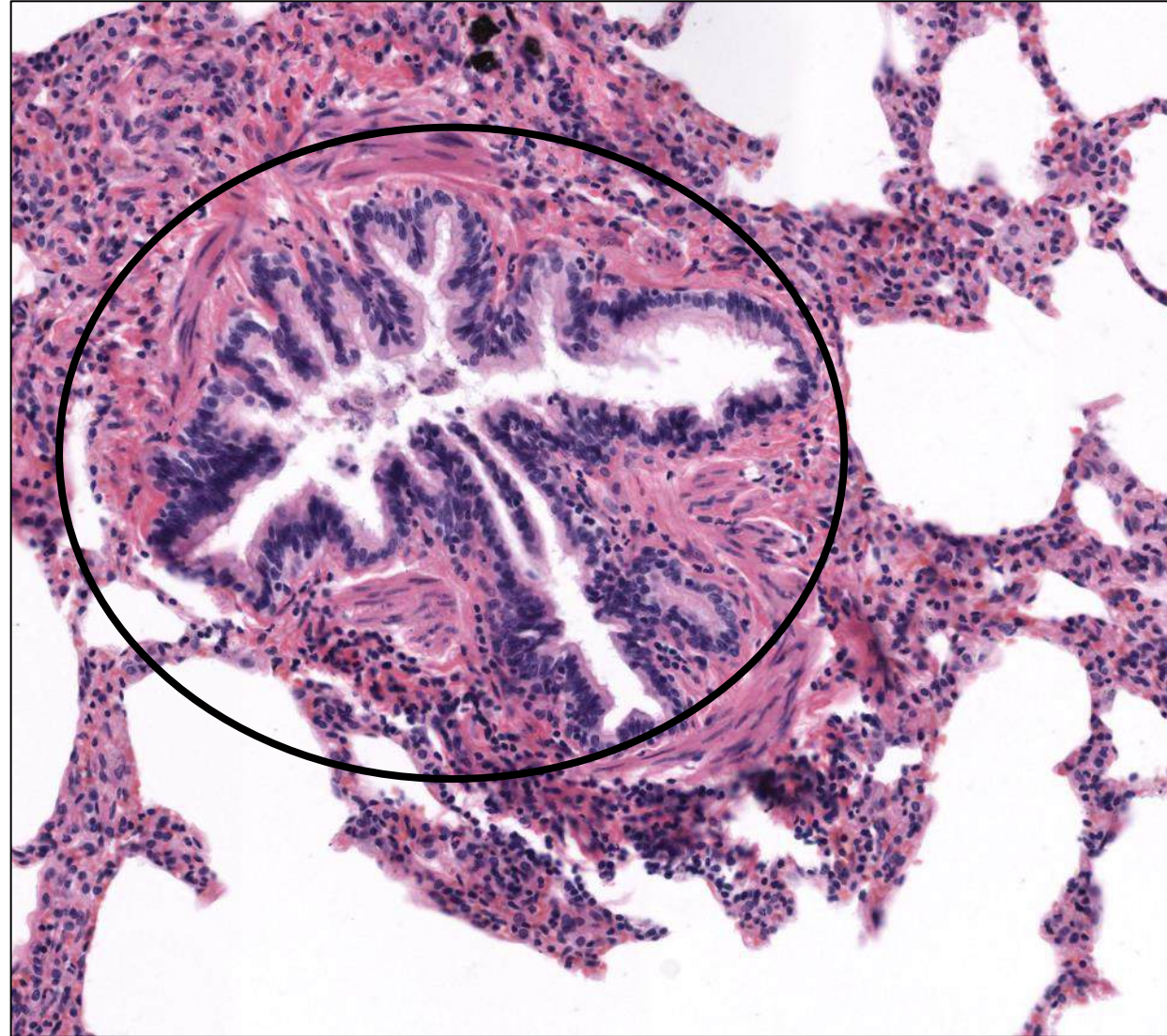
Conducting Airway – Bronchi

Bronchi have walls reinforced with dark-staining **PLATES of Hyaline cartilage**. Bronchi are typically found **close to a pulmonary artery**.

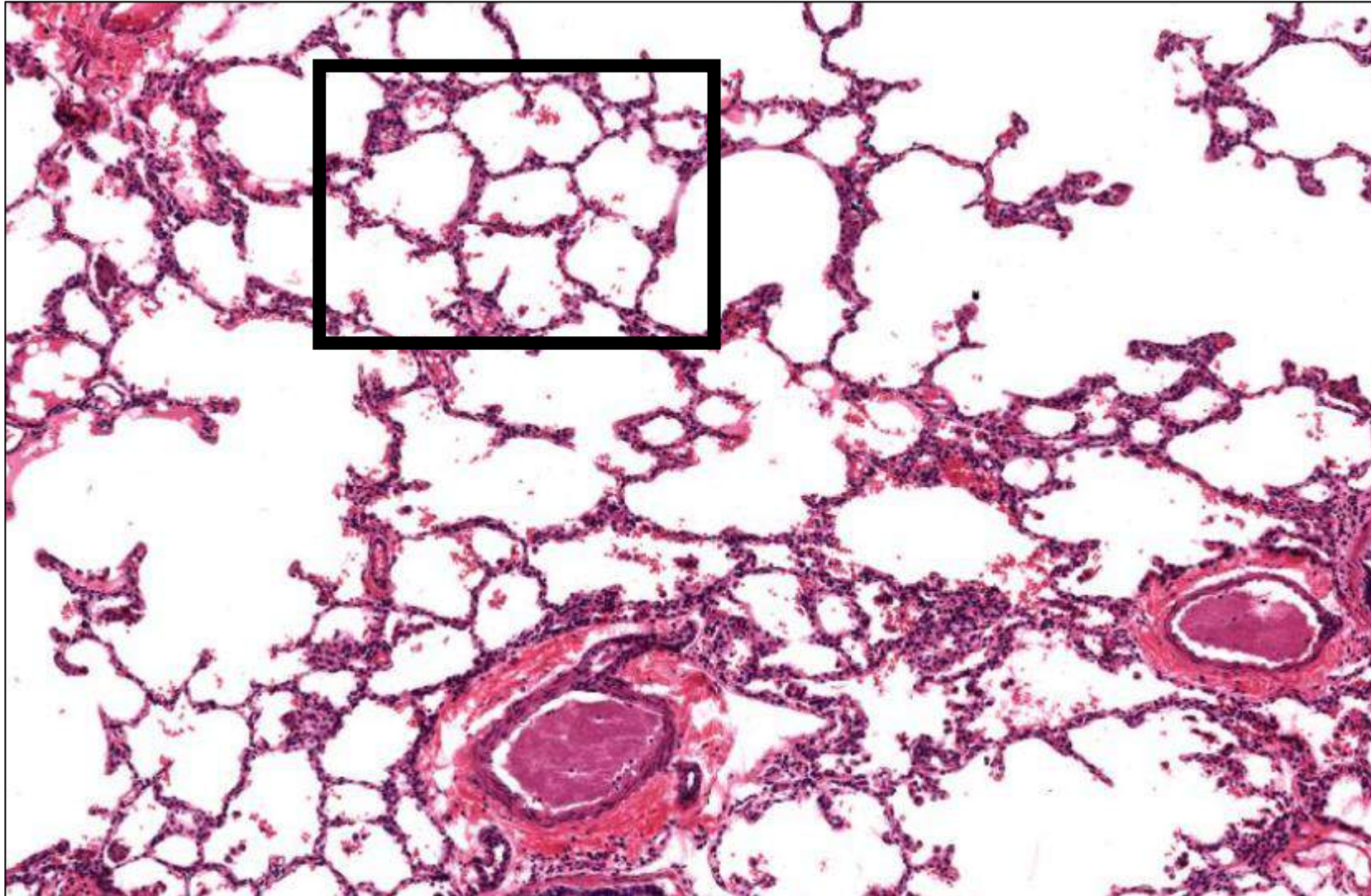


Conducting Airway – Bronchioles

Bronchioles have NO cartilage in their walls – only smooth muscle for support.



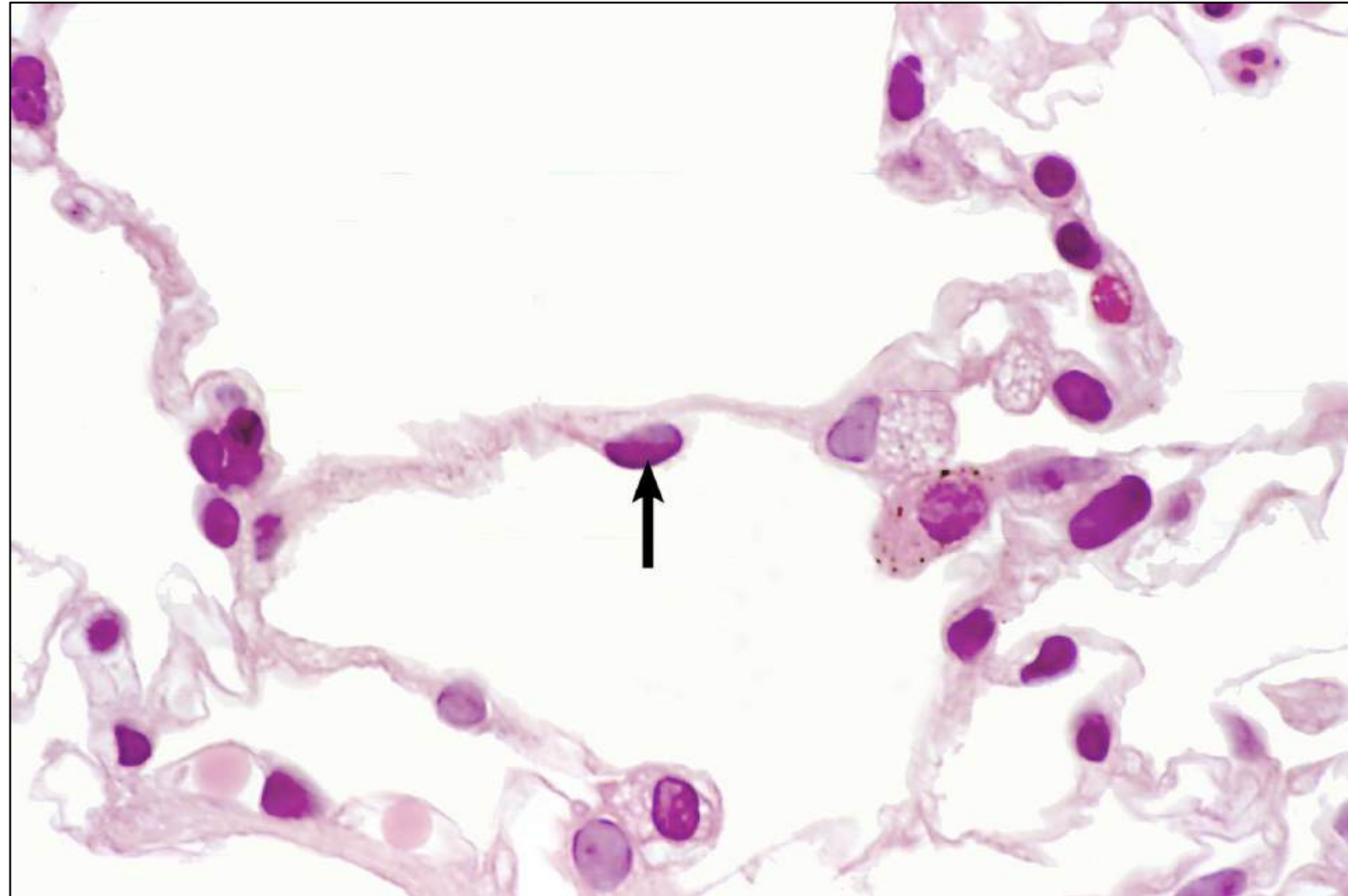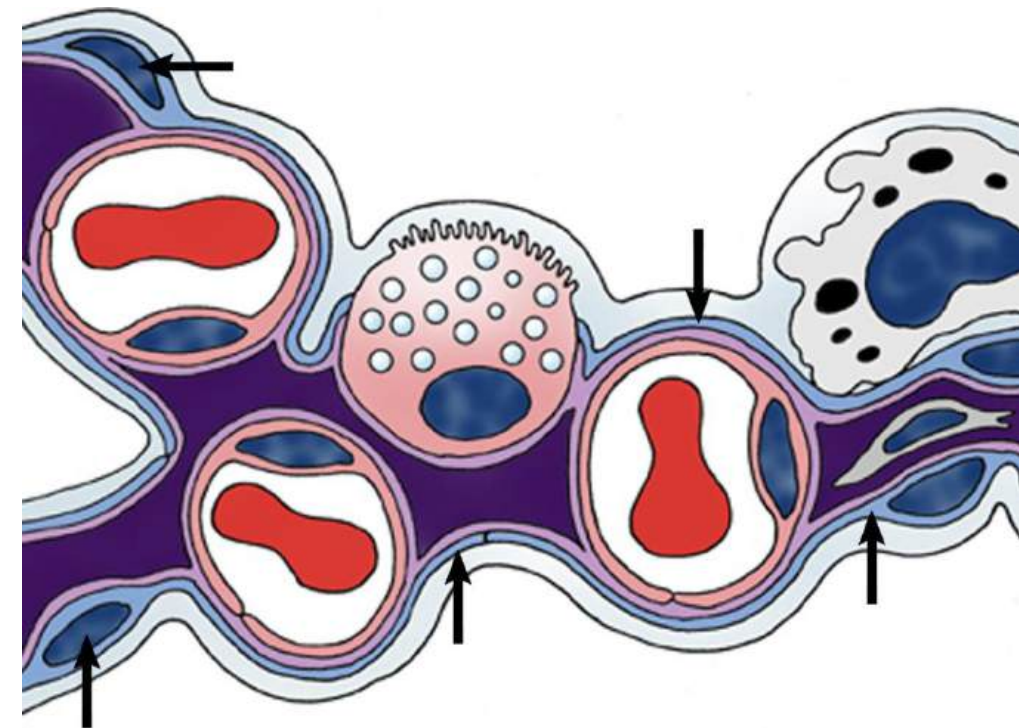
Gas Exchange – Alveolar Sacs/Alveoli



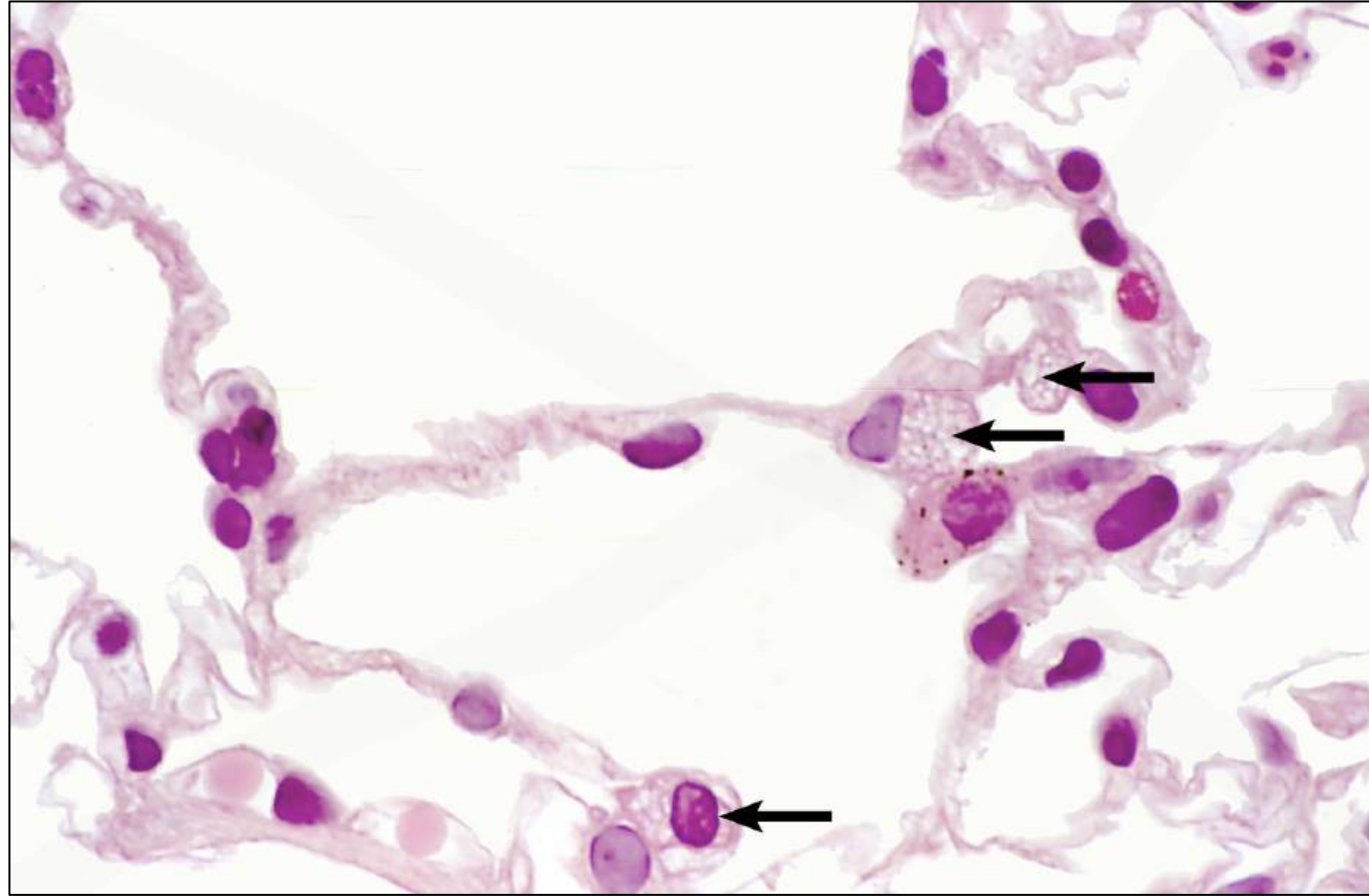
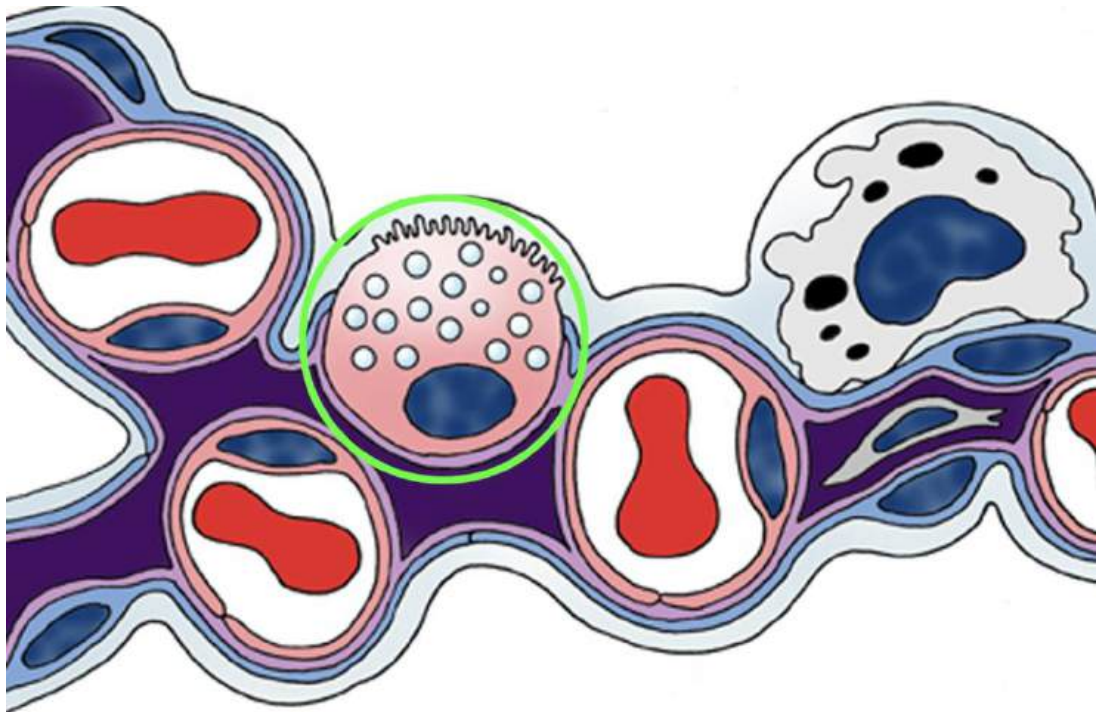
Cells of the Respiratory Zone

- Type I pneumocytes
- Type II pneumocytes
- Dust cell or alveolar macrophages

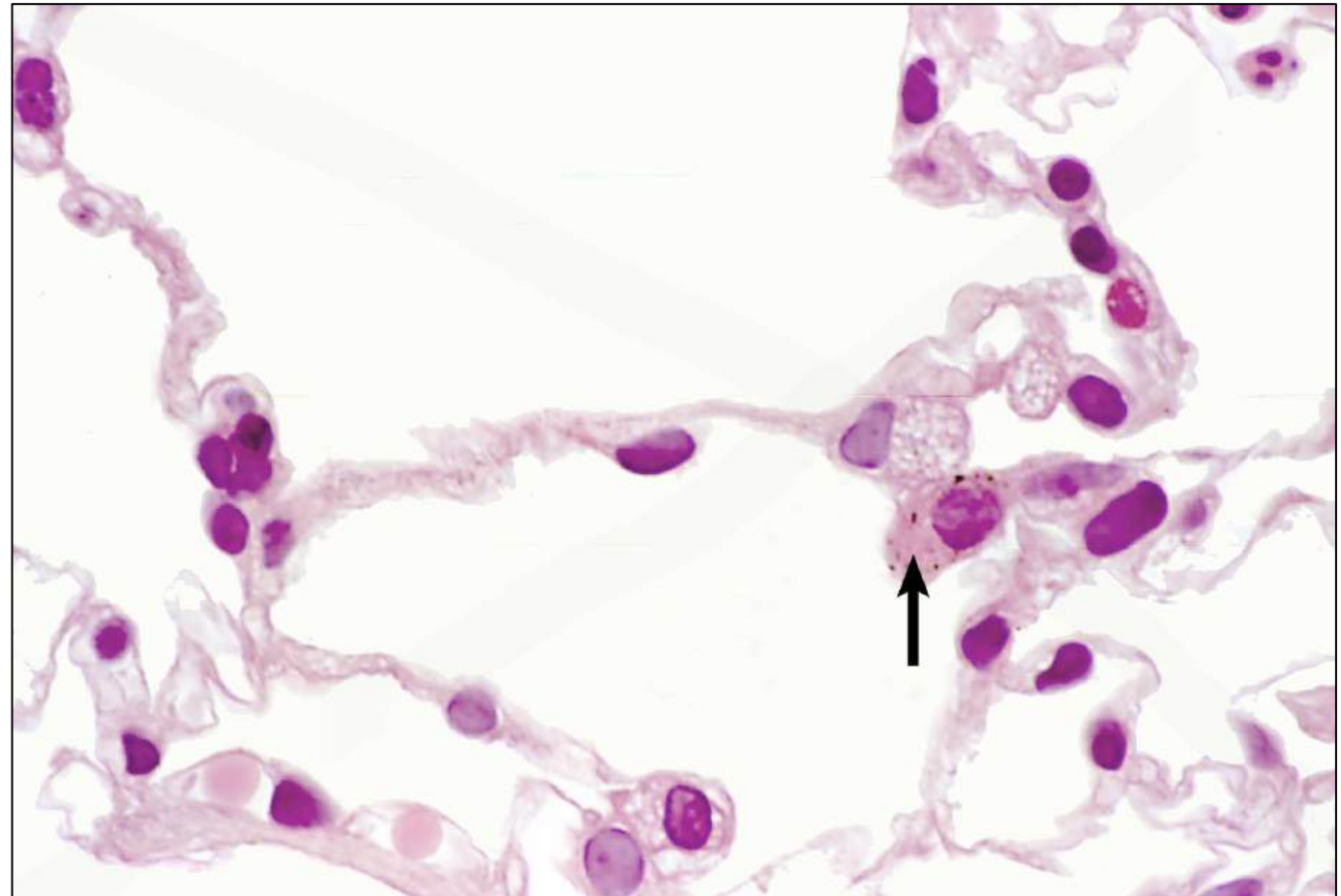
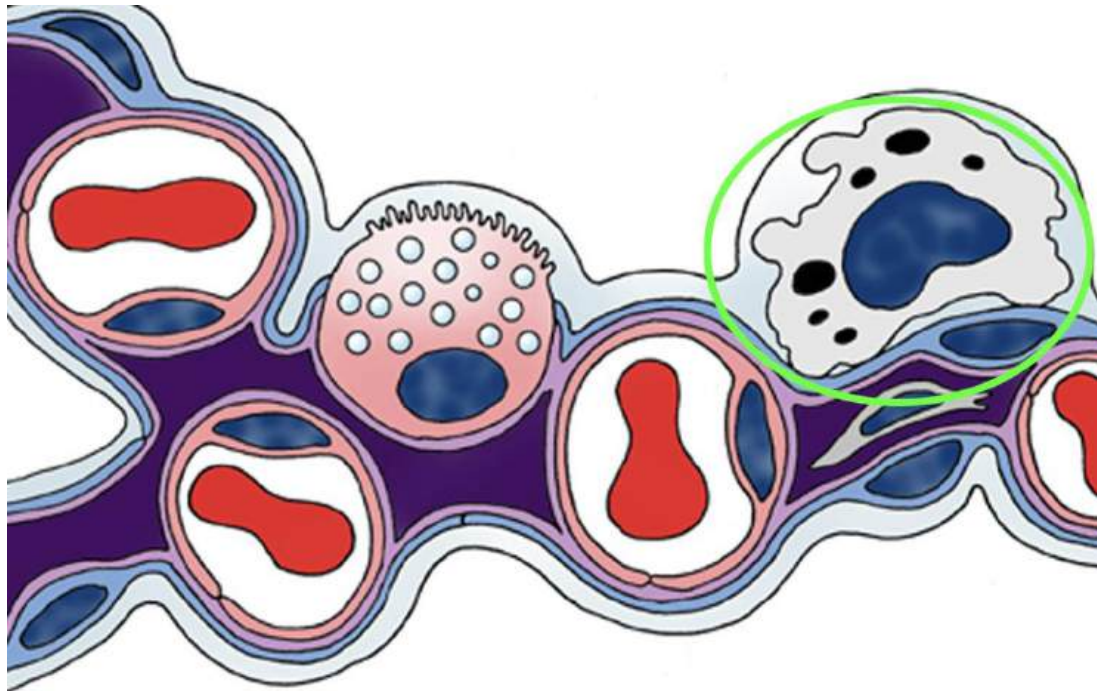
Cells of Respiratory Zone – Type I Pneumocytes



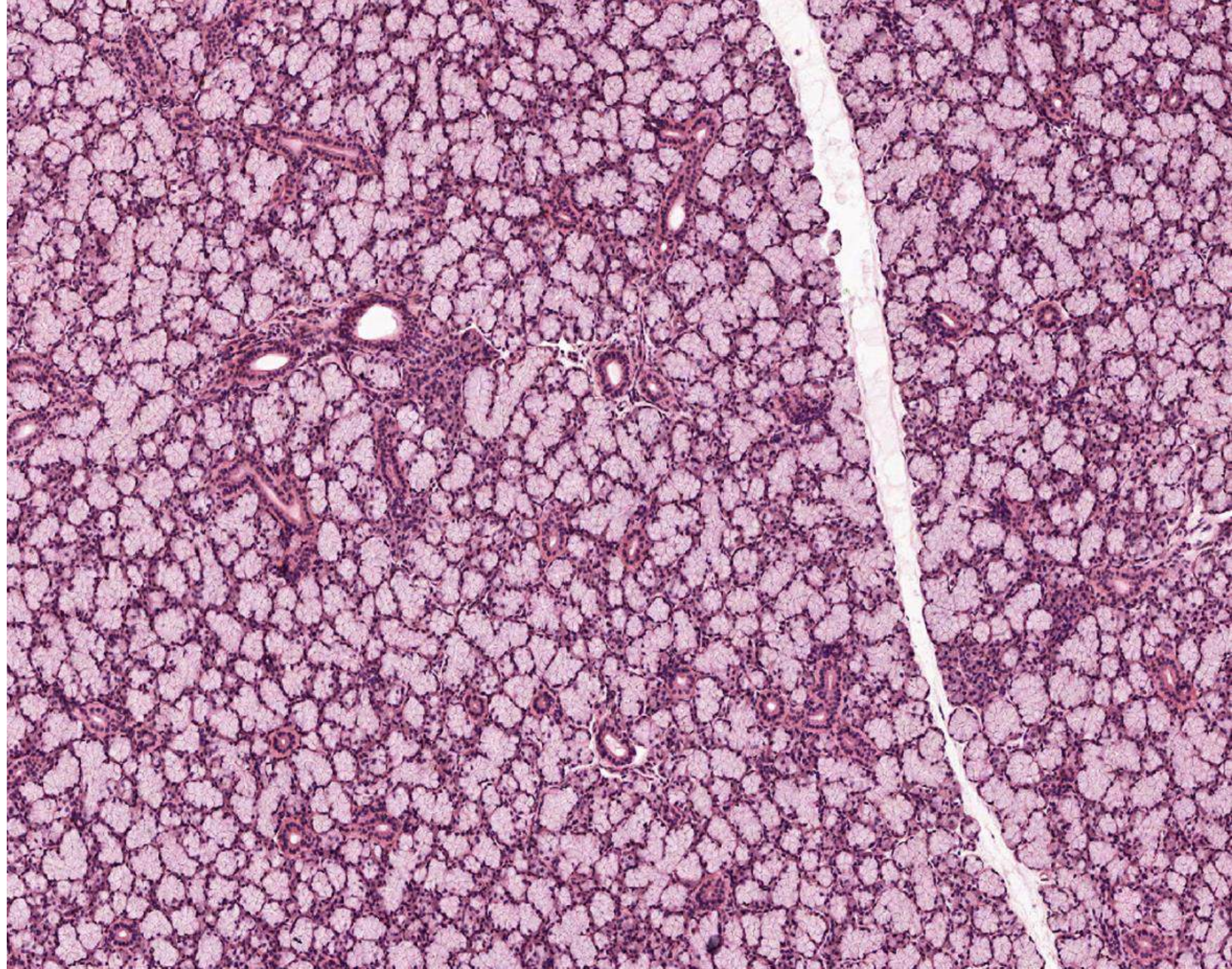
Cells of Respiratory Zone – Type II Pneumocytes



Cells of Respiratory Zone – Dust Cell/Alveolar Macrophage

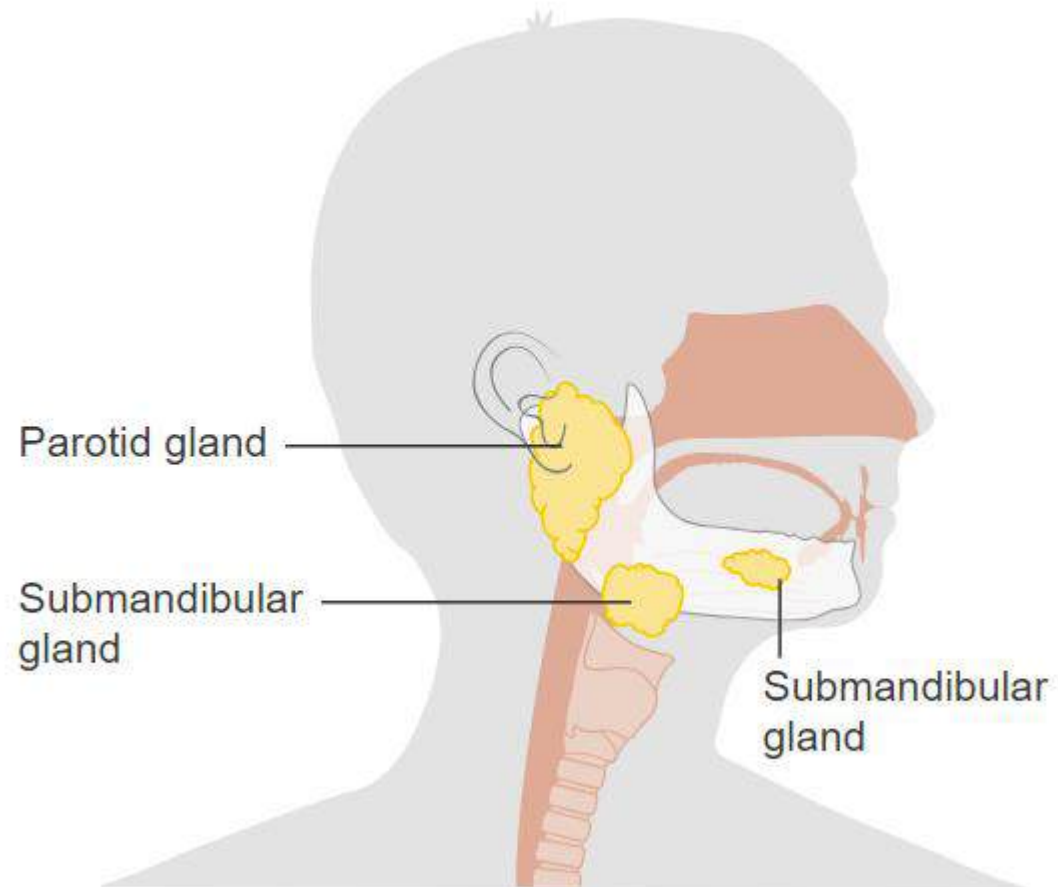


Accessory Organs of Digestion

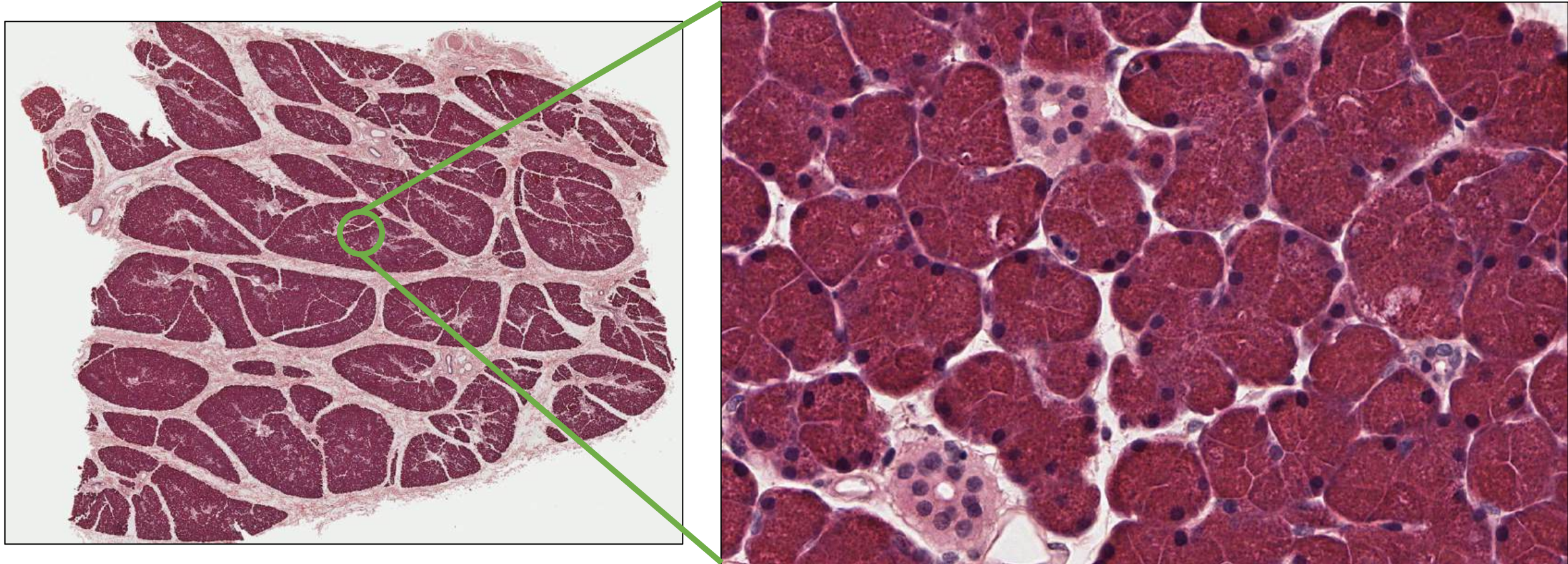


Major Salivary Glands

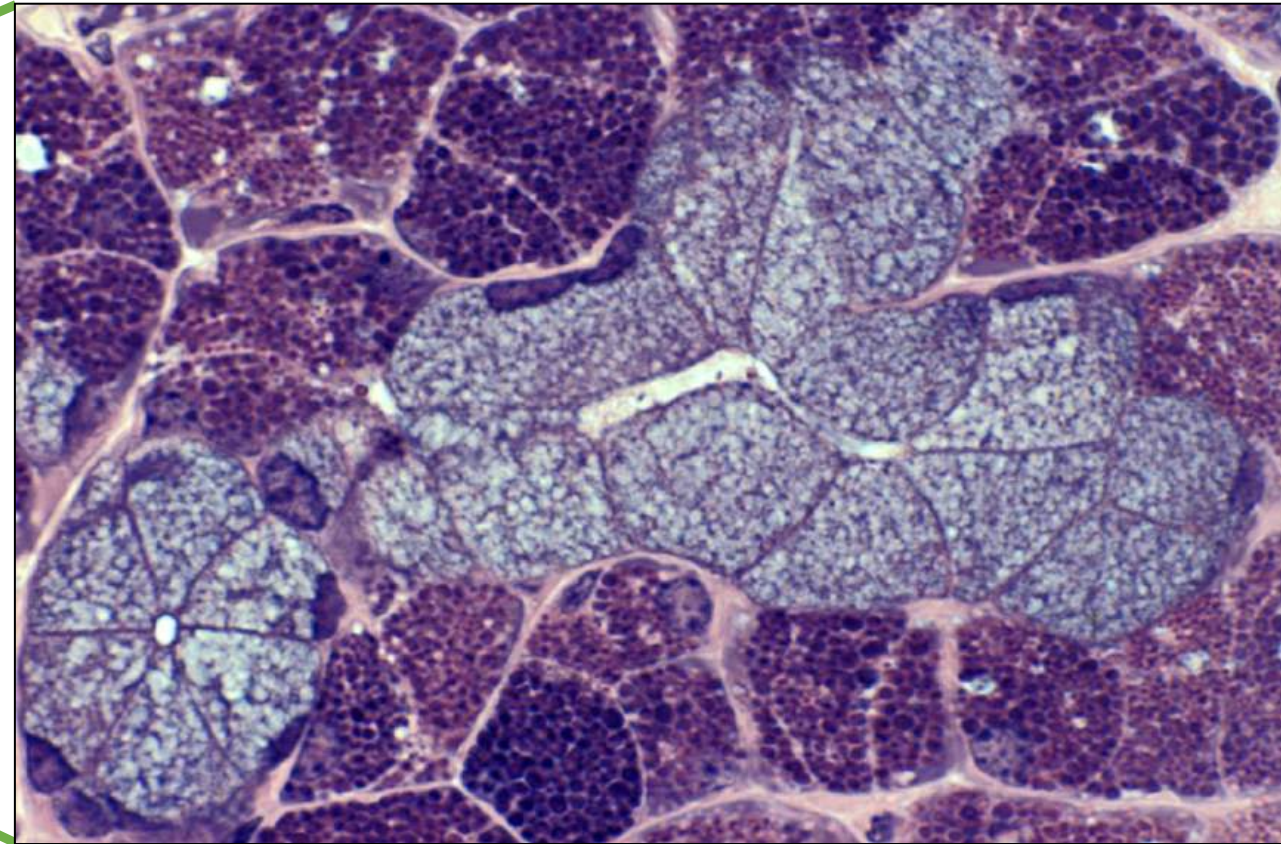
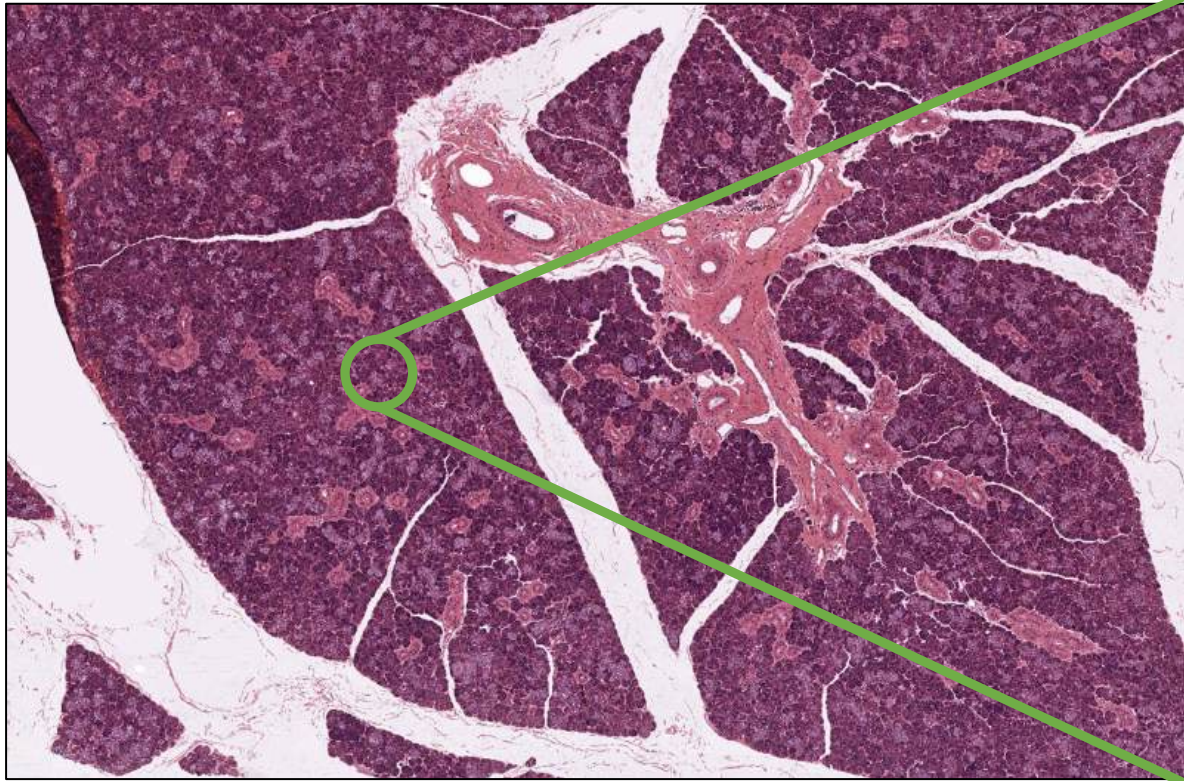- Parotid (mostly serous glands)
- Submandibular (mixed serous and mucous producing glands)
- Sublingual (mostly mucous producing glands)



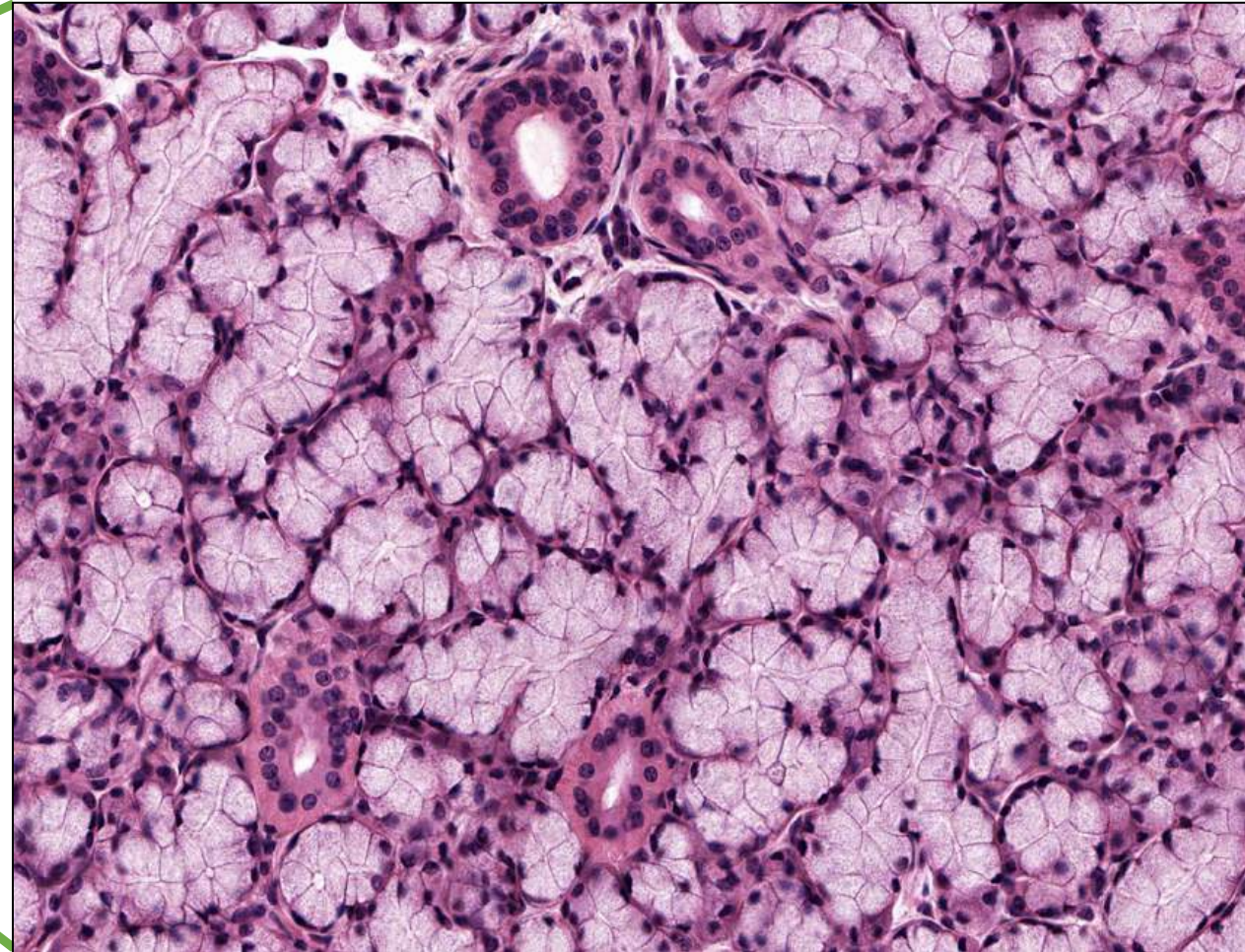
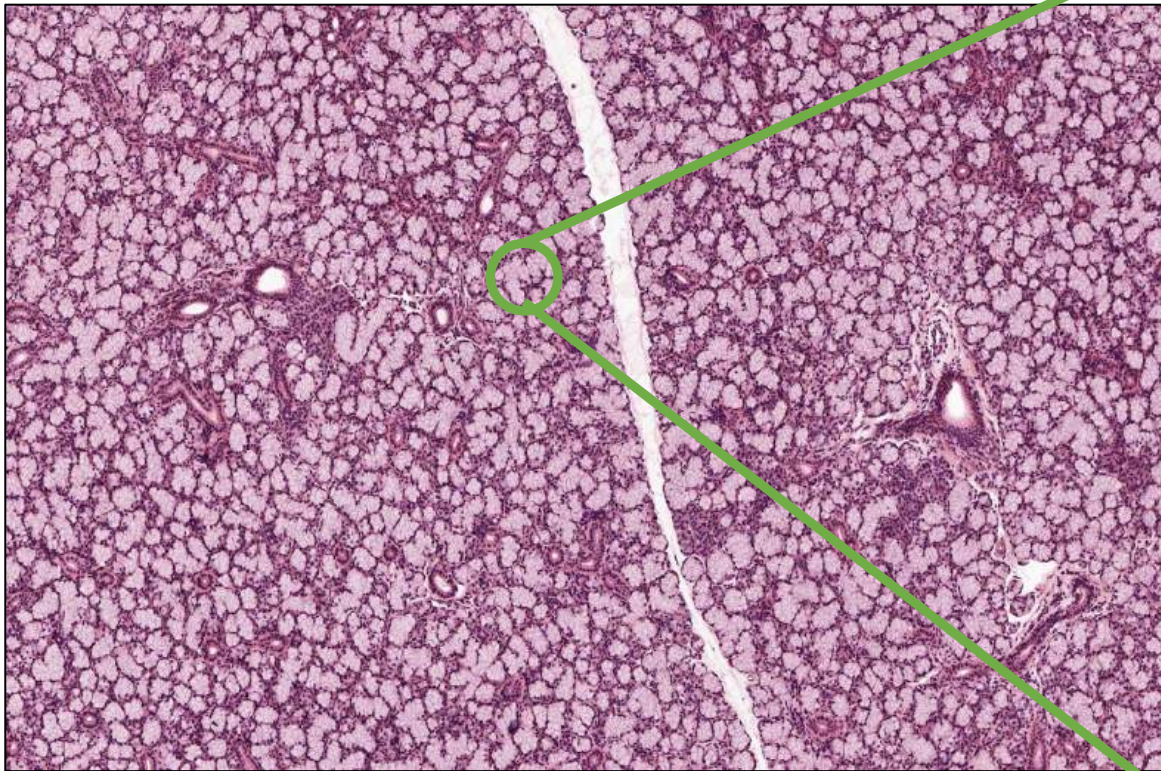
Major Salivary Glands – Parotid (Mostly Serous)



Major Salivary Glands – Submandibular (Mixed Serous & Mucous)



Major Salivary Glands – Sublingual (Mostly Mucous-Producing)

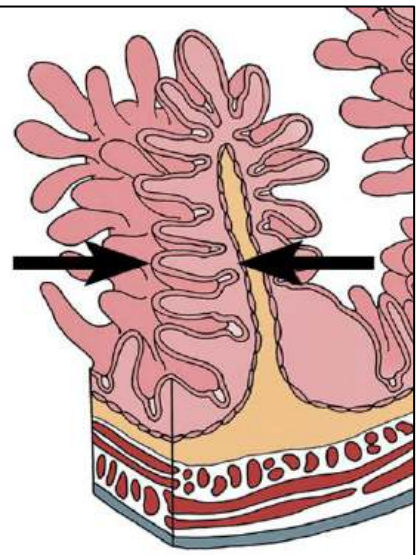
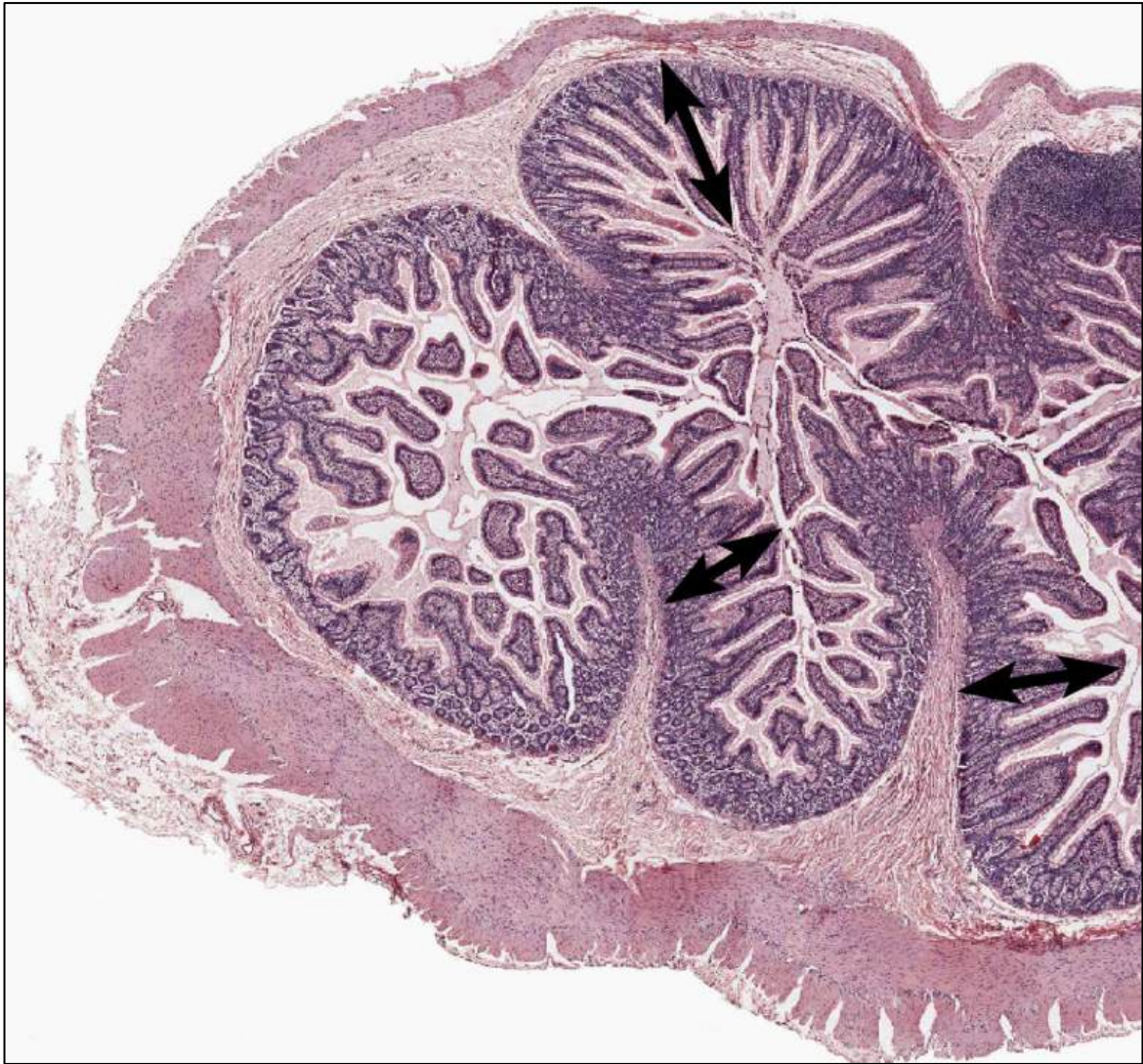


Gastrointestinal Tract

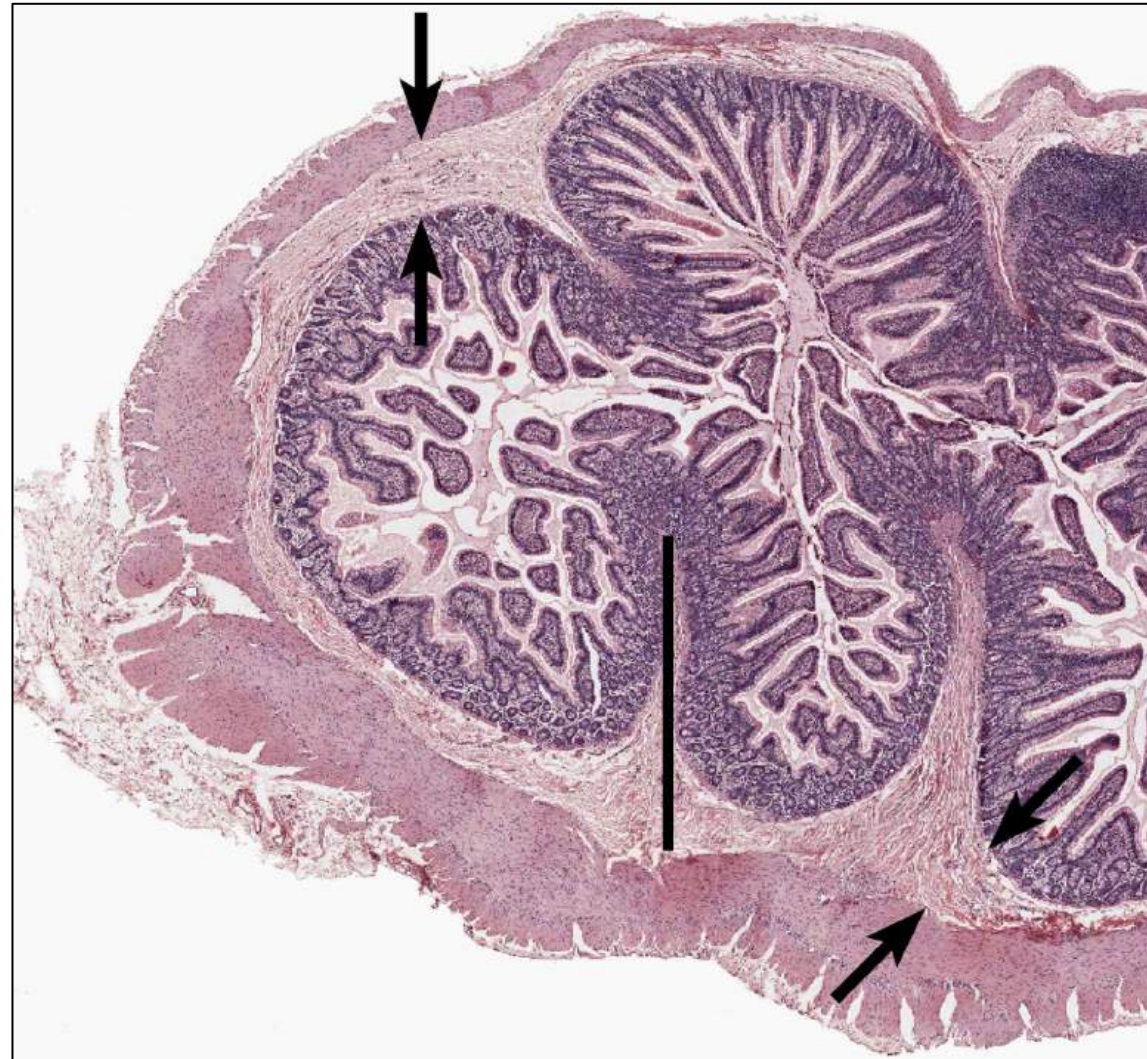
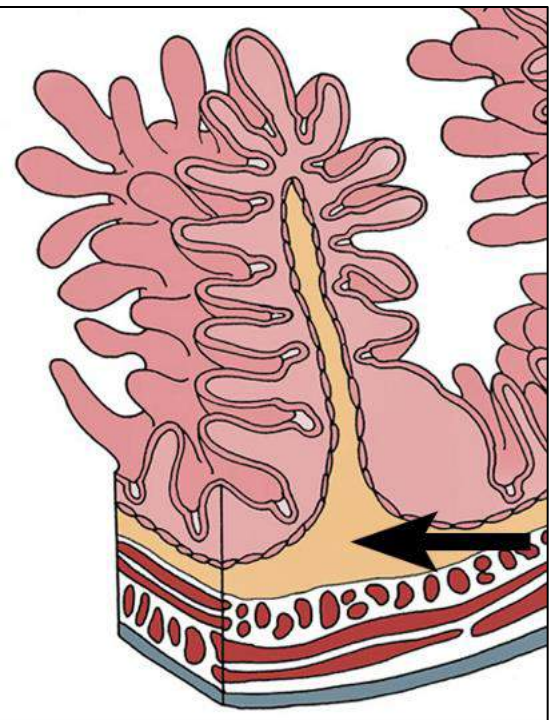
Layers of the Gastrointestinal Tract

- Mucosa
- Submucosa
- Muscularis
- Adventitia/Serosa

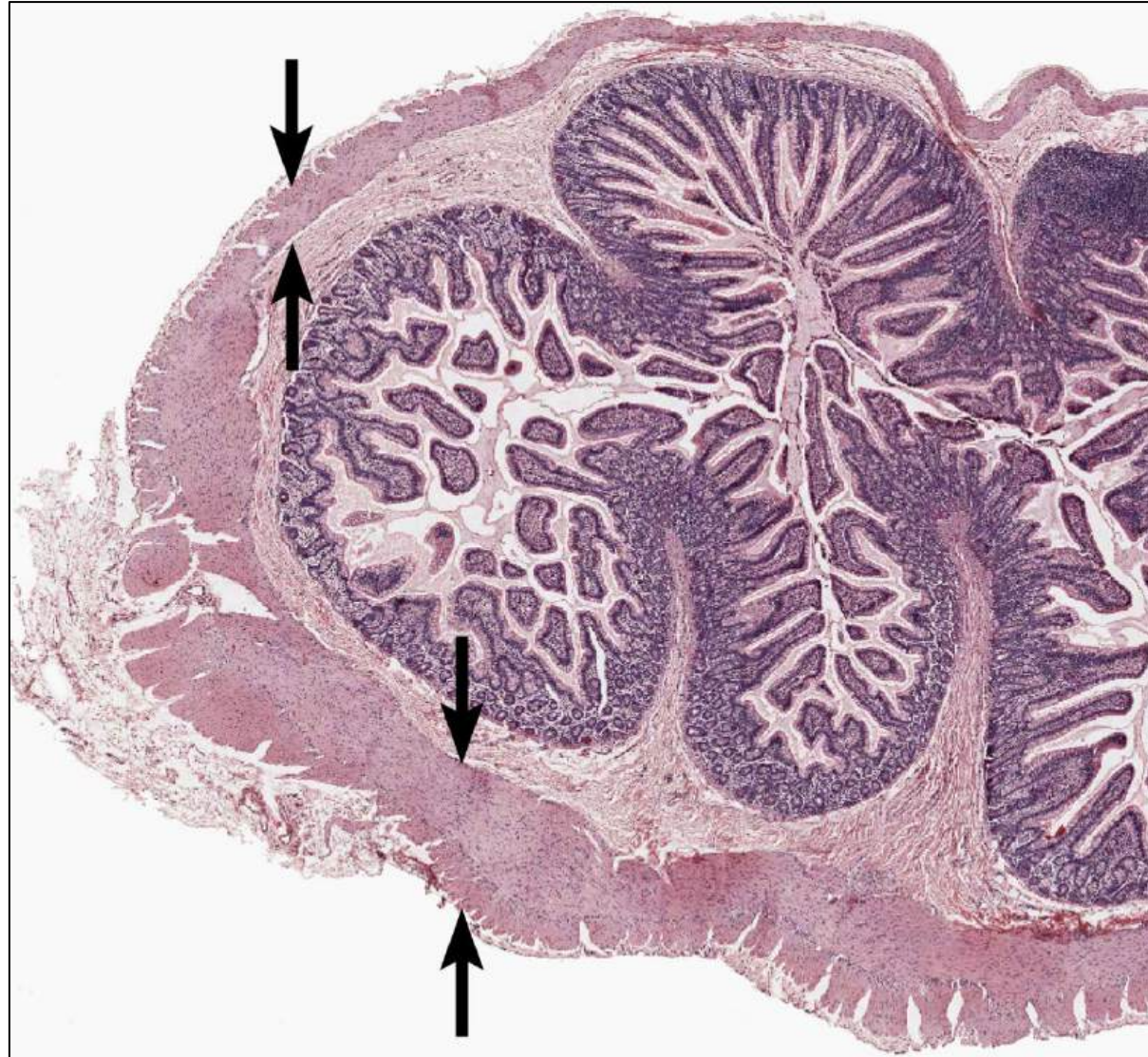
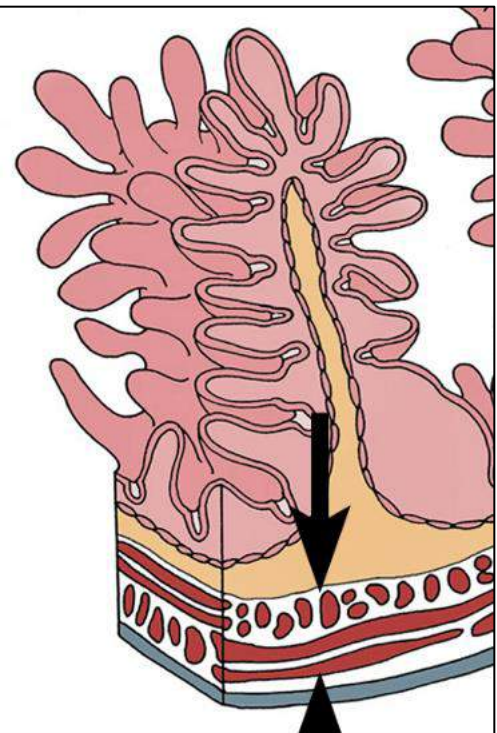
Layers of GI Tract - Mucosa



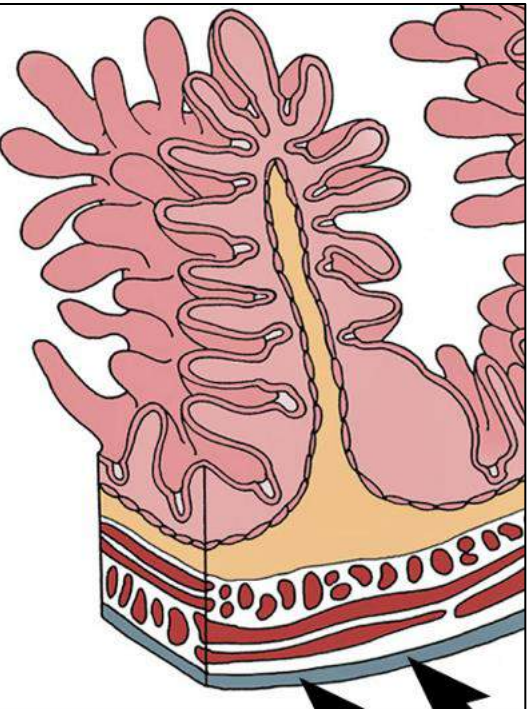
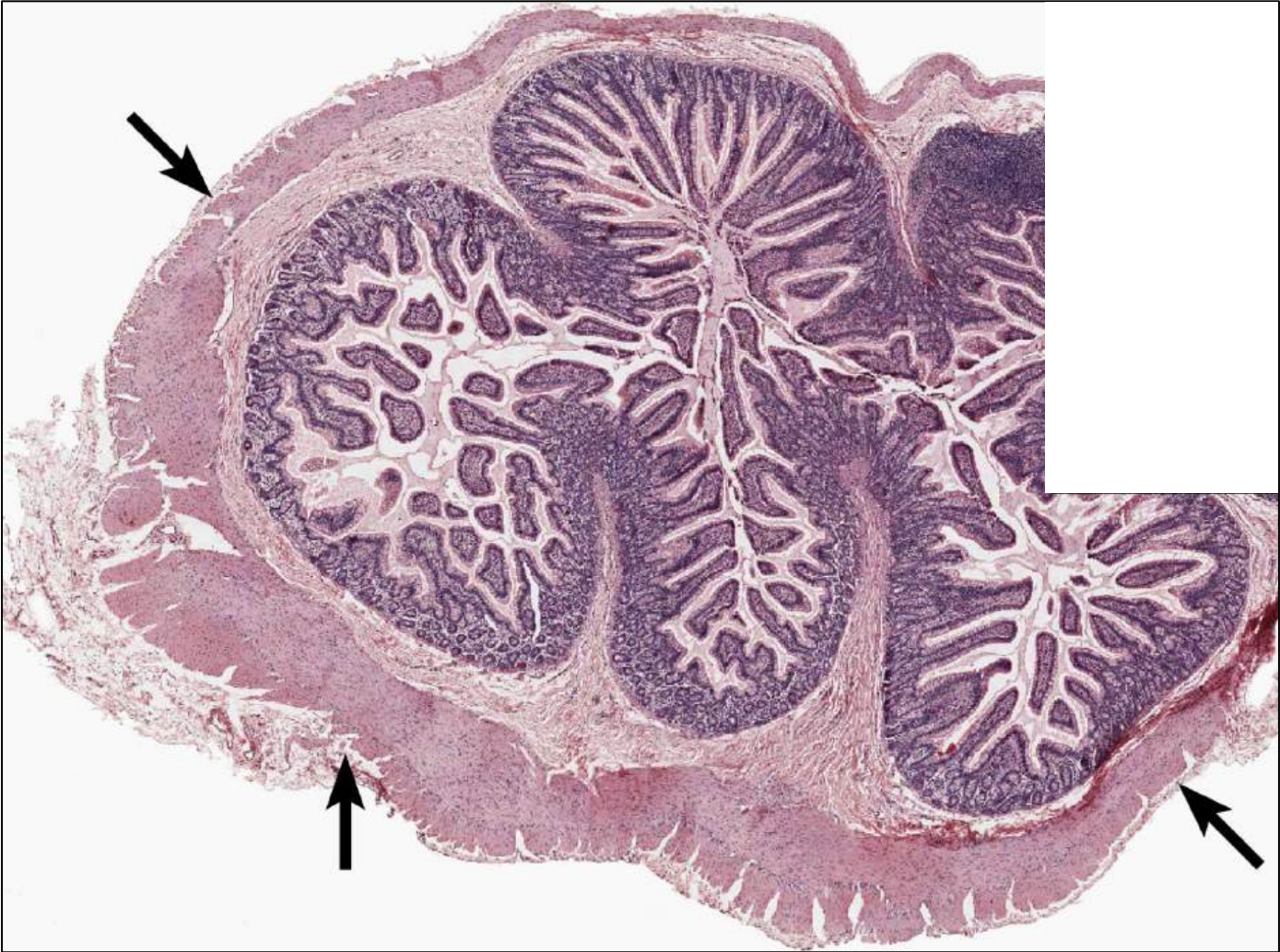
Layers of GI Tract - Submucosa



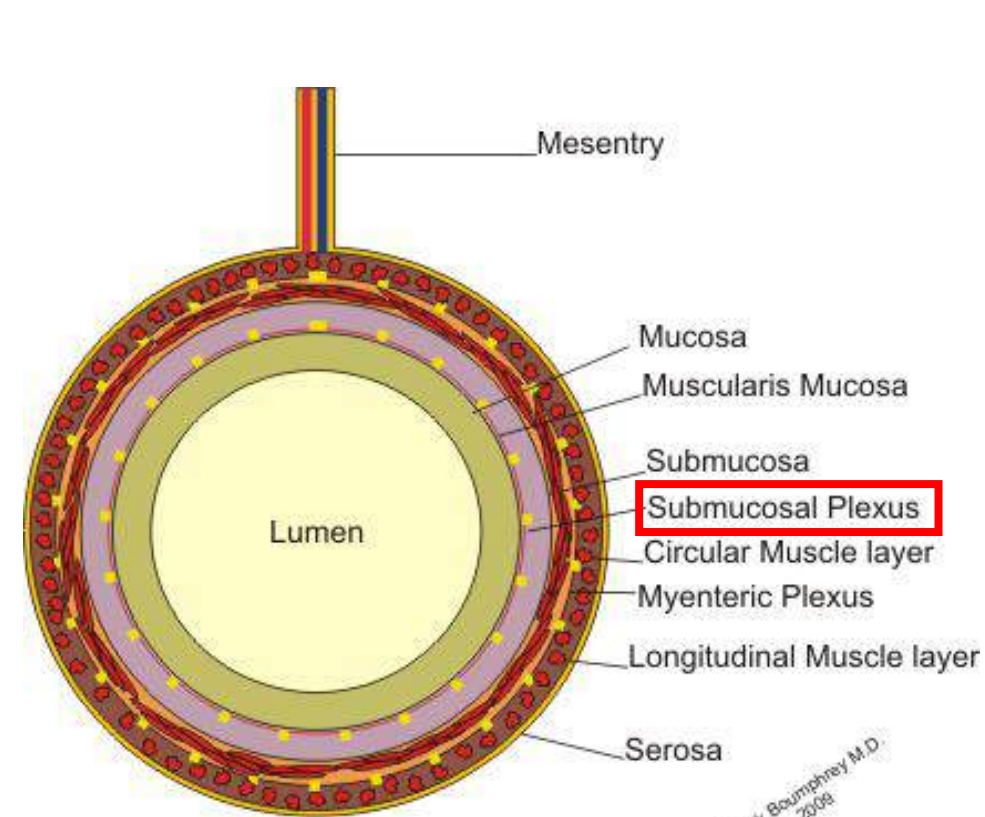
Layers of GI Tract - Muscularis



Layers of GI Tract – Adventitia/Serosa

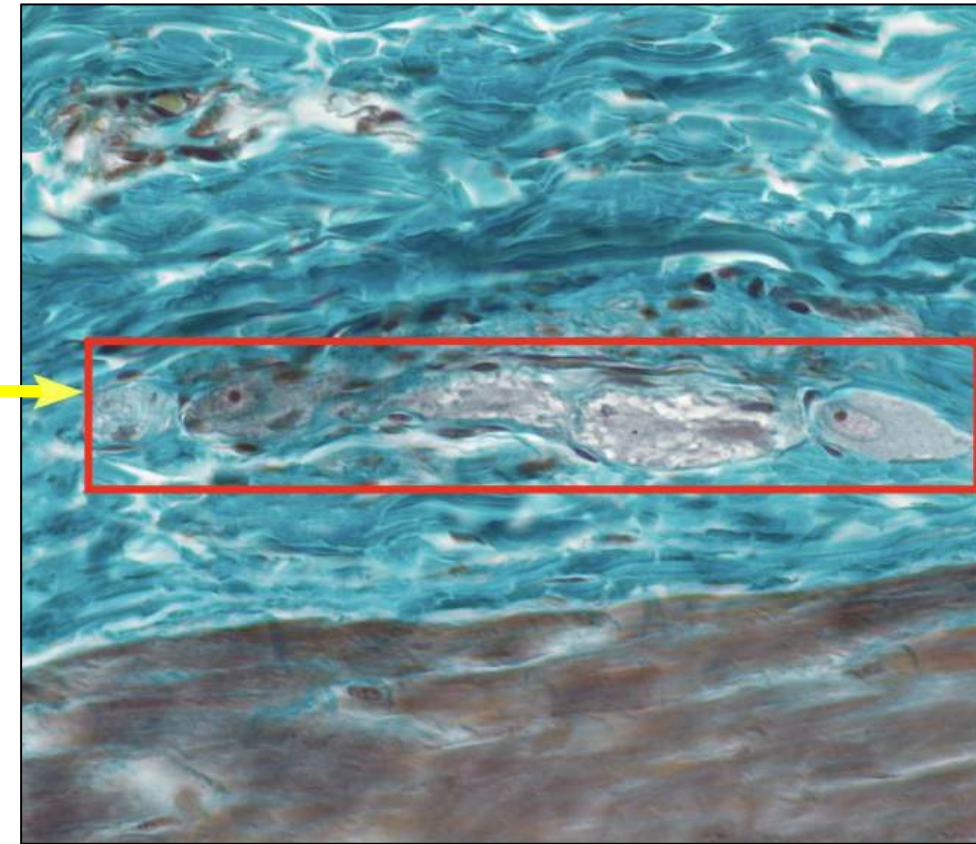
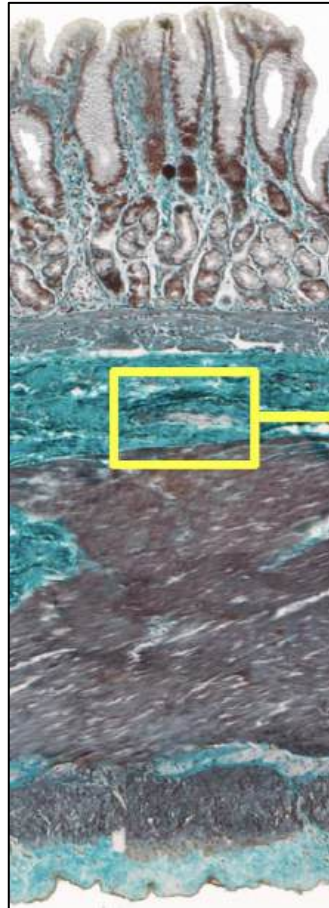


Nervous Tissue of GI Tract – Submucosal/Meissner's Plexus

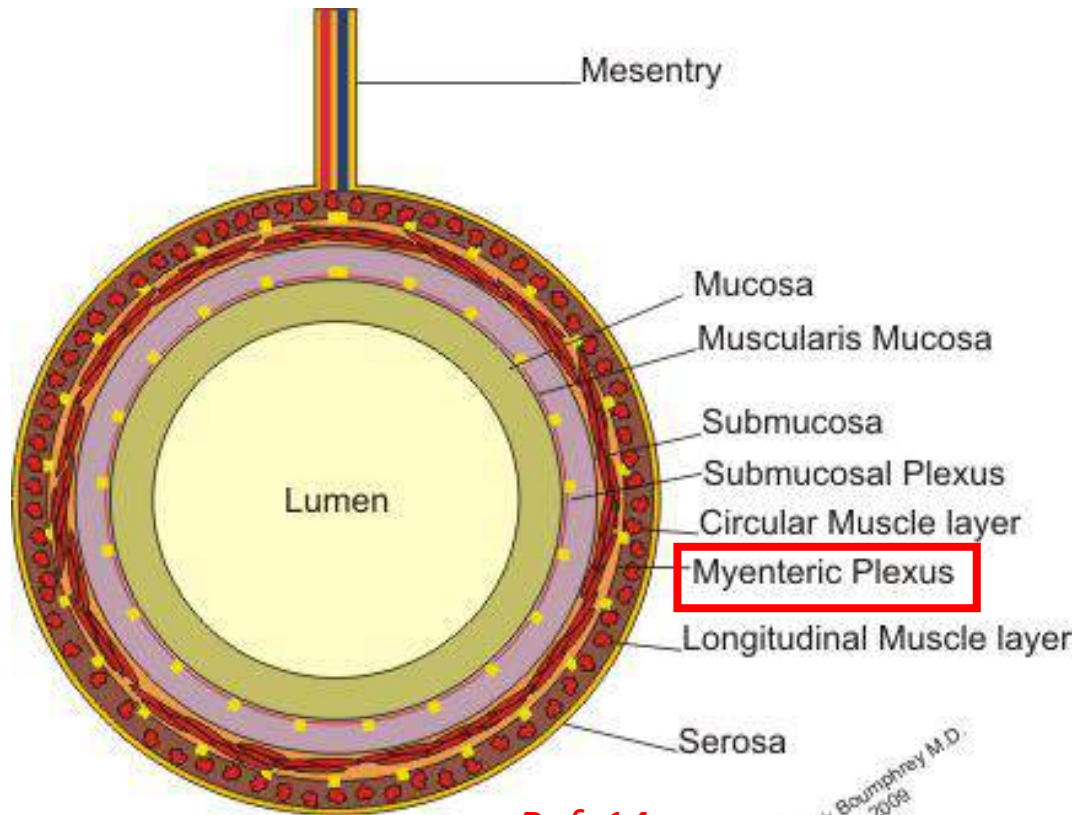


Ref. 14

Frank Baumgartner M.D.
2008

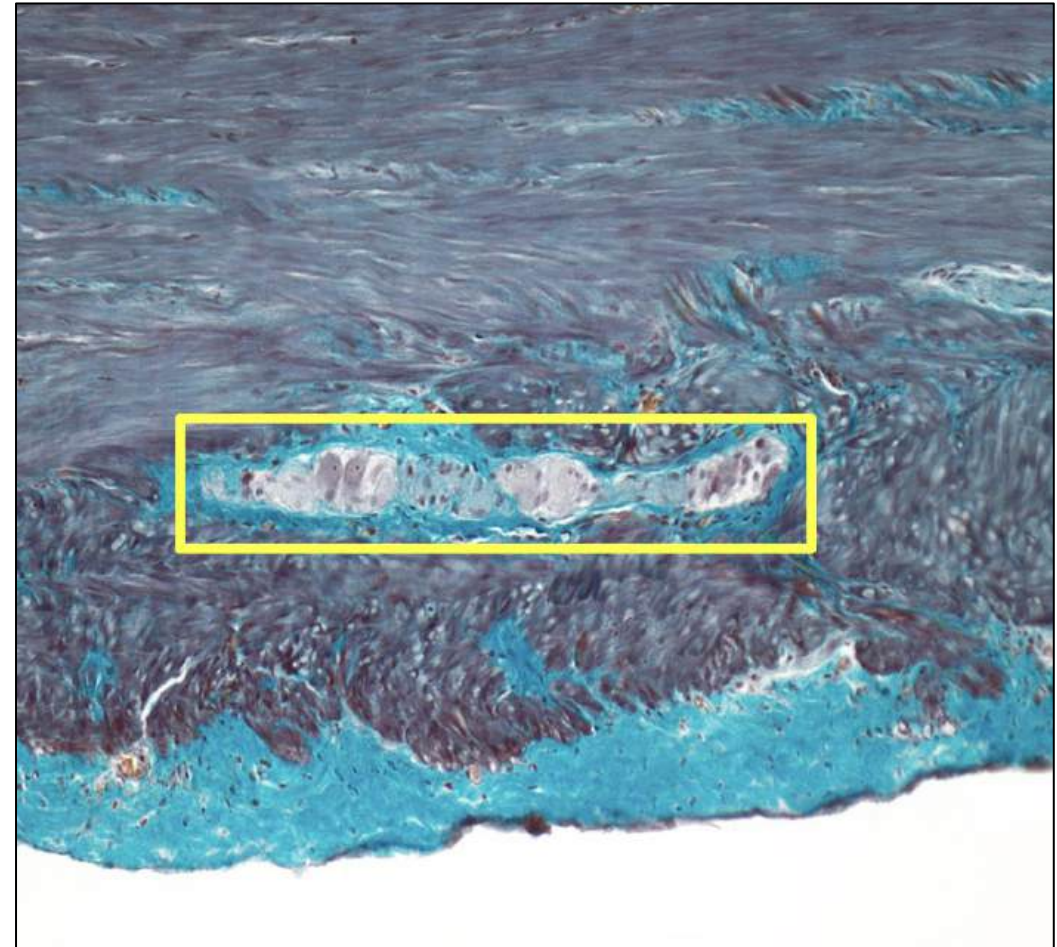


Nervous Tissue of GI Tract – Myenteric/Auerbach's Plexus

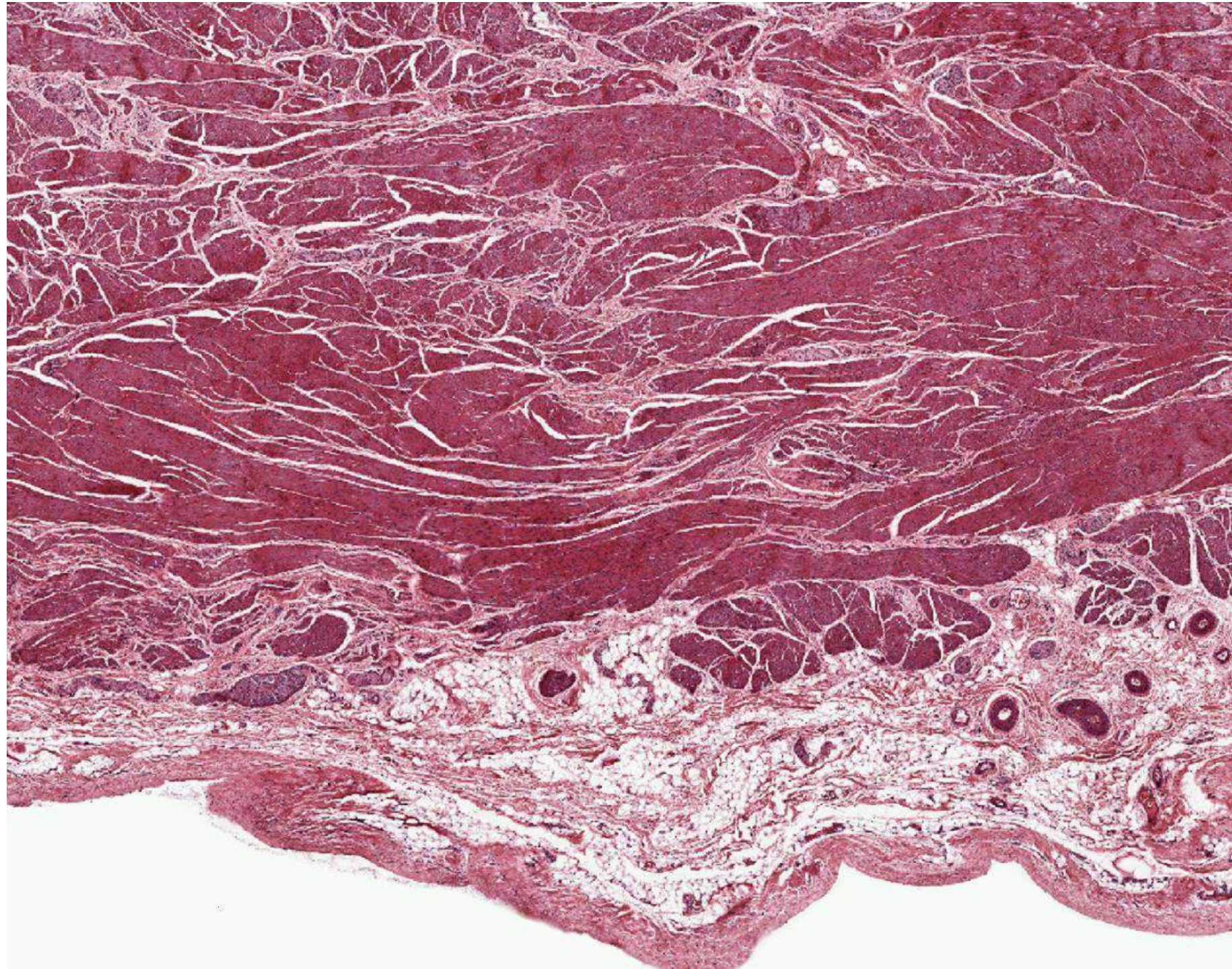


Ref. 14

Frank Boumphey M.D.
2009

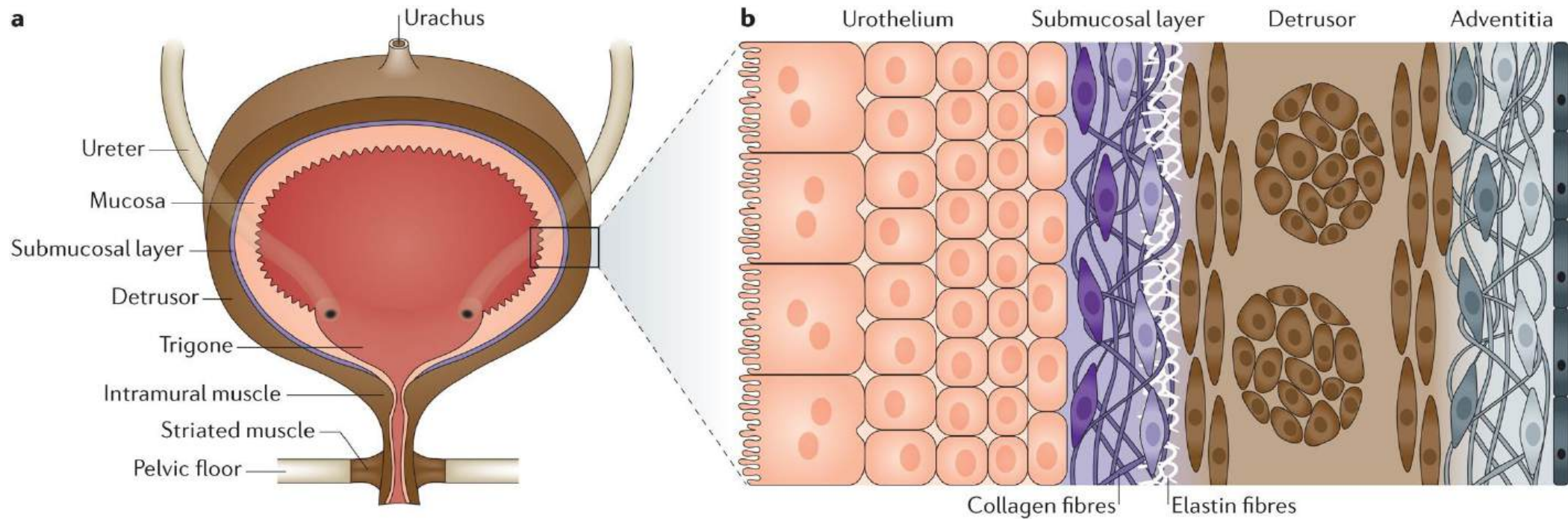


Urinary & Reproductive Systems

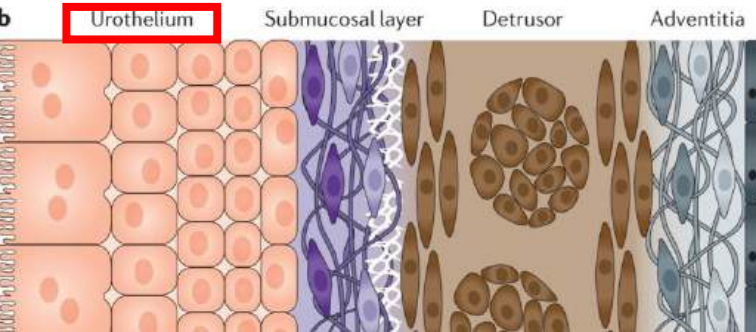
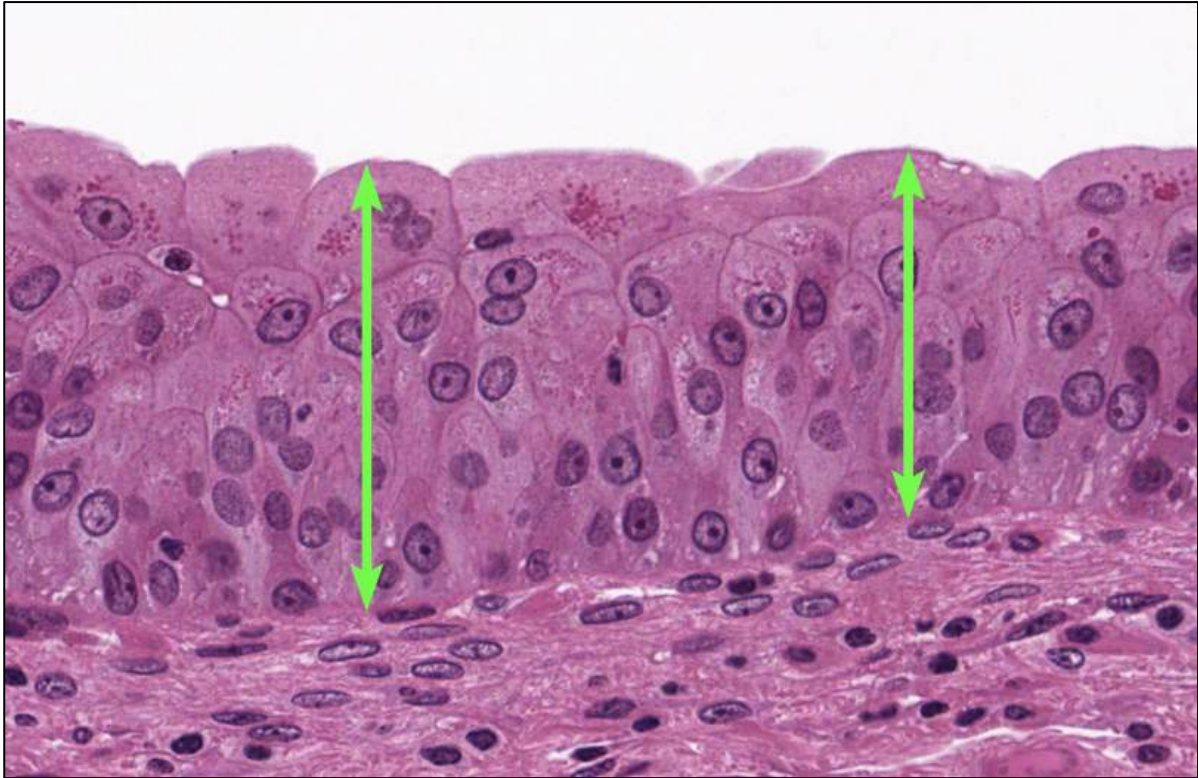
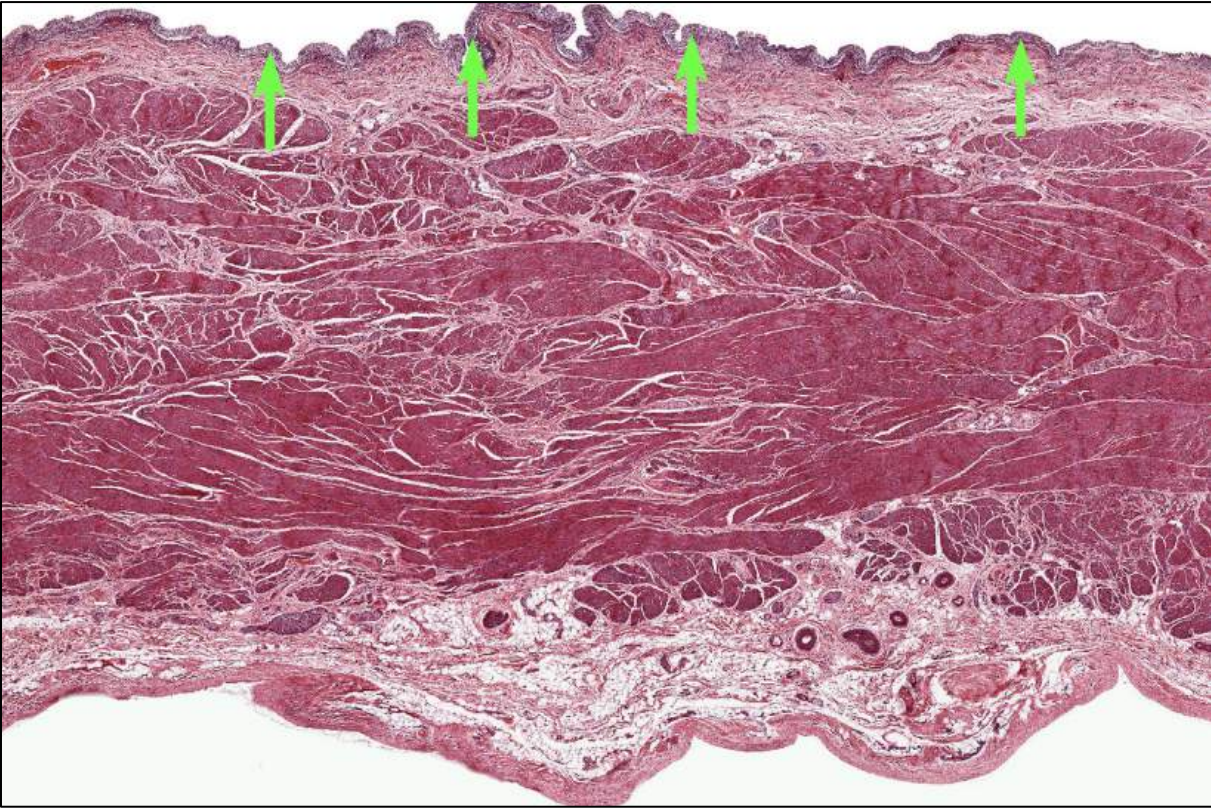


Layers of the Bladder & Ureters

- Transitional Epithelium
- Submucosa
- Muscularis/Detrusor muscle (bladder)
- Adventitia/Serosa

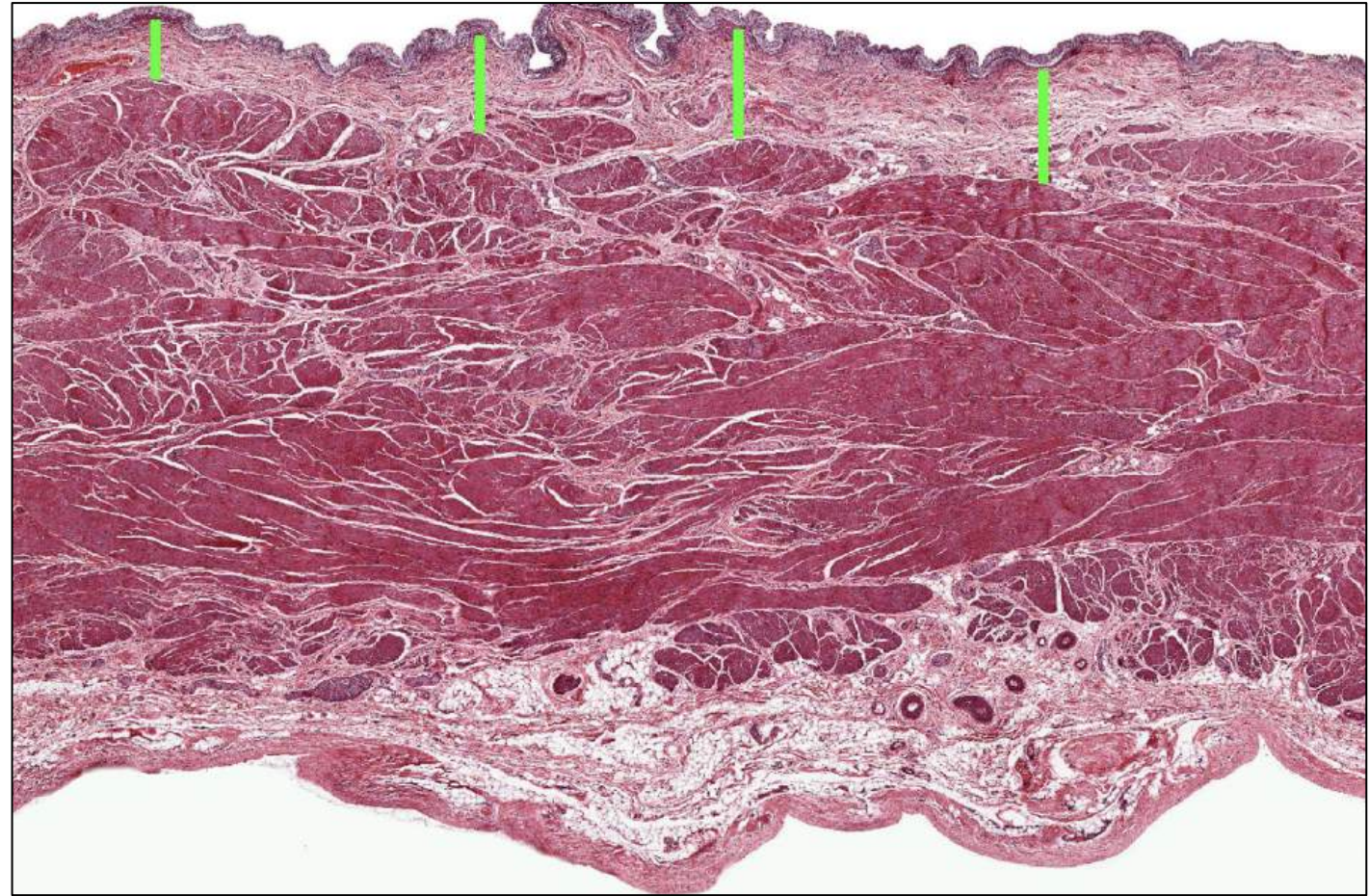
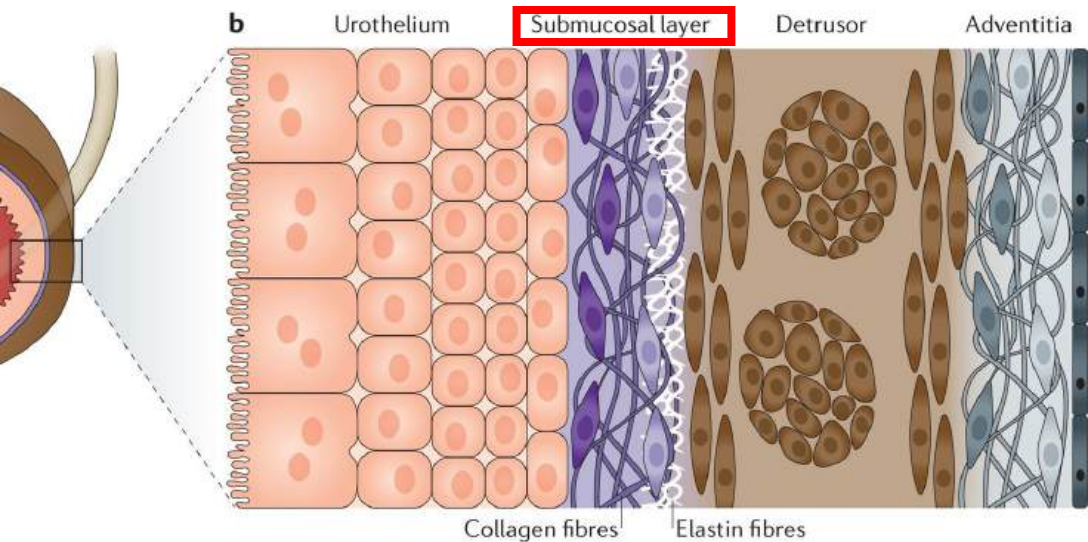


Bladder Layers – Transitional Epithelium

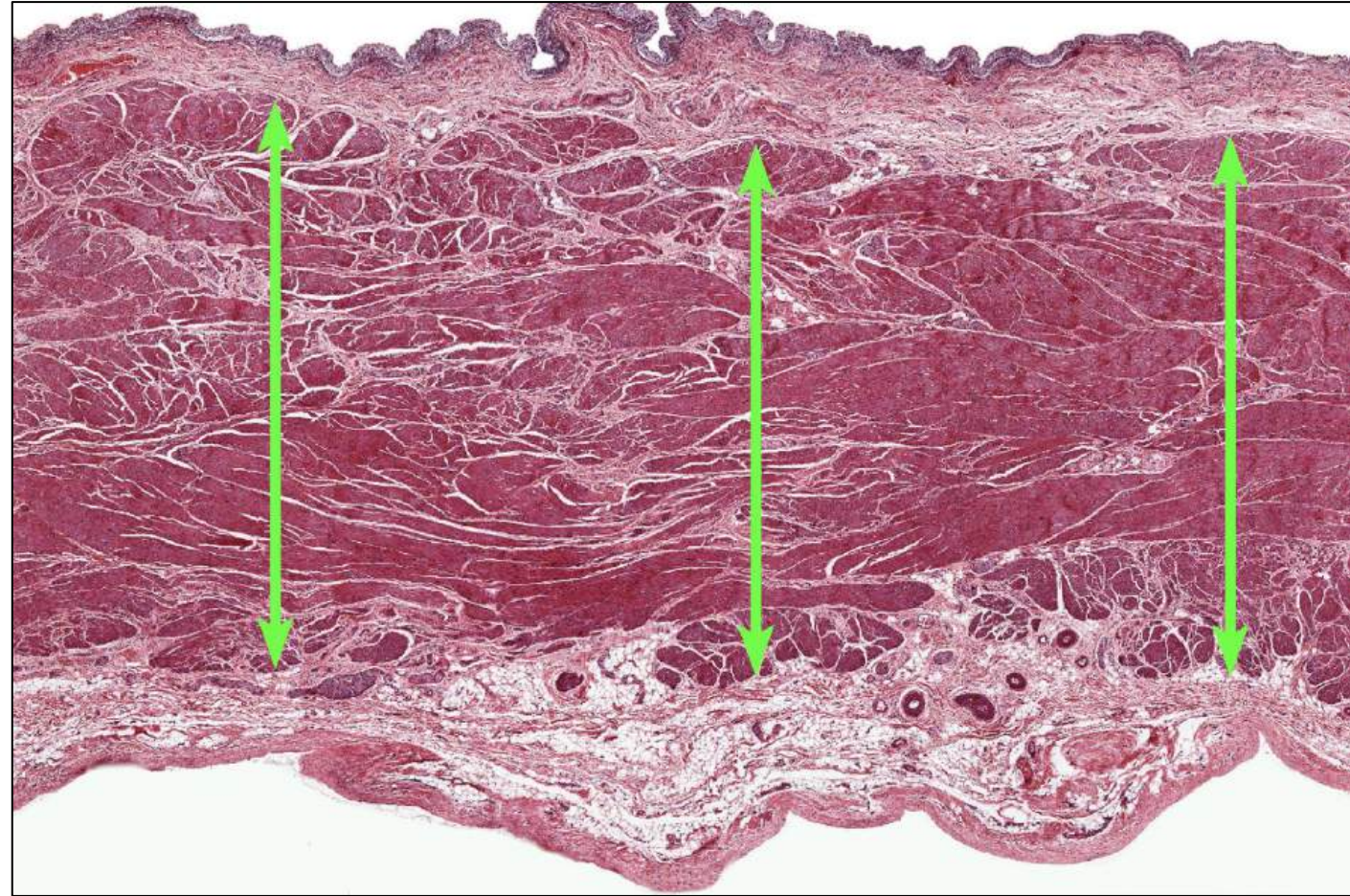
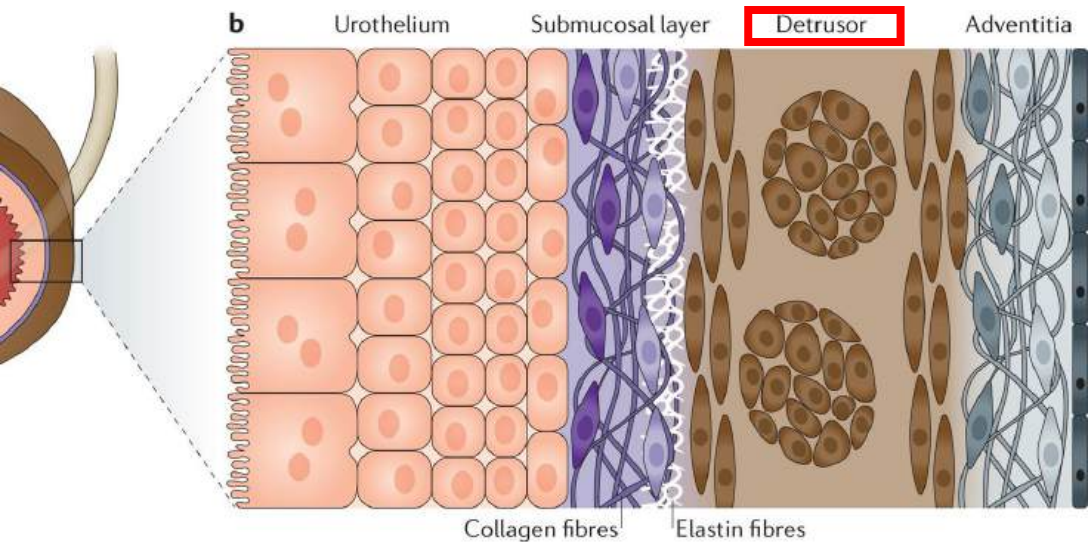


Ref. 15

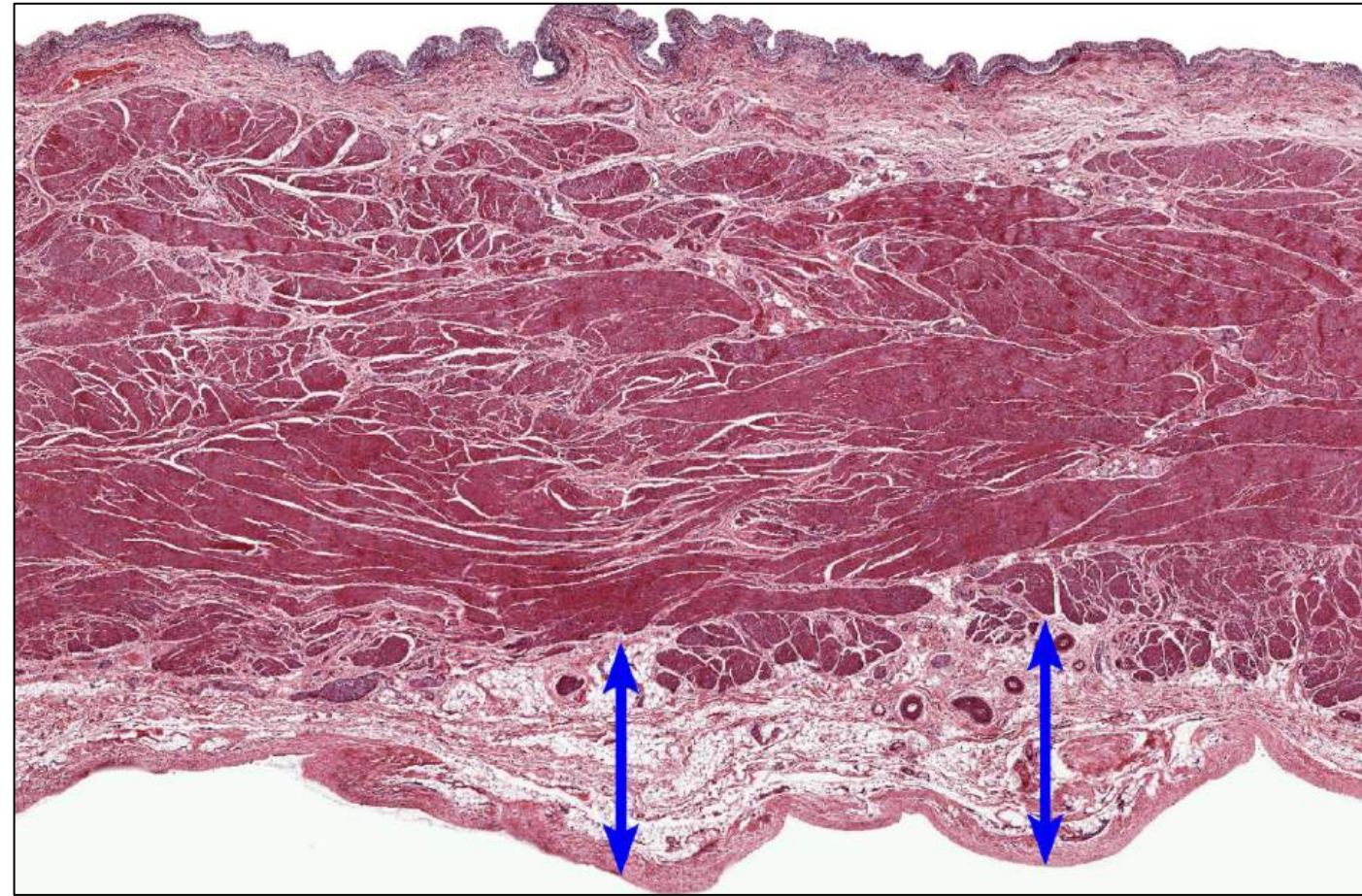
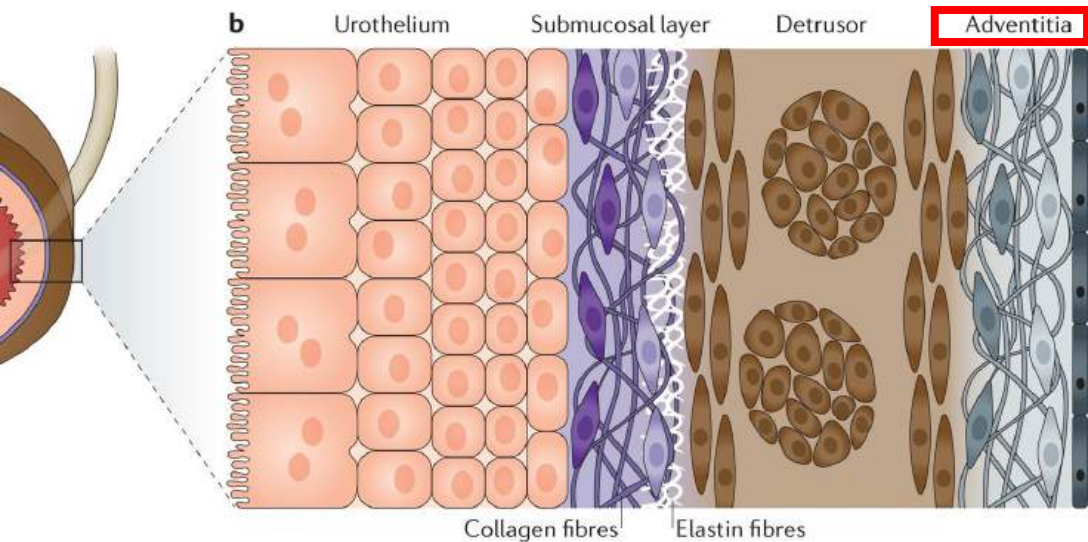
Bladder Layers – Submucosa



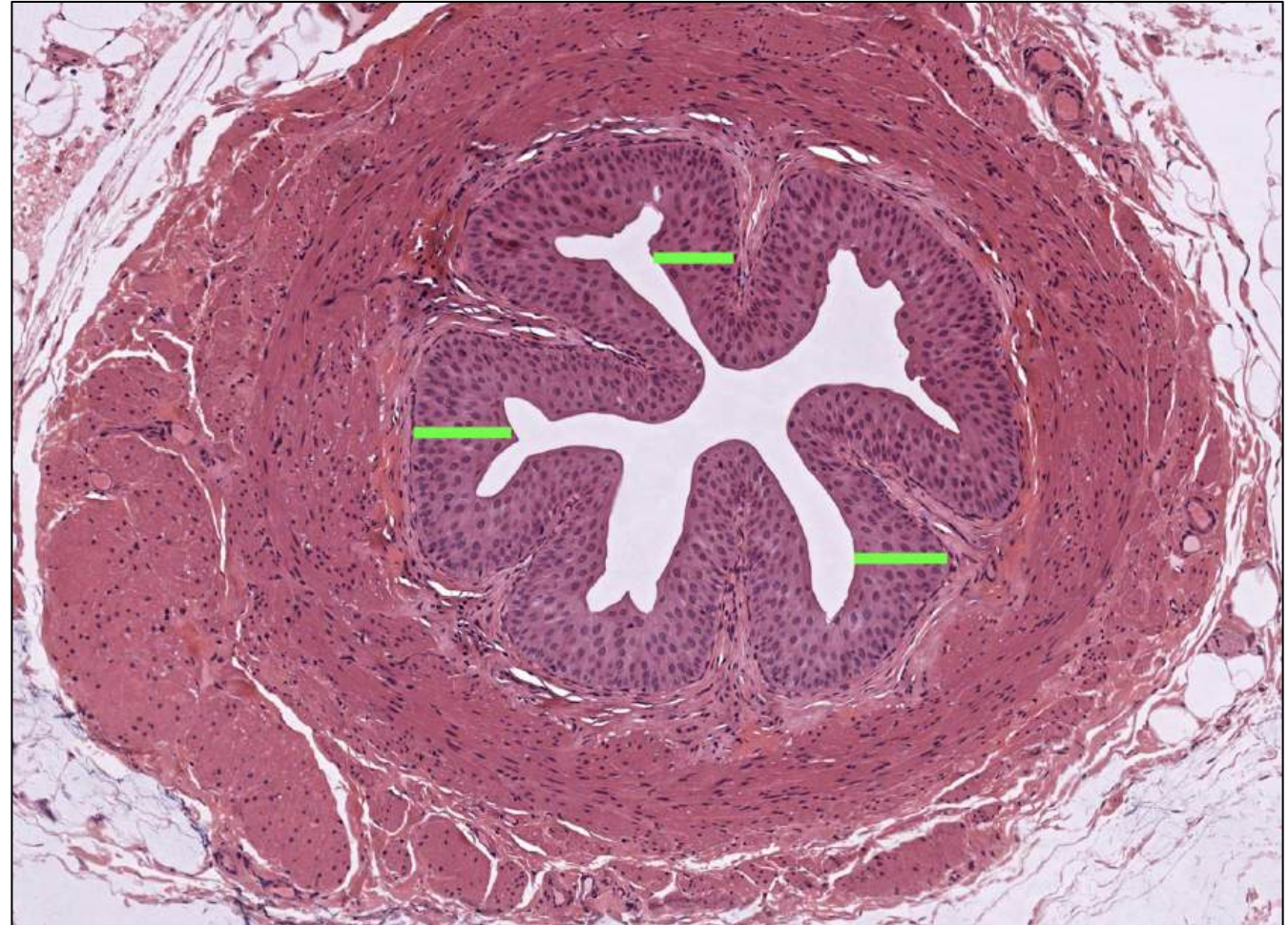
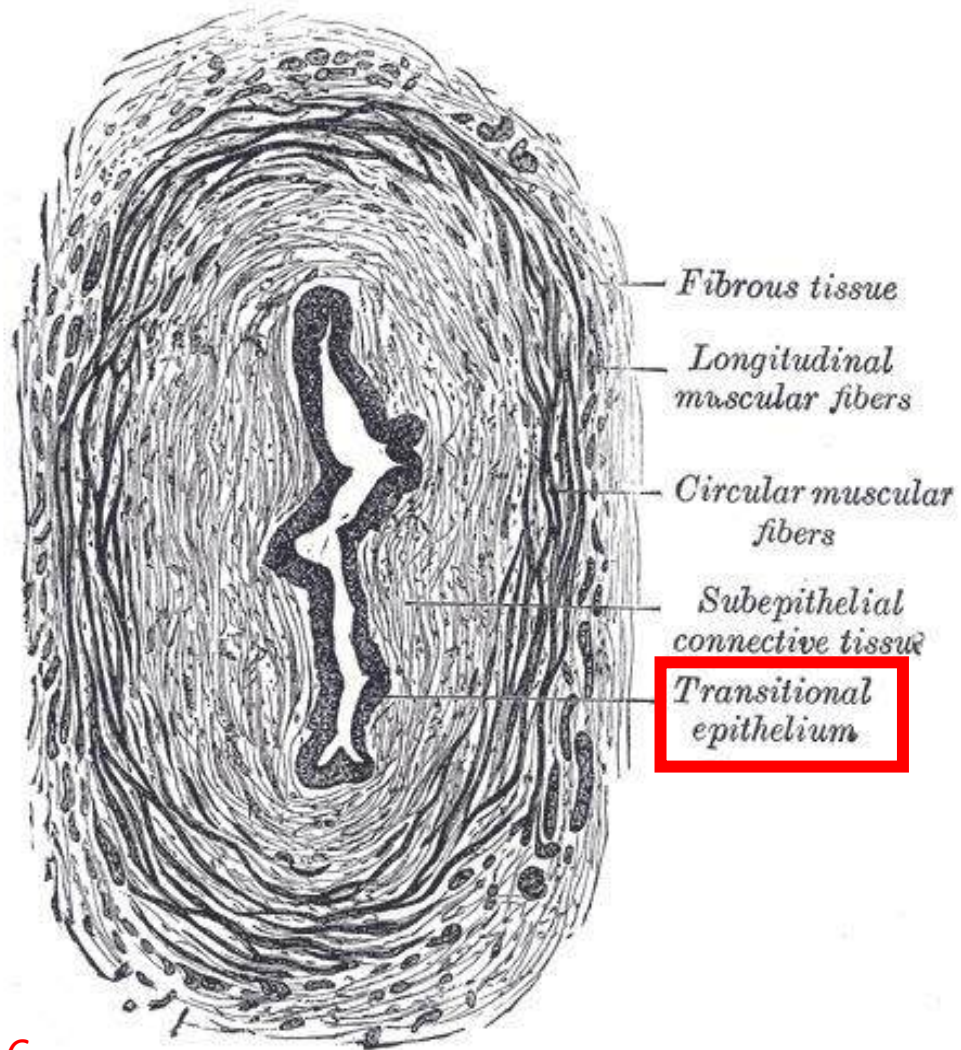
Bladder Layers – Muscularis/Detrusor Muscle



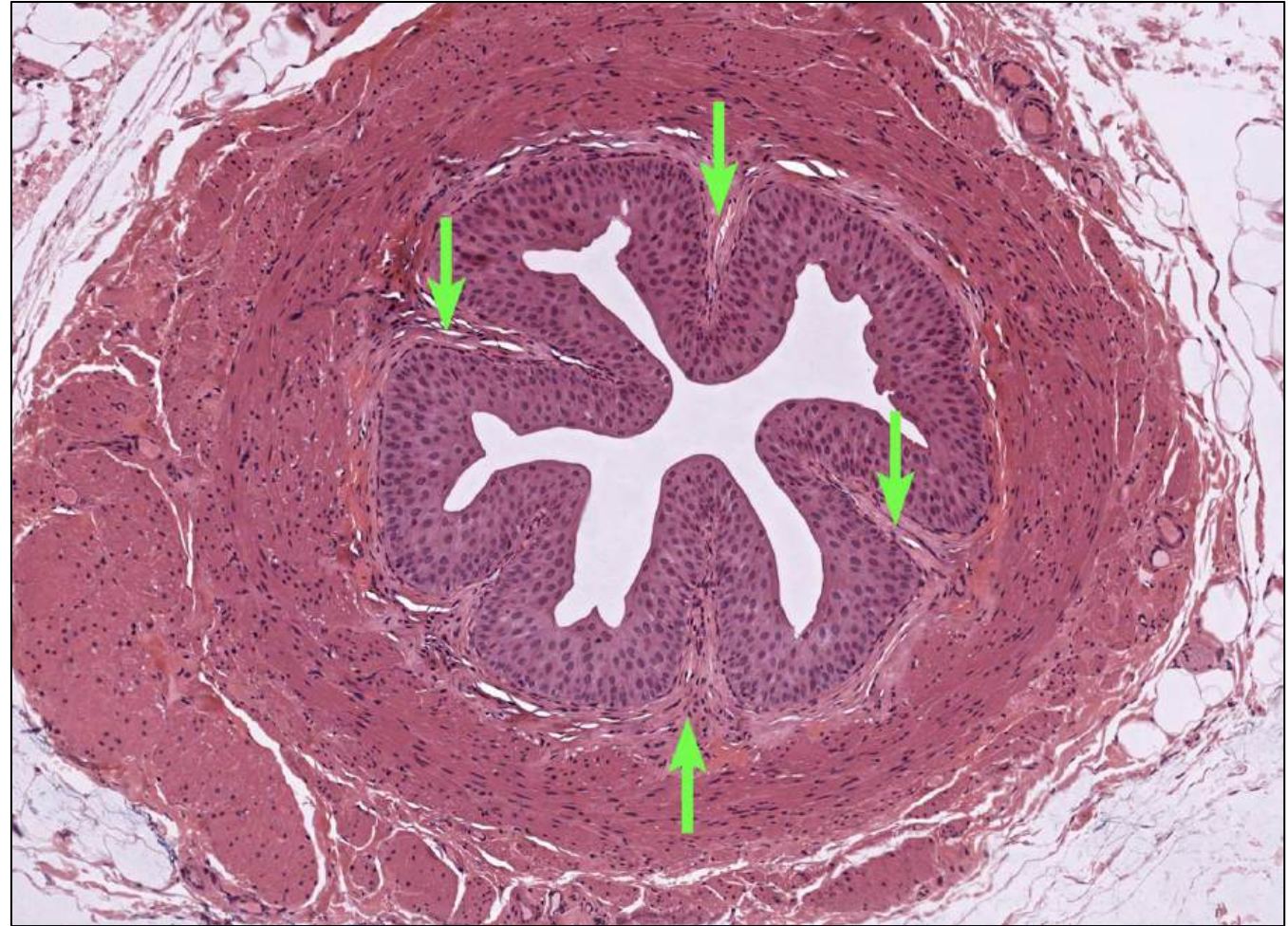
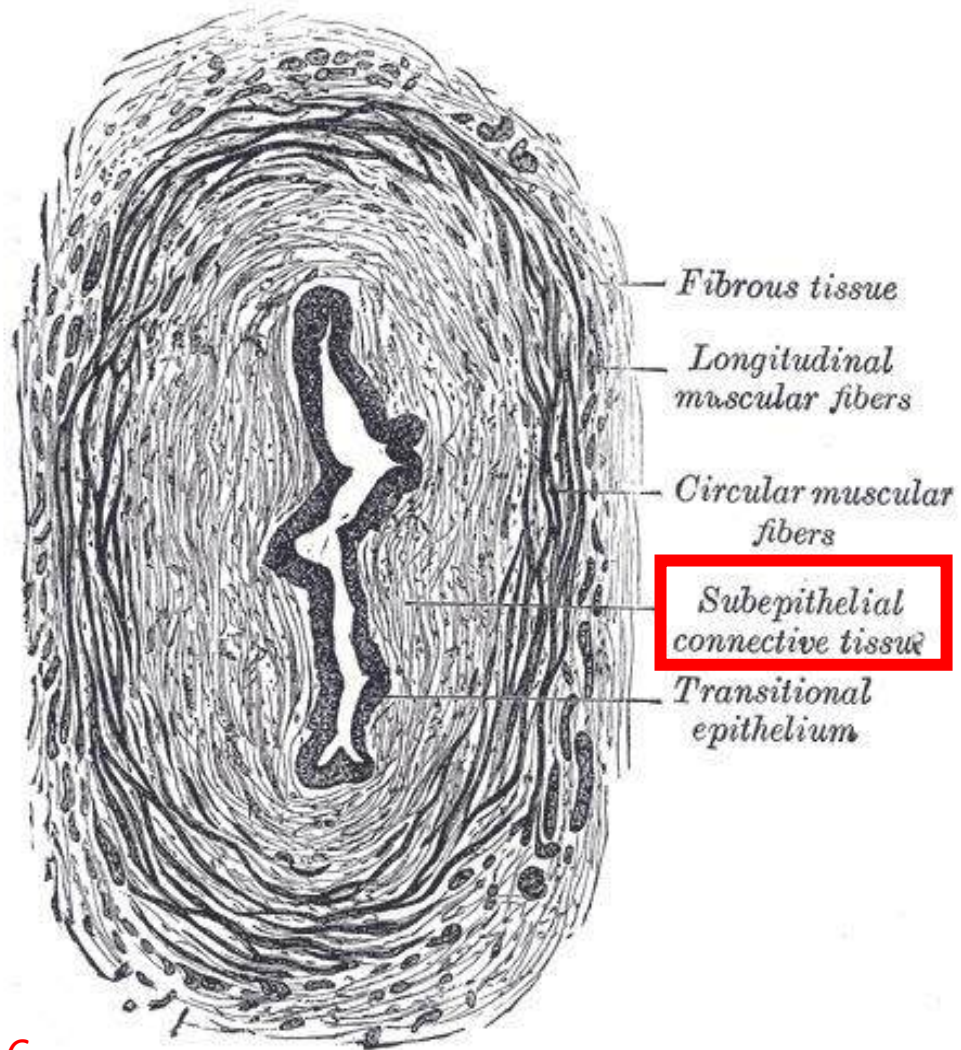
Bladder Layers – Adventitia/Serosa



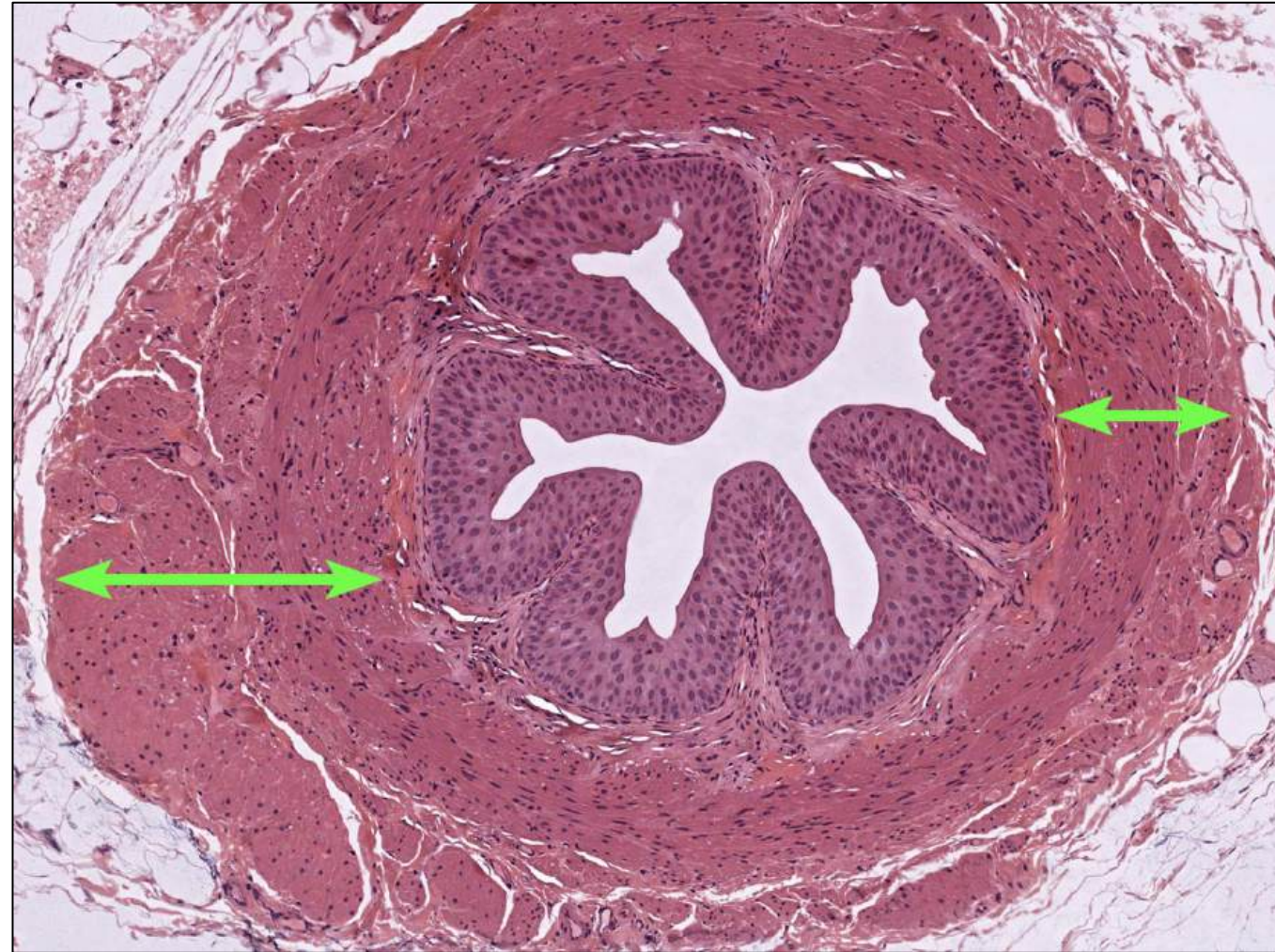
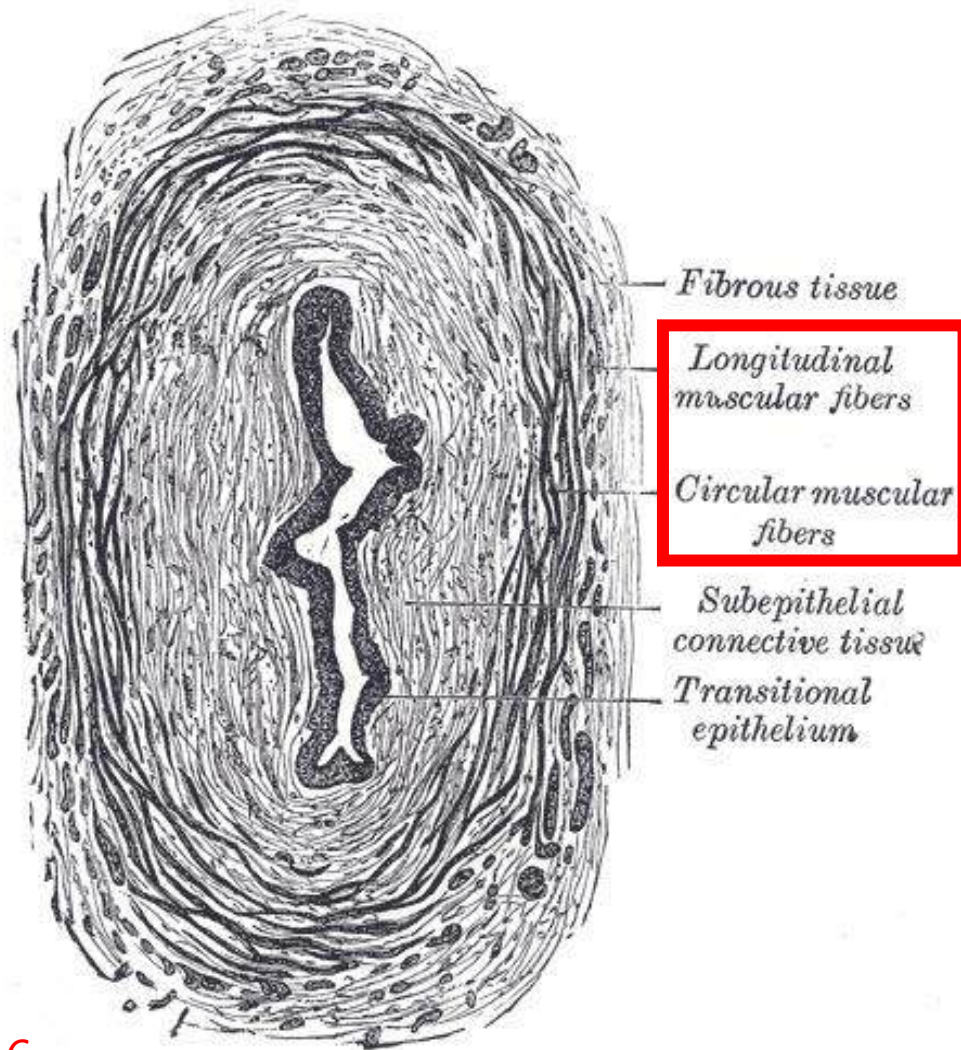
Ureter Layers – Transitional Epithelium



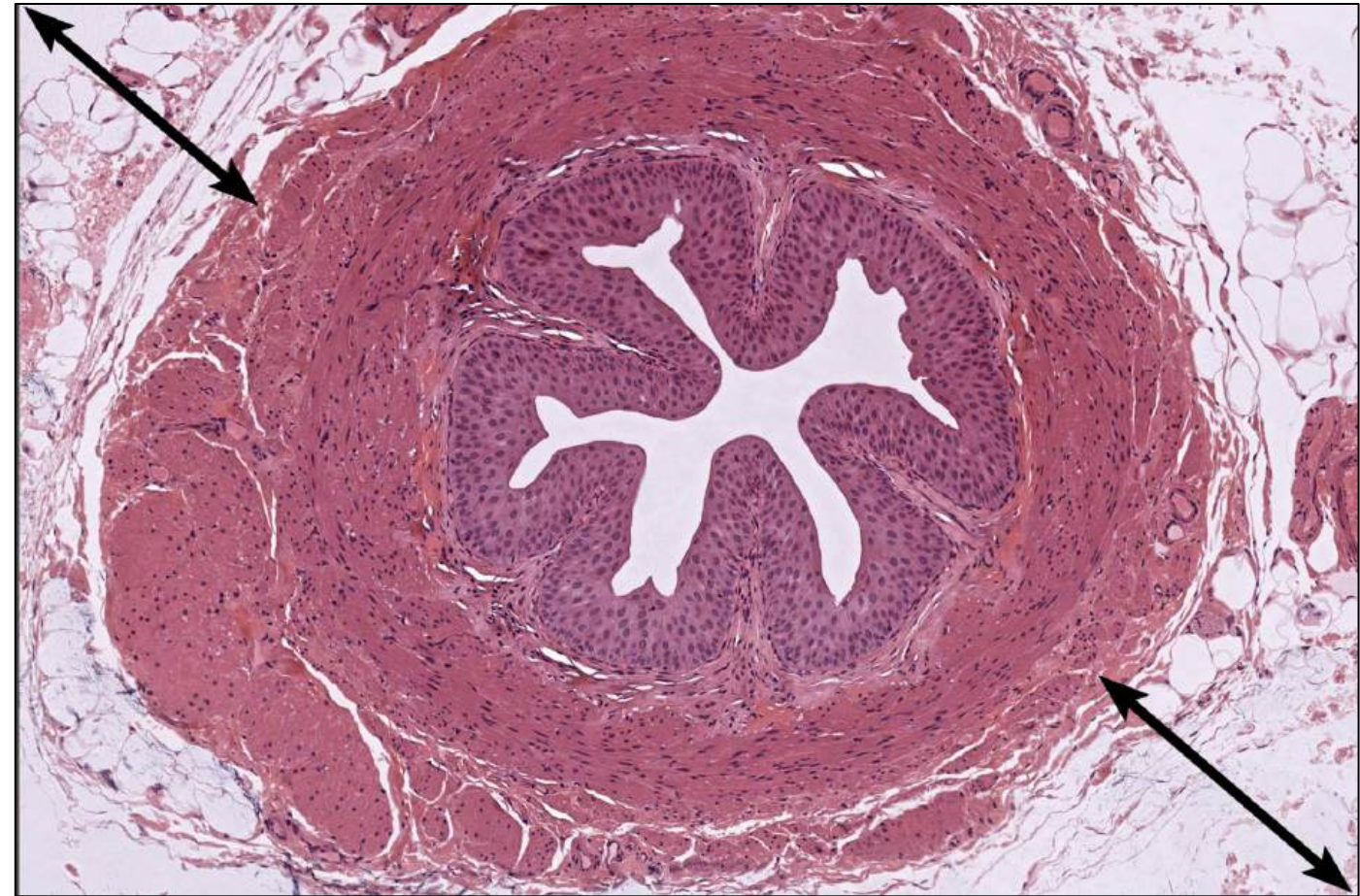
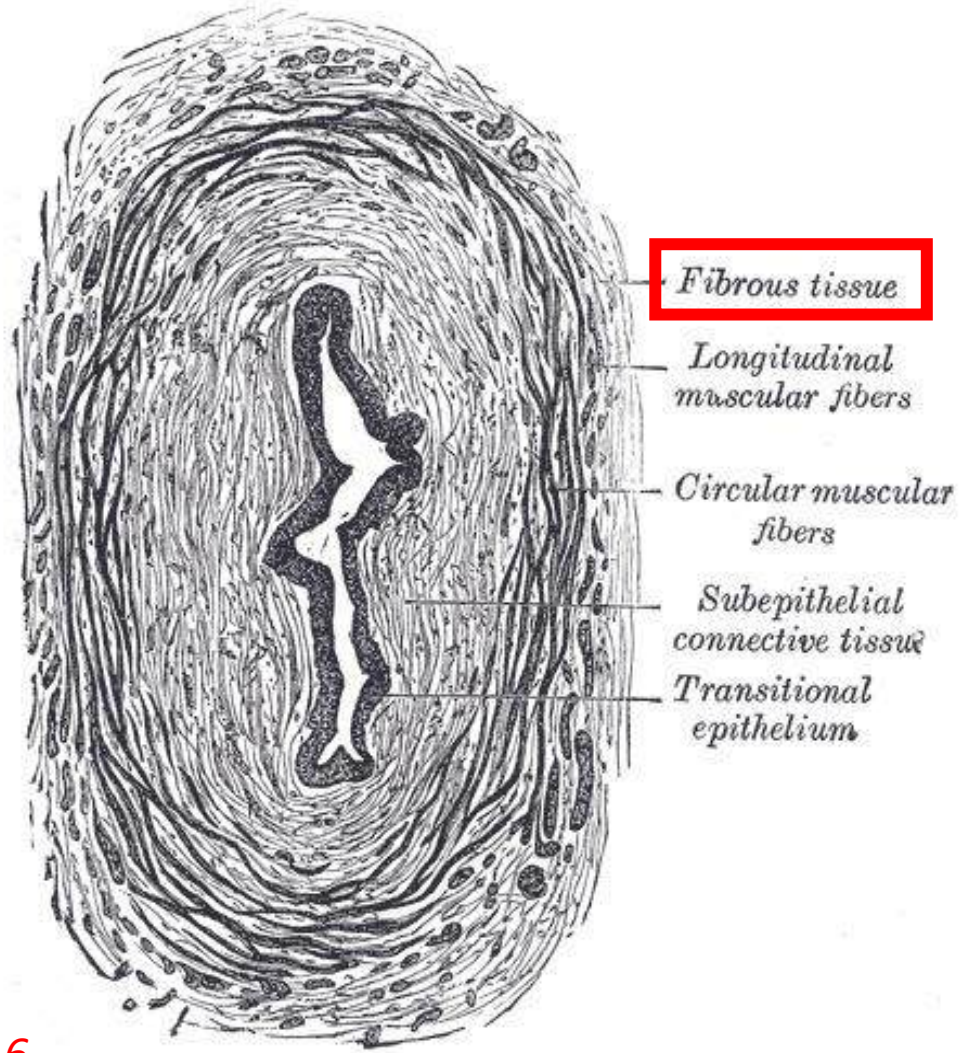
Ureter Layers – Submucosa



Ureter Layers – Muscularis



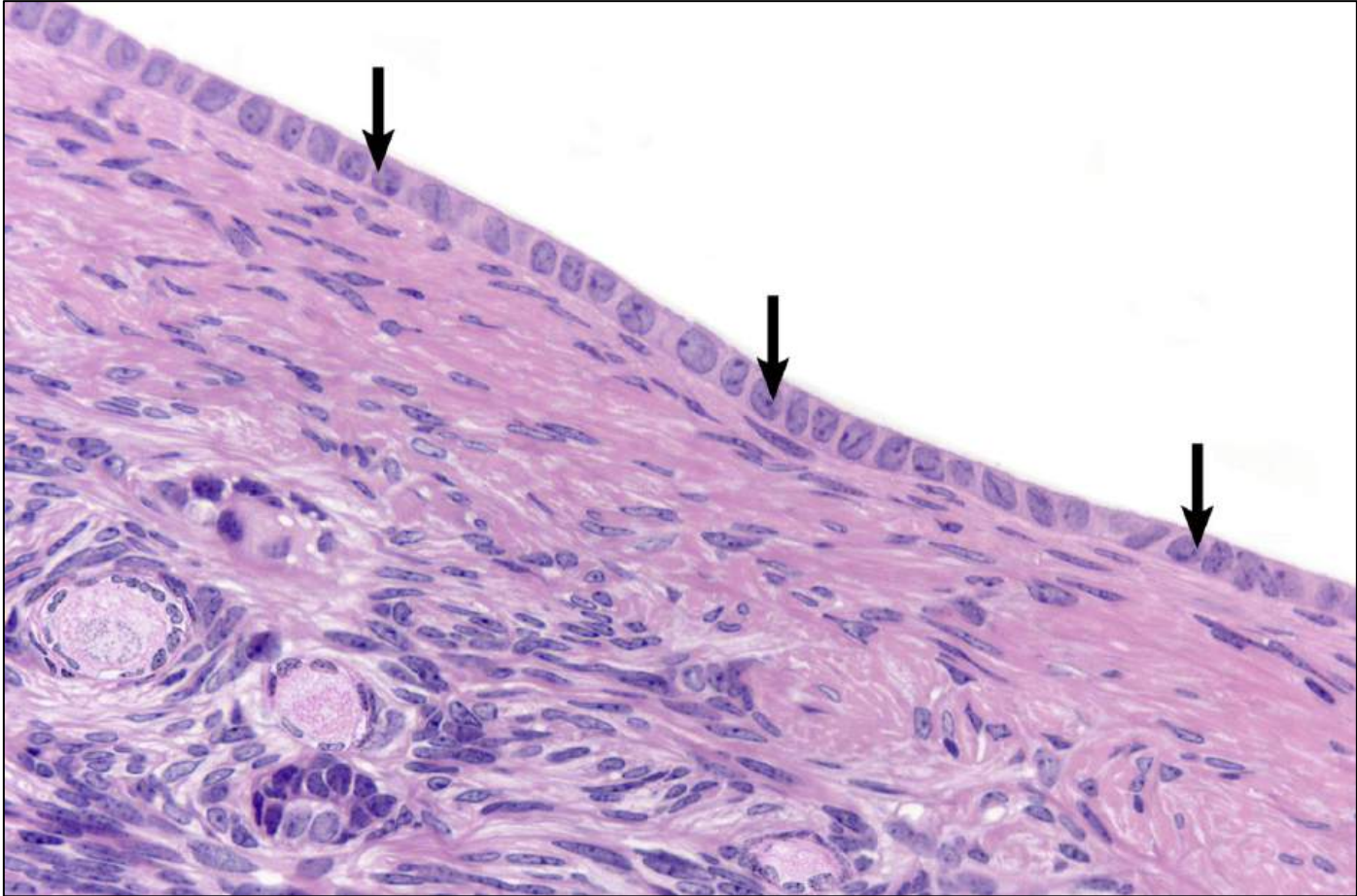
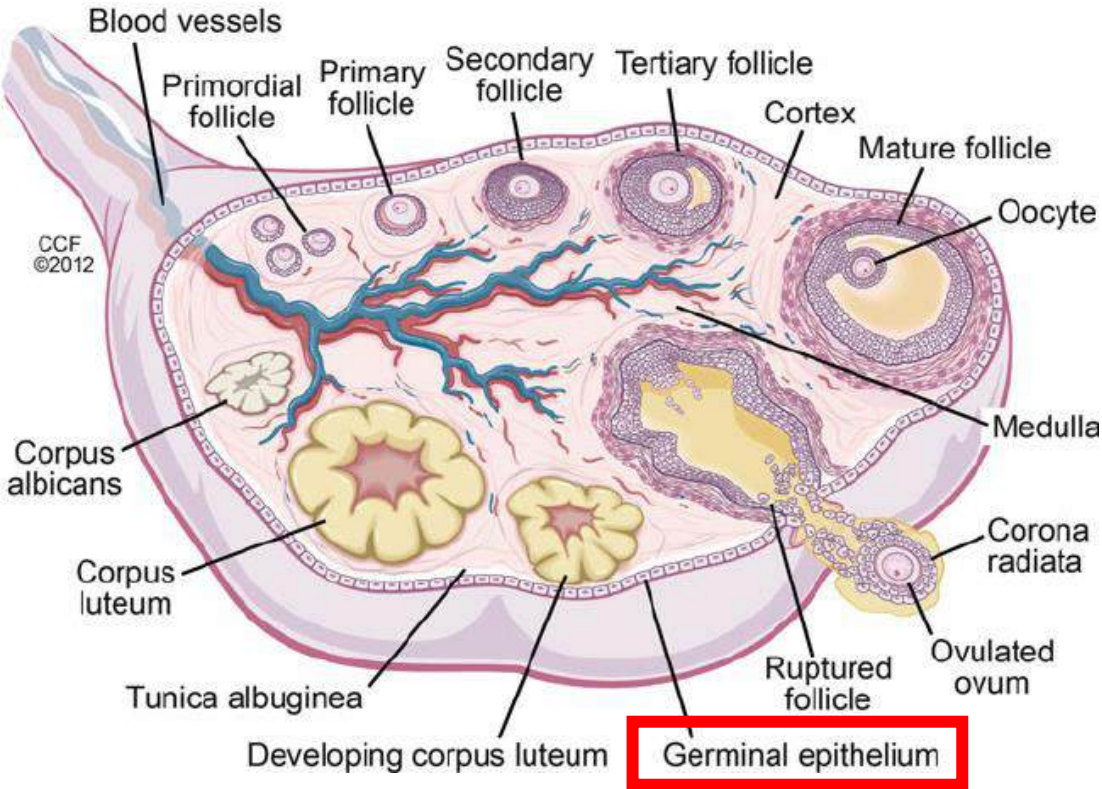
Ureter Layers – Adventitia



Structures of the Ovary

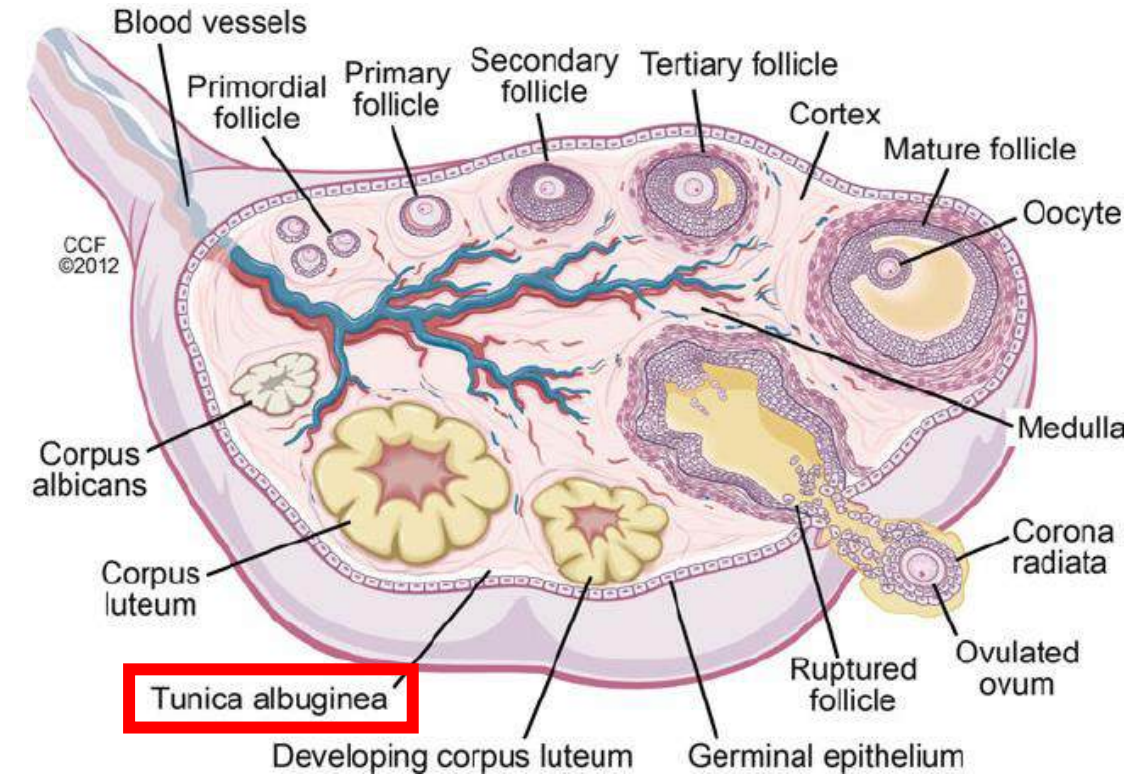
- Germinal Epithelium
- Capsule
- Cortex
- Medulla
- Follicles/Oocyte

Ovary Layers – Germinal Epithelium

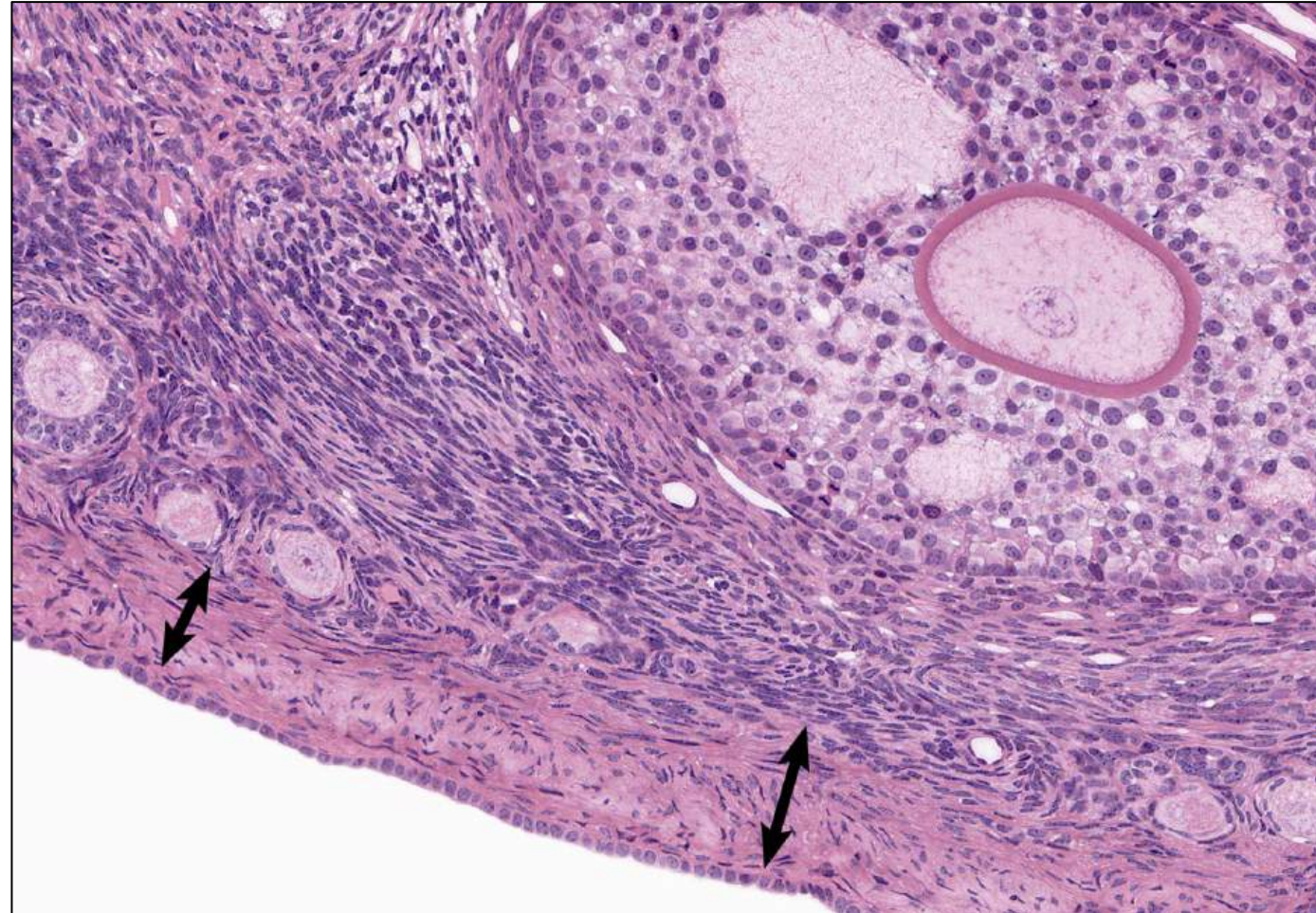


Ref. 17

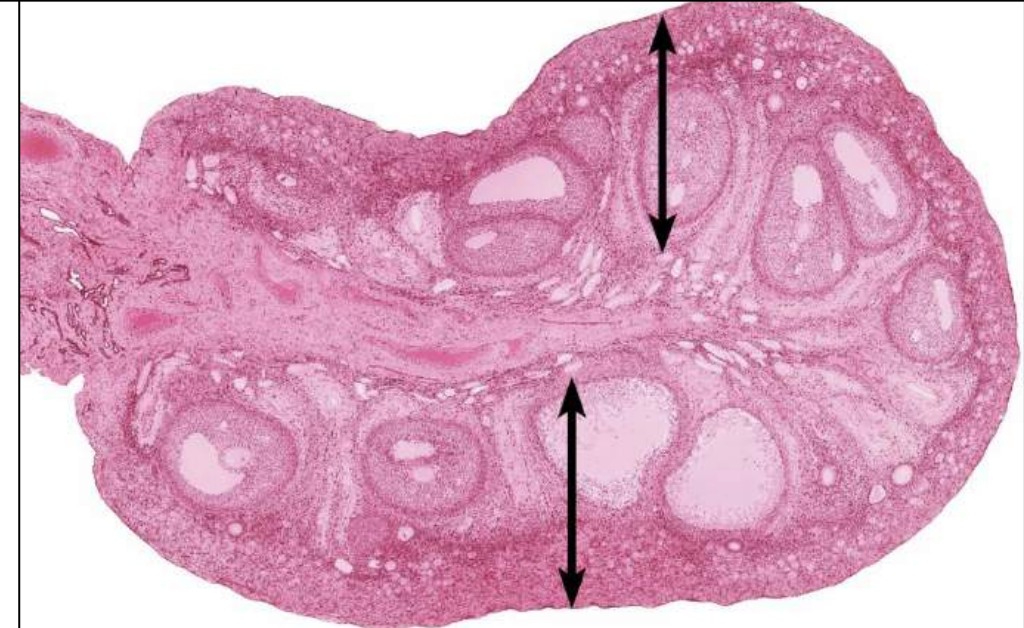
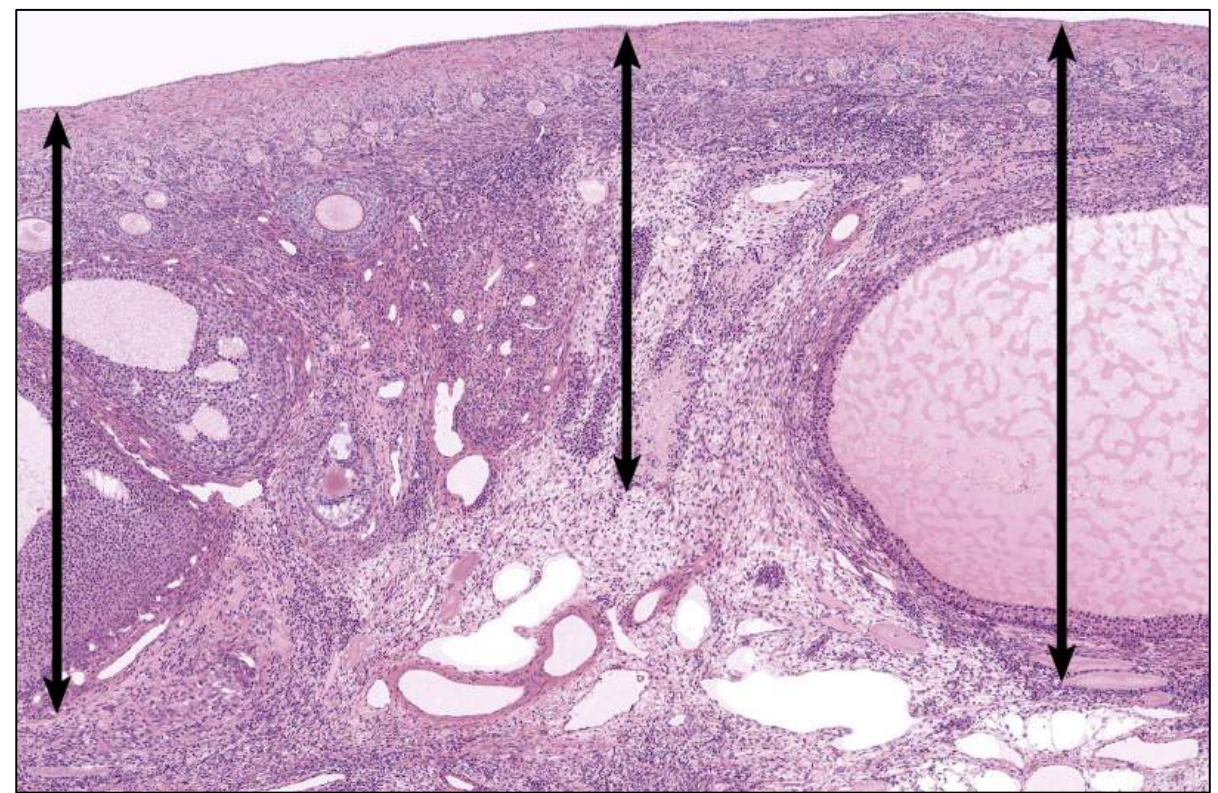
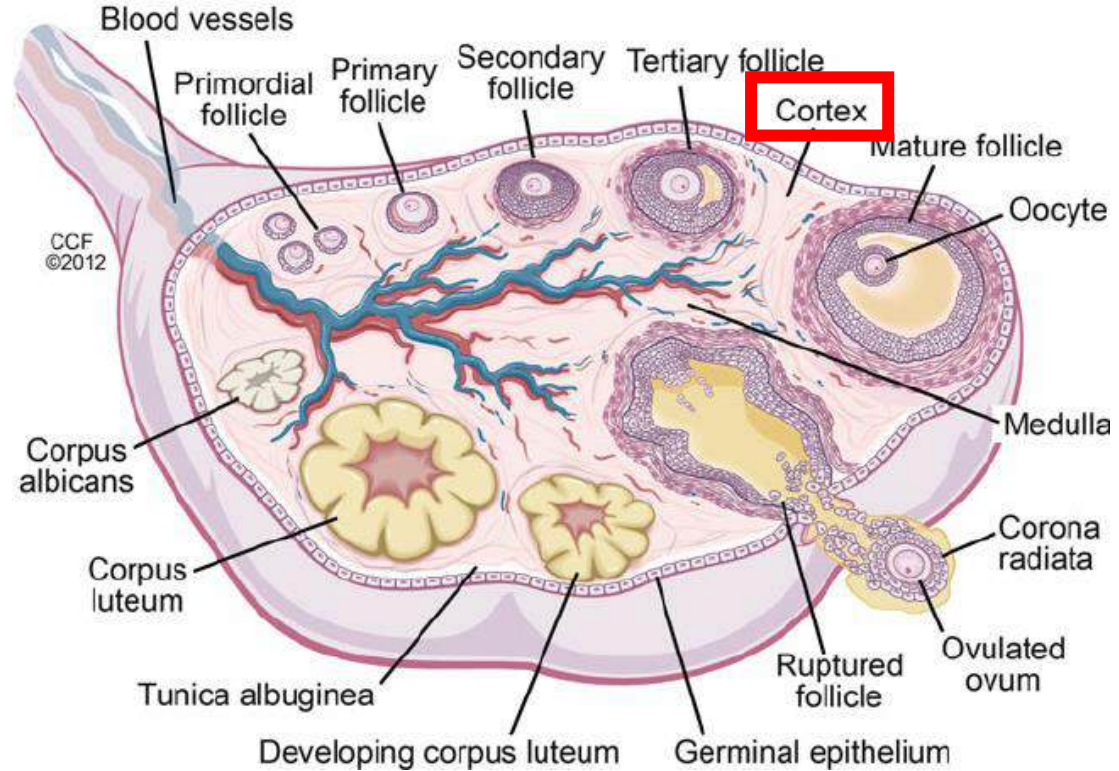
Ovary Layers – Capsule (Tunica albuginea)



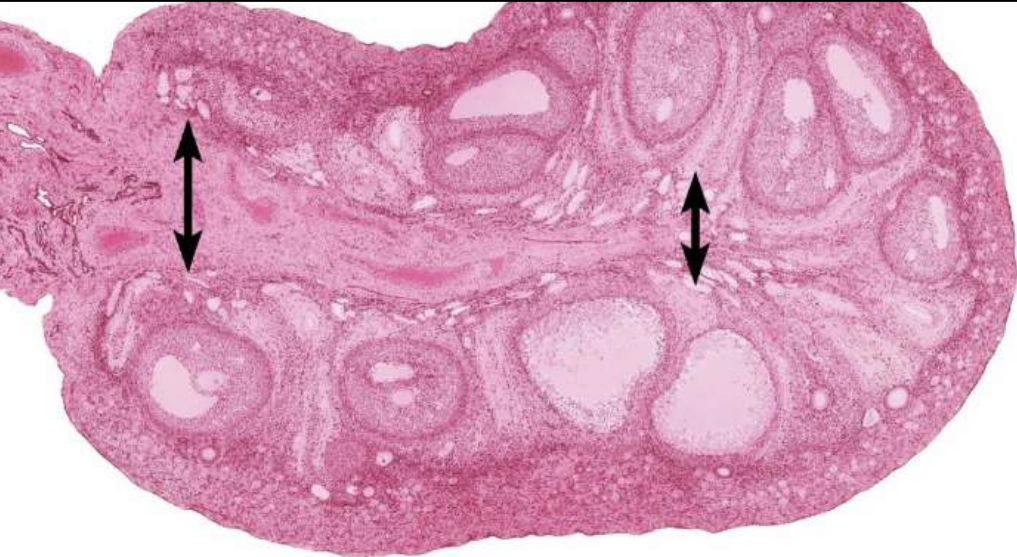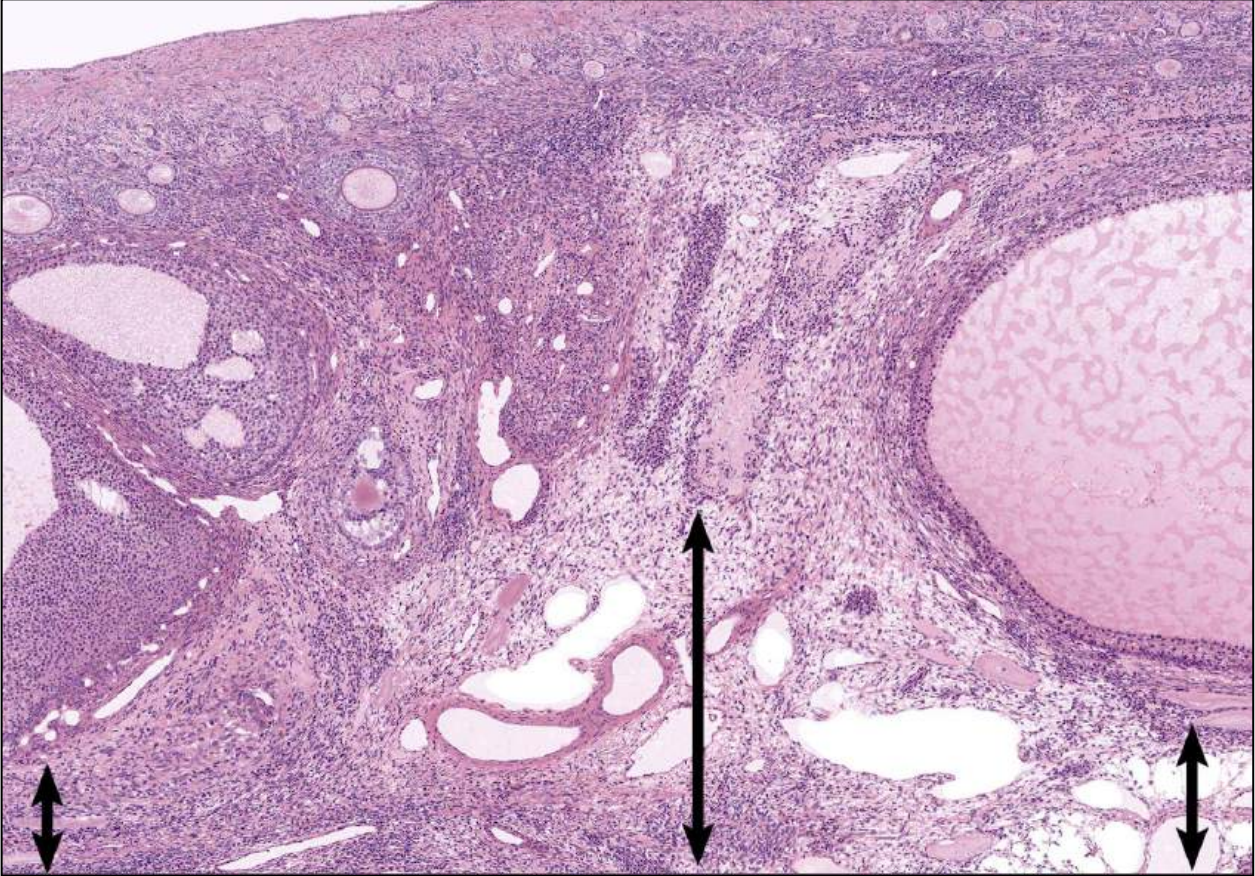
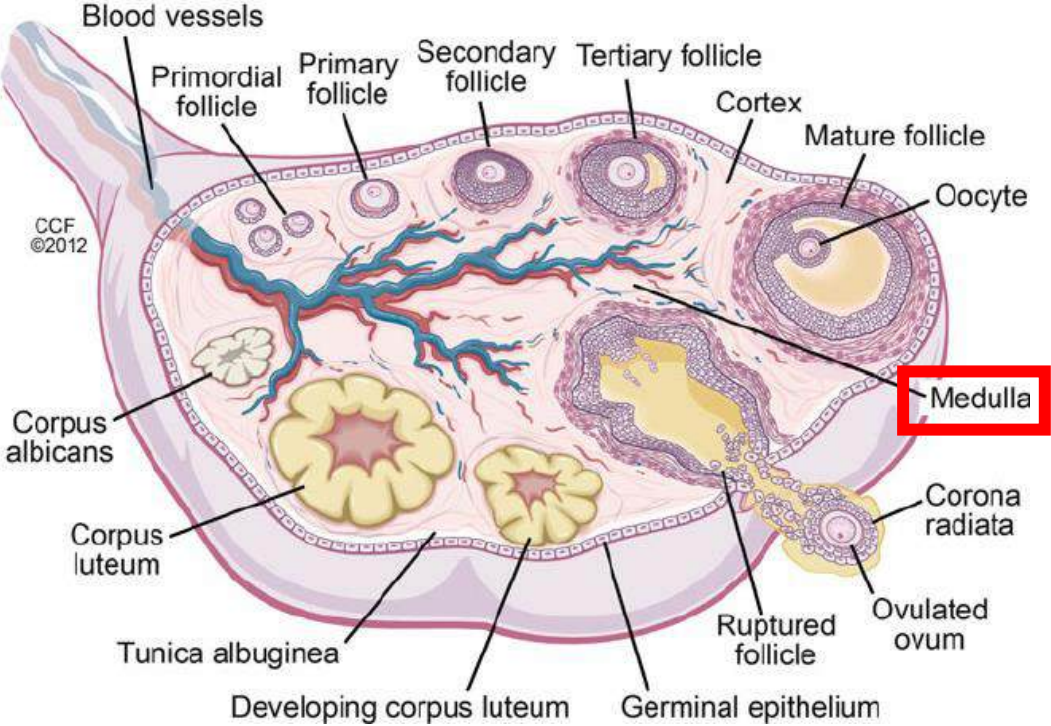
Ref. 17



Ovary Layers – Cortex

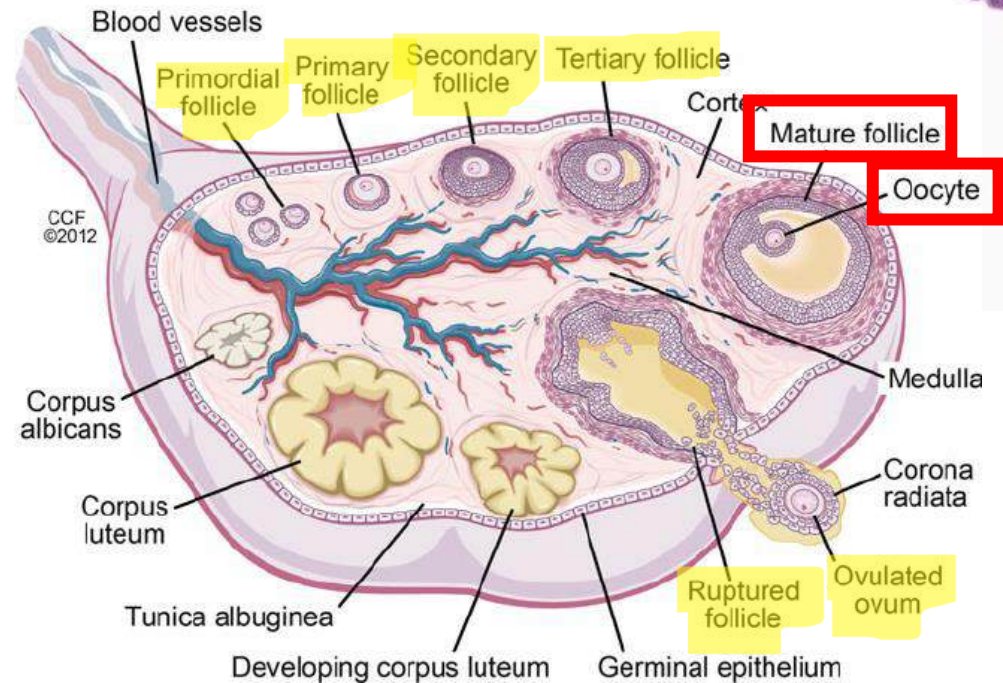
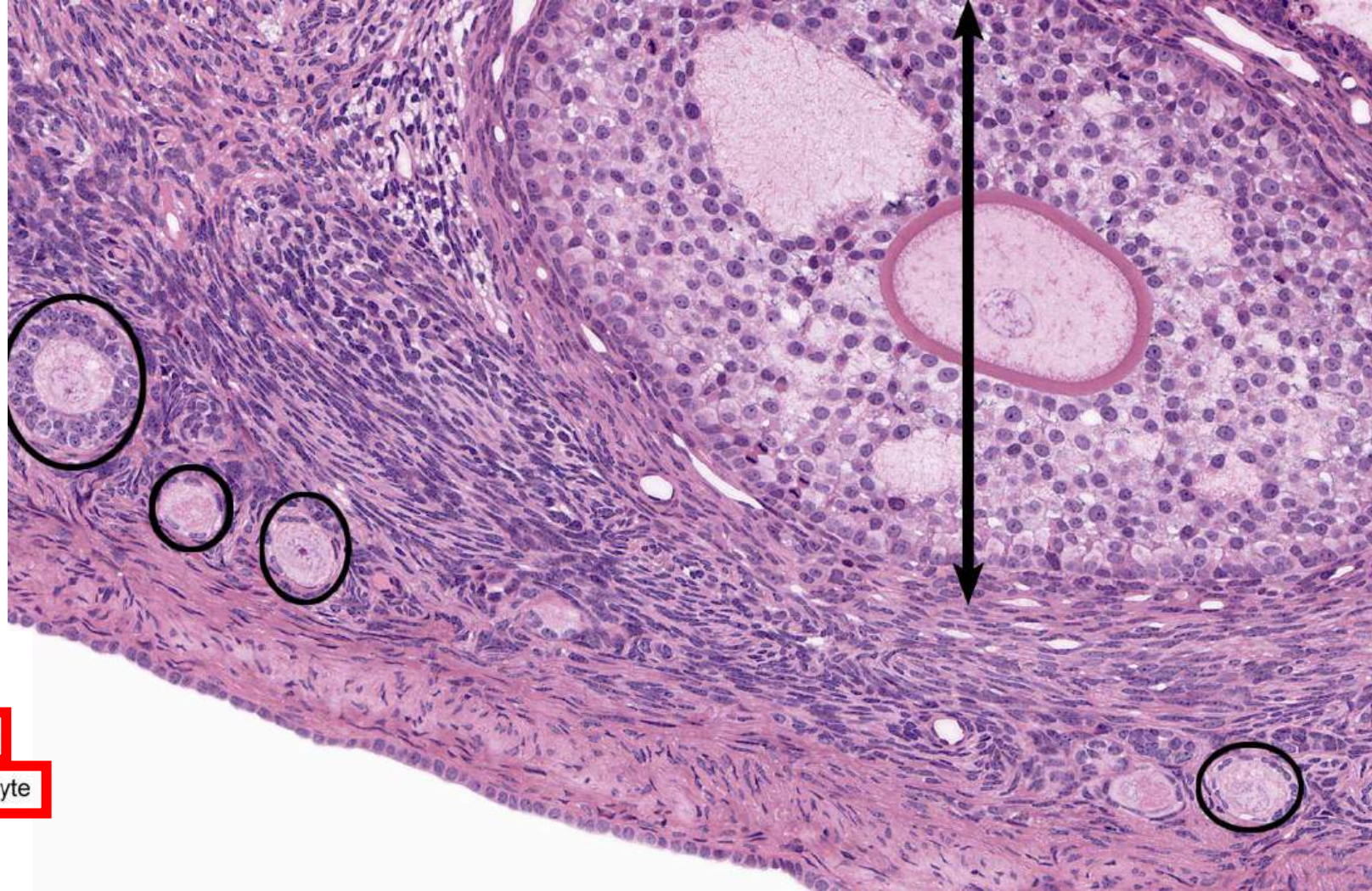


Ovary Layers – Medulla



Ref. 17

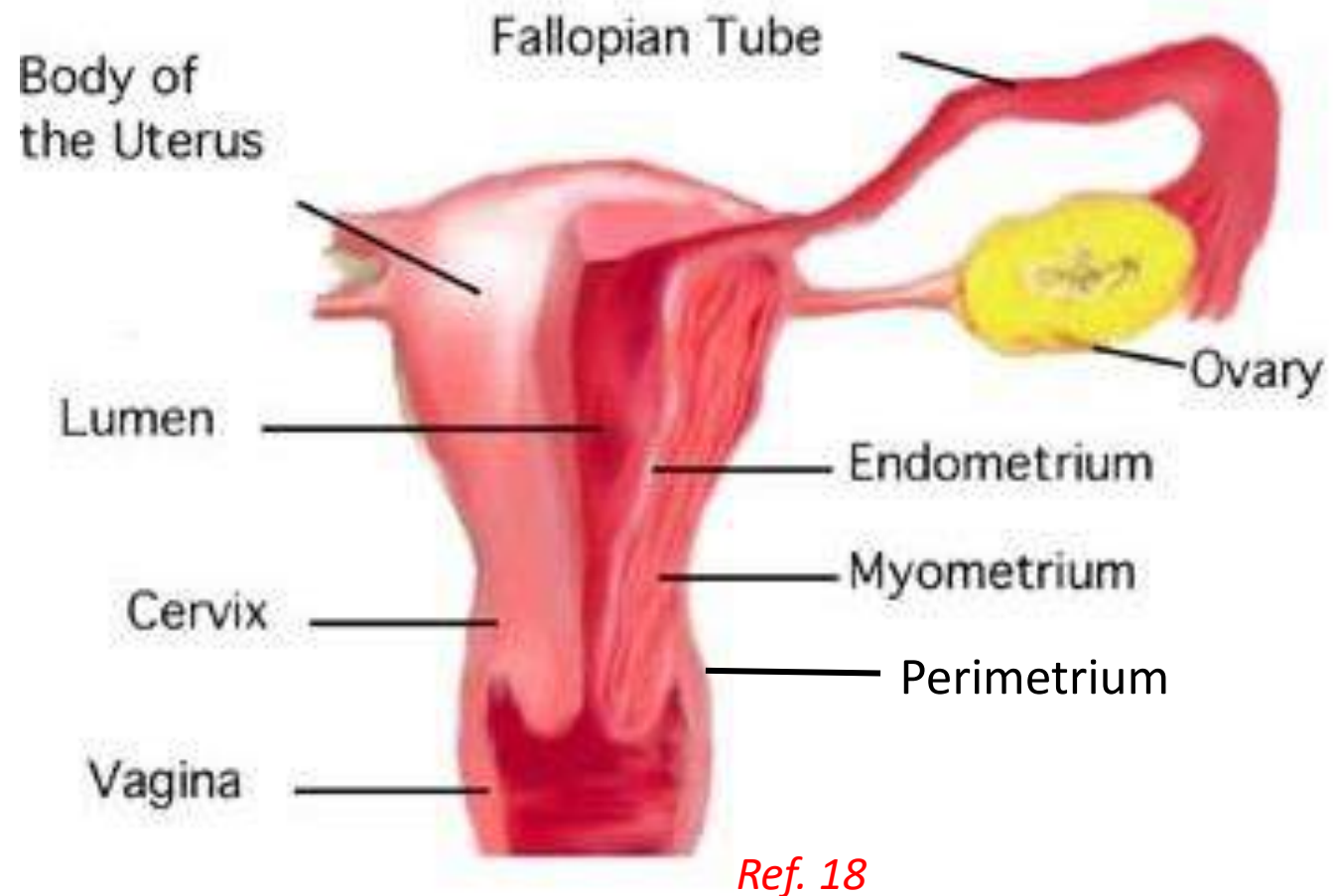
Ovary Layers – Follicles/Oocyte



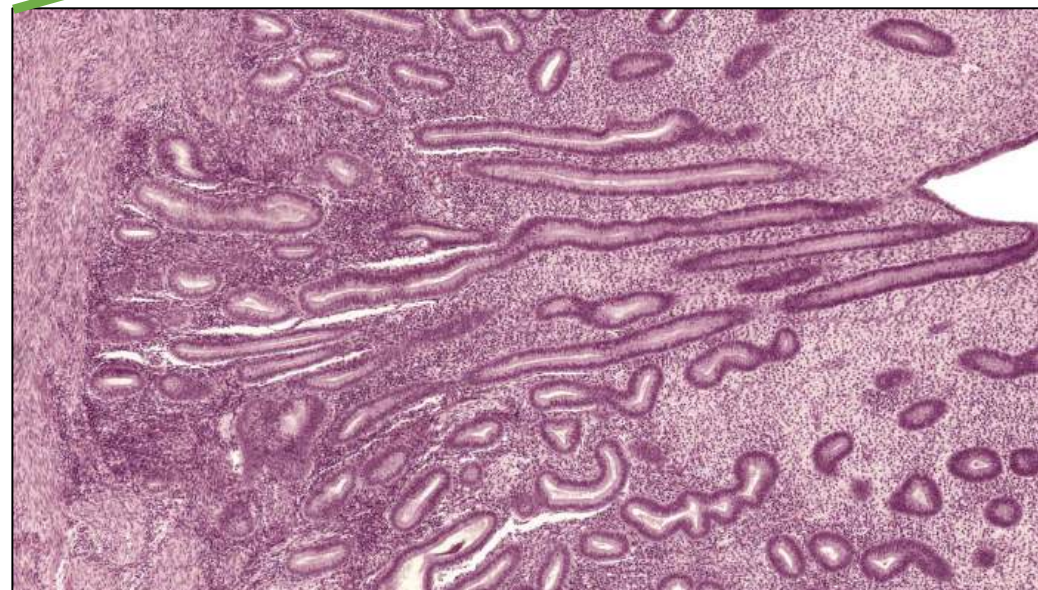
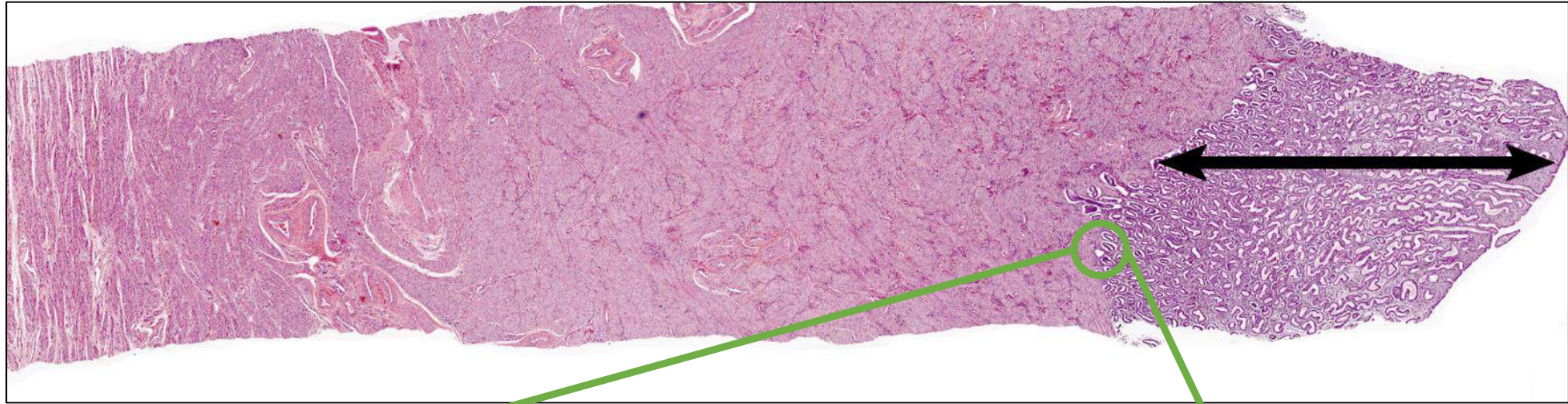
Ref. 17

Layers of the Uterus

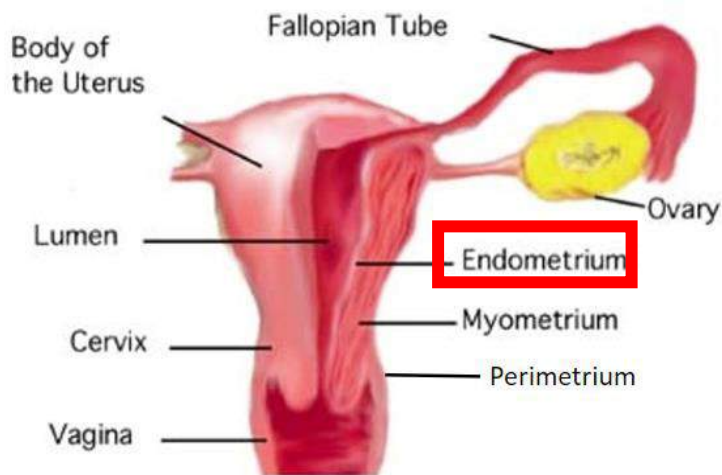
- Endometrium
- Myometrium
- Perimetrium



Uterus Layers – Endometrium

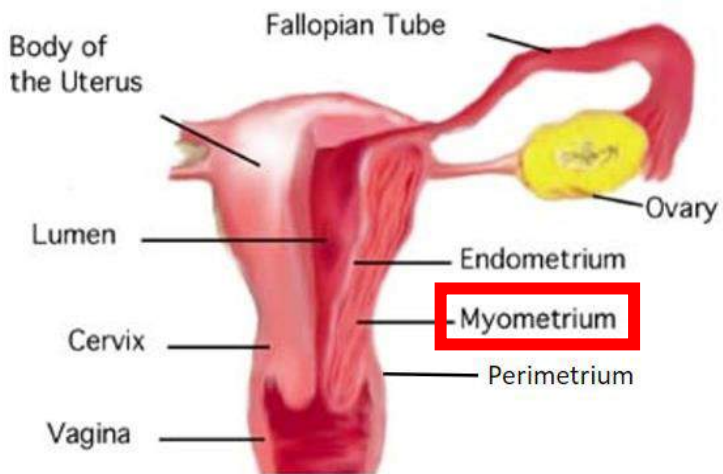
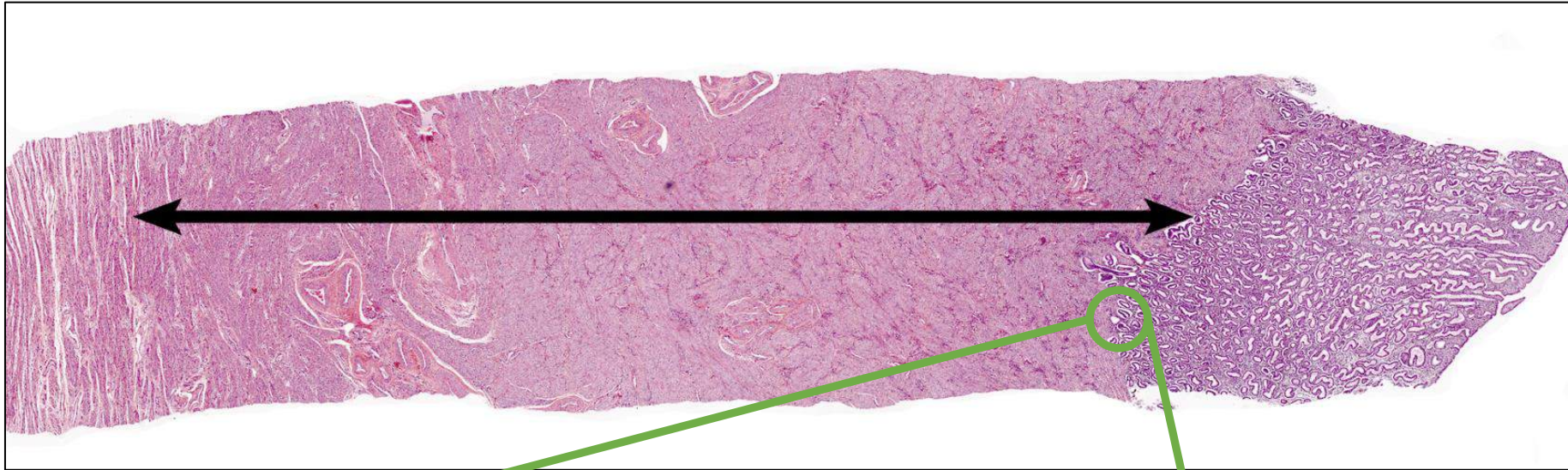


Innermost layer

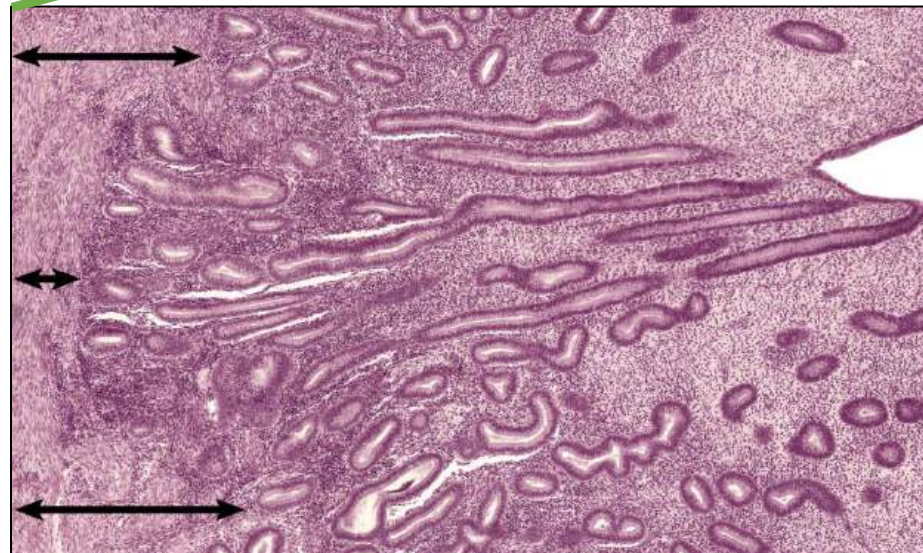


Ref. 18

Uterus Layers – Myometrium

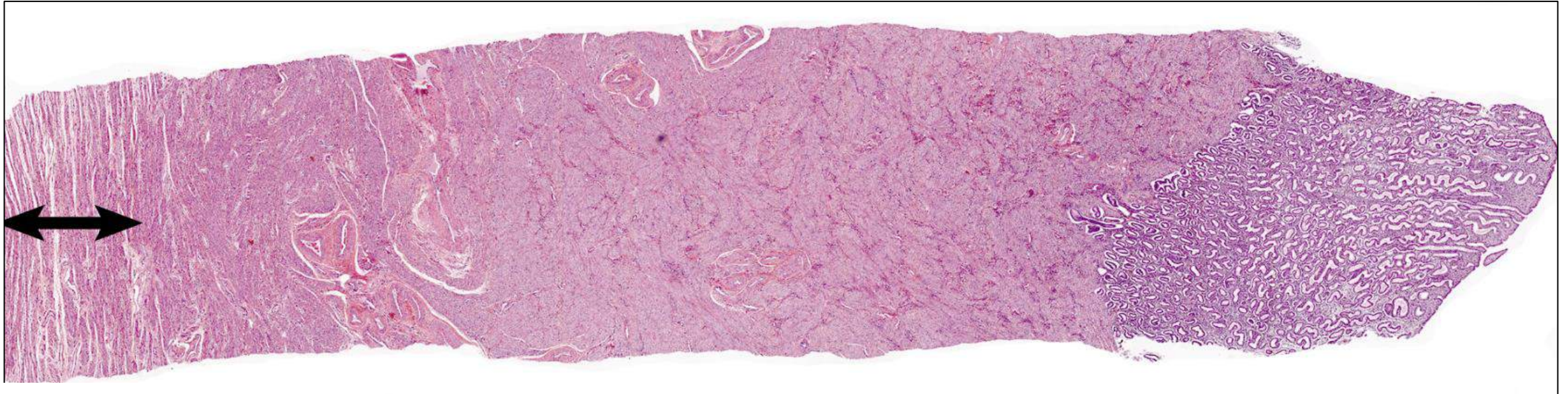


Ref. 18

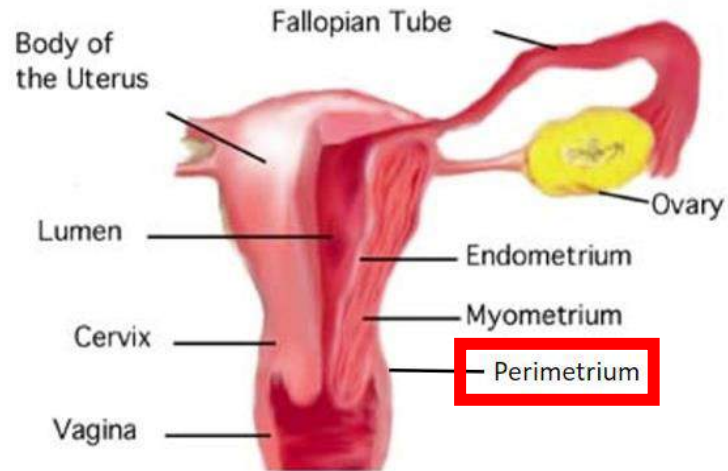


Middle layer

Uterus Layers – Perimetrium



Outermost layer

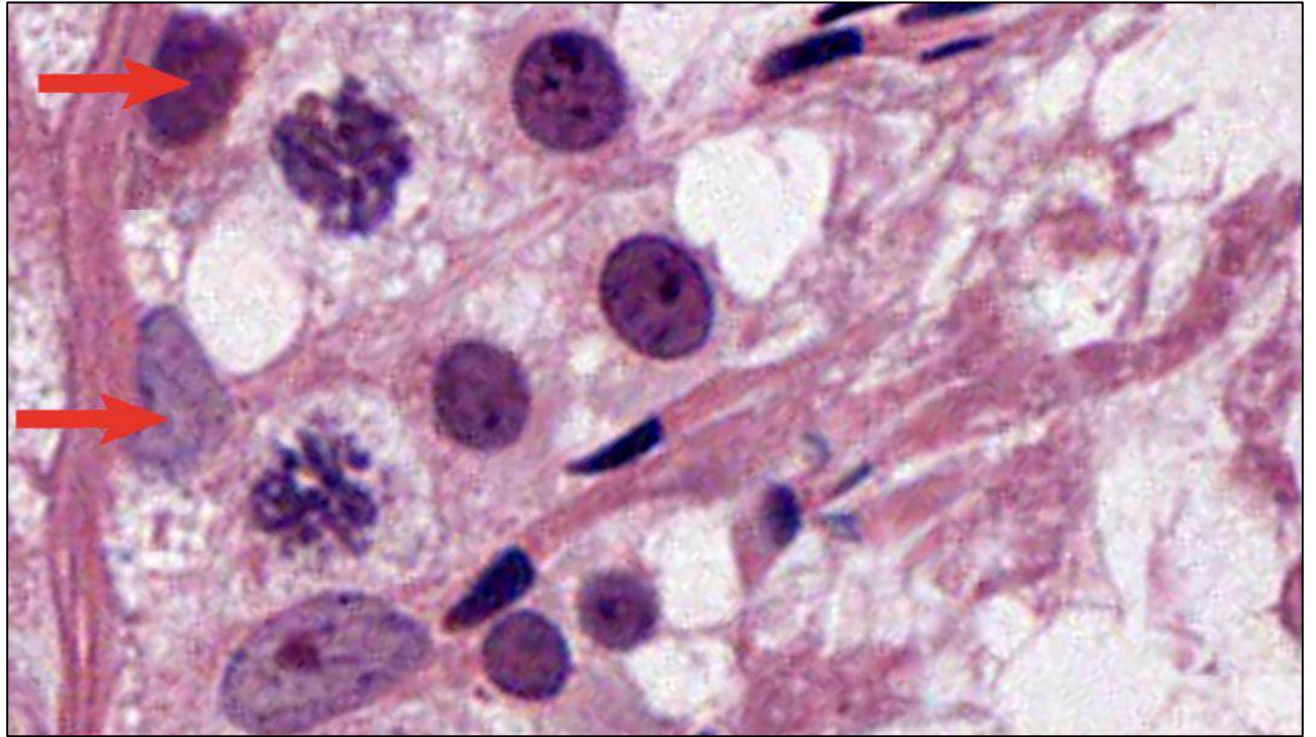
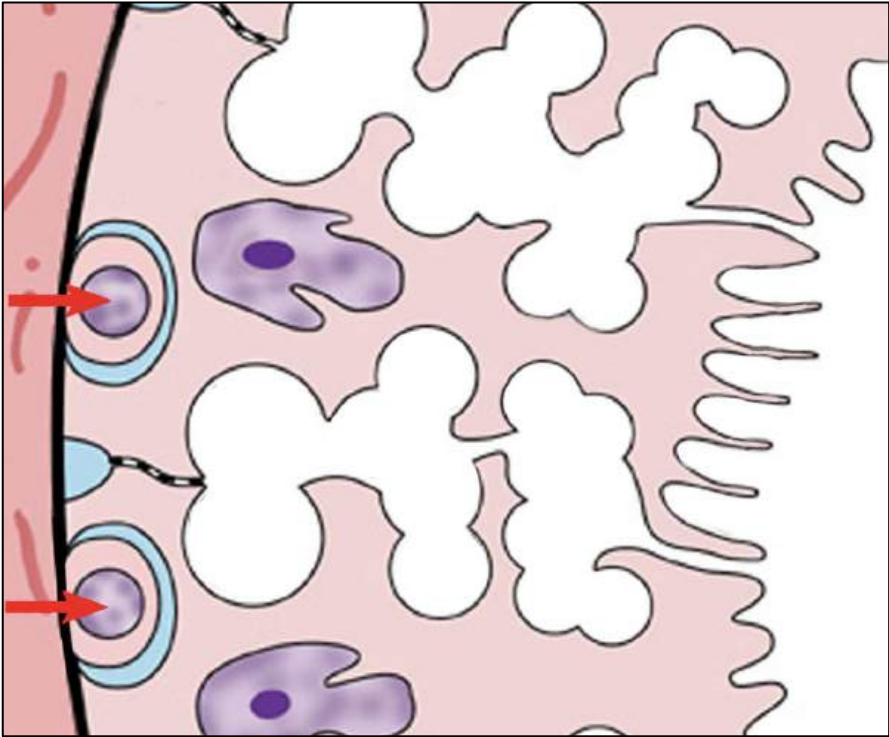


Ref. 18

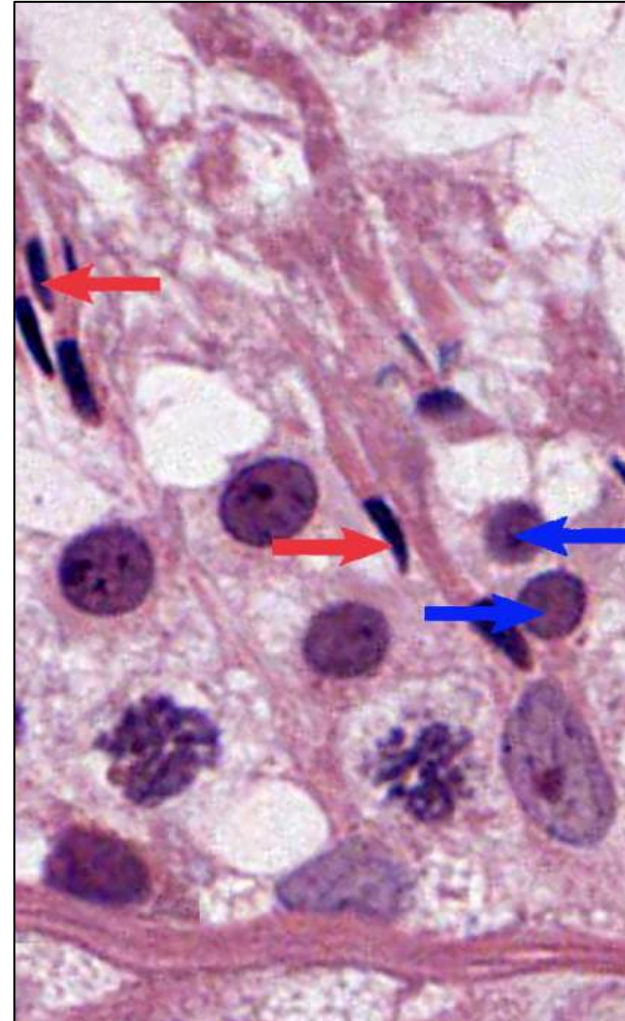
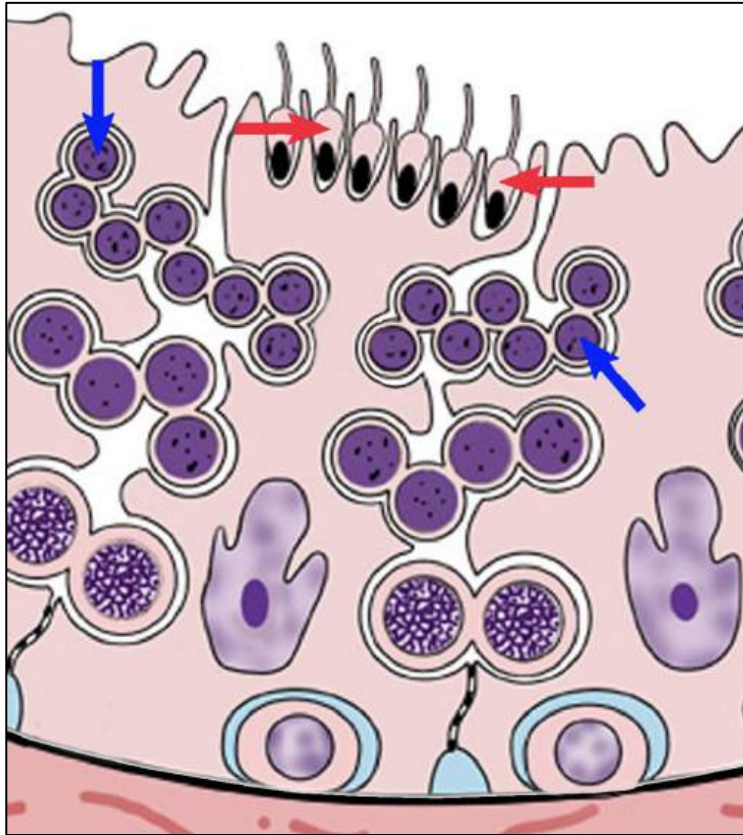
Testis Cell Types

- Seminiferous tubules
 - Spermatogonia
 - Spermatids/Spermatozoa
 - Sertoli cells
- Leydig cells

Testis Structures – Seminiferous Tubules (Spermatogonia)

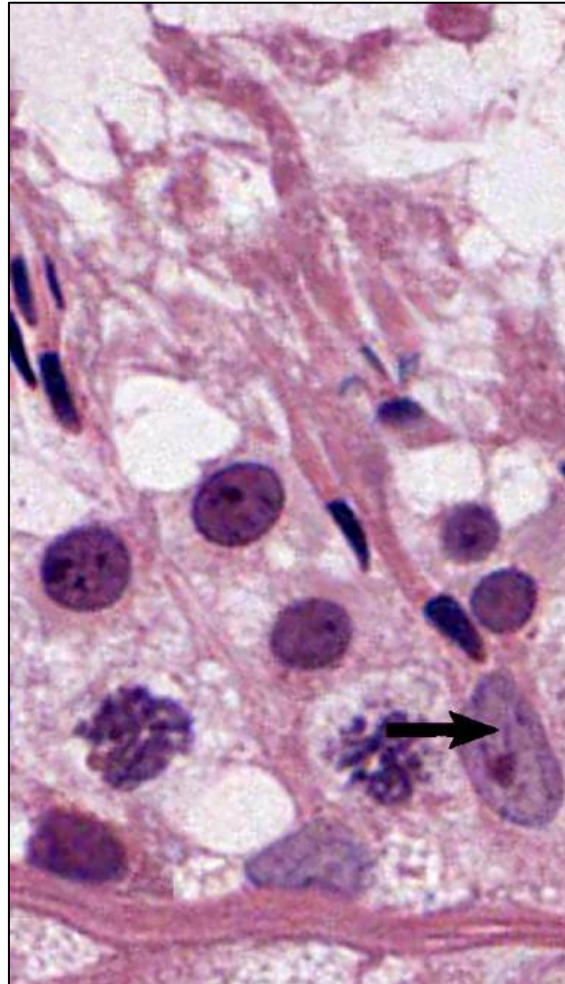
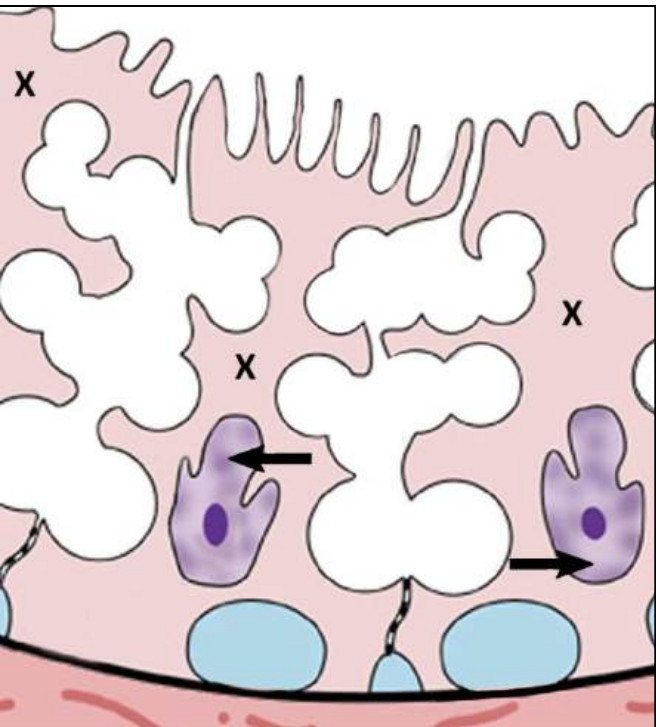


Testis Structures – Seminiferous Tubules (Spermatids/Spermatozoa)

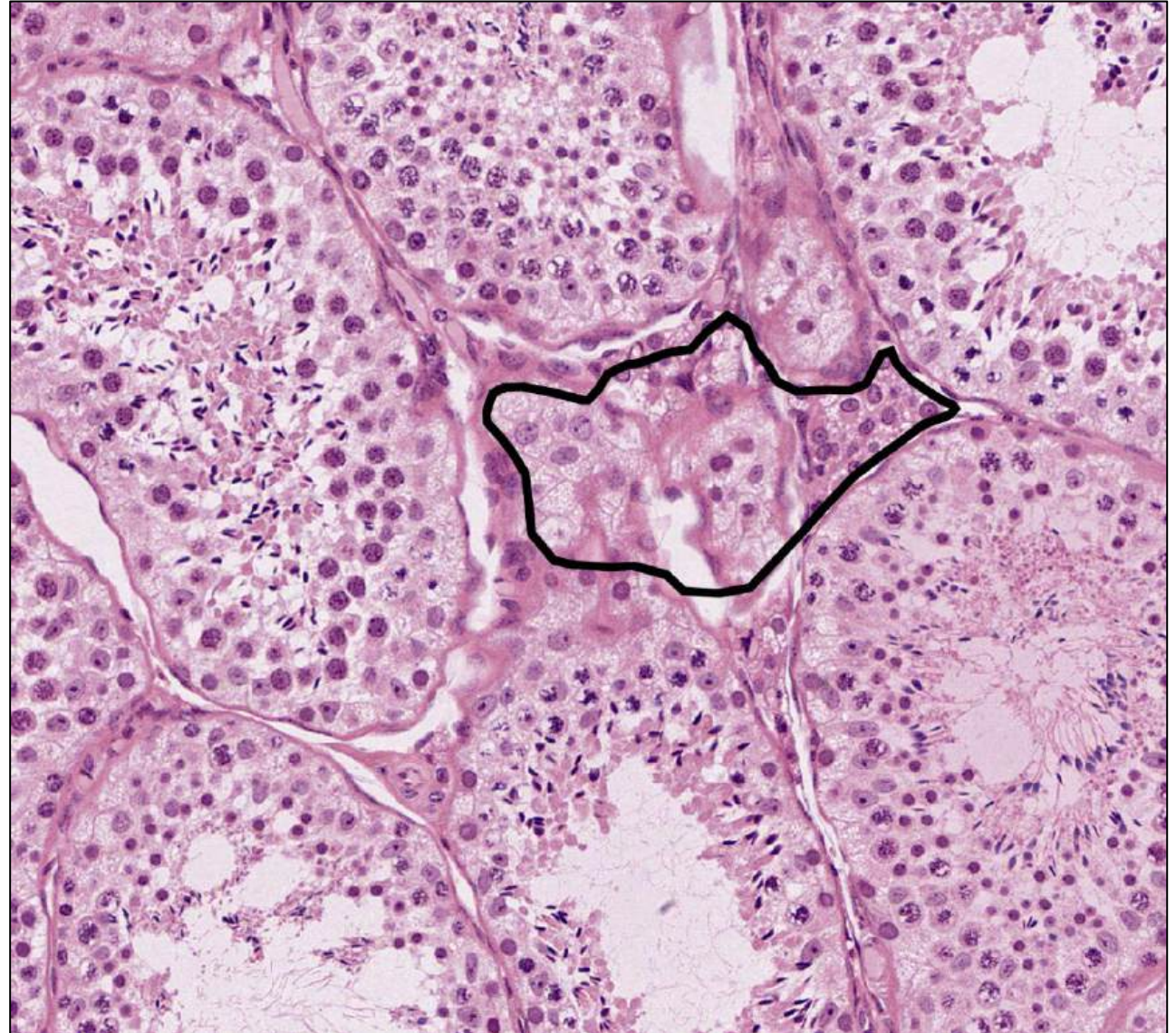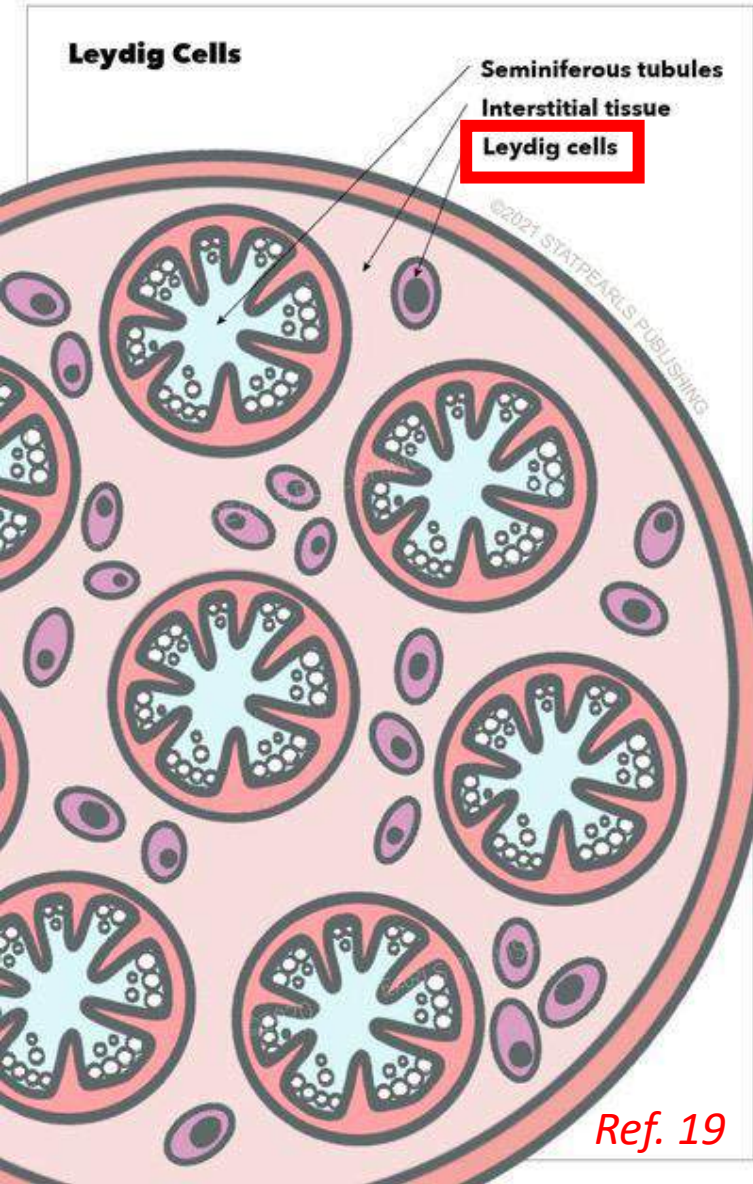


Blue arrows – immature spermatids
Red arrows – more mature spermatids

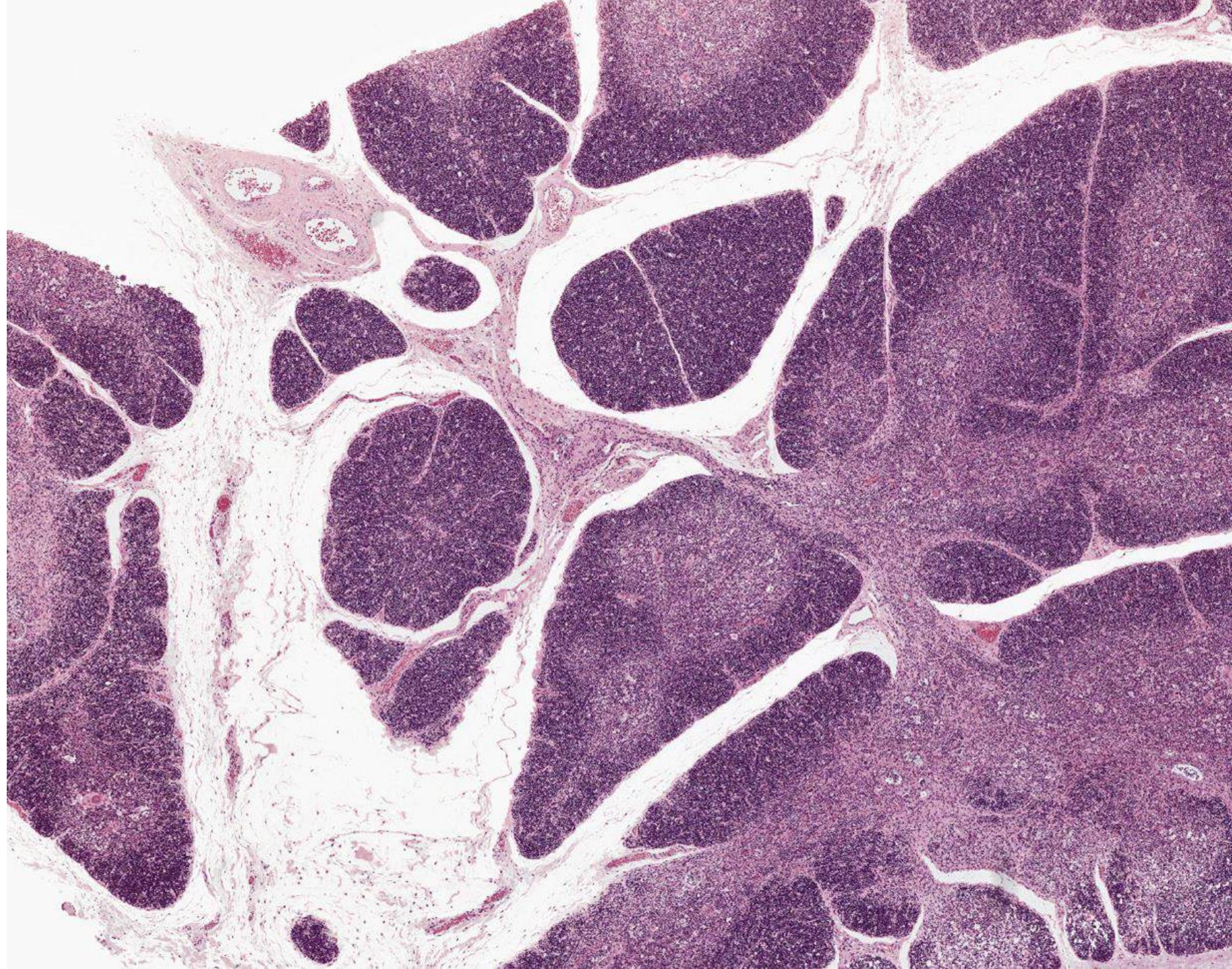
Testis Structures – Seminiferous Tubules (Sertoli Cells = X)



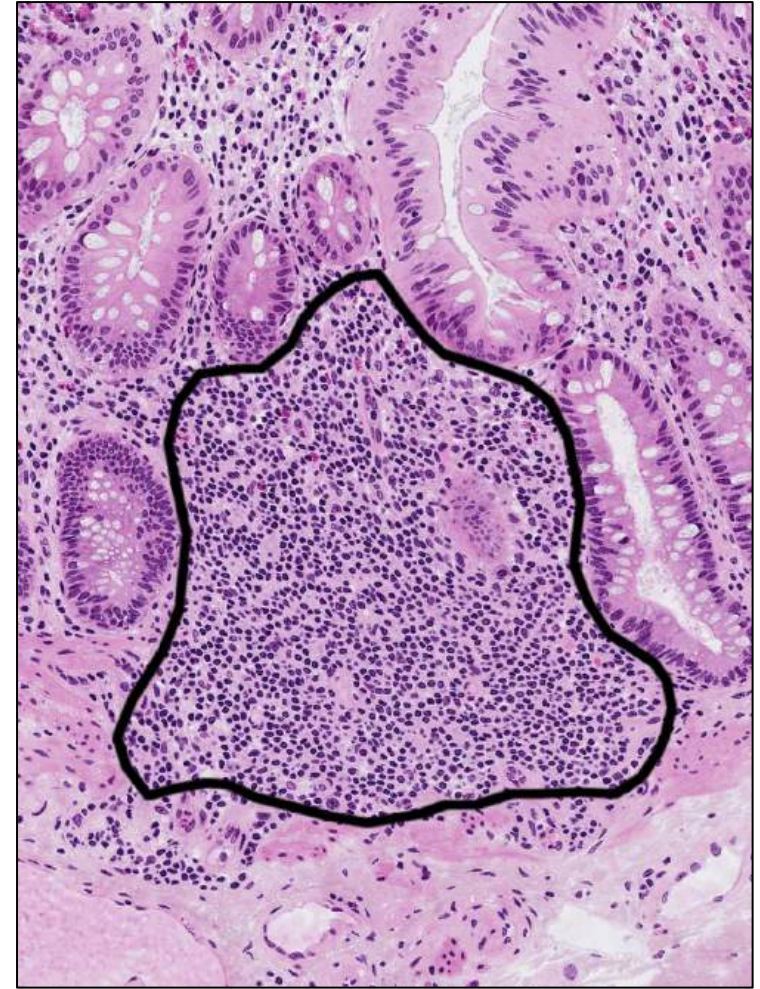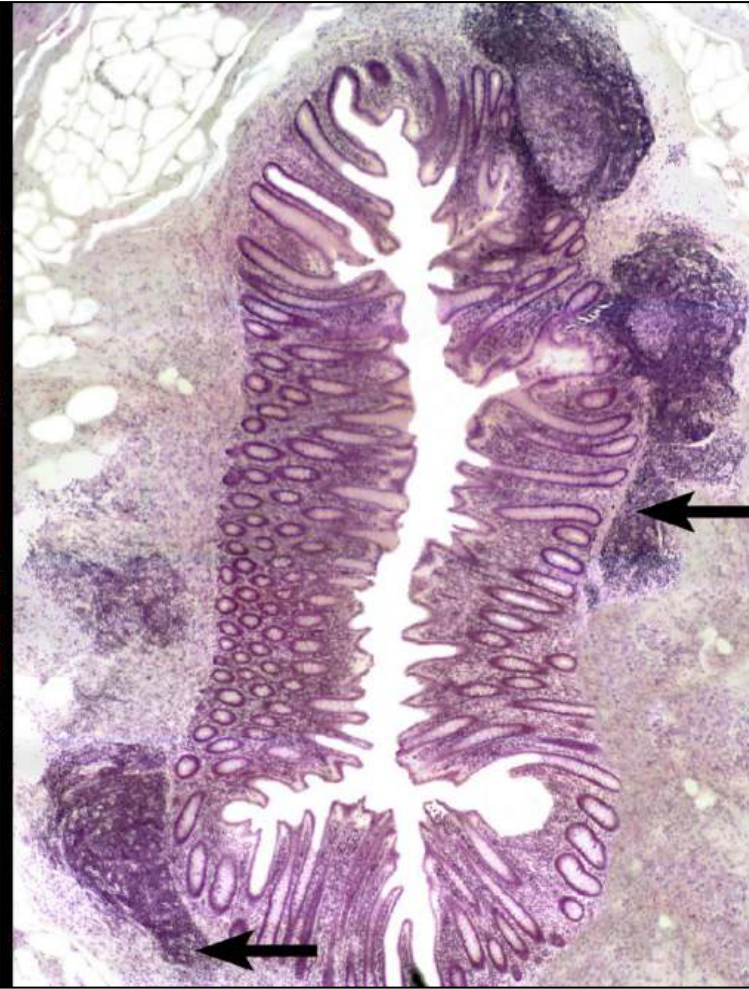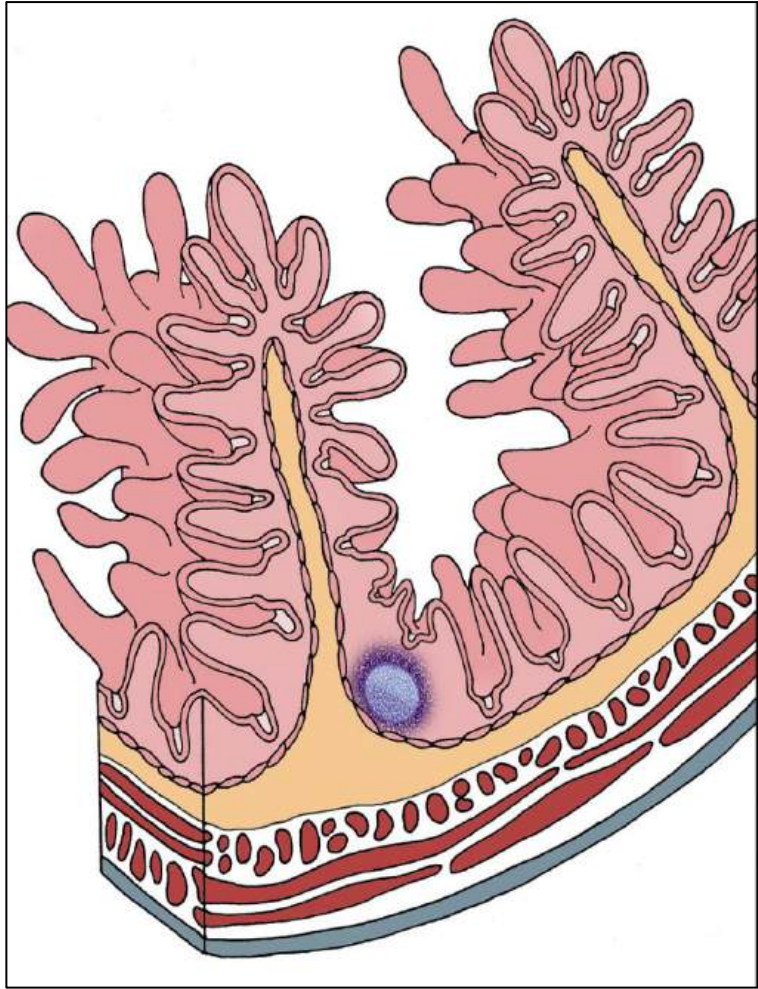
Testis Structures – Leydig Cells



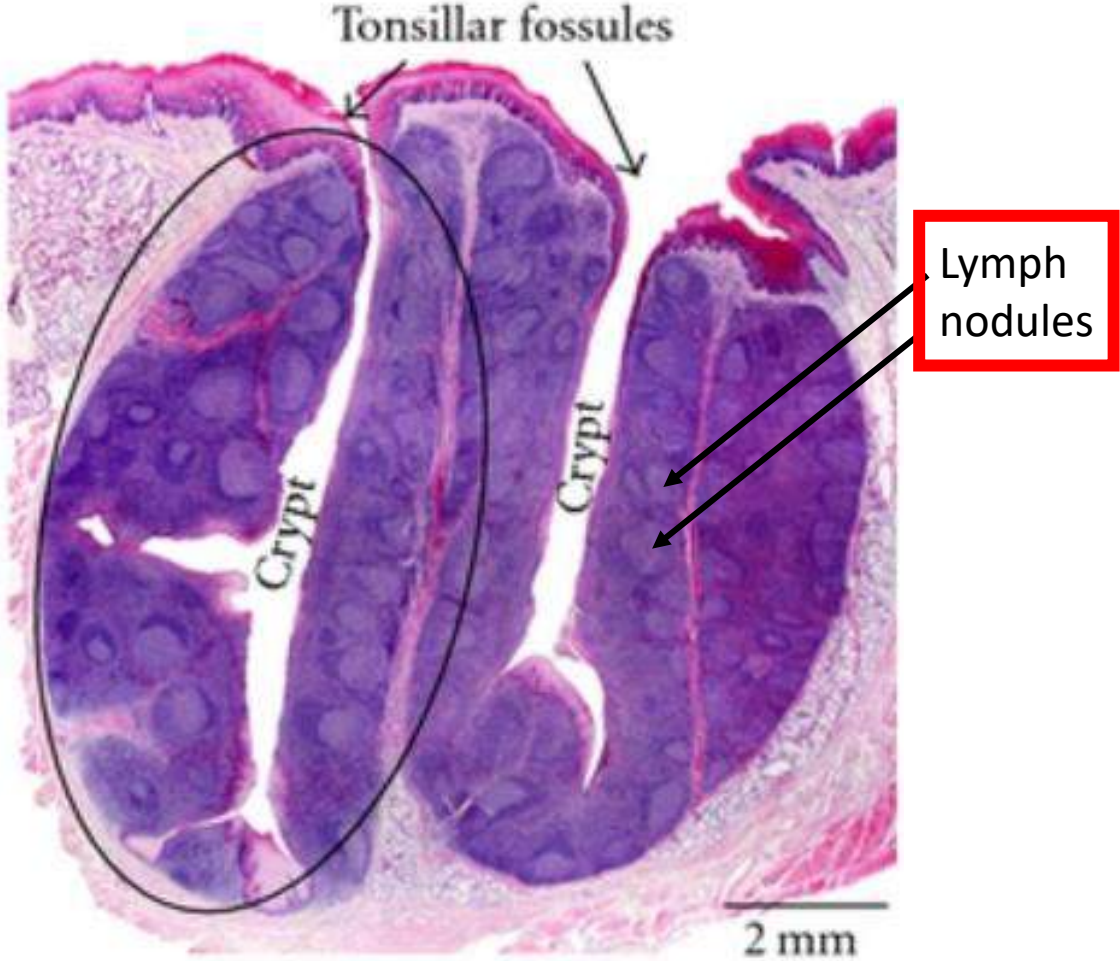
Lymphoid Organs



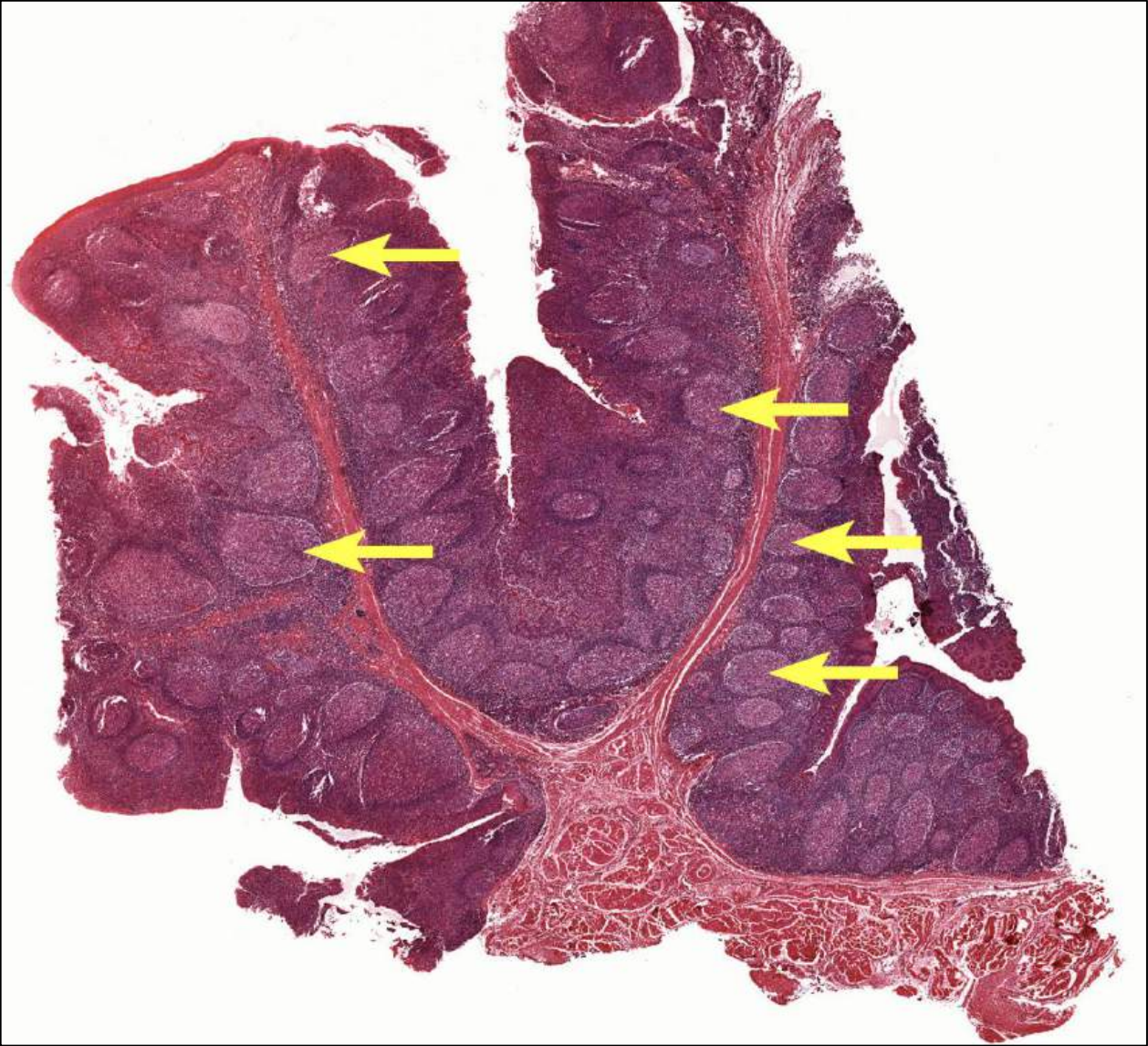
Diffuse Lymphoid Tissue



Lymph nodules - Tonsils

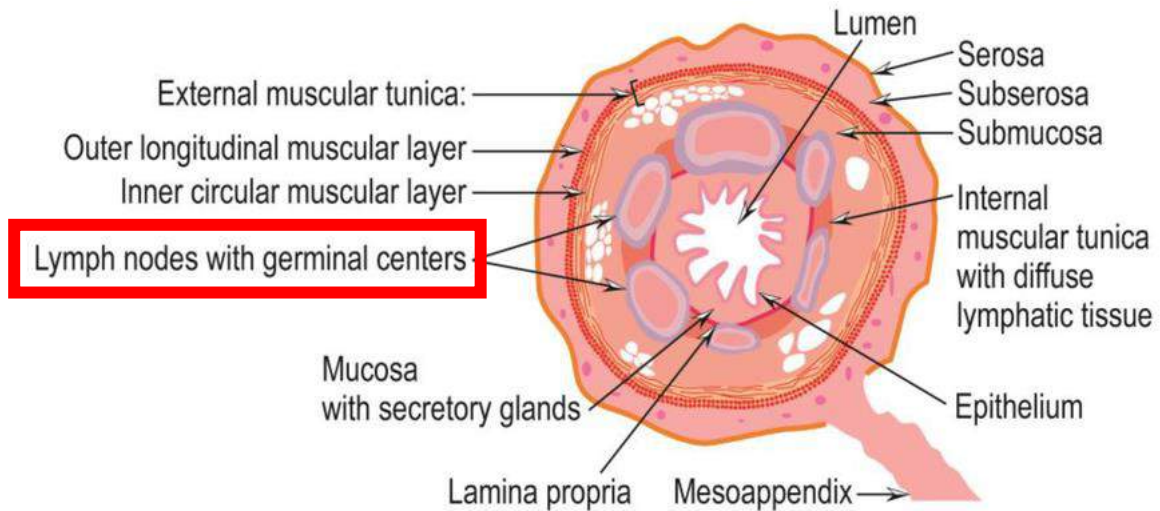


Ref. 20

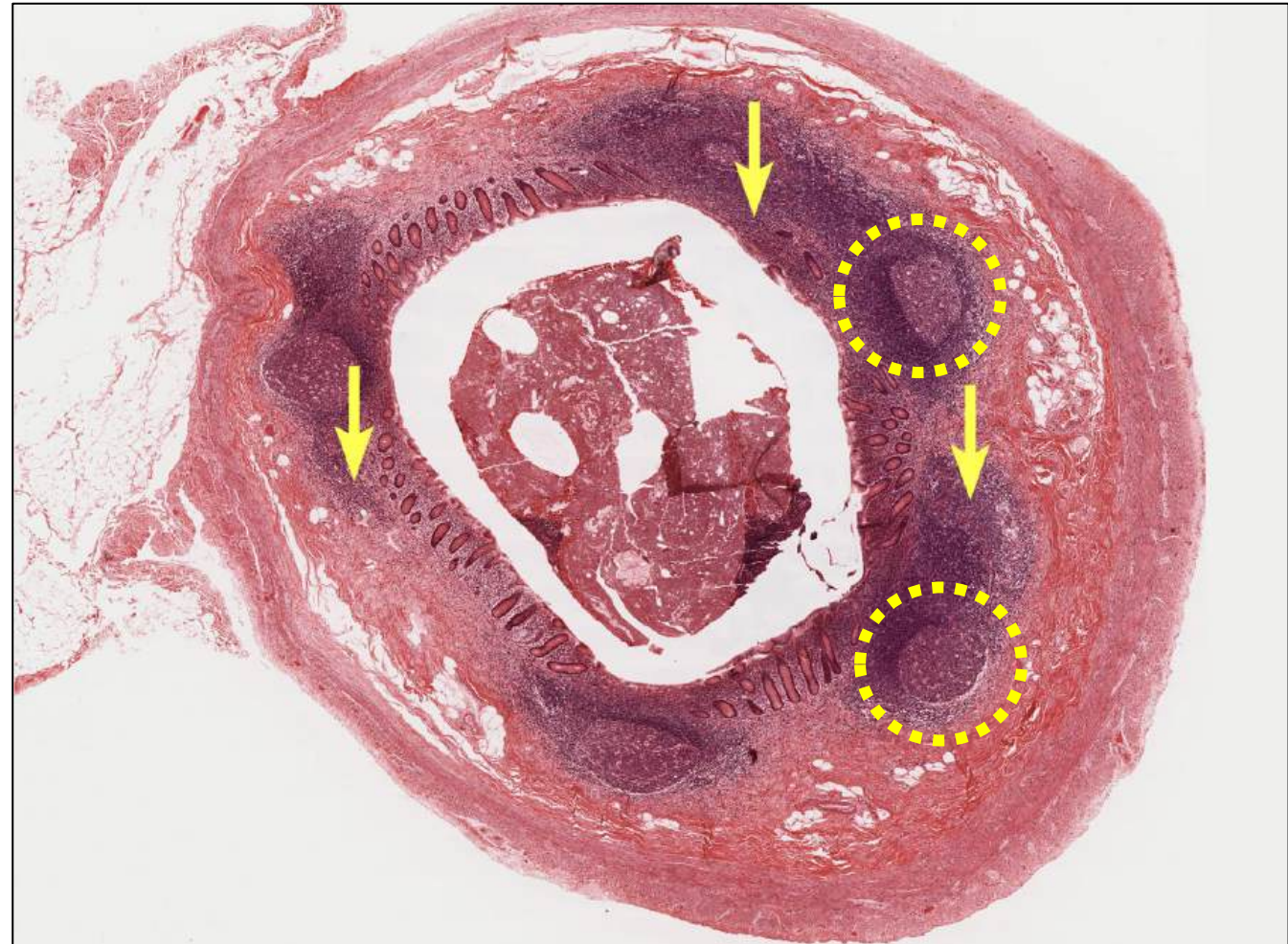


Lymph nodules – Appendix

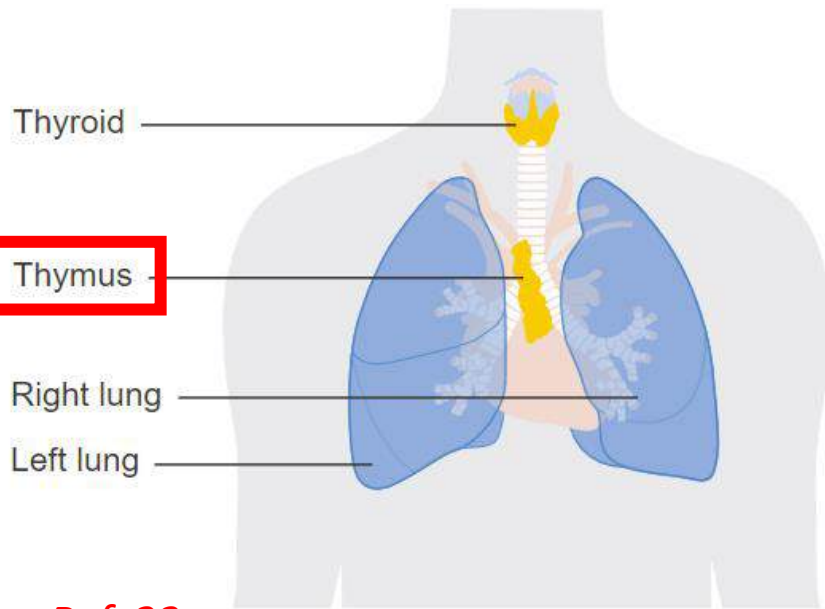
Yellow arrows show diffuse lymphoid tissue



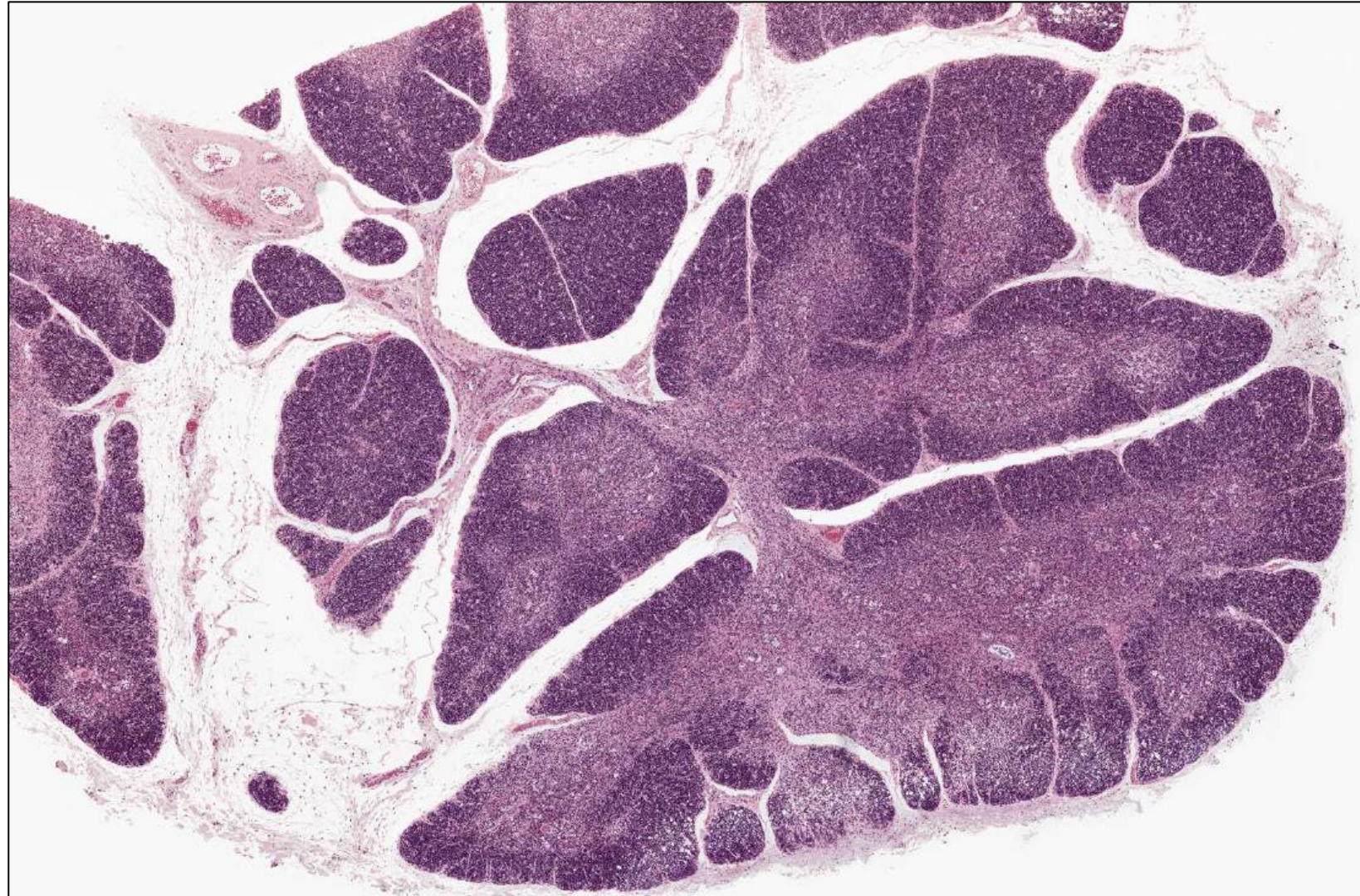
Ref. 21



Lymphatic Organ – Thymus Gland



Ref. 22



Lymphoid Follicles – Secondary Lymphoid Follicles in Peyer's Patches (Small Intestine)

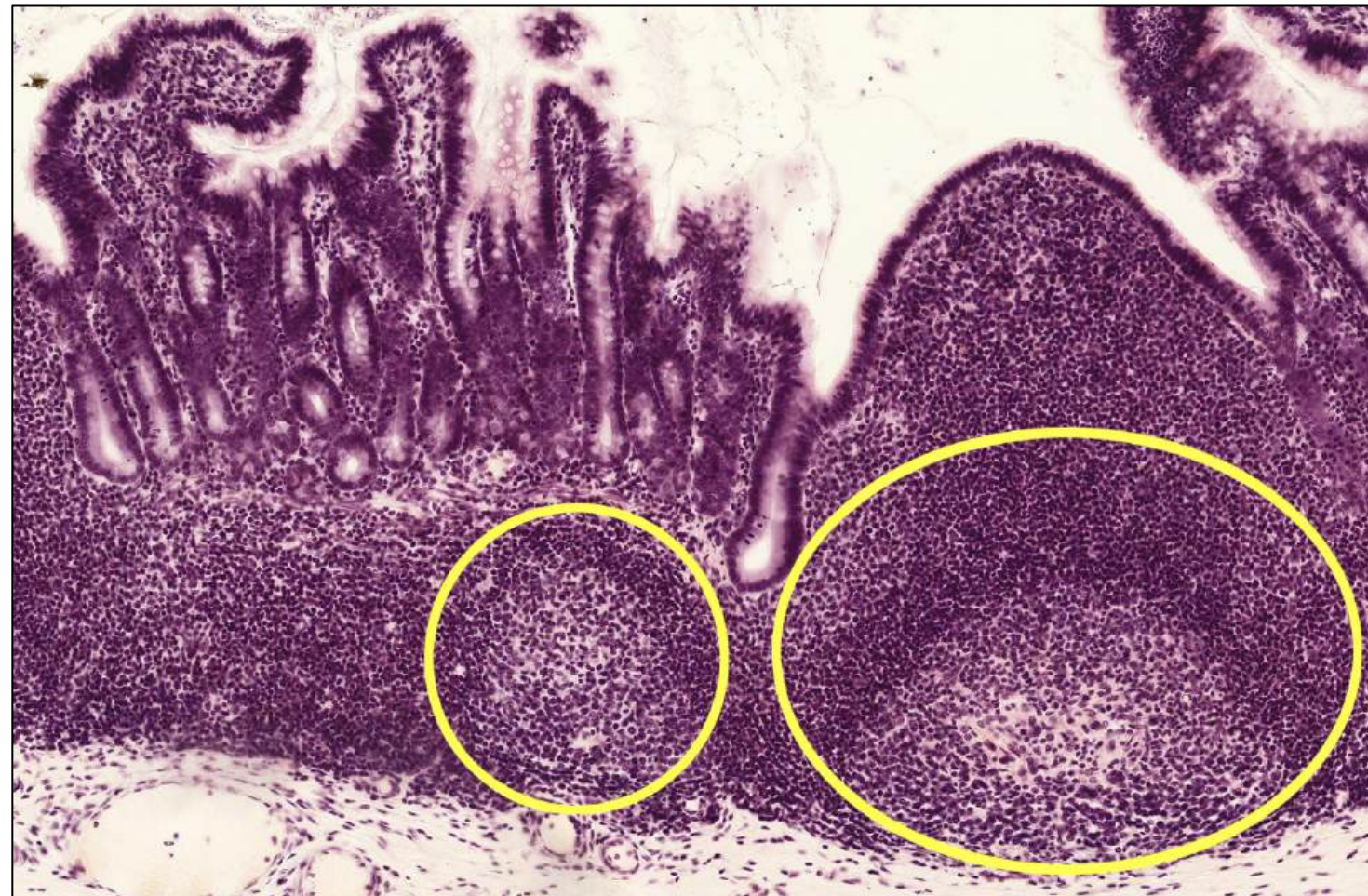
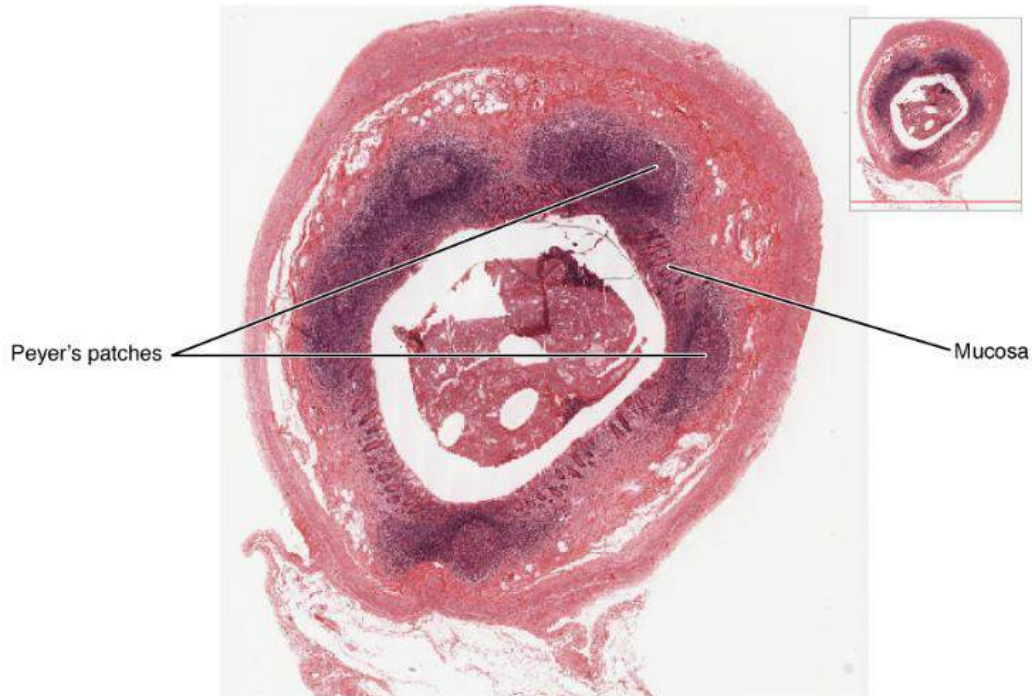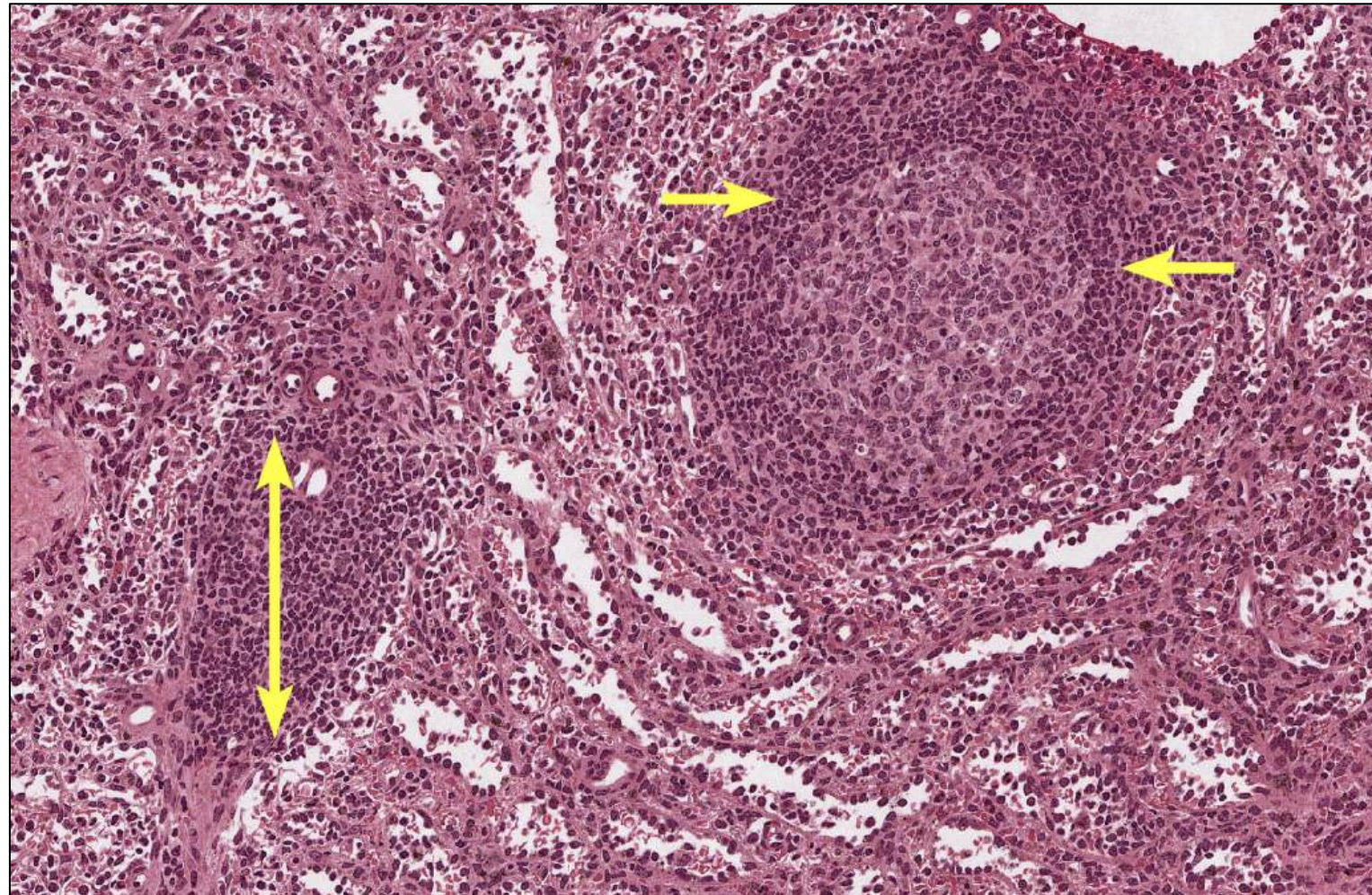
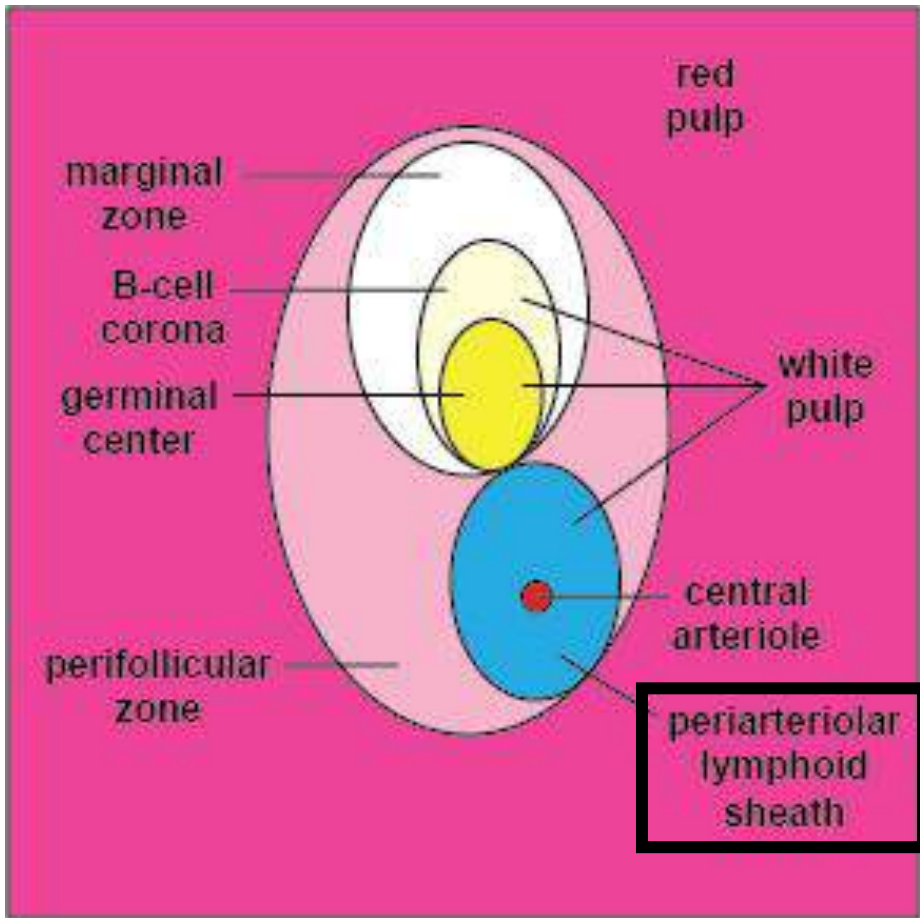


Figure 21.11 Mucosa-associated Lymphoid Tissue (MALT) Nodule LM \times 40.
(Micrograph provided by the Regents of the University of Michigan Medical School \copyright 2012)

Lymphoid Follicles - Periarterial Lymphoid Sheath (Spleen)



References

All slides contain images obtained from Digital Histology. Unless otherwise cited, images were obtained from Digital Histology, Department of Anatomy and Neurobiology and the Office of Faculty Affairs, Virginia Commonwealth University School of Medicine and the ALT Lab at Virginia Commonwealth University. Project Directors: Alice S. Pakurar, Ph.D. and John W. Bigbee, Ph.D.; Design Coordinators: Kenneth Warren Foster, Ed.D. and Thomas W. Woodward, MS; Medical Illustrator: Carole W. Christman, Ph.D. Accessed online at <https://digitalhistology.org>

1. Presland RB, Jurevic RJ. Making sense of the epithelial barrier: what molecular biology and genetics tell us about the functions of oral mucosal and epidermal tissues. *J Dent Educ.* 2002;66(4):564-574. Figure accessed online at https://www.researchgate.net/figure/Structure-of-keratinizing-and-non-keratinizing-stratified-epithelial-tissues-of-skin-and_fig1_11356244
2. Robert B. Tallitsch and Ronald Guastaferrri (Art Coordinator and Illustrator). *Histology: An Identification Manual*. Chapter 13: Endocrine System. Figure 13-6. Book accessed online at <https://pressbooks.pub/rbtallitsch/>
3. Robert B. Tallitsch and Ronald Guastaferrri (Art Coordinator and Illustrator). *Histology: An Identification Manual*. Chapter 3: Connective Tissue Proper. Figure 3-1. Book accessed online at <https://pressbooks.pub/rbtallitsch/>
4. OpenStax College, Rice University. *Anatomy & Physiology I*. Chapter 4: Connective Tissue Supports and Protects. Figure 4. Book accessed online at <https://courses.lumenlearning.com/suny-ap1/chapter/connective-tissue-supports-and-protects/>
5. OpenStax College, Rice University. *Biology*. Chapter 33.2: Animal Primary Tissues. Figure 33.17. Book accessed online at <https://openstax.org/books/biology/pages/preface>
6. Teixeira MA, Amorim MTP, Felgueiras HP. Poly(Vinyl Alcohol)-Based Nanofibrous Electrospun Scaffolds for Tissue Engineering Applications. *Polymers* (Basel). 2019 Dec 18;12(1):7. doi: 10.3390/polym12010007. PMID: 31861485; PMCID: PMC7023576. Figure accessed online at <https://www.mdpi.com/2073-4360/12/1/7>
7. *Gray's Anatomy of the Human Body* from the classic 1918 publication available online at Bartleby.com. Coloured and modified using Adobe Illustrator. Figure accessed online at https://commons.wikimedia.org/wiki/File:Transverse_Section_Of_Bone.svg
8. Ryan Jennings and Chris Premanandan, The Ohio State University College of Veterinary Medicine. *Veterinary Histology*. Chapter 4: Skeletal Muscle. Book accessed online at <https://ohiostate.pressbooks.pub/vethisto/chapter/4-skeletal-muscle/>

References

All slides contain images obtained from Digital Histology. Unless otherwise cited, images were obtained from Digital Histology, Department of Anatomy and Neurobiology and the Office of Faculty Affairs, Virginia Commonwealth University School of Medicine and the ALT Lab at Virginia Commonwealth University. Project Directors: Alice S. Pakurar, Ph.D. and John W. Bigbee, Ph.D.; Design Coordinators: Kenneth Warren Foster, Ed.D. and Thomas W. Woodward, MS; Medical Illustrator: Carole W. Christman, Ph.D. Accessed online at <https://digitalhistology.org>

9. **Rose M. Spielman, Kathryn Dumper, William Jenkins, Arlene Lacombe, Marilyn Lovett, and Marion Perlmutter. Introduction to Psychology (A critical approach).** Chapter 3: Biophysiology. Figure 3.4. Book accessed online at <https://pressbooks.cuny.edu/jsevitt/chapter/cells-of-the-nervous-system/>
10. **Robert B. Tallitsch and Ronald Guastaferrri (Art Coordinator and Illustrator). Histology: An Identification Manual.** Chapter 7: Nervous Tissue. Figure 7-13. Book accessed online at <https://pressbooks.pub/rbtallitsch/>
11. **OpenStax College, Rice University. Biology.** Chapter 35.1: Neurons and Glial Cells. Figure 35.7. Book accessed online at <https://openstax.org/books/biology/pages/35-1-neurons-and-glia-cells?query=oligodendrocyte&target=%7B%22index%22%3A0%2C%22type%22%3A%22search%22%7D#fs-idm2931648>
12. **OpenStax College, Rice University. Anatomy and Physiology.** Chapter 13.4: The Peripheral Nervous System. Figure 13.21. Book accessed online at <https://openstax.org/books/anatomy-and-physiology/pages/13-4-the-peripheral-nervous-system?query=epineurium&target=%7B%22index%22%3A0%2C%22type%22%3A%22search%22%7D#fs-id1287072>
13. **John Byrne, Cancer Research UK in London.** Wikimedia Commons. Image accessed online at [https://commons.wikimedia.org/wiki/File:Diagram showing the position of the salivary glands CRUK 451.svg](https://commons.wikimedia.org/wiki/File:Diagram_showing_the_position_of_the_salivary_glands_CRUK_451.svg)
14. **Frank Boumphrey, M.D., Wikimedia Commons.** Image accessed online at https://commons.wikimedia.org/wiki/File:Smallintestine_layers2.png
15. **Ajallouean F, Lemon G, Hilborn J, Chronakis IS, Fossum M. Bladder biomechanics and the use of scaffolds for regenerative medicine in the urinary bladder.** Nat Rev Urol. 2018;15(3):155-174. doi:10.1038/nrurol.2018.5. Image accessed online at <https://www.nature.com/articles/nrurol.2018.5>
16. **Kamrani P, Marston G, Arbor TC, et al. Anatomy, Connective Tissue.** StatPearls Publishing. Available from <https://www.ncbi.nlm.nih.gov/books/NBK538534/figure/article-36687.image.f1/>

References

All slides contain images obtained from Digital Histology. Unless otherwise cited, images were obtained from Digital Histology, Department of Anatomy and Neurobiology and the Office of Faculty Affairs, Virginia Commonwealth University School of Medicine and the ALT Lab at Virginia Commonwealth University. Project Directors: Alice S. Pakurar, Ph.D. and John W. Bigbee, Ph.D.; Design Coordinators: Kenneth Warren Foster, Ed.D. and Thomas W. Woodward, MS; Medical Illustrator: Carole W. Christman, Ph.D. Accessed online at <https://digitalhistology.org>

17. Desai, Nina & Ludgin, Jennifer & Sharma, Rakesh & Anirudh, Raj & Agarwal, Ashok. (2013). Female and Male Gametogenesis. 10.1007/978-1-4614-6837-0_3. Accessed online at https://www.researchgate.net/publication/259657103_Female_and_Male_Gametogenesis
18. Teixeira, J., Rueda, B.R., and Pru, J.K., Uterine Stem cells (September 30, 2008), StemBook, ed. The Stem Cell Research Community, StemBook, doi/10.3824/stembook.1.16.1. Accessed online at https://commons.wikimedia.org/wiki/File:Uterine_anatomy.jpg
19. Aladamat N, Tadi P. Histology, Leydig Cells. StatPearls [Internet]. Treasure Island (FL): StatPearls Publishing. Figure, Leydig cells, seminiferous tubules, interstitial tissue. Available from <https://www.ncbi.nlm.nih.gov/books/NBK556007/figure/article-24239.image.f1/>
20. Casteleyn C, Breugelmans S, Simoens P, Van den Broeck W. The tonsils revisited: review of the anatomical localization and histological characteristics of the tonsils of domestic and laboratory animals. Clin Dev Immunol. 2011;2011:472460. doi: 10.1155/2011/472460. Epub 2011 Aug 21. PMID: 21869895; PMCID: PMC3159307. Accessed from <https://www.ncbi.nlm.nih.gov/pmc/articles/PMC3159307/>
21. Constantin M, Petrescu L, Mătanie C, Vrancianu CO, Niculescu AG, Andronic O, Bolocan A. The Vermiform Appendix and Its Pathologies. Cancers (Basel). 2023 Jul 29;15(15):3872. doi: 10.3390/cancers15153872. PMID: 37568688; PMCID: PMC10417615. Accessed from <https://www.ncbi.nlm.nih.gov/pmc/articles/PMC10417615/#:~:text=Pathologies%20of%20the%20vermiform%20appendix%20can%20be%20classified%20into%20three,detail%20in%20the%20following%20sections.>
22. Cancer Research UK, Wikimedia Commons. File:Diagram showing the position of the thymus gland CRUK 362.svg. Accessed online at https://commons.wikimedia.org/wiki/File:Diagram_showing_the_position_of_the_thymus_gland_CRUK_362.svg
23. OpenStax College. (2013). Anatomy & Physiology 2E. OpenStax. Chapter 21.1: Anatomy of the Lymphatic and Immune Systems. Figure 21.11. Accessed online at <https://openstax.org/books/anatomy-and-physiology-2e/pages/21-1-anatomy-of-the-lymphatic-and-immune-systems>
24. Gary E. Kaiser, Ph.D. Professor of Microbiology, The Community College of Baltimore County, Catonsville Campus. Illustration of a Section of a Spleen Showing Red Pulp and White Pulp. Accessed online at <https://cwoer.ccbcmd.edu/science/microbiology/lecture/unit6/intro/gensteps/spleen.html>