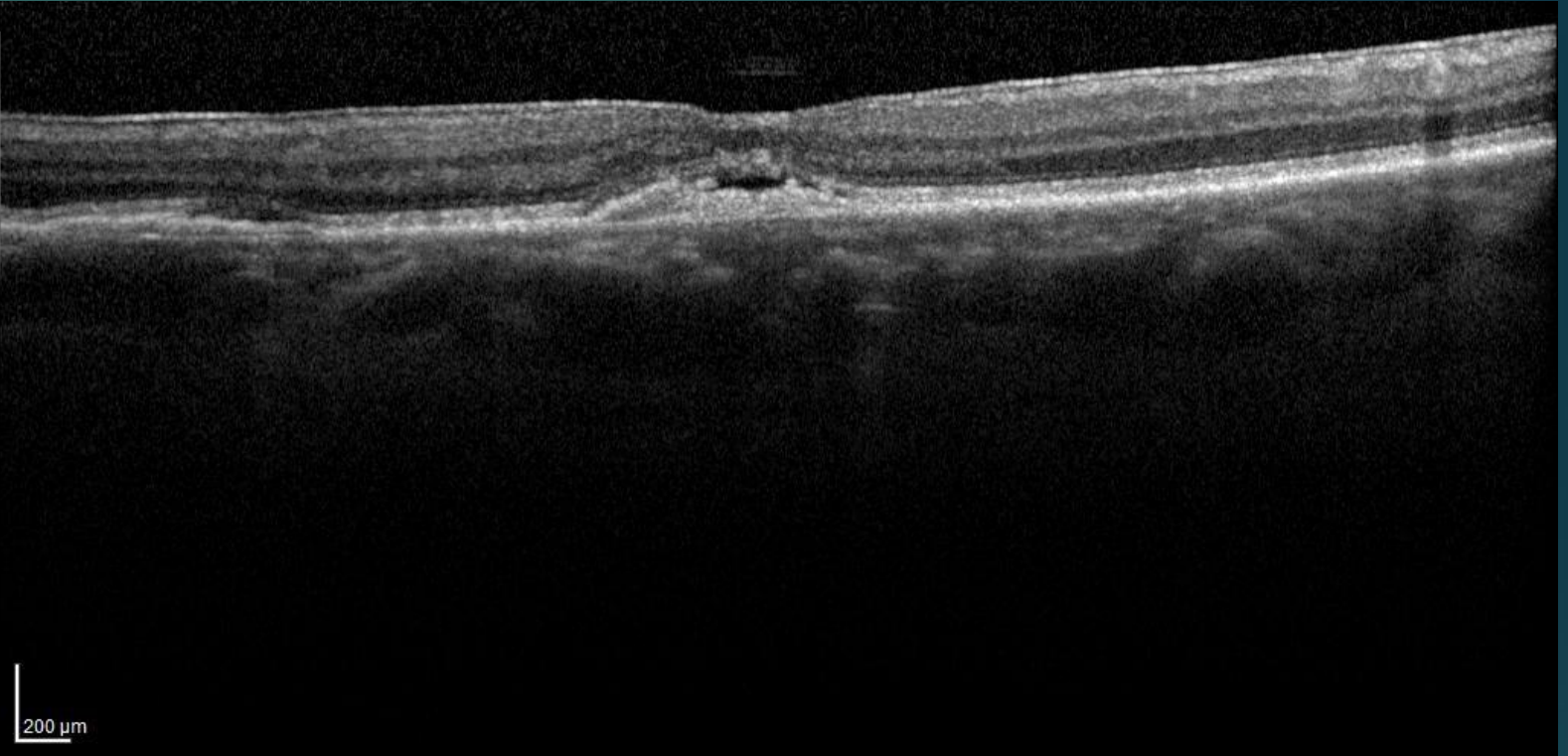
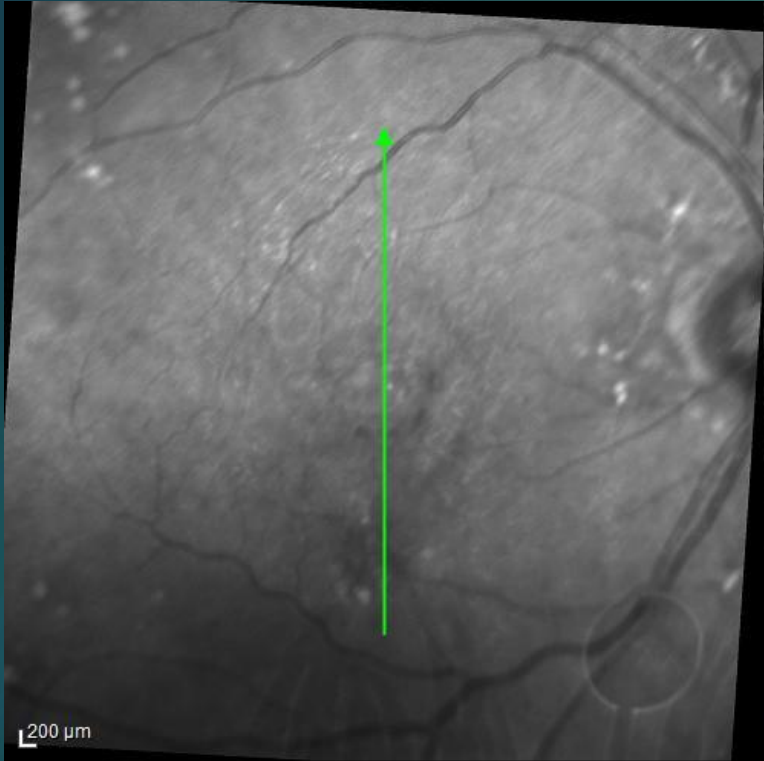




OCT Image Scans and Color Images of My Right Eye

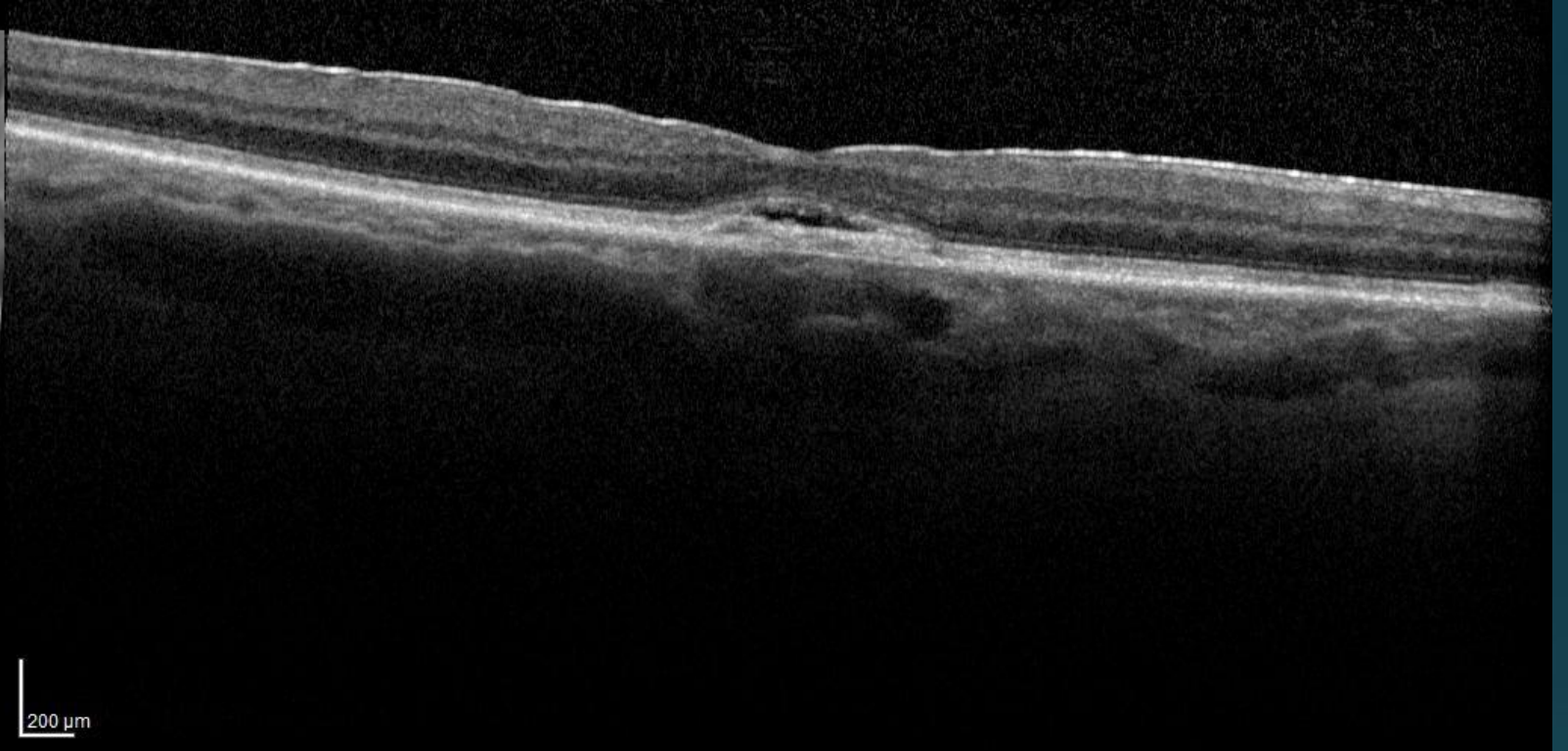
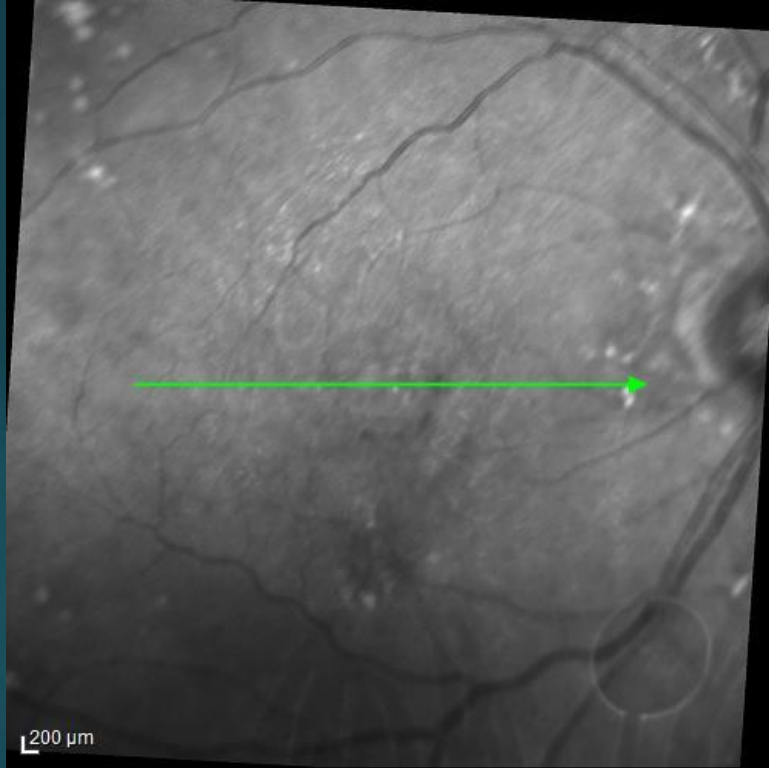
BY

ROBERT ROSENBERG, OD

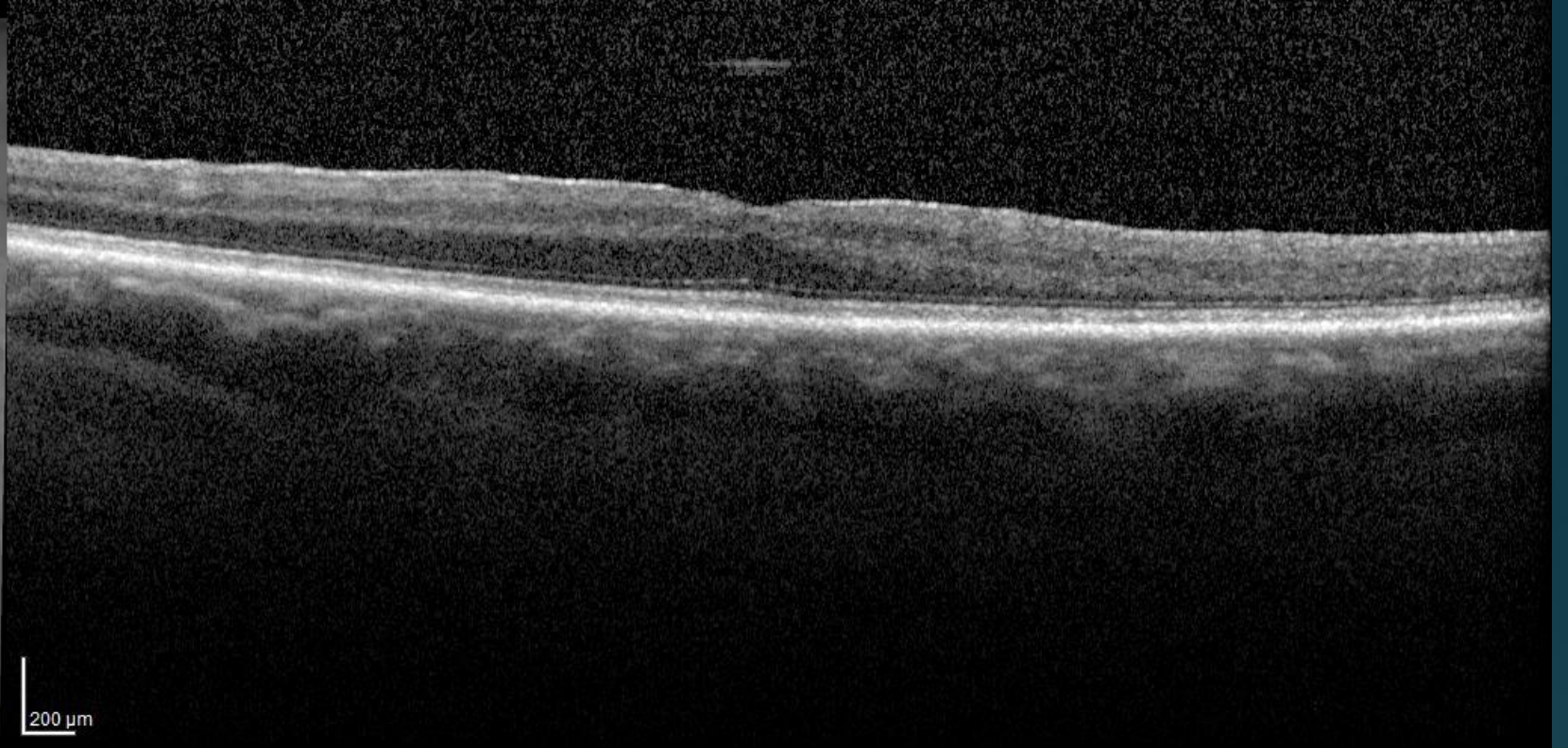
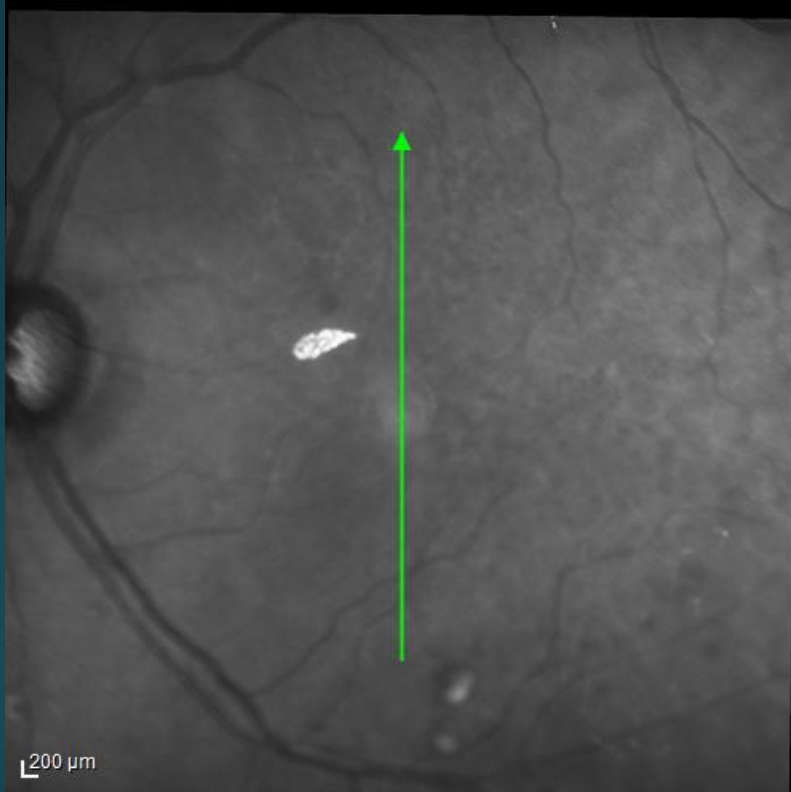

12/6/2017, OD

IR&OCT 30° [HR] ART(9) Q: 27

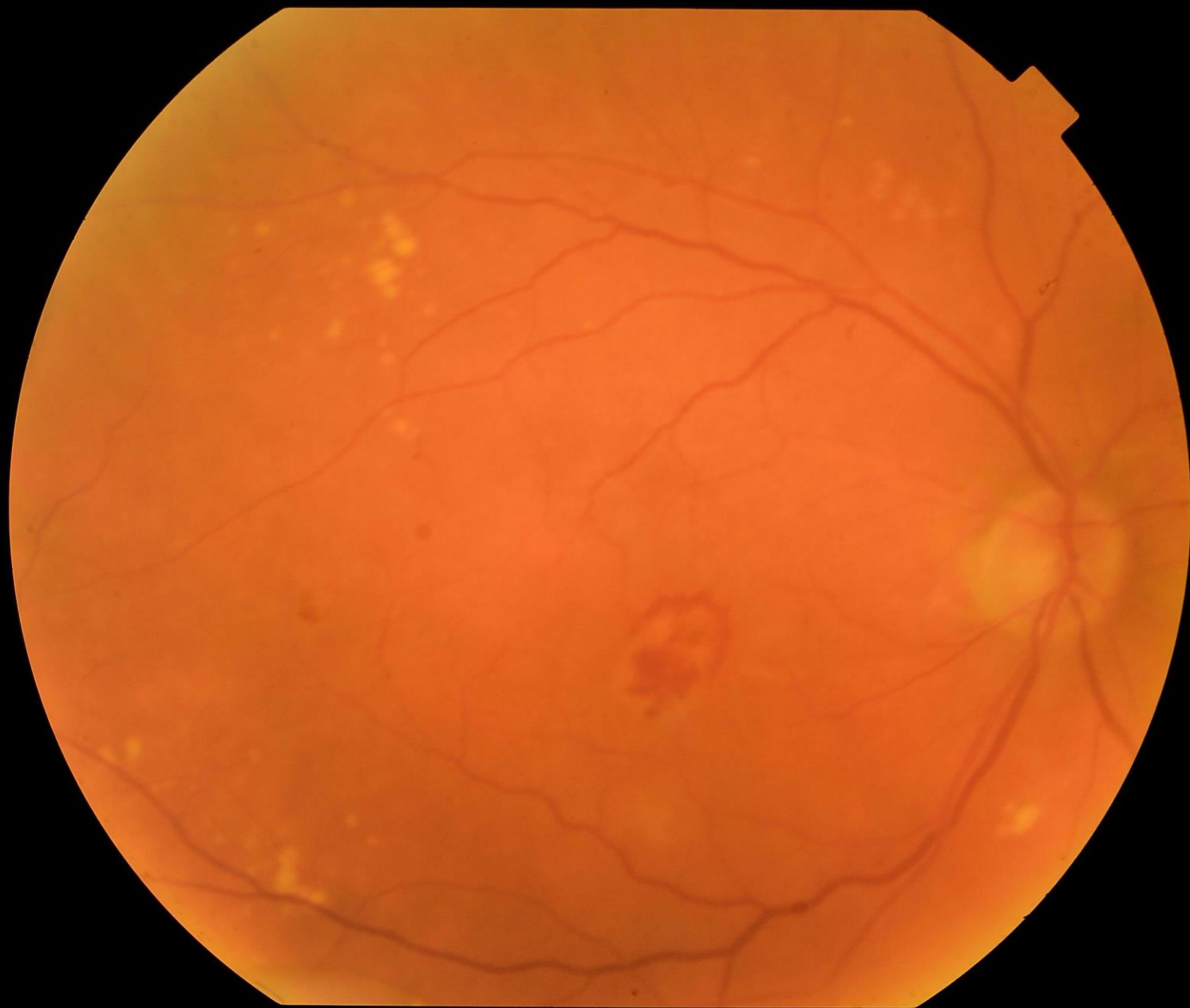


12/6/2017, OD
IR&OCT 30° [HR] ART(9) Q: 32

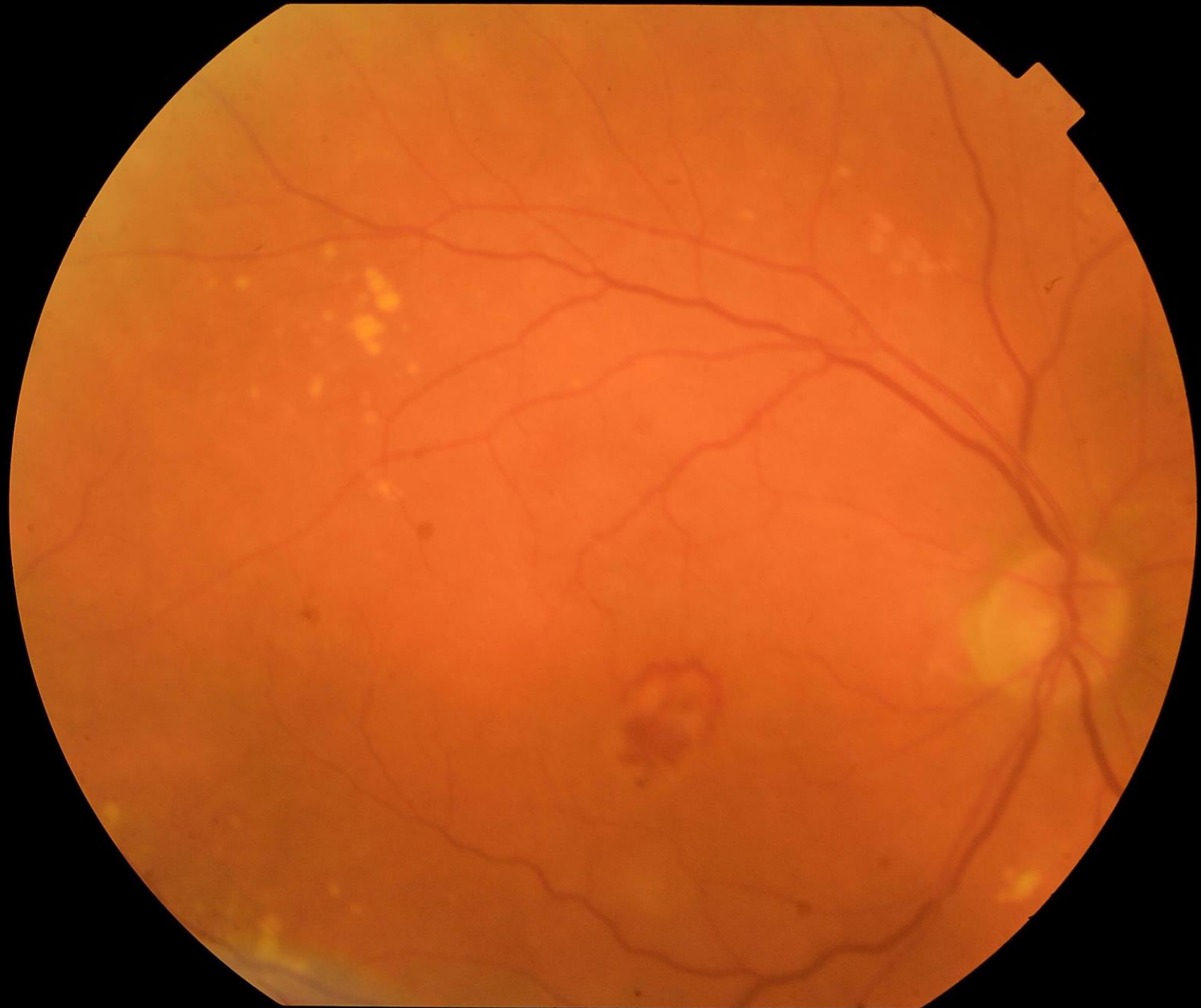


11/16/2016, OS

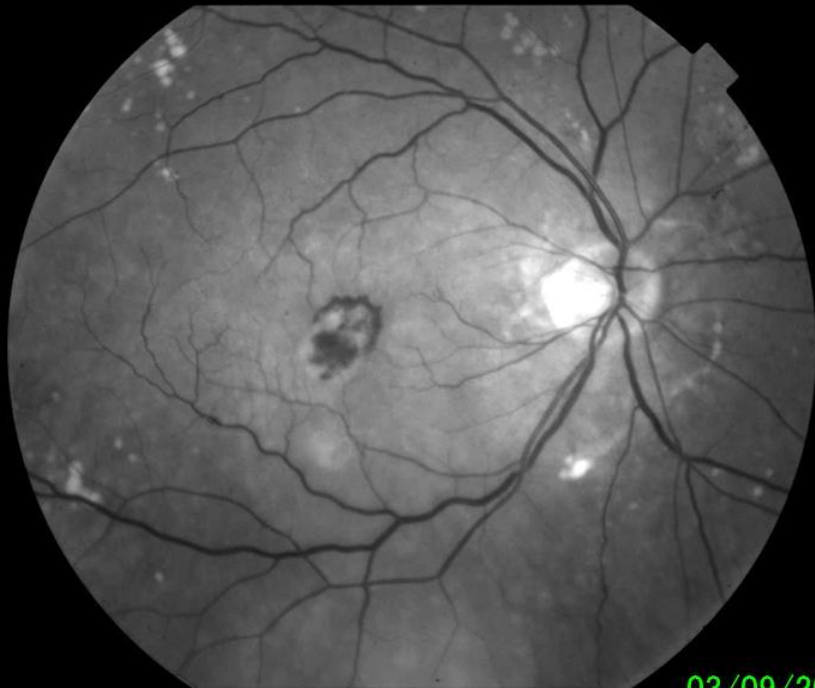IR&OCT 30° ART [HR] ART(9) Q: 26



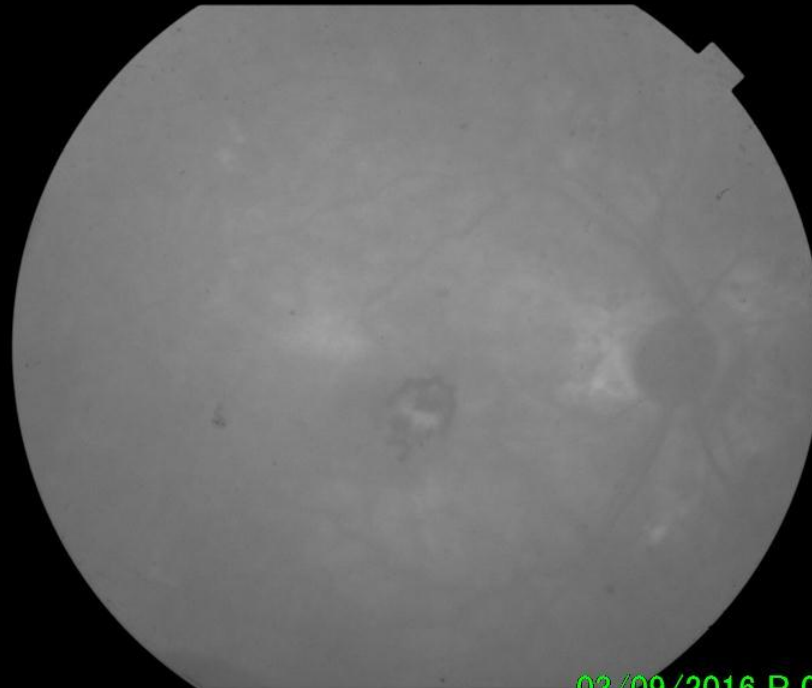
337911 82 Rosenberg Robert




337911 82 Rosenberg Robert



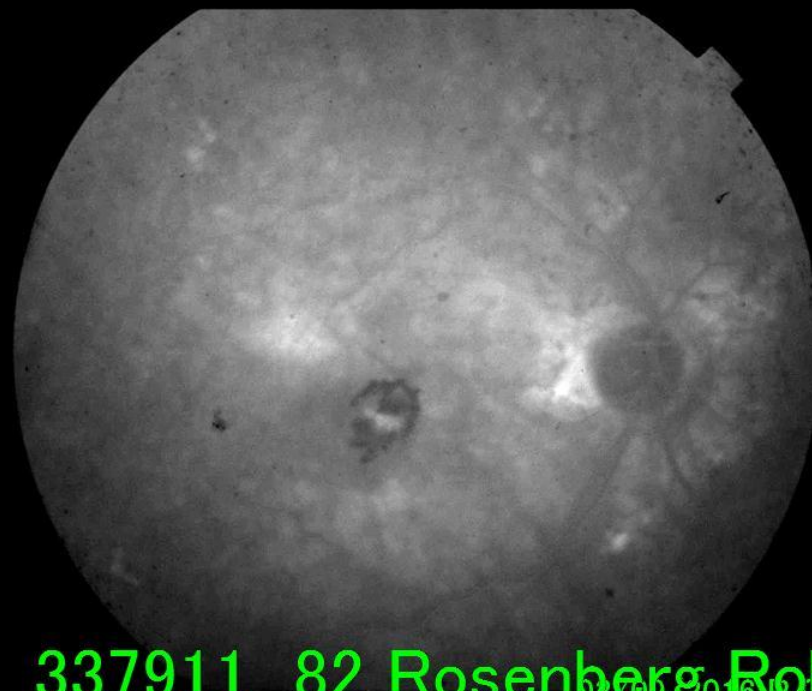
03/09/2016 R



03/09/2016 R 05:12.7

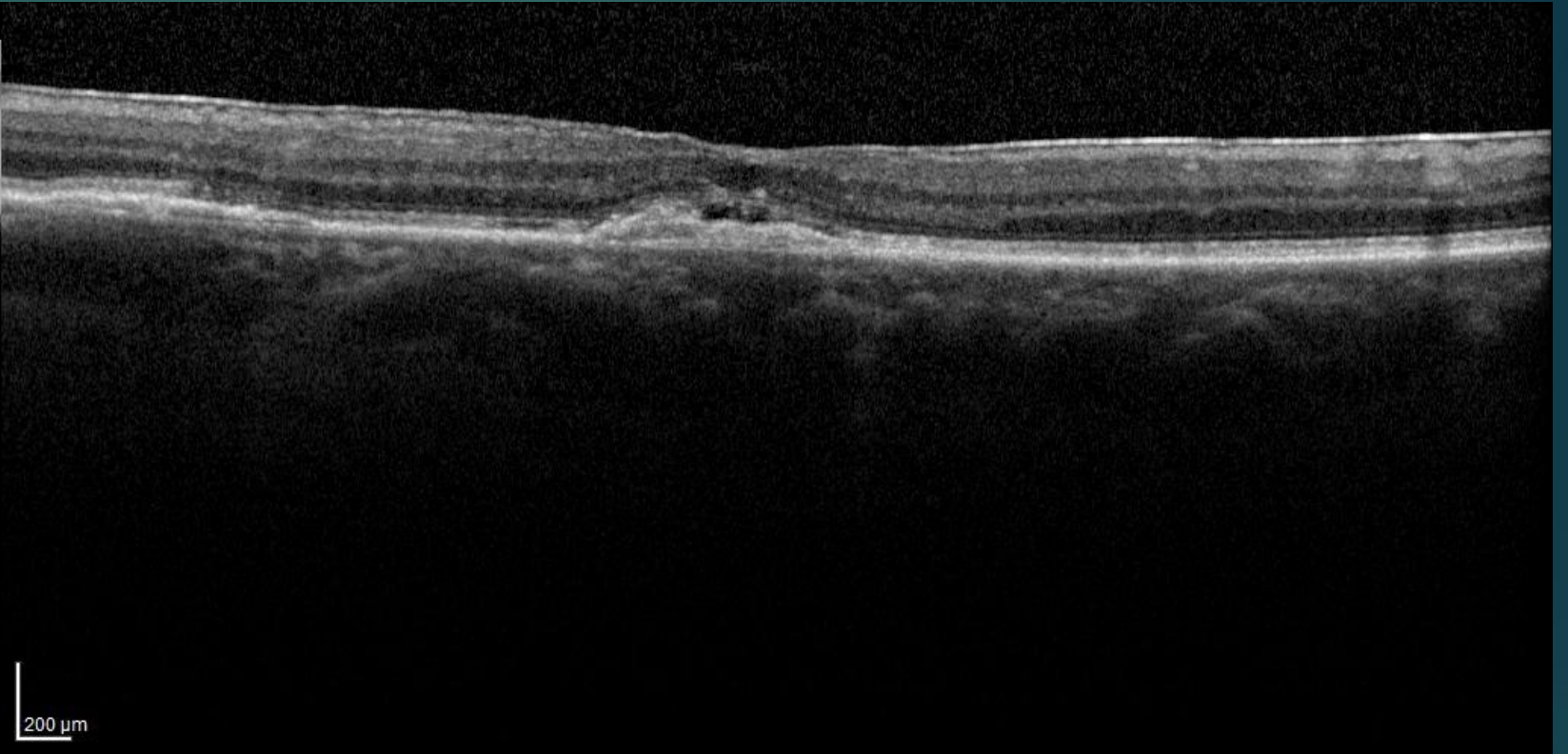
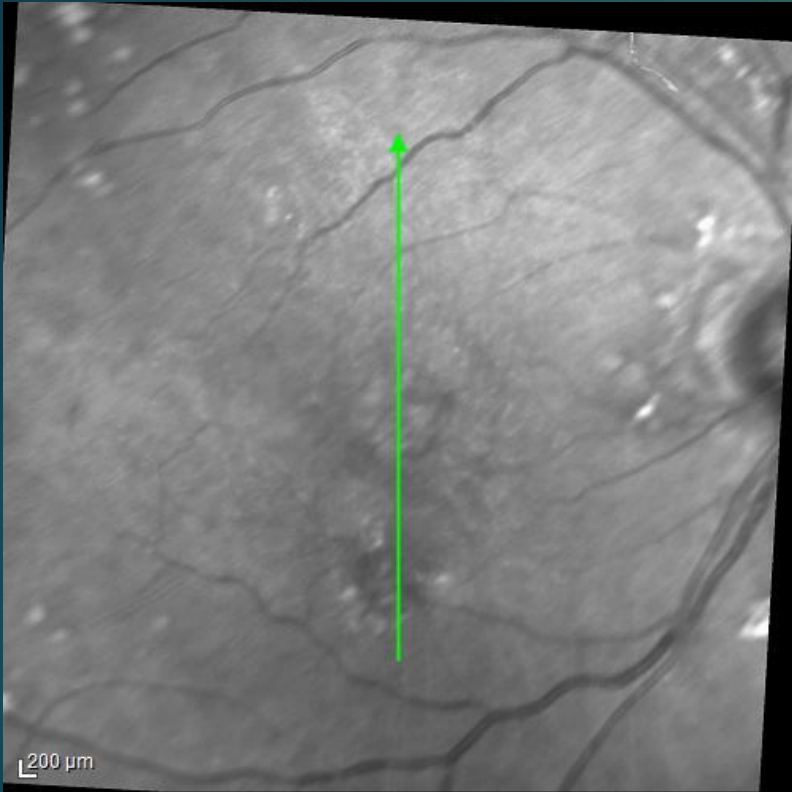


03/09/2016 R 01:33.9

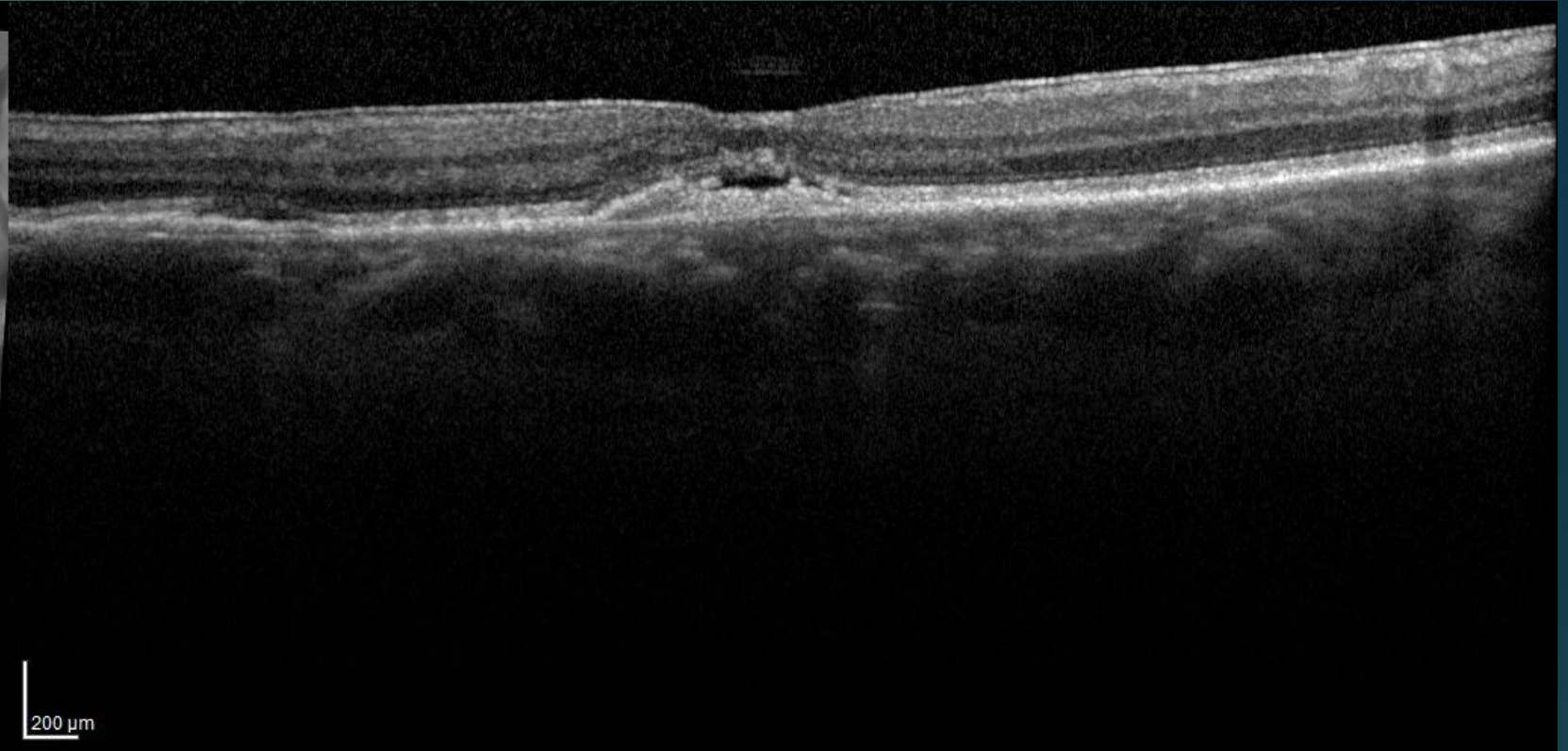
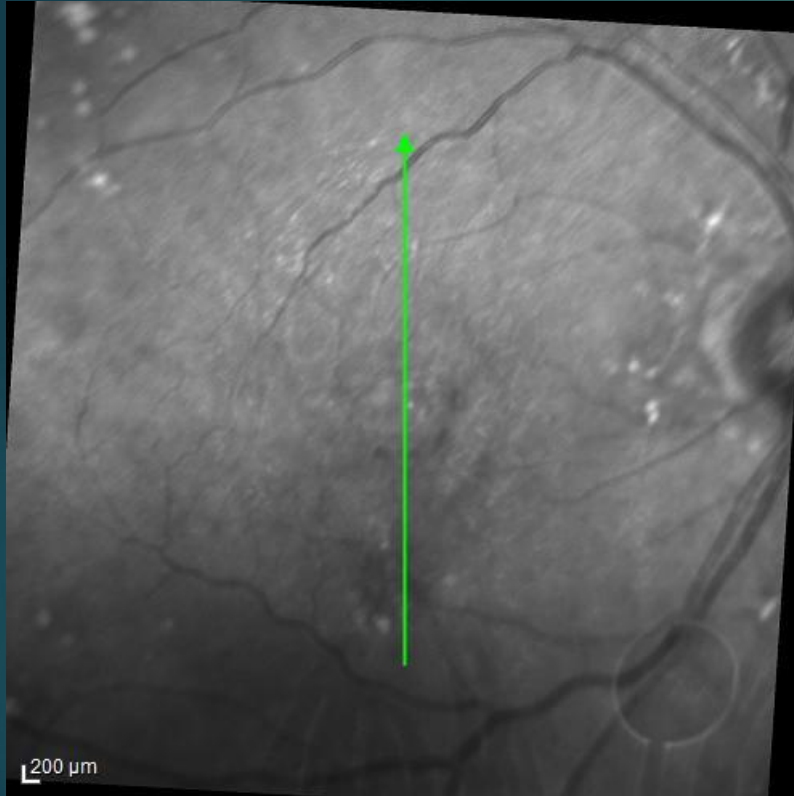


337911 82 Rosenberg, Robert

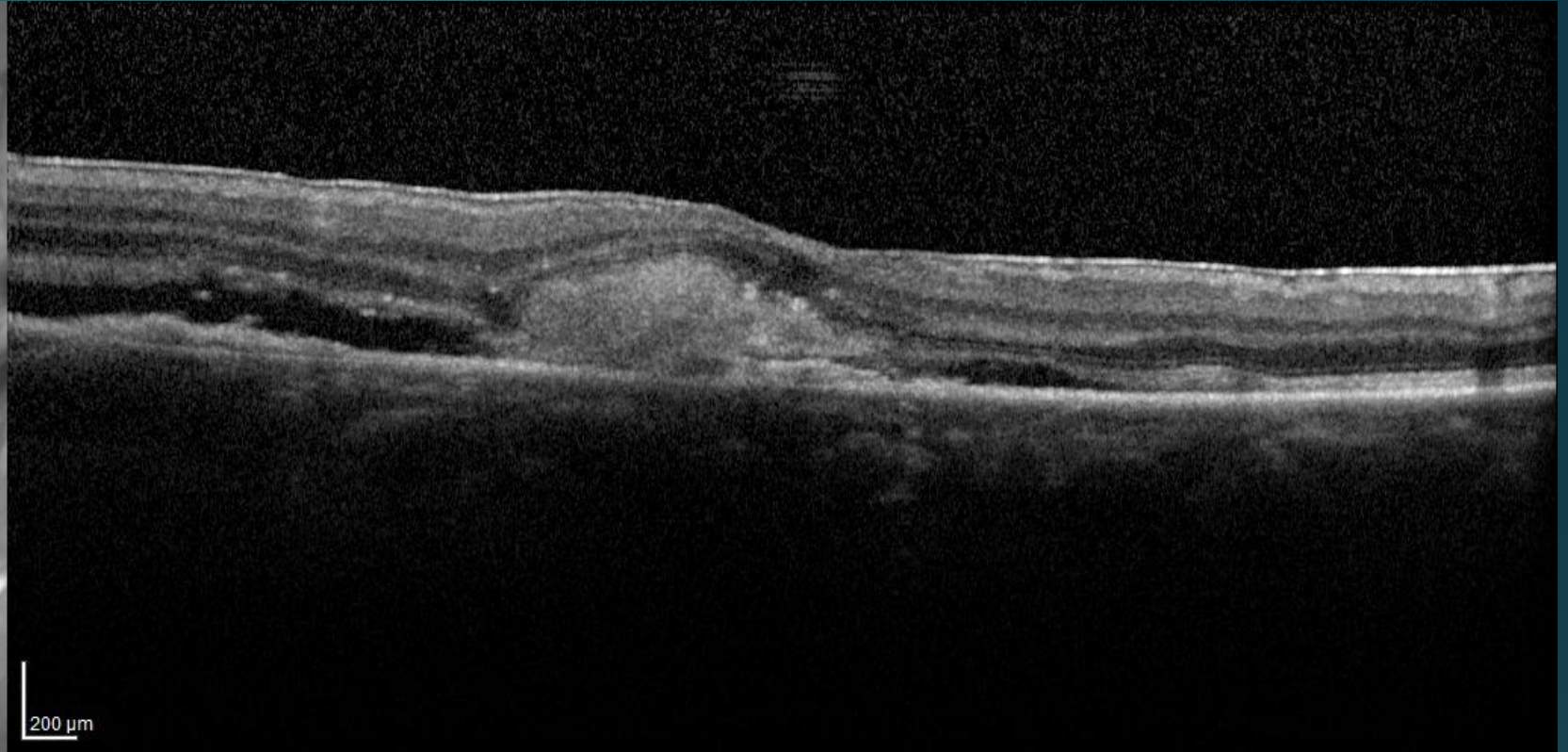
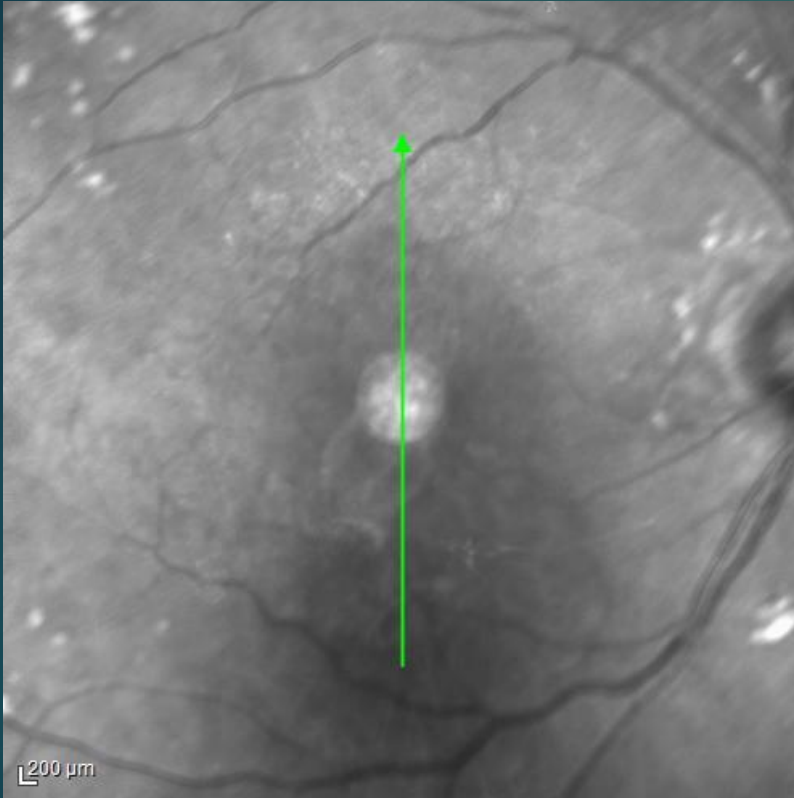
03/09/2016 R 09:13.5



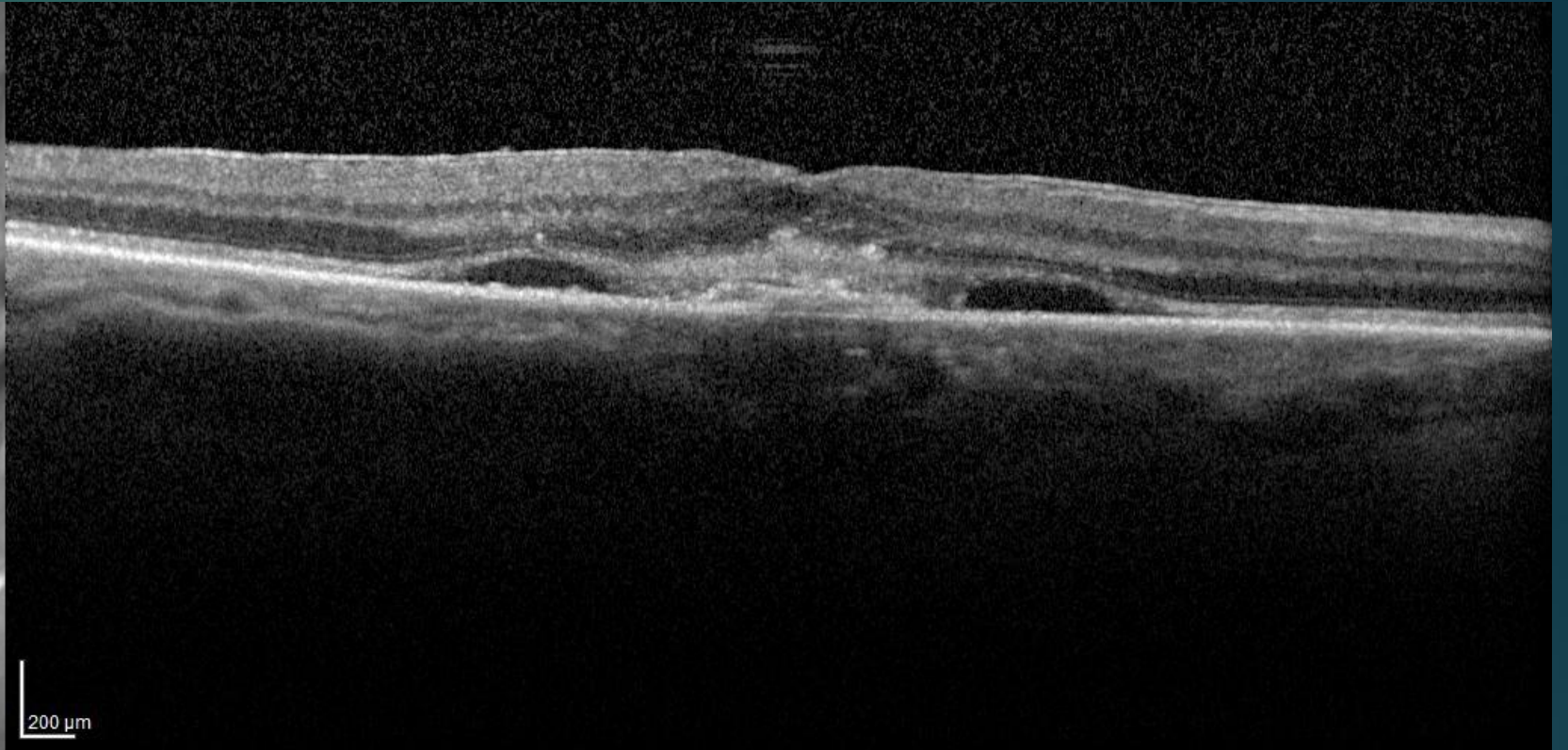
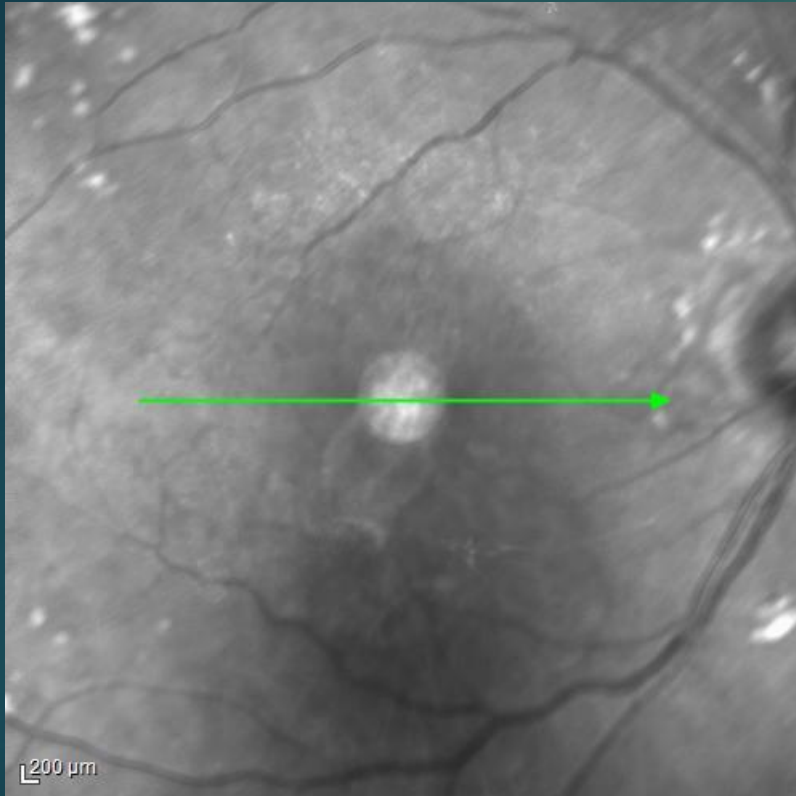
12/28/2016, OD
IR&OCT 30° [HR] ART(9) Q: 26



12/6/2017, OD
IR&OCT 30° [HR] ART(9) Q: 27



3/9/2016, OD
IR&OCT 30° ART [HR] ART(9) Q: 28



3/9/2016, OD

IR&OCT 30° ART [HR] ART(9) Q: 26

Thank You