

# When Is Disc Swelling Not Disc Swelling, and What Do We Do About It?

Kraskin Invitational Skeffington Symposium

Jan 19-21, 2019

John Abbondanza, OD



## Oona - 9 yr old

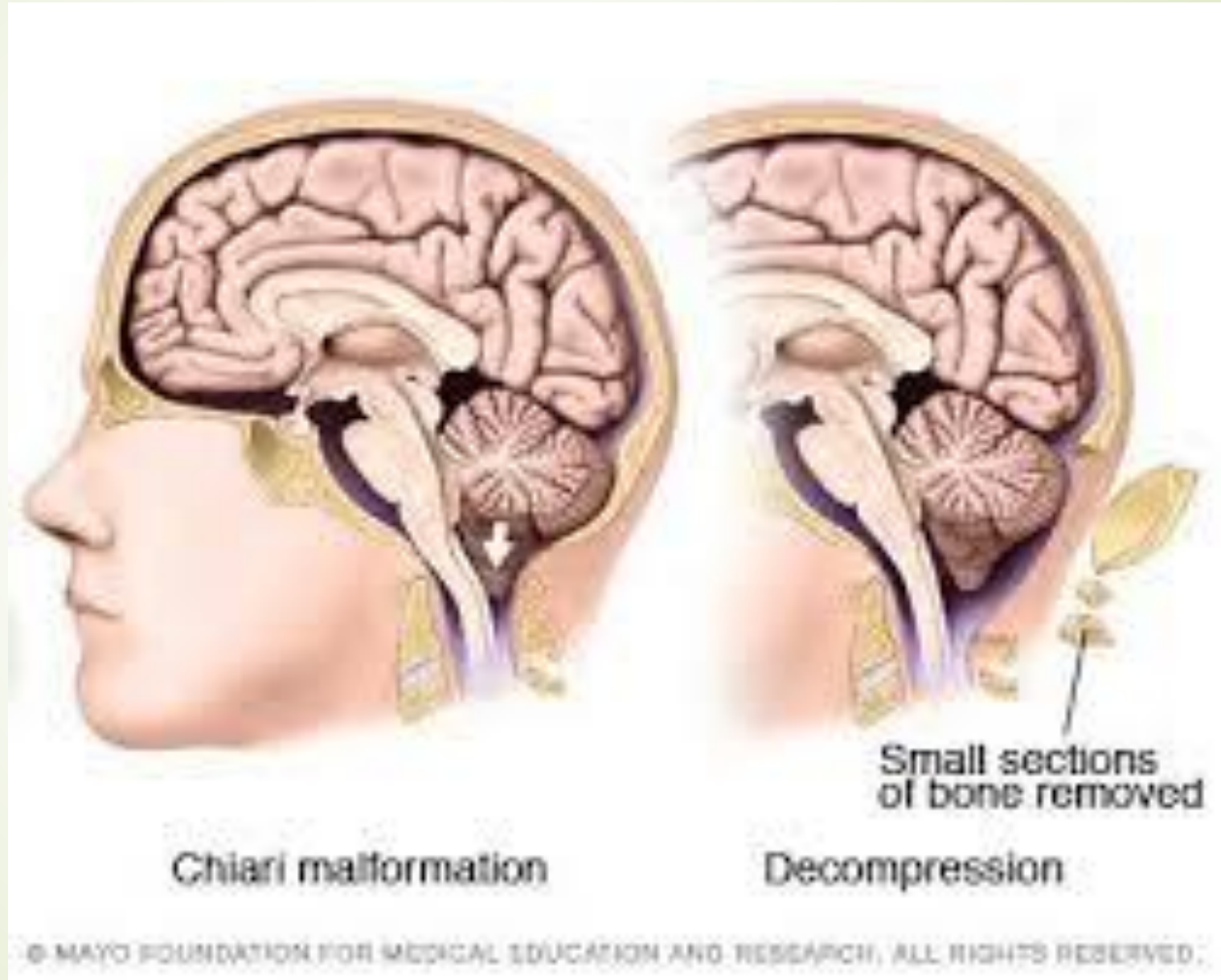
- Referred by OT and tutor for 'tracking problems'
- Hx of chiari malformation, LD, 'on and off' headaches
- On IEP since 3 yrs old for OT, speech
- In 3<sup>rd</sup> grade, 1 ½ - 2 yrs behind in reading
- LEE 5 months prior (OMD) found no visual problems and did not recommend Rx
- No other medical issues and no medications



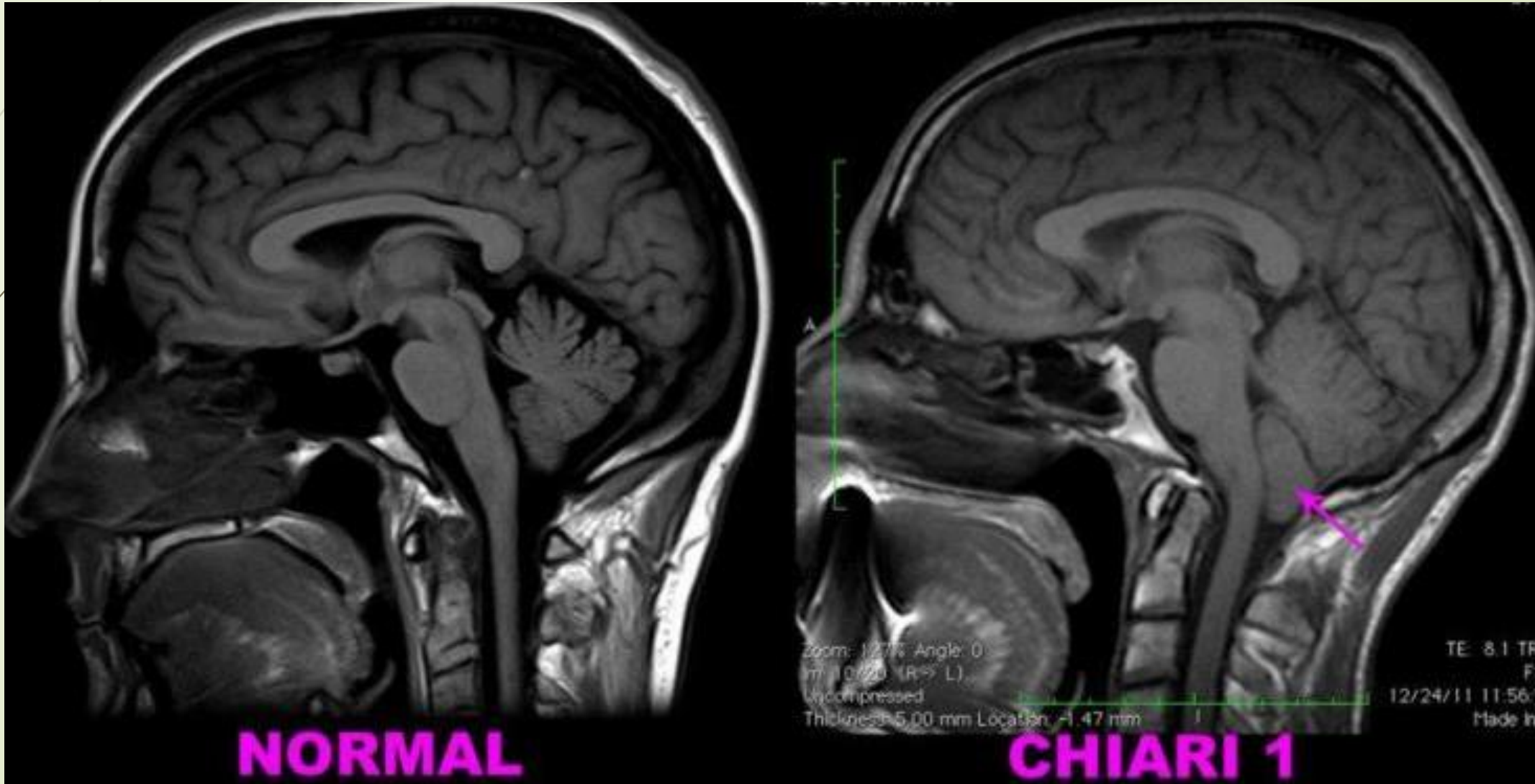
# Chiari Malformation

- Growing brain in a small skull pushes brain into the spinal canal
- Symptoms include:
  - Headaches, especially with Valsalva
  - Problems with balance and fine motor
  - Numbness, tingling, dizziness
  - Blurry or double vision
  - Delayed speech

# Chiari Malformation



# Chiari Malformation





# Oona

- sc VA 20/25+ OD, 20/20- OS
- sc CT Ortho 6-8 XP'
- NPC 5"/7", 8"/11" with red lens OD
- Reach Grasp Release 4"
- Ret OD +1.00 – 0.50 X 080  
OS +1.00 – 0.50 X 095
- MEM +1.25 OD/OS
- Stress Point Ret +1.25
- Significantly reduced pursuits and saccades, with multiple losses of fixation, and mild to moderate head movement




# Oona

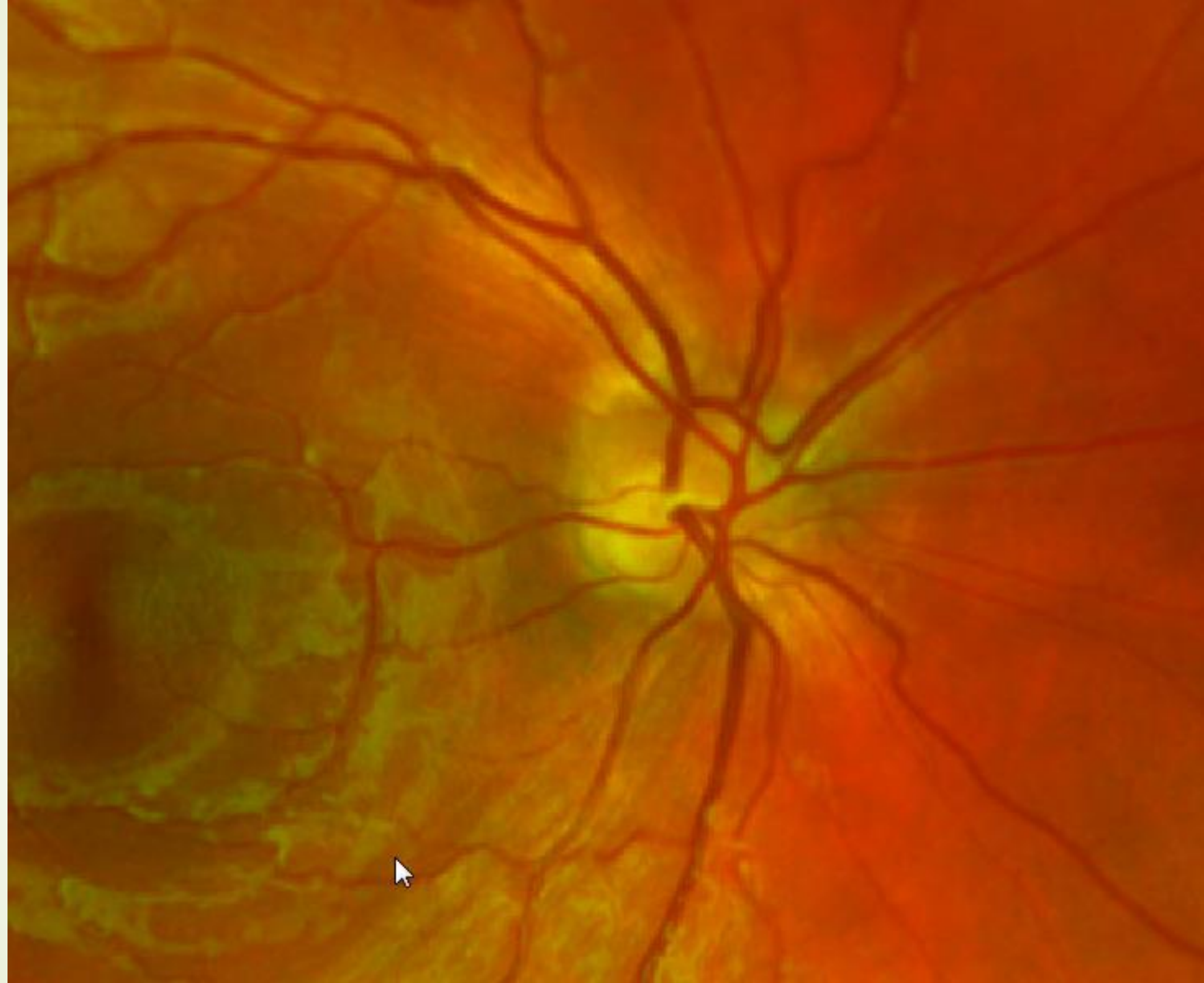
- FCF full OD/OS
- EOM's full all POG
- SLE – healthy
- O'scope – healthy maculae, vessels, periphery

**BUT is there anything going on with the ON??**


(see photos)



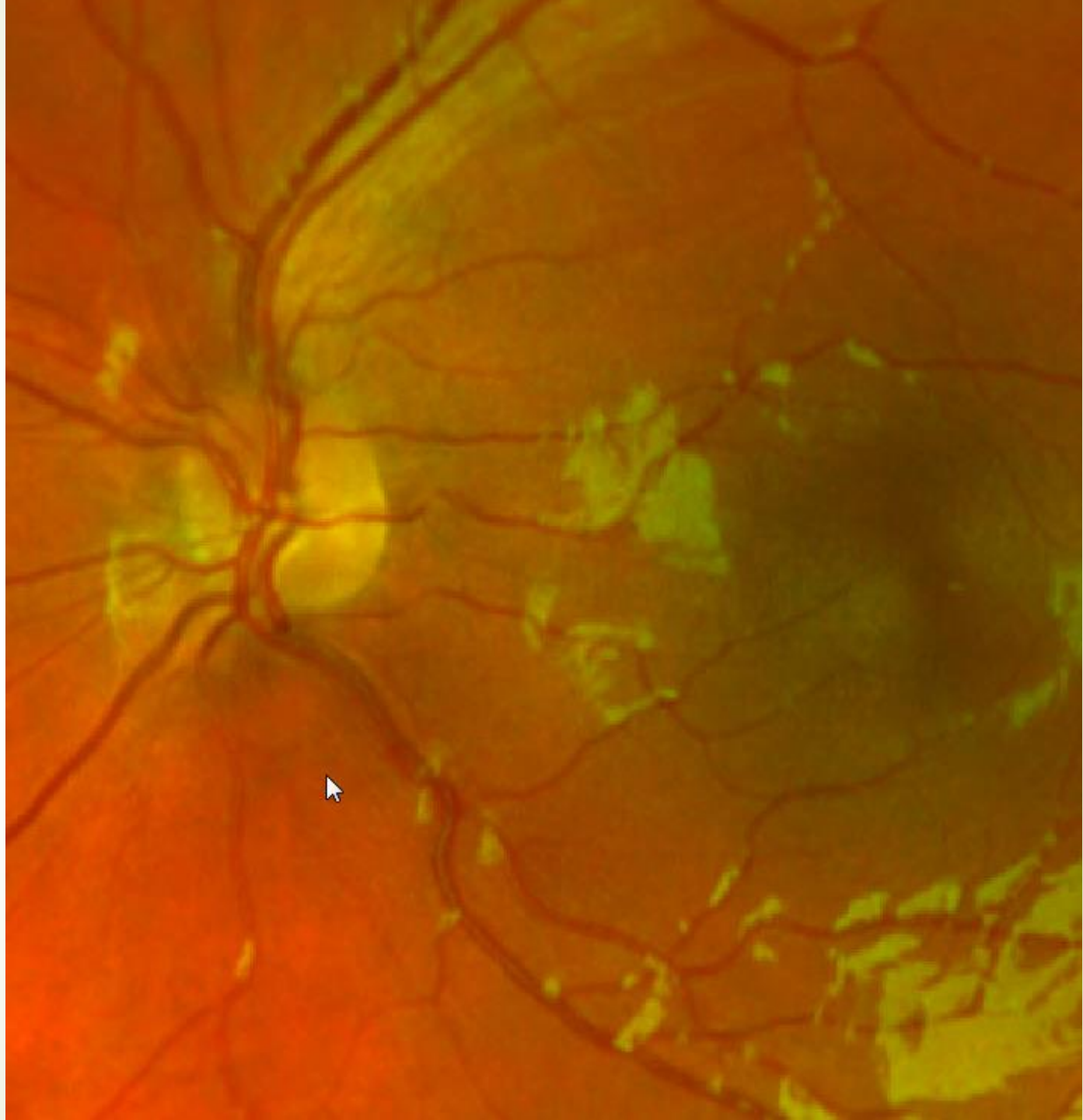

Feb 22,  
2018







Feb 22,  
2018



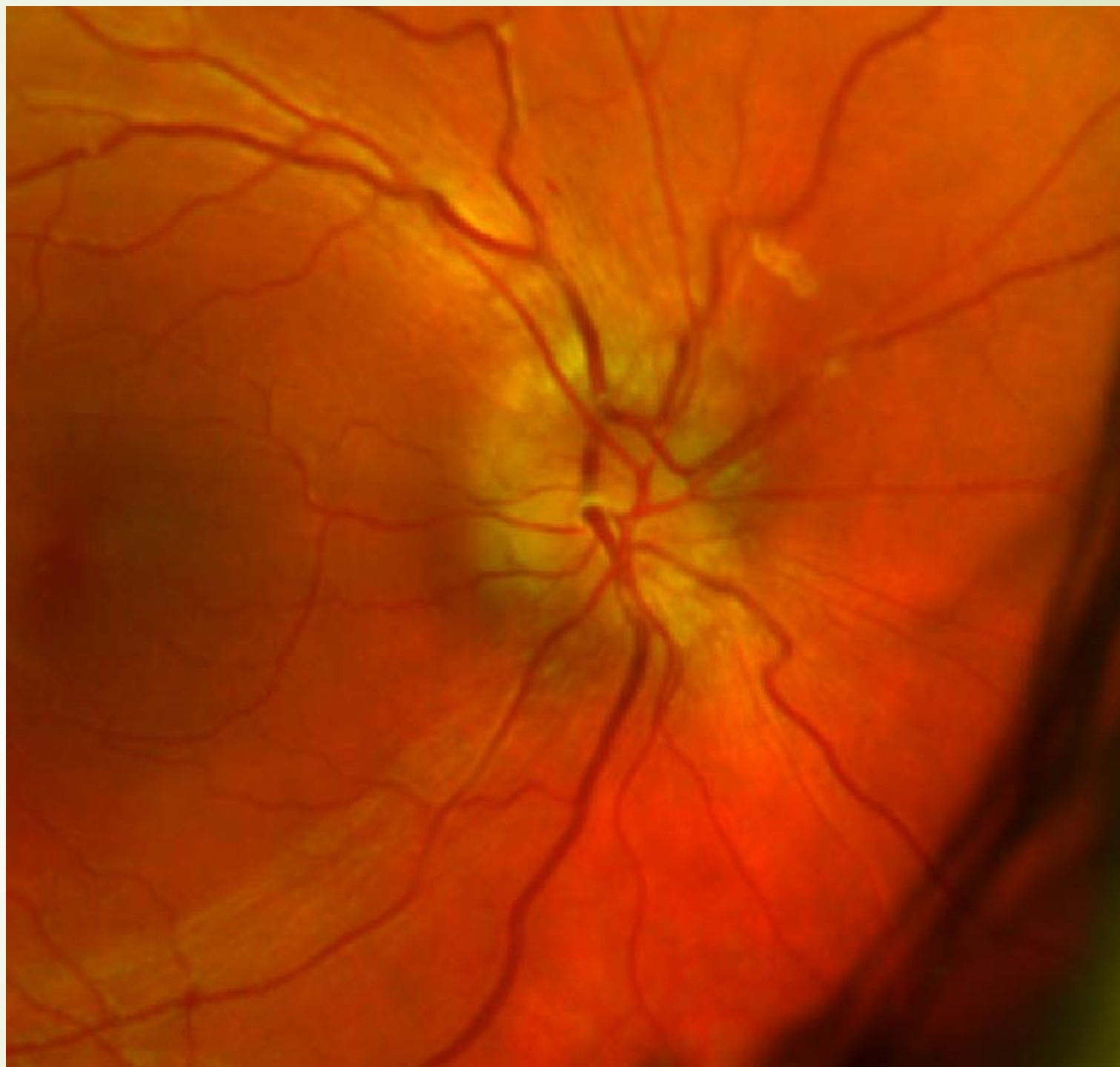


# Oona

- Impression - Convergence insufficiency, OMD, accomm dysfunction
- Plan:
  - Rx +0.75 OU full time in school and for all reading, studying, computers, and homework
  - Office based VT (OEP Clinical Curriculum 2)
  - Set up recall for 6 mo, in case they did not sign up for VT

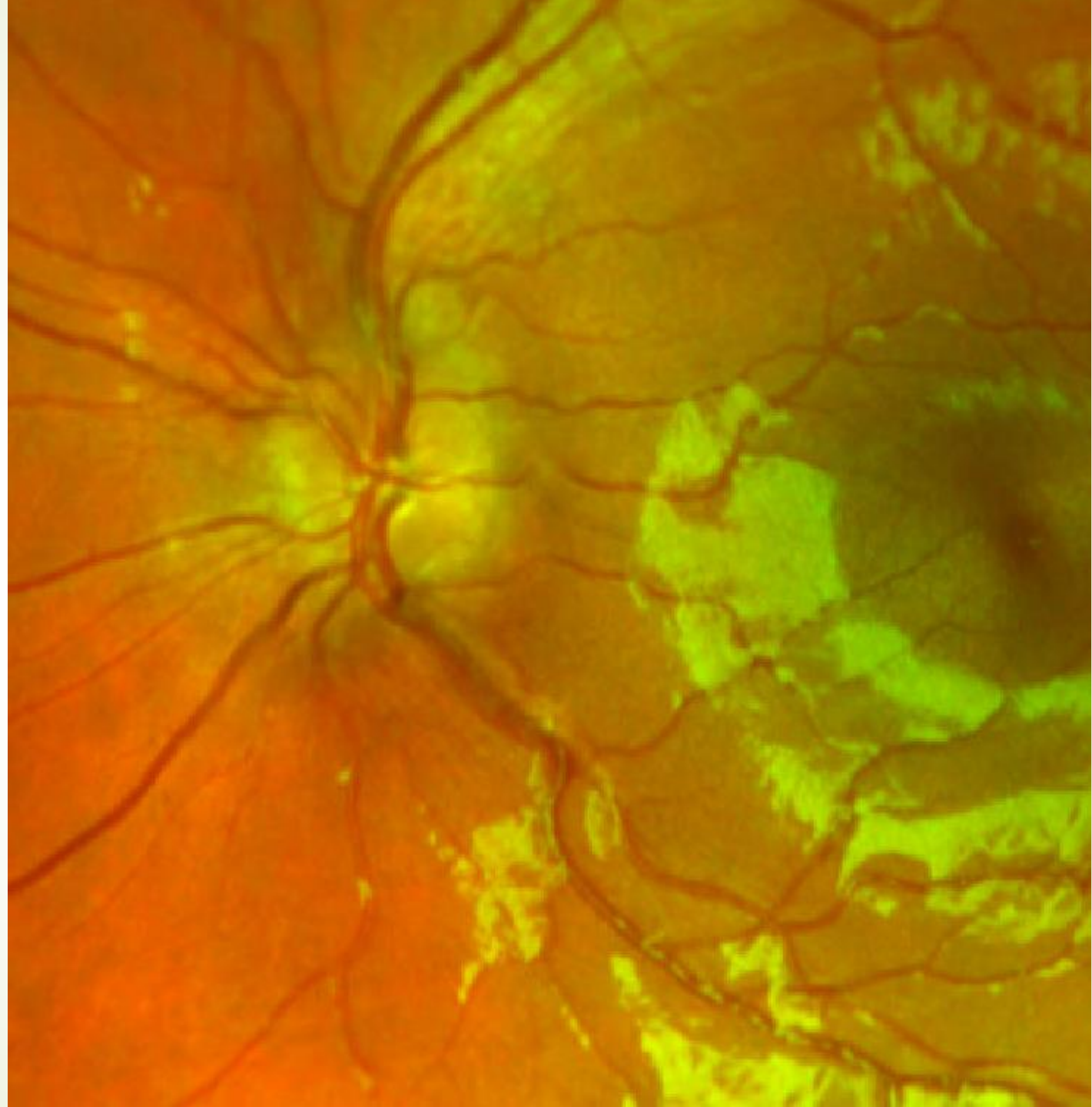


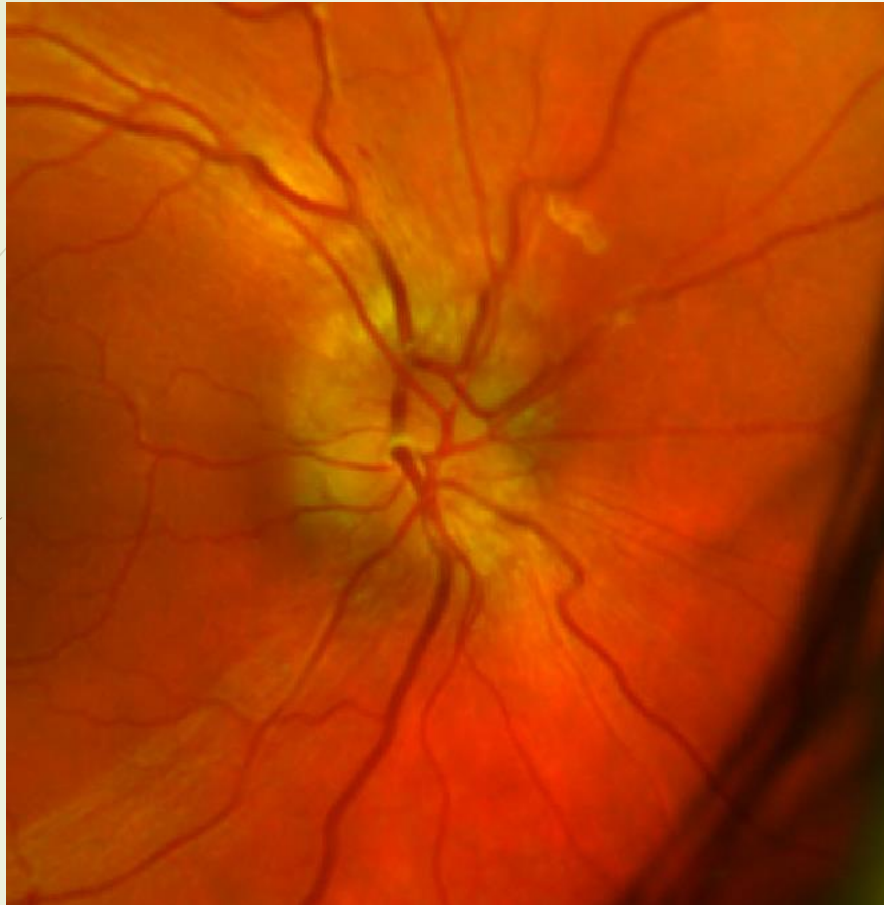Nov 19,  
2018





Nov 19,  
2018





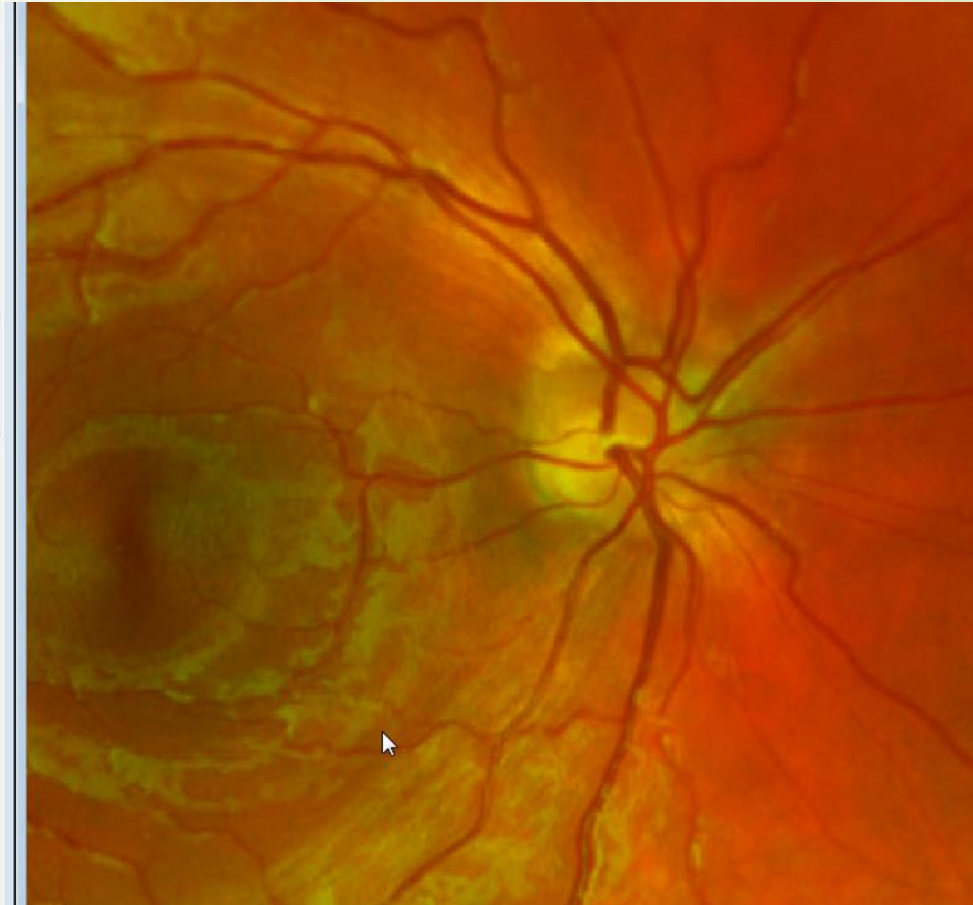Contrast x1.00  
Brightness +0  
Gamma 1.00

Optimize  
Restore

Green Balance  
Contrast x1.00  
Brightness +0

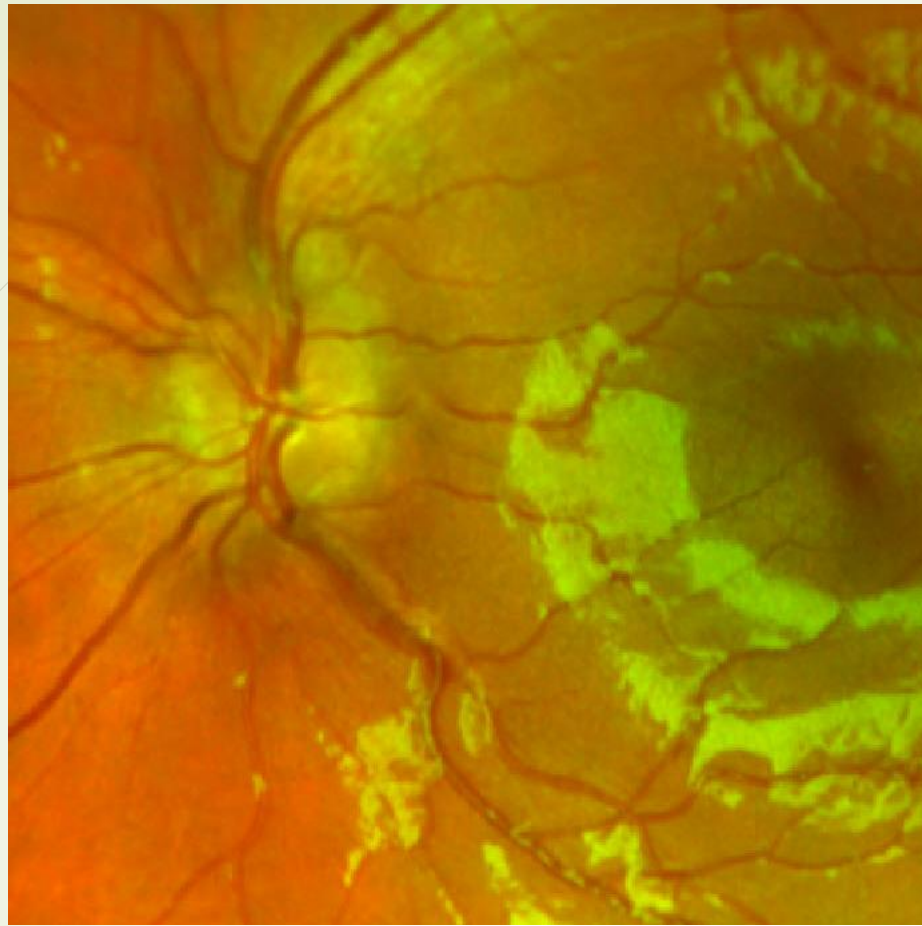
Captured By:  
John Abbondanza

Automated View

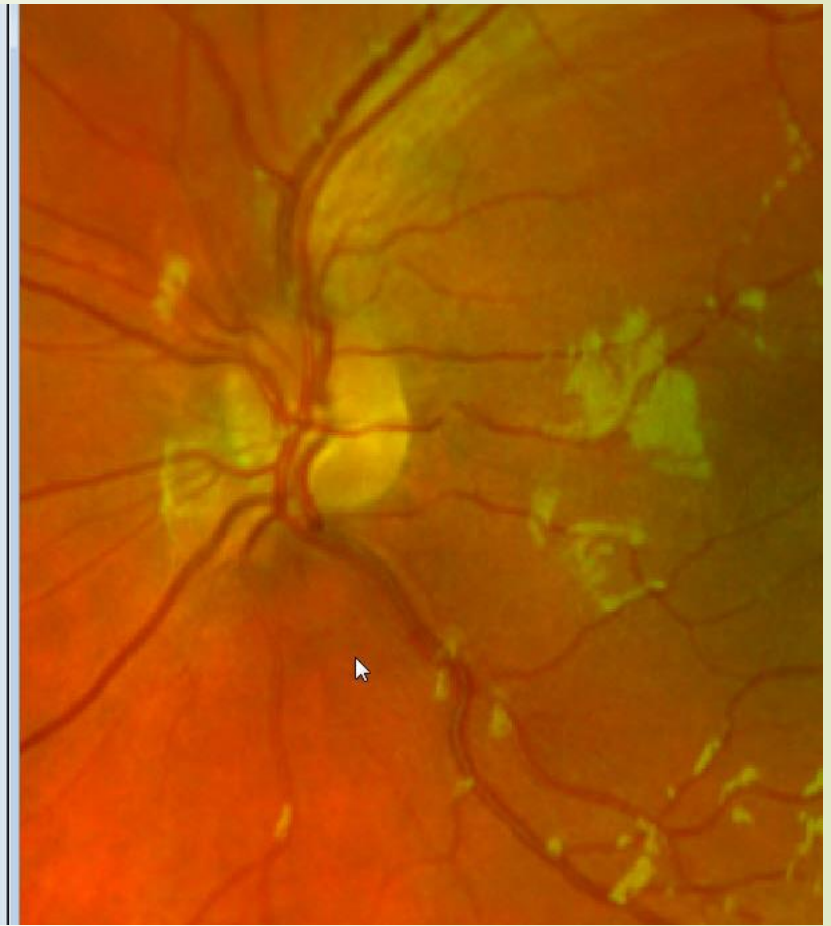


Nov 2018

Feb 2018



Brightness +0  
Gamma 1.00  
Optimize  
Restore  
Green Balance  
Contrast x1.00  
Brightness +0  
Captured By:  
John Abbondanza  
Automated View



Nov 2018

Feb 2018



# Management

- Refer to neurology – seen at Children's Hospital Boston
- MRI and CT negative
- Increased intracranial pressure
- Started on Diamox
- Will begin VT soon (supposedly)



# Questions for the group

- When do you refer?
- Would you have referred on the 1<sup>st</sup> visit?
- What happens when the ON is elevated but not swollen?
- How do you find good referral sources in your area?