

A Vivid Recovery of Stereopsis

Amina Weed, COVT VR VT Specialist

Background

- The patient had two strabismus surgeries prior to vision therapy.
- This afforded her orthoptic cosmetic positioning of OD without measurable stereopsis
- This was followed by an eventual regression to >30 prism diopter OD ET at distance and >25 prism diopter alternating ET at near
- She sought out vision therapy due to her worsening visual symptoms (diplopia, asthenopia, and occasional dizziness)
- She began vision therapy in January of 2016

New and Old Methods Combined


Using standard and new vision therapy techniques I was able to see progress in this patient more rapidly than patients prior.

- Therapy began with standard pursuits and saccades as well as accommodative therapy and eventually MFBF
- The biggest hurdle was the suppression in OS as well as her large strabismic angle
- Binasal occlusion was applied, this made her dizzy
- Central occlusion of OS was applied, this made her unsure of her location in space
- Started using VR to break down the suppression in OS, this had a major impact on the patient progress


Session Timing and Sequencing



- 45 minute sessions 1x/wk
- 5 days of home therapy
- 15 min of that 45 min was spent on VR in the beginning of the session
- 30 min was spent on pursuits with Marsden Ball, antisuppression and fusion with brock string, and hart chart for accommodation

Lives: 5 | Score: 0 x1 | Level: 1

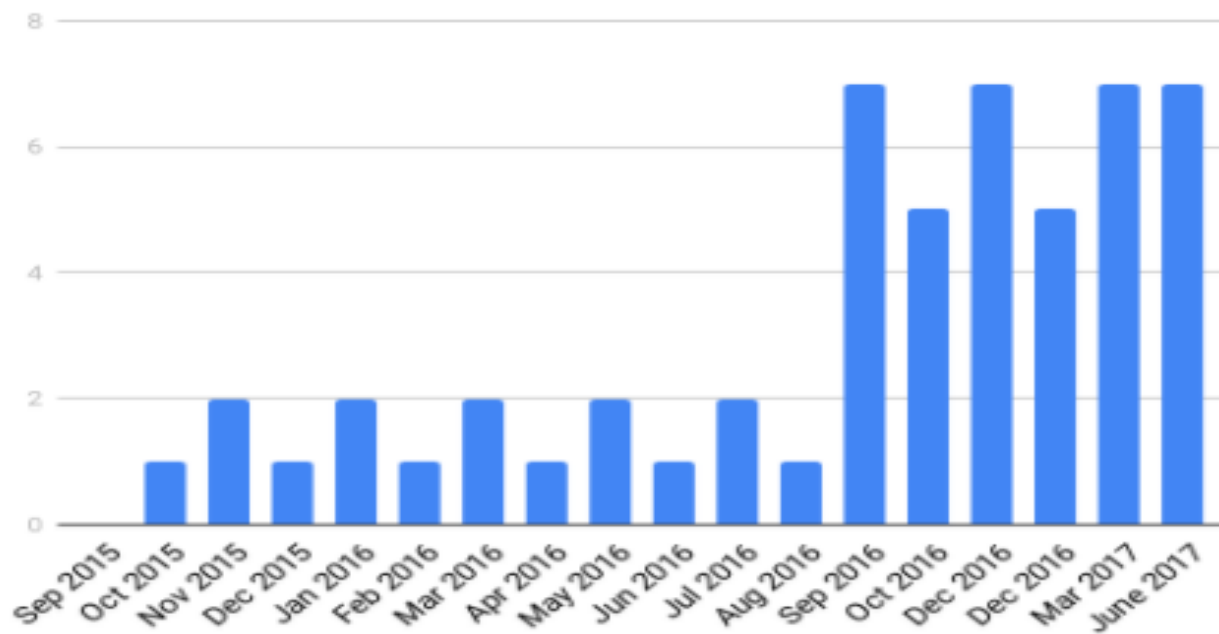


Lives: 5 | Score: 0 x1 | Level: 1





Change in Bubble Scores over time



Results

- ▷ When she was binocular, she had measurable stereo (40 arc seconds)
- ▷ Her deviation required an additional surgery and follow up vision therapy
- ▷ Her pre- and post-surgical visual rehabilitation prepared her visual system to use both eyes simultaneously
- ▷ She is now orthoptic with measurable stereo





Amina Weed, COVT

VR VT Specialist

amina@seevividly.com