

# **Anterior Eye Conditions Managing Common Anterior Eye Conditions in Practice**

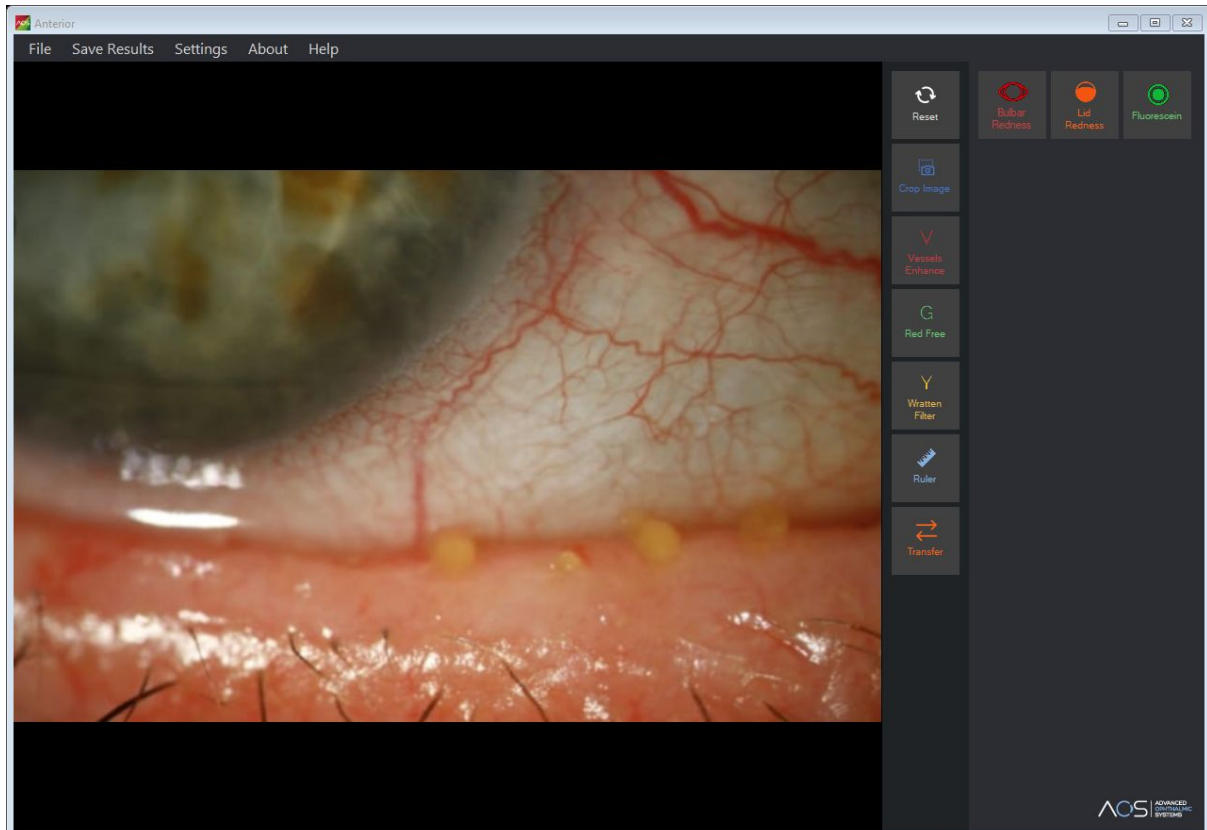
**C-73869**

The ability to recognise and diagnose common anterior eye conditions is an important skill for DO's, CLO's and Optoms. Whether it's understanding the conditions so they can be diagnosed, treated or triaged or so you can give the relevant advice to the patient, being able to recognise and understand the risk factors and management options is essential. This discussion workshop will focus on four case studies with different anterior eye conditions.

Images provided by:



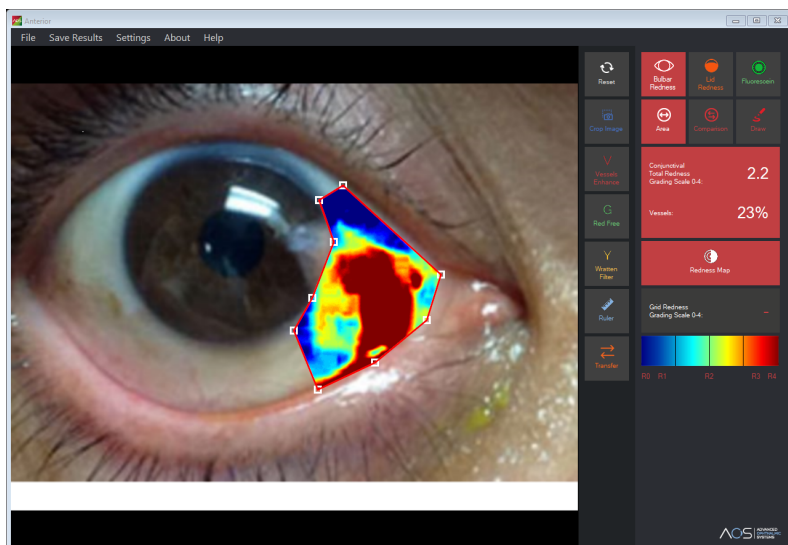
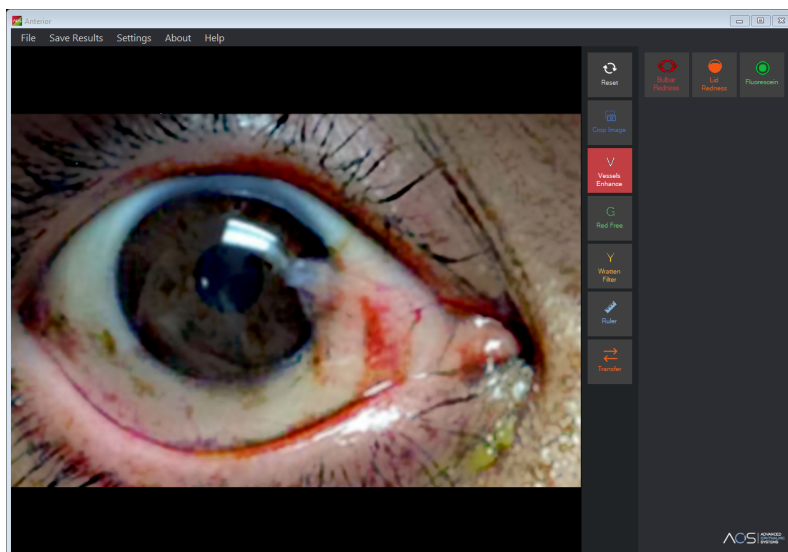
Px 1 is a 62 year old male contact lens wearer who attends for an eye test in January. Over the last few weeks he has noticed his eyes are watering constantly but also feel itchy and irritated. Vision with contact lenses becomes smeary after a while. The px currently wears monthly lenses. Upon slit lamp examination inferior corneal staining is noticed and lipid deposits are apparent on the lens surface. The lid margins appear thickened.



#### Discussion Points:

- Possible diagnosis
- Aetiology
- Management options

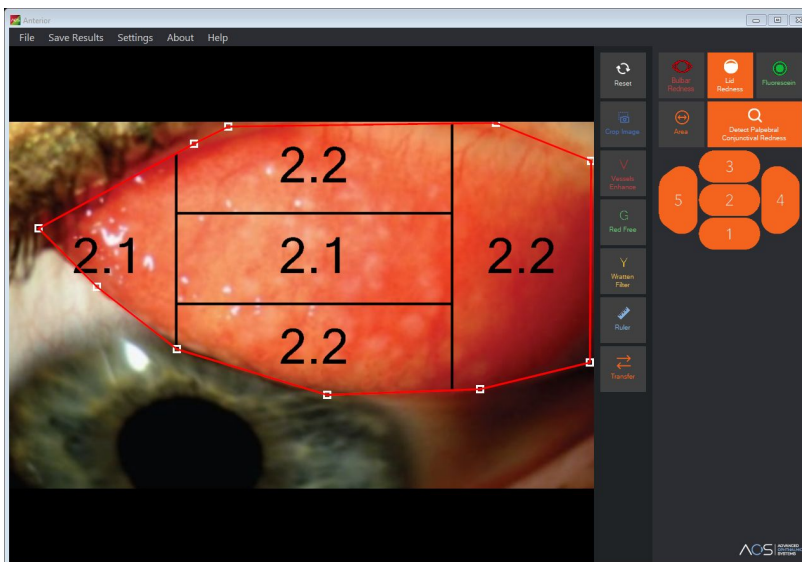
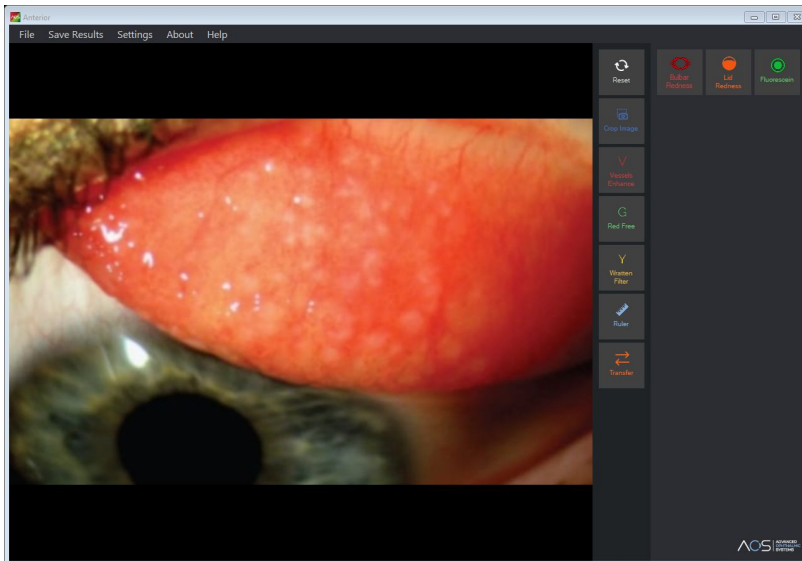
Px 2 is a 52 year old female who has moved to the UK from Kenya. She is concerned about a growth on the bulbar conjunctiva, situated on the nasal side. Although she has no symptoms, she is concerned that it has got bigger over time and is concerned about the cosmetic appearance. The right eye is worse but she has noticed a smaller one on the left. The px is interested in contact lenses but is worried this may cause a problem.



#### Discussion Points:

- Possible diagnosis
- Aetiology
- Management options
- Are CIs possible?

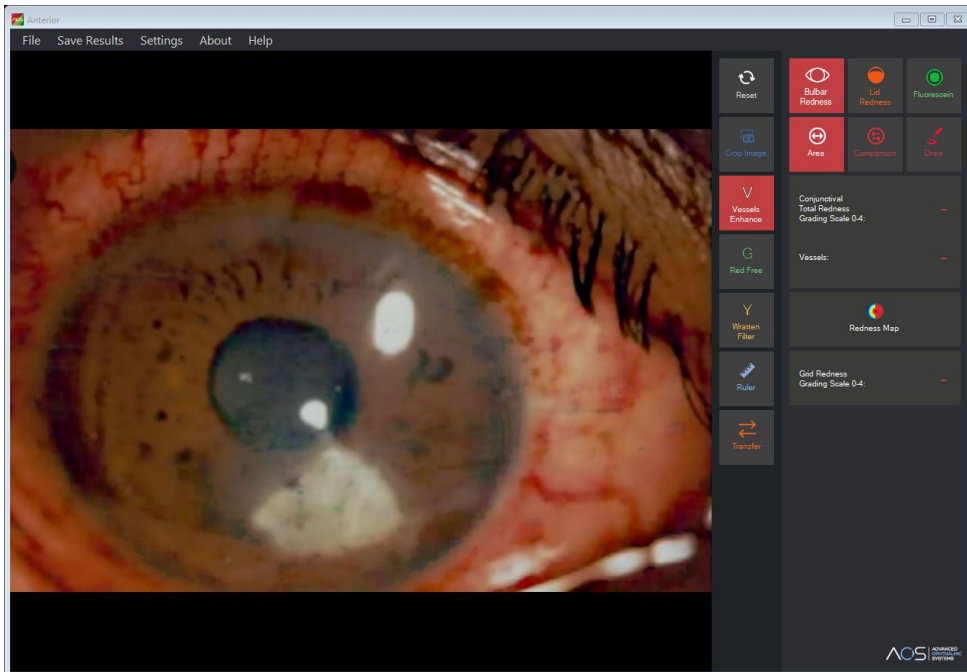
Px 3 is a 26 year old female contact lens wearer. She has increased her wear time considerably since her last aftercare, which was 1 year ago. She now wears Air Optix monthly lenses for 12-14 hours per day, whereas previously she wore 1 Day Acuvue Moist for around 10 hours per day. Recently she has noticed her eyes feel uncomfortable and itchy, which gets worse when the lenses are removed. Towards the end of the day she feels her vision is smeary.



#### Discussion Points:

- Possible diagnosis and cause
- What kind of signs would you expect to see under the slitlamp?
- Management options

Px 4 is a 19 year old male student, who is also a contact lens wearer. The px currently wears extended wear monthly lenses, which he removes once per week. He took the lenses out two nights ago but dropped one in the sink before putting it in the case. The px came into practice today complaining of severe pain that suddenly came on earlier in the day. He is photophobic and his lids appear puffy. He has left his lenses in as the pain doesn't improve on removal.



#### Discussion Points:

- Possible diagnosis and aetiology?
- What kind of signs would you expect to see under the slitlamp?
- Management options
- Prognosis

**Reflective Learning Statement C-73869      Paediatric Dispensing**

Name: \_\_\_\_\_ GOC Number: \_\_\_\_\_

Date of Peer Review: \_\_\_\_\_

Name of Facilitator: Stuart Wellings D-14262

**Summarise the clinical skills and competencies that were discussed during this session:**

**List the main things you learned from this session:**

**Describe how you will apply this learning in your practice:**

**Has this session identified any areas where further personal learning is needed? If so briefly describe these below:**

**Signed: .....**      **Date:** \_\_\_\_\_