



Available online at
SciVerse ScienceDirect
www.sciencedirect.com

Elsevier Masson France
EM|consulte
www.em-consulte.com/en



REVIEW ARTICLE

Lumbar-pelvic-femoral balance on sitting and standing lateral radiographs

J.Y. Lazennec^{a,*,b,c}, A. Brusson^c, M.A. Rousseau^{a,b}

^a Department of orthopedic and trauma surgery, La Pitié-Salpêtrière hospital, 47-83, boulevard de l'Hôpital, 75013 Paris, France

^b Biomechanics Lab, Arts et Métiers Paritech, 151, boulevard de l'Hôpital, 75013 Paris, France

^c Department of Anatomy, université Pierre-et-Marie-Curie-Paris-6, 105, boulevard de l'Hôpital, 75013 Paris, France

Accepted: 27 November 2012

KEYWORDS

Sagittal spinal balance;
Pelvic balance;
Posture;
Standing;
Sitting;
Total hip arthroplasty;
Cup anteversion;
Hip flexion contracture;
Pelvic rotation;
EOS imaging system

Summary Trunk balance in upright stance expresses an individual postural strategy found on anatomic and functional parameters. The “pelvic vertebra” is an essential transitional region for the coherence of spinal parameters (notably, lumbar lordosis and thoracic kyphosis) and pelvic parameters (sacral slope, pelvic tilt and incidence). Deterioration of this postural harmony is often associated with spinal aging, maladjusted spinal arthrodeses, or mechanical abnormalities of the hip joints. Spinal surgeons are aware of the importance of detecting and analyzing sagittal imbalance, whether compensated or not. The influence of the hip joint, however, is underestimated and poorly objectified on conventional imaging, as are its interrelations with overall lower-limb posture. Currently, hip surgeons focus basically on the pelvis as bone reference in planning implantation, peroperative adjustment and failure analysis. The antero-posterior (AP) pelvic view is the gold standard, with lateral views being little used. Influenced by the classic anatomic attitude in favor of transverse slices in dorsal decubitus, CT is considered the reference method for “horizontal” assessment of the hip joint. The present study draws attention to a more global vision of the pelvic and subpelvic regions in the sagittal balance of the trunk, relying on the sitting as well as the standing posture, as both involve subtle mechanisms of adaptation governed by the pelvic incidence angle.

© 2013 Published by Elsevier Masson SAS.

Introduction

Trunk balance results from a postural strategy determined by anatomic features inducing adaptations that may vary greatly from one subject to another. Balance deterioration, often associated with spinal aging, may trigger a functional,

neurological and/or mechanical cascade [1]. The role of the pelvic region in sagittal balance in upright stance is obvious to spine surgeons, who take full account of sacral slope, pelvic incidence angle and pelvic tilt [2–6]. Interpretation of spino-pelvic parameters is fundamental to the detection and analysis of sagittal imbalance, both compensated and non-compensated [7].

In contrast, the role of the hip joint, and of its interrelations with the lower-limb posture as a whole, remains underestimated and poorly determined on conventional imaging. These factors are often neglected by hip surgeons,

* Corresponding author.

E-mail address: lazennec.jy@wanadoo.fr (J.Y. Lazennec).

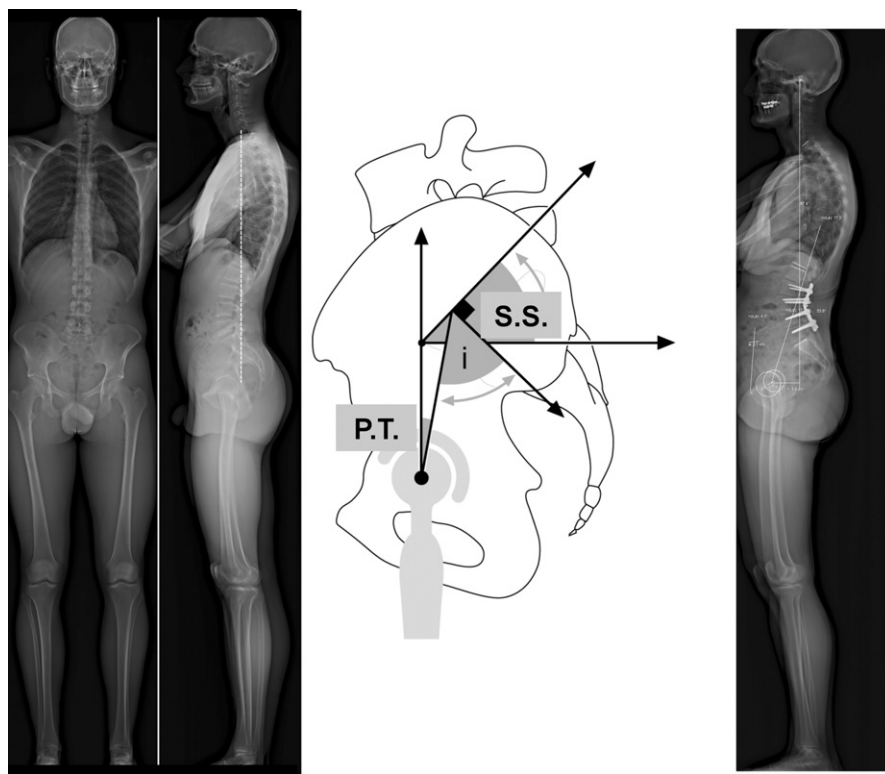


Figure 1 Normal or "neutral" sagittal balance: the vertical through the center of C7 should project near the posterosuperior angle of the sacrum. The same criteria apply to the operated spine. The pelvic incidence angle (I) is related to sacral slope (SS) and pelvic tilt (PT) as $I = SS + PT$.

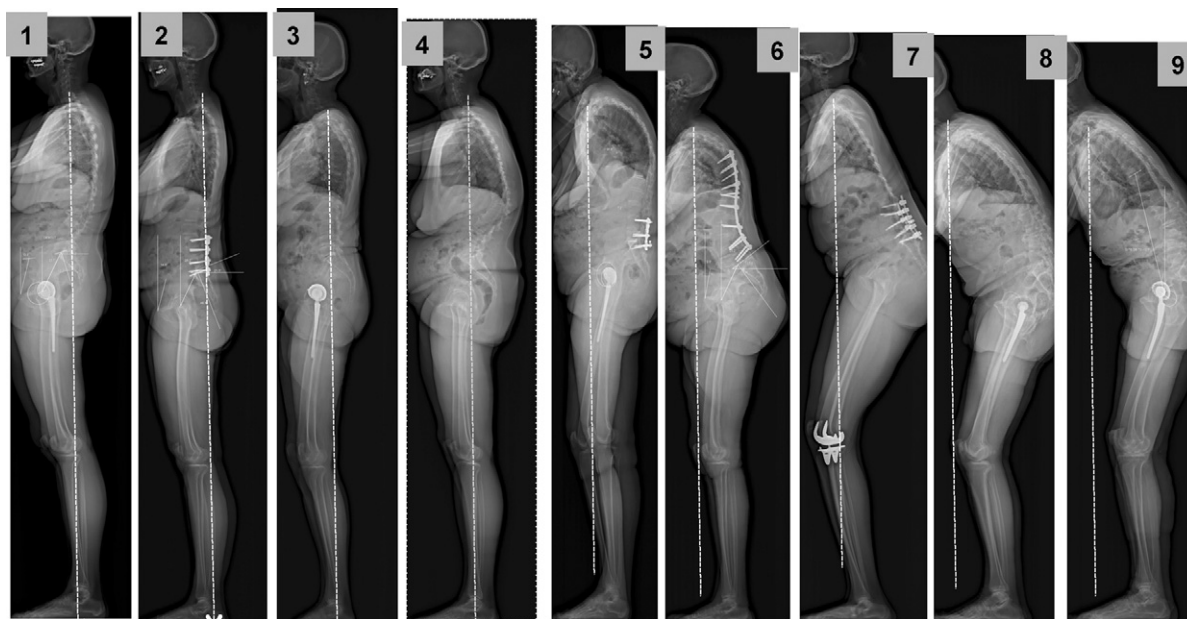


Figure 2 Compensated sagittal posture disorder: case 1: extensive thoracolumbar spinal deterioration; hip compensation in hyperextension; case 2: poorly adjusted lumbar arthrodesis; hip compensation in hyperextension; case 3: angular loss related to multilevel discal lesions: compensation by mild adaptive flexion contracture of the hip; case 4: defective sagittal posture compensated for by remodeled spinal curvature.

Non-compensated sagittal posture disorder; case 5: flexion contracture of the hips fails to compensate flat back and cervicothoracic kyphosis; case 6: insufficient hip-joint compensation under an arthrodesis failing to achieve sufficient lordosis; cases 7, 8, 9: flatback and pelvic posterior tilt; the deformity is so severe that the hip and knee flexion contracture compensation mechanisms are no longer effective.

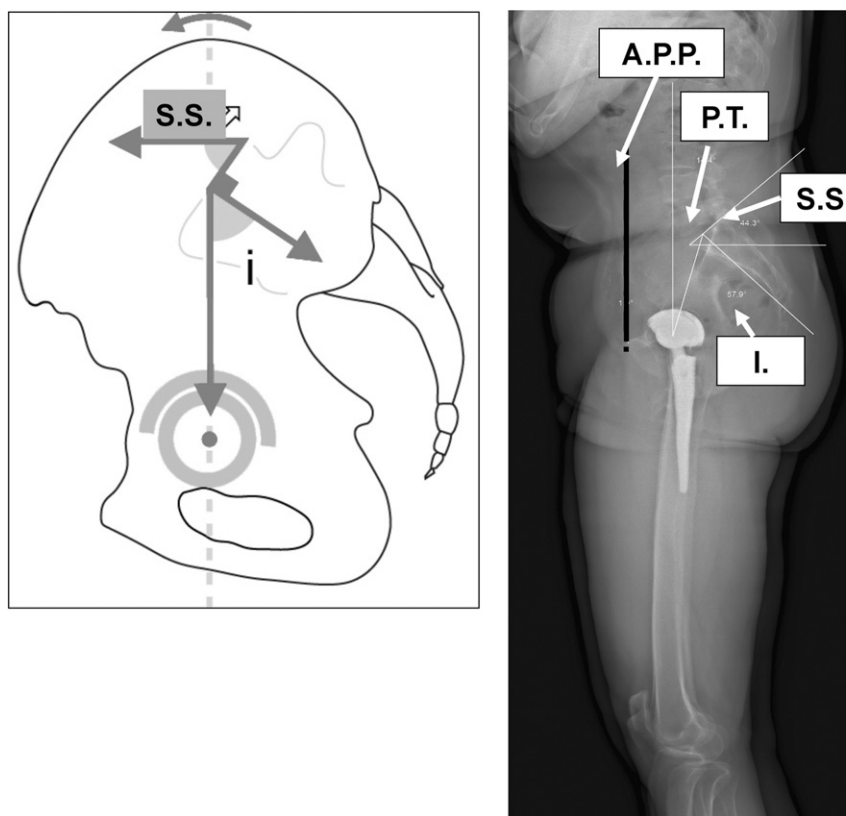


Figure 3 Standing posture involves anterior tilt of the pelvis: the superior sacral endplate on lateral view determines sacral slope (SS: about 40° to horizontal); the anterior pelvic plane (APP) or Lewinnek's plane is considered vertical.

who focus exclusively on the pelvis as bone reference in implantation planning, peroperative adjustment and failure analysis. The AP pelvis view is the gold standard, with lateral views of the pelvic region being little used. Influenced by the classic anatomic culture of transverse slices, CT is considered the reference method of "horizontal" hip-joint assessment [6].

Analysis of sagittal trunk balance, however, cannot be limited to the standing posture. The sitting posture also brings into play adaptation mechanisms governed by the pelvic incidence angle, modifying sacral slope and pelvic tilt. As it is not explored by conventional imaging, the sitting posture has been neglected, despite being critical in hip replacement and for lumbar arthrodesis or disc replacement.

The present study draws attention to a more global vision of the role of the pelvic and subpelvic region in the sagittal balance of the trunk. The analysis, based on EOS® imaging and a novel view of conventional imaging, sheds new light on certain aspects of hip and spine pathology as part of a functional entity as such.

Fundamental principles: postural variations of the lumbar-pelvic reference in the sagittal plane

Analysis of series of "normal" subjects identified the spino-pelvic criteria of ergonomic sagittal balance in the standing

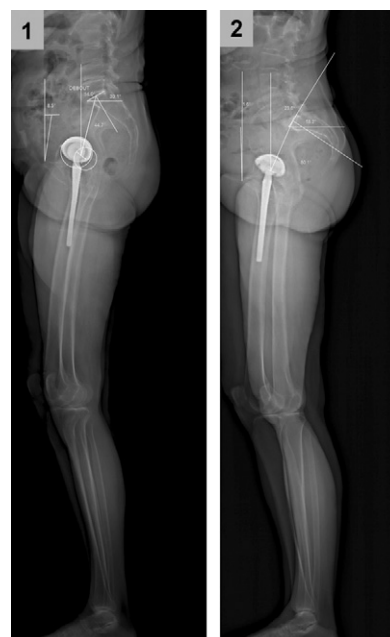

Figure 4 Case 1: in some subjects, sacral slope is lower in the standing position: the sacrum appears more vertical (posterior pelvic tilt, pelvic "extension" or pelvic "retroversion"). This may be associated with reduced pelvic incidence angle; case 2: in some subjects, sacral slope is higher in the standing position (anterior pelvic tilt, pelvic "flexion" or pelvic "anteversion"). This is often associated with elevated pelvic incidence angle.

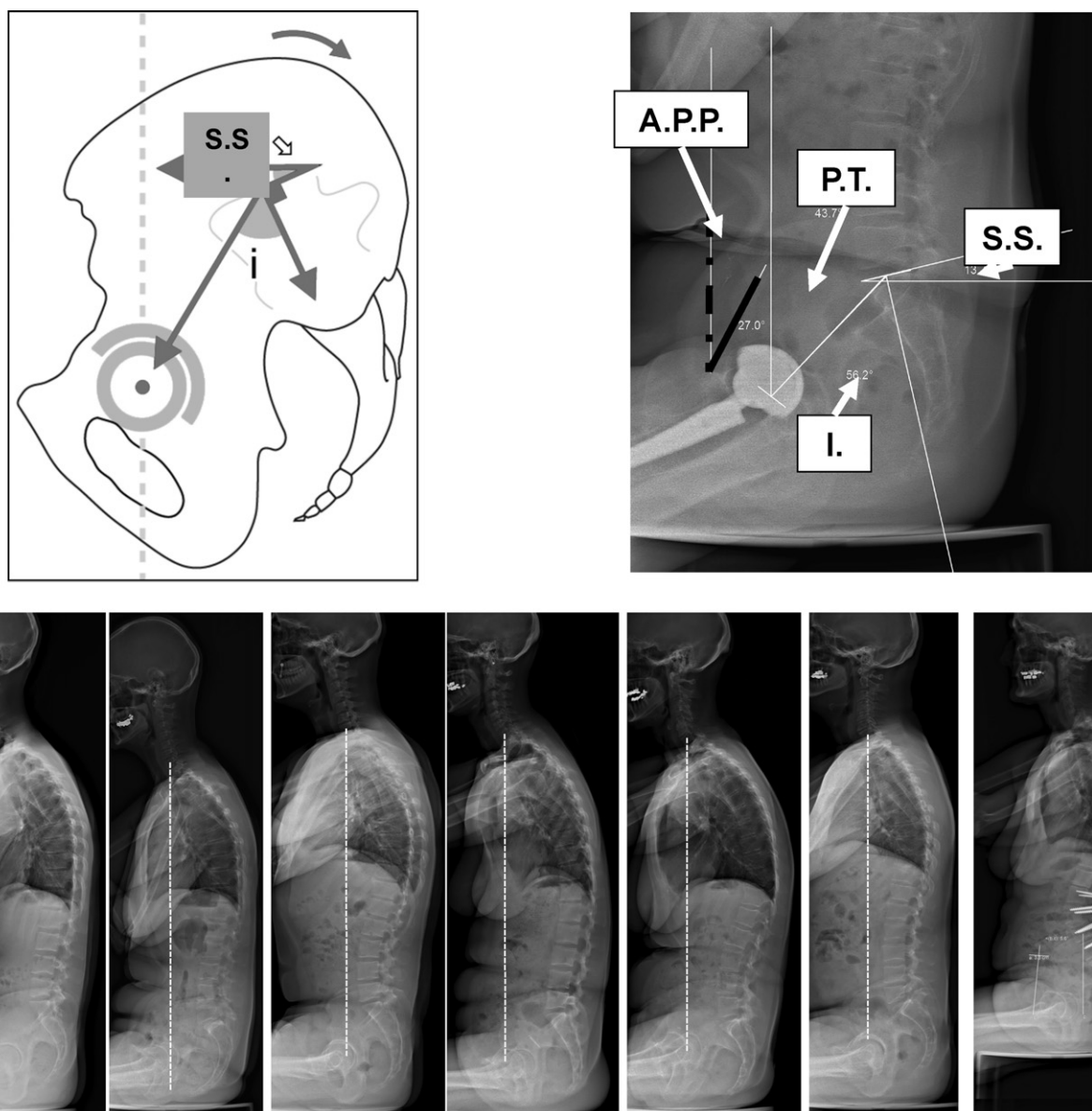


Figure 5 In the sitting posture, the pelvis tilts backward and sacral slope is reduced, with about 20° difference between standing and sitting. The center of C7 projects on the femoral heads. Vertebral arthrodesis prevents lumbar spine adaptation in the sitting position, as the associated reduction in lordosis is no longer possible. The patient sits as if standing.

position, although not all studies used the same assessment criteria [4,8,9].

Sagittal balance in upright stance is considered normal or “neutral” when the vertical plumb-line from the center of the C7 vertebra projects to or near to the posterosuperior angle of the first sacral body, S1 [7].

More precisely, the vertical through C7 projects at less than 2.5 cm from the posterosuperior angle of S1 in two-thirds of asymptomatic adults, according to Jackson and McManus [10].

The lumbar-pelvic-femoral complex constitutes a functional entity as such, Dubousset described the pelvis as the “pelvic vertebra”, an intercalary bone. The hip joints, like the lumbar-sacral junction, are involved adapting to the change in position between standing and sitting posture.

The individual coherence of the spino-pelvic configuration has been highlighted in studies [8,11–14] of spinal and pelvic parameters on lateral standing X-ray.

Each individual subject is characterized by a set “morphological” parameter: the “pelvic incidence angle”, which schematically corresponds to pelvic width, and thus to the pedestal on which the spine balances. This angle ($55^\circ \pm 10.6^\circ$) is measured on lateral views as the angle between the line perpendicular to the middle of the cranial sacral endplate and the line joining the middle of this endplate to the center of the bicoxofemoral axis [4].

Adapting the other “functional” factors (pelvic tilt and the spinal parameters of sacral slope, lumbar lordosis and thoracic kyphosis) enables the center of gravity of

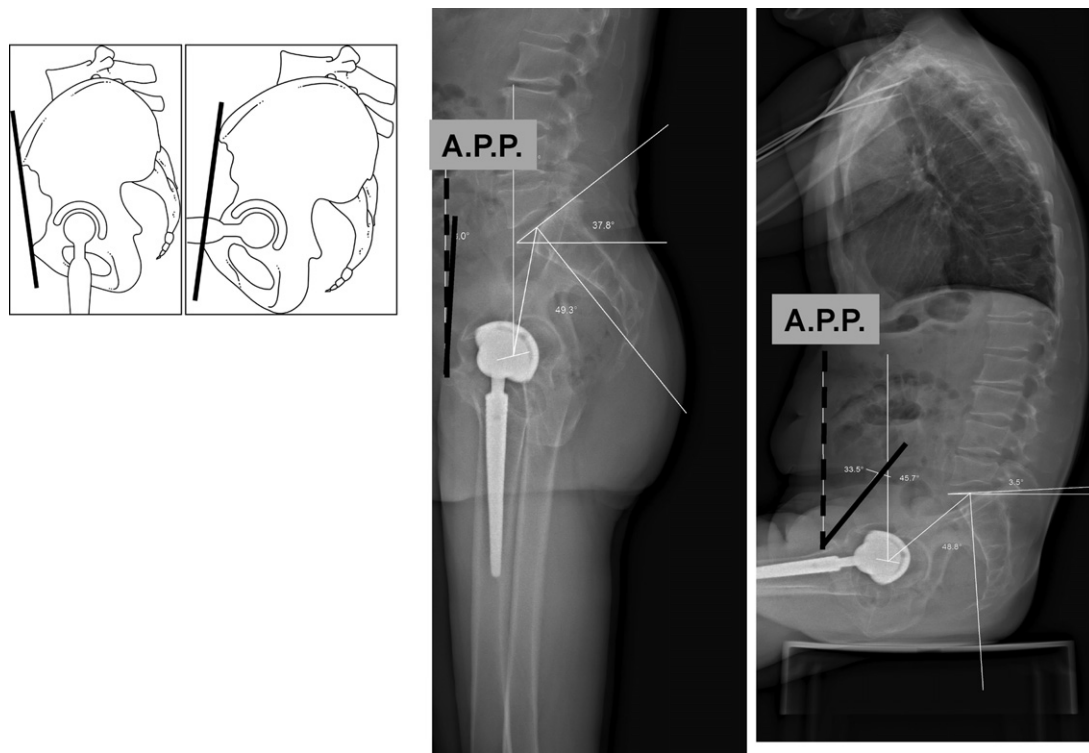


Figure 6 The pelvis turns around the bicoxofemoral axis. Anterior tilt is related to the standing position. Posterior tilt (associated with straightening of lumbar lordosis) is seen in the sitting position. The orientation of the anterior pelvic plane (APP) is greatly modified.

the body-segment supported by the femoral heads to be positioned specifically with respect to the pelvic pedestal so as to maintain balance with minimal muscular effort [13,15,16].

Sacral slope (SS) is the angle subtended by the horizontal and the superior S1 endplate; pelvic tilt (PT) is the angle between the vertical and the line joining the middle of the sacral endplate and the center of the bicoxofemoral axis (the line between the geometric center of both femoral heads).

Pelvic incidence (I: a morphologic parameter) is geometrically related to sacral slope and pelvic tilt (SS and PT: positional parameters) as $I = SS + PT$ (Fig. 1) [13].

A set of significant correlations between the anatomic parameter of pelvic incidence and the functional parameters of sacral slope and lordosis has been described: elevated pelvic incidence correlates with elevated sacral slope and lordosis, and low pelvic incidence with low sacral slope and lordosis.

Understanding this geometrical compromise is important in analyzing anterior trunk imbalance and subpelvic compensation (Fig. 2).

The pelvis displays rotational movement around the bicoxofemoral axis, leading to tilt with anterior flexion ("pelvic anteversion"), with the cranial part of the pelvic block tilting forward or posterior extension ("pelvic retroversion") with the trunk tilting backward. The degree of tilt can be assessed from the angular variation in sacral slope and pelvic tilt.

Upright stance

The standing position involves a forward tilt of the pelvic block (Fig. 3). The superior S1 endplate on lateral view subtends a sacral slope angle with the horizontal of about $40.6^\circ (\pm 8.5)$ [17,18]. For a given incidence angle, the pelvic tilt ($11.4^\circ \pm 5.9$) can be assessed as $PT = I - SS$.

The degree of posterior pelvic tilt available to compensate anterior sagittal imbalance depends on the pelvic incidence: the greater the latter, the greater the theoretic adaptability of posterior pelvic tilt; conversely, subjects with small pelvic incidence have a lower potential for compensation.

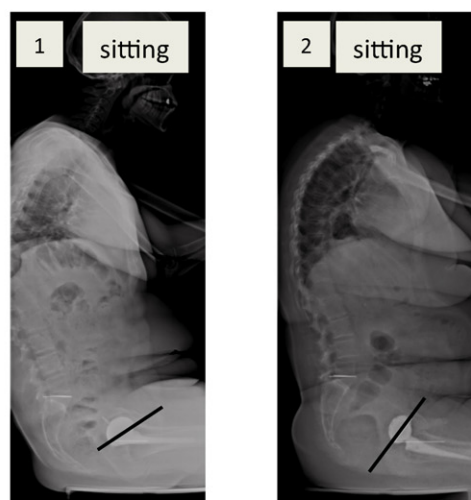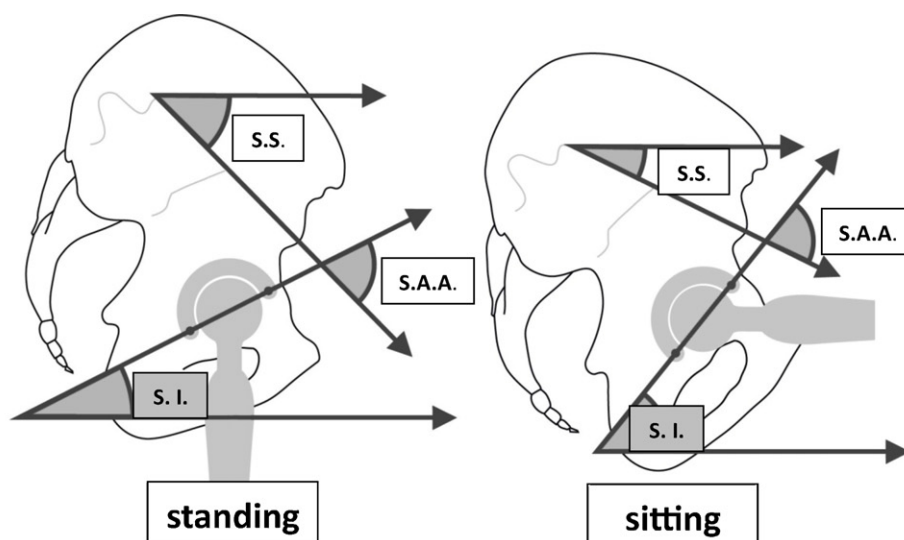
When compensatory phenomena reach their limit, the hip joints have no further possibilities of extension and encounter a posterior block – at which point, the patient will bend his or her knees.

In some subjects, sacral slope is low in the standing posture: this is called "posterior pelvic tilt", and the sacrum appears unusually vertical on lateral views.

In other subjects, the sacrum is very horizontal in the standing posture, with a slope often considerably exceeding 50° : this is called "anterior pelvic tilt" (Fig. 4).

Sitting posture

The situation here is the opposite (Fig. 5). The pelvis tilts backward during the transition to the sitting posture. Sacral slope diminishes, to a mean 20° to 25° [17,19], sometimes as low as 5° to 10° or even negative. Depending on the



the influence of the S.A.A. adjustment for the hip function in sitting position :

- low sagittal inclination angle can induce anterior impingement (case 1)
- high sagittal inclination angle prevents anterior impingement (case 2)

Figure 7 Interdependence between acetabular tilt or sagittal inclination (SI) and sacral slope (SS) is expressed by the sacro-acetabular angle (SAA). In THA, this angle is set by the surgeon. If it is too narrow, the acetabulum appears too “horizontal” on lateral view, which may induce impingement in the sitting posture.

height of the seat, individual morphology and associated spinal pathology, a variable degree of posterior pelvic tilt is observed, with the sacrum more or less vertical. As in the upright posture, pelvic incidence (I) is geometrically related to PT and SS as $I = SS + PT$ [1]. The difference in sacral slope between the standing and sitting positions corresponds to the available flexion of the lumbar-sacral junction (available extrinsic pelvic flexion), as distinct from potential hip-joint flexion (available intrinsic pelvic flexion).

Transition from standing to sitting position

The process of sitting down considerably modifies the orientation of the anterior pelvic plane, which is currently the

reference for adjusting total hip arthroplasty (THA) cups [20]. Lewinnek’s plane (anterior pelvic plane) is assessed in dorsal decubitus from the morphologic data collected for THA planning. This information is to be extrapolated with caution, as Lewinnek’s plane is not necessarily vertical in the standing position, and tilt is very variable in the sitting posture [21]. For a mean 3° standing, the mean sitting value is 17.5° [17] (Fig. 6).

In the supine position

When the lower limbs are in extension in the supine position, sacral slope is often greater than in the standing position

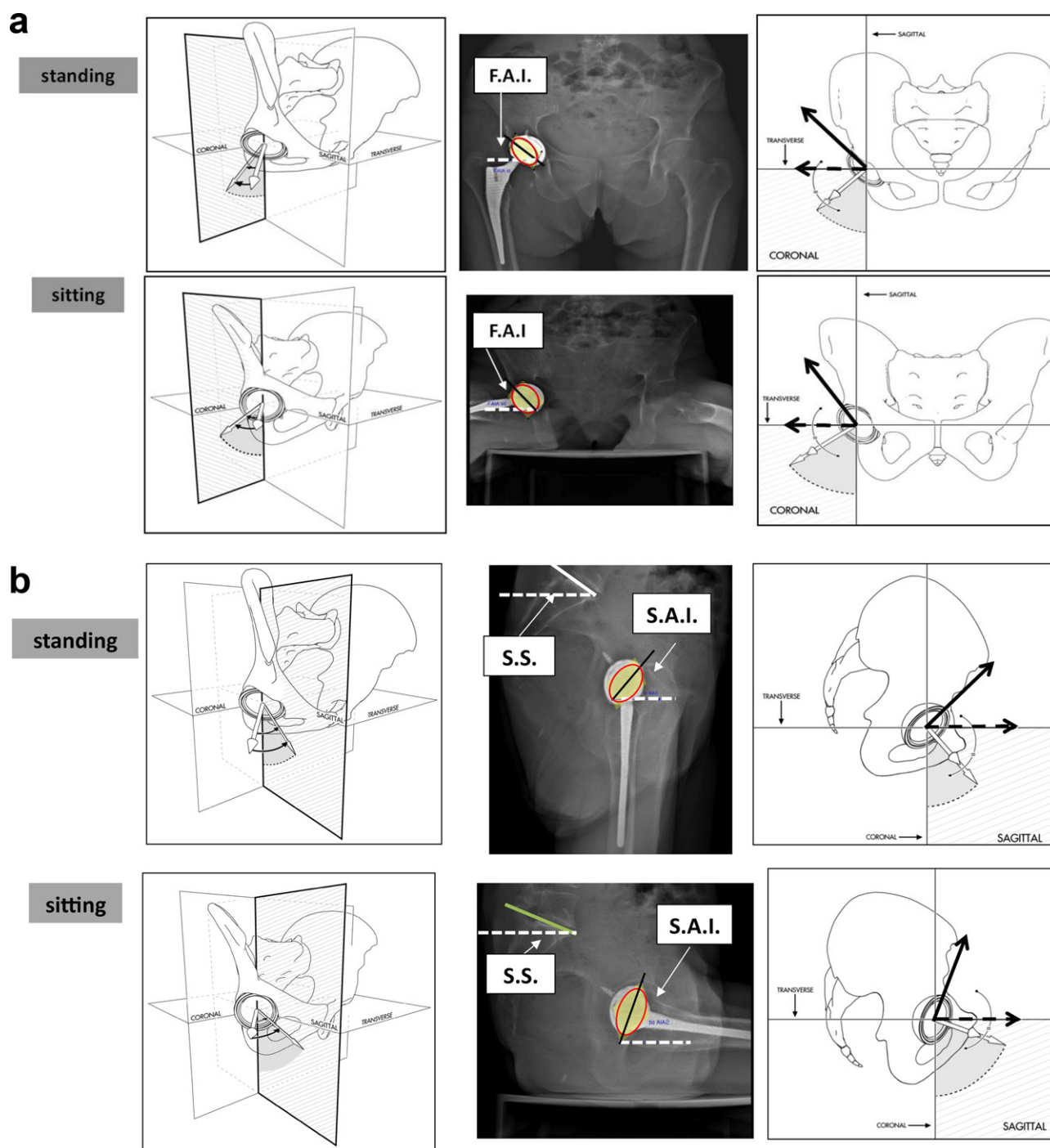


Figure 8 a and b: frontal acetabular inclination (FAI) is defined by Murray as the angle between the patient's longitudinal axis and the axis of the cup projected on the coronal plane, and is equal to the angle between the horizontal and the long axis of the acetabular ellipse on AP standing and sitting views. Sagittal acetabular inclination (SAI) is defined as the angle between the patient's longitudinal axis and the axis of the cup projected on the sagittal plane, and is equal to the angle between the horizontal and the long axis of the acetabular ellipse on lateral standing and sitting views. On both lateral and AP views, the acetabular THA component appears more vertical in the sitting than the standing position.

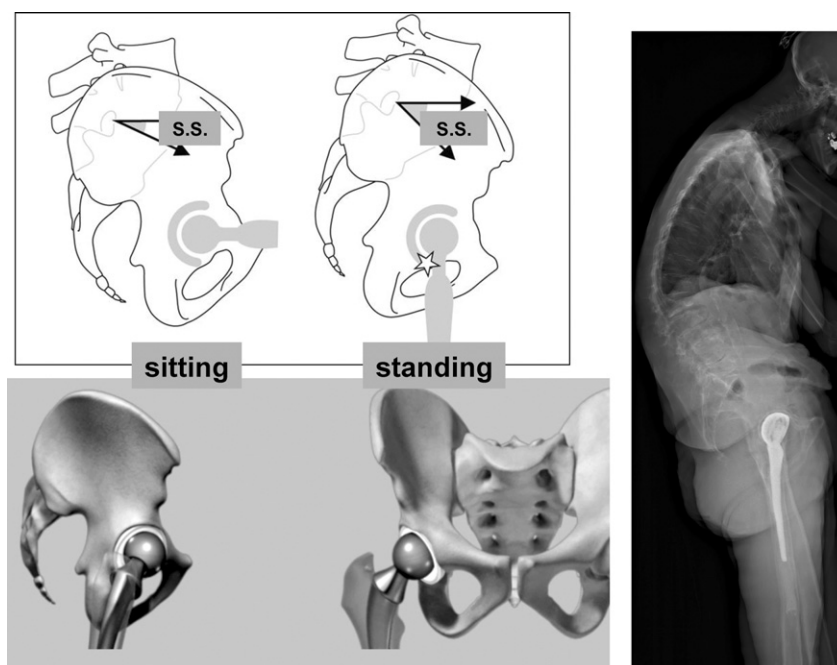


Figure 9 Excessive posterior pelvic tilt often corresponds to sagittal imbalance of the trunk in the standing position. In this example, there is posterior impingement with the THA, although the cup is correctly positioned with respect to the pelvic bone reference; the patient presented iterative anterior subluxation in the standing position, despite a posterior approach for THA implantation.

[19,22]. This extra pelvic tilt may be poorly tolerated if the spine is stiff or deformed, as dorsal decubitus aggravates the lumbar lordosis. Limited available hip extension or posterior osteoarthritis may make strict decubitus unbearable without a compromise by means of slight hip-joint flexion.

Influence of sagittal posture on functional frontal and sagittal acetabular orientation

Anatomic fundamentals

The interdependence between acetabular sagittal tilt and sacral slope is clear on lateral radiographs of the lumbar-sacral junction in sitting and standing posture.

It is expressed by the sacro-acetabular angle (SAA), defined as the tangent of the sacral endplate and the axis of the acetabular ellipse on lateral view (the latter defining the angle of sagittal acetabular inclination to the horizontal). The SAA is fixed and specific to each acetabulum, and is empirically applied by the surgeon to the acetabular component in THA [22] (Fig. 7).

In the standing position, sacral slope is high and acetabular inclination low. Conversely, in the sitting position, sacral slope decreases and acetabular inclination increases. On both lateral and AP views, the acetabular THA component is more vertical in the sitting than in the standing position (Fig. 8) [17,19]. These variations in acetabular tilt contribute to the change in anterior opening of the acetabulum and thus in the orientation of the functional mobility cone of the hip joint [19].

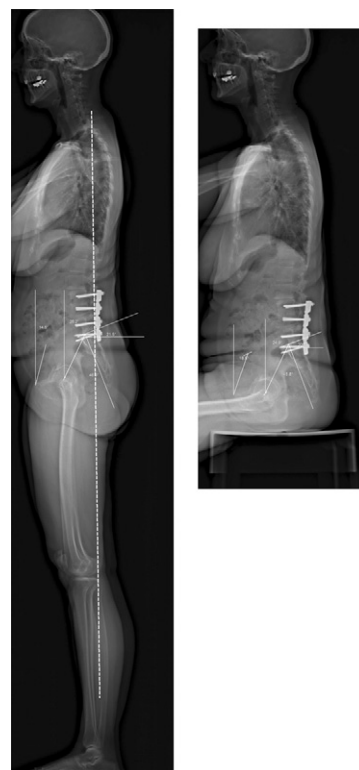

Figure 10 Absence of variation in pelvic tilt between standing and sitting positions abolishes adaptation for the anterior acetabular opening. In this example, the pelvis is fixed by lumbar arthrodesis imposing posterior pelvic tilt ("vertical" sacrum) in the standing position; although suitable for the sitting position, this may induce posterior impingement with the hips in the standing position.

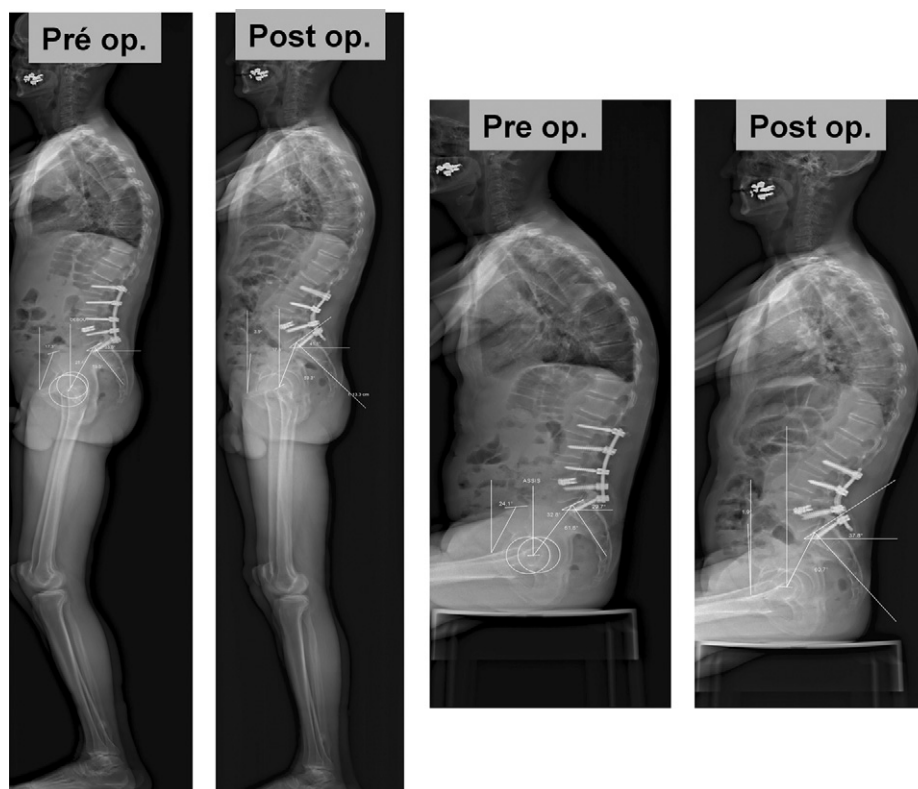


Figure 11 Correcting sagittal imbalance improves hip posture and reduces pain induced by posterior impingement. The sitting posture is also improved.

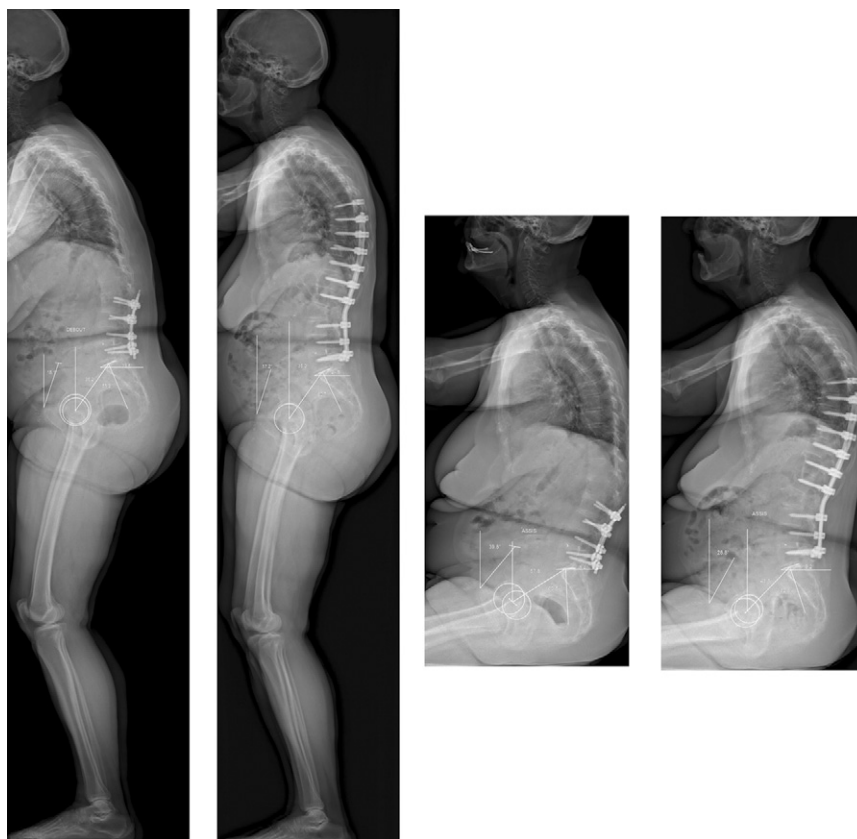


Figure 12 Partial correction of sagittal imbalance improves overall posture; but, in this case, hip-joint compensation persists postoperatively in the standing position. The 58° angle of incidence should require greater lordosis.

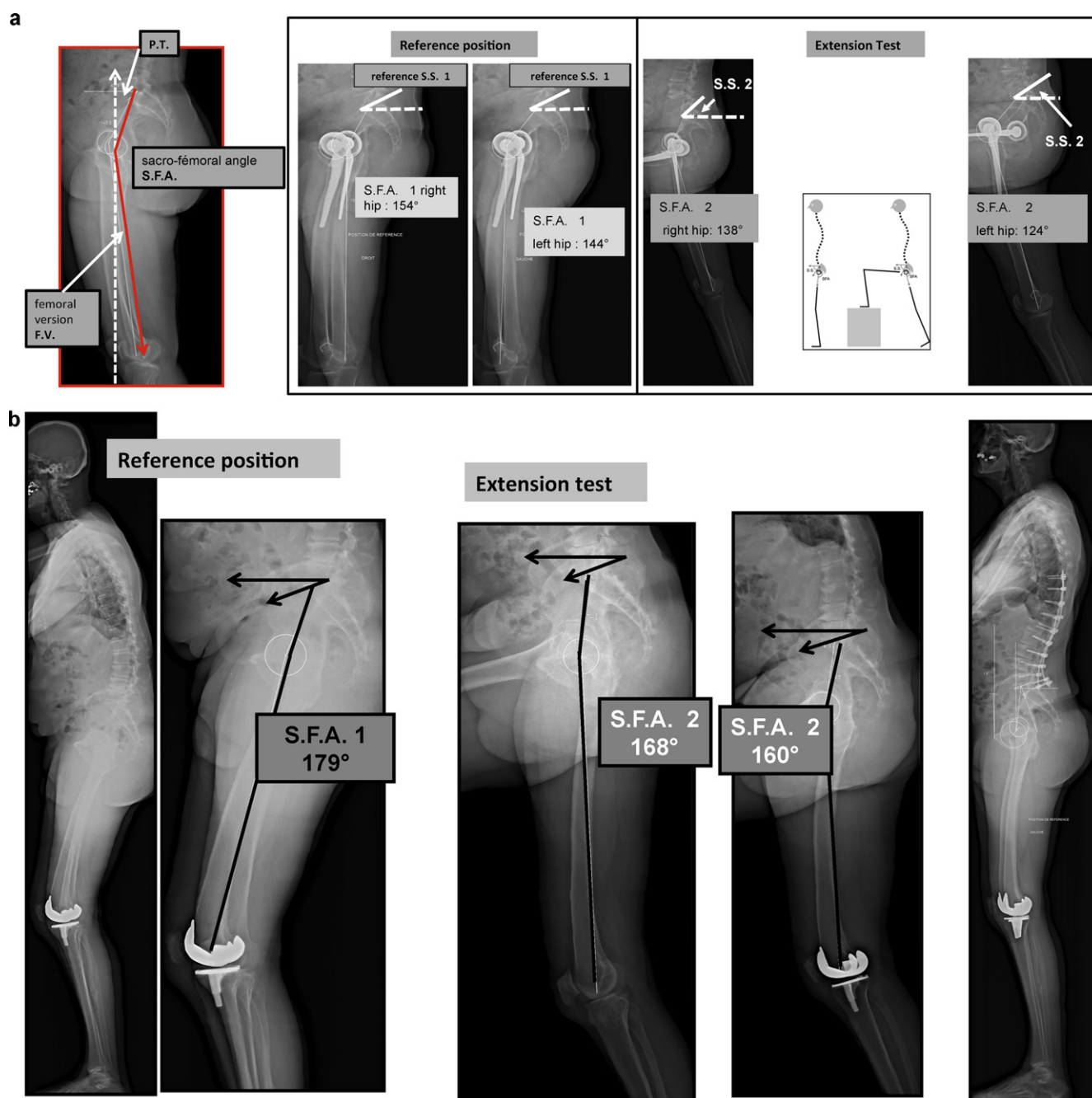


Figure 13 a: measure of available extension: the lower limbs are alternately placed on a calibrated step. The adaptation capacity of the lumbosacral hinge is expressed as the variation in sacral slope (increased sacral slope induces a reserve of available "extrinsic" extension). The available extension of either hip ("intrinsic reserve") is expressed as the reduction in sacro-femoral angle and change in femoral version. The sacro-femoral angle is determined by the intersection of two lines: the line between the center of the sacral endplate and the midpoint of the line through the centers of the two femoral heads; and the line between the midpoint of the line through the centers of the two femoral heads and the top of Blumensaat's line in the knee. Femoral version is determined by the angle subtended by the vertical and the lateral femoral axis (defined by the line between the center of the femoral head and the top of Blumensaat's line). In this example, available extension is 16° in the right hip and 20° in the left; b: interest of measuring available extension: this patient requires spinal fixation with correction of sagittal balance – will the subpelvic region be able to tolerate the new posture? The reference position shows a sacro-femoral angle (SFA) of 179°. Dynamic tests show that this can reduce to 160°. Spinal correction was able to be performed with success.

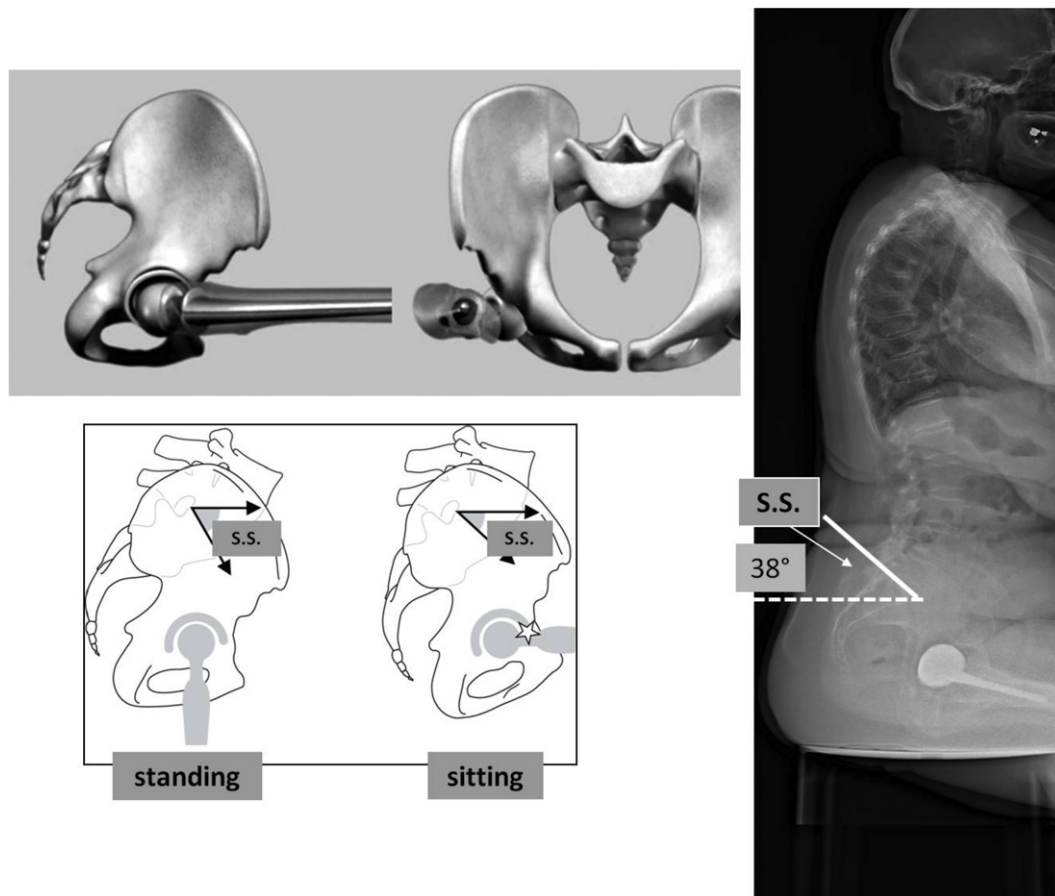


Figure 14 Excessive anterior pelvic tilt in the sitting position may induce anterior impingement; here, complete hip flexion is lacking (available hip flexion deficit); in the standing position, there is no impingement.

These changes in acetabular orientation impact THA stability and medium to long-term tribology [23], whence the importance of a specific study of the sitting posture as part of defective THA assessment and for preoperative screening for at-risk subjects.

The absence of variation in pelvic tilt between the standing and sitting positions represents a loss of adaptability for anterior acetabular opening: some subjects are effectively “sitting” in their standing posture, which may induce posterior impingement.

Atypic posture may induce disorder

Excessive posterior tilt of the pelvis is often associated with postural imbalance to compensate for a forward tilt of the trunk as a whole, especially with spinal aging. This postural adaptation verticalizes the acetabulum frontally and laterally, putting the hips in “upright hyperextension”. This at-risk configuration may be aggravated by poorly adjusted lumbar arthrodesis [24].

This strain on available hip extension can lead to posterior impingement. A typical example is posterior impingement in THA in the standing position, even when the acetabular component has been positioned perfectly with respect to the pelvic bone reference (Fig. 9).

In such cases, the orientation of the acetabular component is impaired by excessive sagittal inclination and

anteversion (about 0.5° anteversion for 1° of pelvic rotation defect). This phenomenon may also explain late-onset THR instability in a context of overall sagittal disorder of the lumbar-pelvic-femoral complex, independently of joint surface wear [20].

The same situation may be encountered in a native hip in case of posterior pelvic tilt (due to trunk aging or defective spinal arthrodesis inducing osteoarthritis of the hip) [25,26] (Fig. 10). Correcting the postural imbalance may resolve the induced hip pathology if the sagittal defect is treated soon enough (Fig. 11), although local anatomic conditions do not always allow optimal correction, especially in case of elevated incidence angle, requiring an elevated angle of lordosis (Fig. 12).

These situations can be difficult to analyze, due to the interrelation of spine and hip pathology. Assessing hip extension capacity is essential for the analysis of decompensated or “borderline” sagittal imbalance (Fig. 13). The EOS® system assesses the sagittal orientation of the subpelvic region in the reference posture. Dynamic testing in standing position can individualize available extension related to the lumbar-sacral hinge (available extrinsic extension) and the available intrinsic extension of each hip joint.

Femoral version is defined, on lateral view, as the angle subtended by the vertical and the femoral axis between the center of the femoral head and the summit of Blumen-saat’s line. It is greater in case of flexion contracture of the

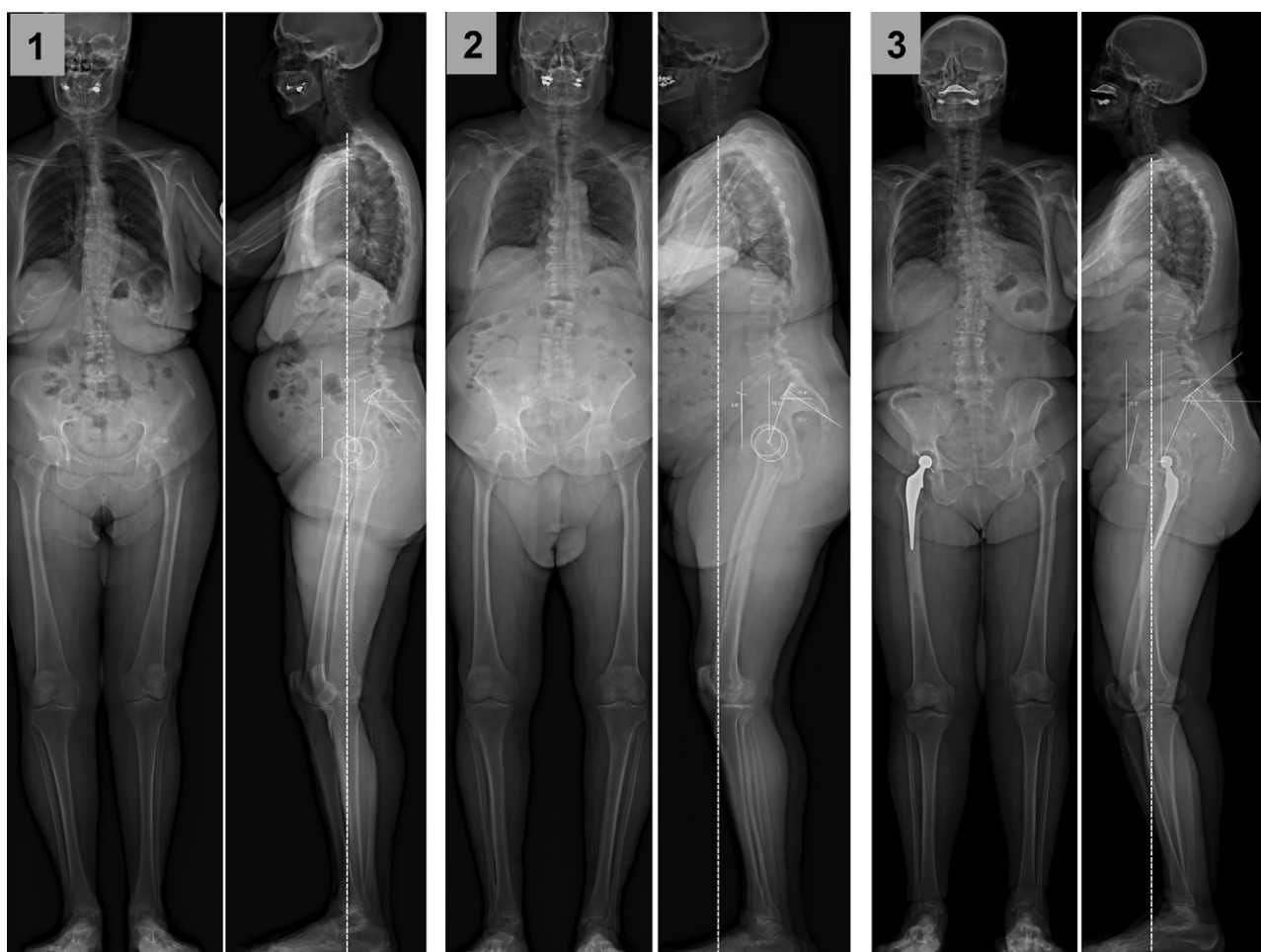


Figure 15 In case of hip flexion contracture secondary to hip-joint abnormality, there is a specific adaptation mechanism. Loss of extension capacity in the pathological hip induces anterior pelvic tilt when the patient attempts to stand up. When possible, the spine adapts by increasing lordosis, inducing lower back pain; case 1: left hip osteoarthritis; moderate residual imbalance, more or less compensated for by lumbar lordosis; case 2: clear imbalance with right hip osteoarthritis; insufficient lumbar compensation; case 3: complex imbalance, associating lengthening and medialization on right THA; adaptation by flexion contracture of the hip, not compensated by the lumbar spine.

hip in standing position, and can be negative in hyperextension of the hip. Femoral version correlates statistically with pelvic tilt: the greater the pelvic tilt, the greater the femoral version [1].

The adaptation capacity of the lumbar-sacral hinge is expressed as the variation in sacral slope: increased sacral slope induces a reserve of available extrinsic extension.

The extension capacity of each hip is assessed from the sacro-femoral angle, defined by the intersection between the femoral axis and the line between the centers of the two femoral heads and the middle of the sacral endplate. Reduction of this sacro-femoral angle during extension testing indicates available extension.

Excessive anterior pelvic tilt in the sitting posture may induce anterior impingement (Fig. 14). In such cases, the anterior tilt of the acetabulum in the standing posture is also excessive: the acetabulum is "horizontalized", frontally and laterally; it is as though the hips were permanently functioning in flexion when the subject is standing. Such a mechanism may be suspected in a native hip in case of

anterior impingement, especially in certain repeated movements in sports or at work.

In flexion contracture of the hip related to osteoarthritis, there is a specific adaptation mechanism. Loss of extension capacity in the affected hip induces anterior pelvic tilt when the subject tries to stand up; the spine, when possible, adapts by increasing the lumbar lordosis, leading to lower back pain. Frequently a single hip is implicated: the available extension test enables selective assessment (Fig. 15).

Atypic morphotype may induce disorder:

The pelvic incidence angle (I) is a morphologic parameter, determining spino-pelvic sagittal balance adaptation. It is related to the two functional parameters of pelvic tilt and sacral slope, as $I = SS + PT$:

- in elevated pelvic incidence, theoretic lumbar lordosis is elevated and sacral slope adaptation is potentially

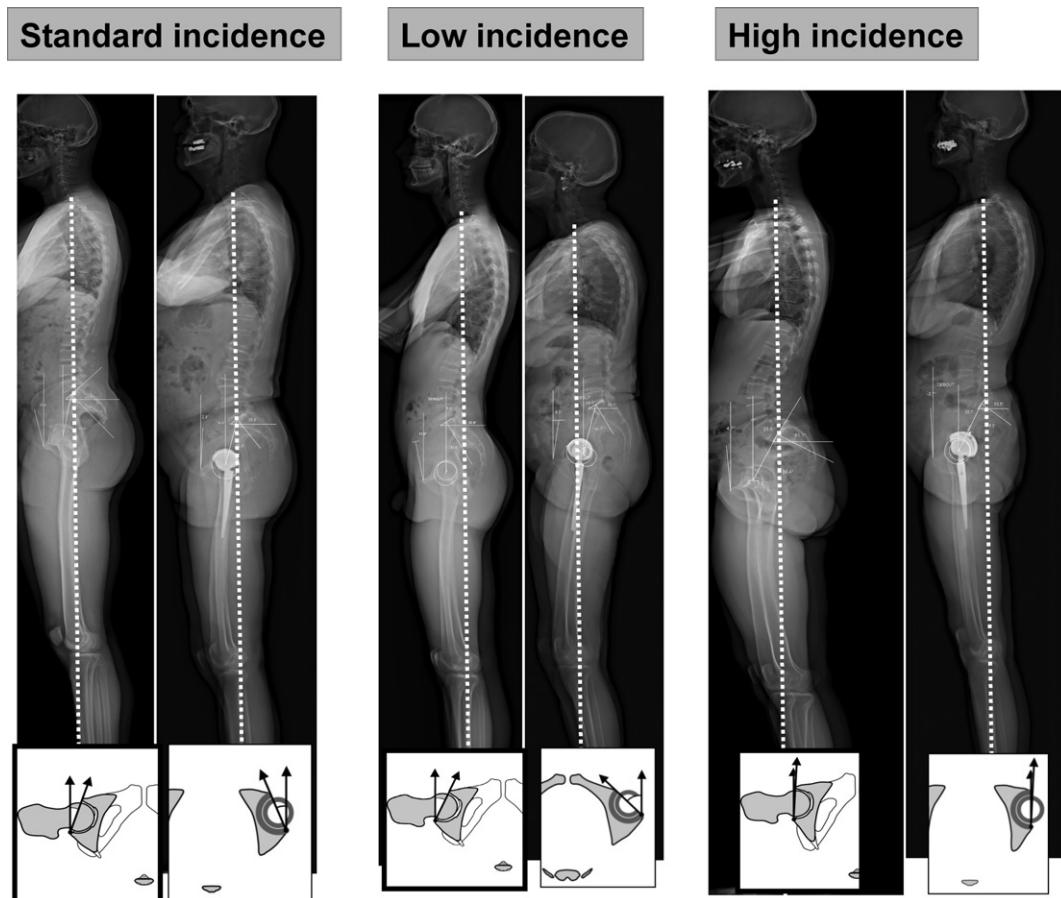


Figure 16 In standing position, subjects with a high angle of incidence, hip extension capacity is greater but the acetabulum is less open anteriorly.

greater. The femoral heads are projected forward with respect to the sacrum, and anterior acetabular opening is reduced with potential anterior impingement mainly in sitting position. Such subjects have a greater theoretic available hip-joint extension and hence better subpelvic adaptability. They are, on the other hand, more at risk in case of spinal arthrodesis, as adequate lordosis is difficult to obtain, with poor tolerance of a flat back;

- conversely, in low pelvic incidence, theoretic lumbar lordosis is lower and sacral slope adaptation more limited. The femoral heads are "embedded" under the sacrum, and the anterior acetabular opening is greater. Such subjects have less theoretic available hip-joint extension and less adaptability to sagittal imbalance (Fig. 16). Potential posterior impingement puts these patients at greater risk of dislocation or subluxation in upright stance following THA.

Impact of sagittal posture on transverse acetabular orientation: anatomic anteversion and functional anteversion

Classic data

The sagittal orientation of the pelvis determines the frontal and sagittal orientation of the acetabulum, with obvious

consequences for the cone of mobility of the hip, especially in case of THA. In THA, there is often degenerative spinal comorbidity, and postural imbalance is often characteristic. Acetabular anteversion is a key parameter in joint stability.

"Anatomic" or "morphologic" anteversion is a restrictive concept, inasmuch as it is assessed on a transverse plane perpendicular to the sagittal plane of the pelvic bone reference [6].

CT is supposed to measure anatomic anteversion directly on transverse slices. These may happen to be strictly perpendicular to the sagittal plane of the pelvic bone reference, but usually they are perpendicular to the examination table and do not correspond to the plane anatomists use since the subject's supine posture induces a certain degree of pelvic tilt [19]. Consequently, the angle measured in dorsal decubitus represents only "functional" anteversion, and corresponds to the acetabular opening angle in this position only [1].

To avoid imprecision due to the variable position of the subject in dorsal decubitus, anatomic acetabular anteversion on CT has been described using a plane perpendicular to the anterior pelvic plane (Lewinnek's plane).

In this plane, the slice analyzes the acetabulum in a constant orientation, independent of the patient's position; the measured anteversion corresponds exclusively to the pelvic

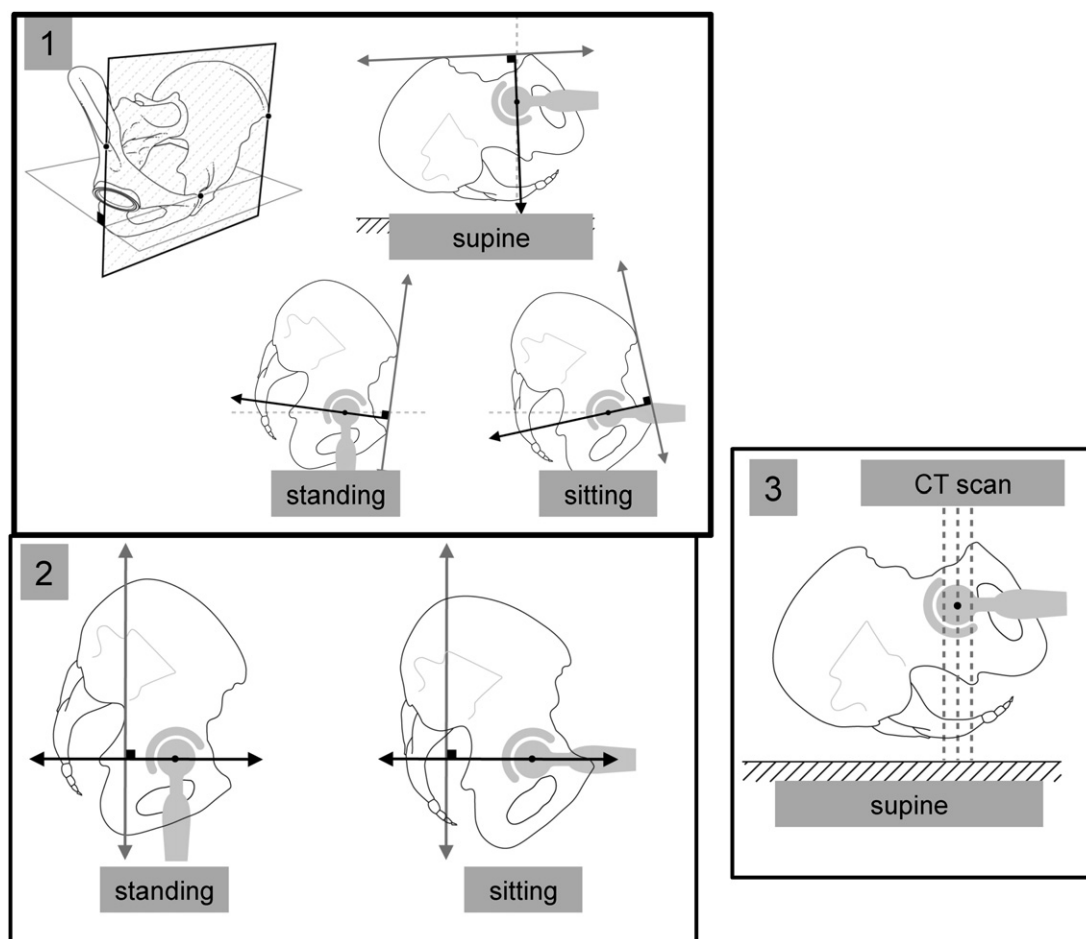


Figure 17 1: Measure of acetabular anteversion according to anterior pelvic plane: the reference is the pelvis and does not take account of its sagittal tilt. The slice always passes through the acetabulum in the same way. 2: Acetabular functional anteversion: measurements are made on the horizontal plane, whether in standing or sitting position, and thus, like with the EOS® system, take account of the pelvis's sagittal orientation. 3: The anteversion measured on CT is only a "snapshot".

bone landmarks, without taking account of variations due to the sagittal dynamics of the lumbar-pelvic complex: it is fixed, whatever the patient's position. Anteversion can also be measured on CT using a different transverse reference plane [22,23], passing through the superior endplate of the sacrum; the limitation, however, is the same: pelvic tilt and its impact on the acetabulum are not taken into account (Fig. 17).

Understanding lumbar-sacral posture and its impact on acetabular tilt shows that anteversion cannot be measured with an arbitrary CT slice orientation. This is an essential consideration for assessing real acetabular anteversion in THA in case of instability, especially when the lumbar-sacral hinge is stiff and/or atypically positioned [27].

The concept of functional anteversion

Functional acetabular anteversion measures the anterior acetabular opening angle, which varies with pelvic tilt.

It can be calculated from CT slices adjusted according to sacral slope as measured on a prior plain lateral radiograph:

the plane of these slices reconstructs the sacral tilt angle with the superior endplate of the sacrum, in standing, sitting and supine posture [23]. EOS® now provides easier access to such data, as measures are taken directly on the subject in the desired position.

In upright stance, transverse anteversion is less than in the sitting position, where the acetabulum opens forward completely, facilitating hip flexion and avoiding impingement with the femoral neck (Fig. 18). In the supine position with the lower limbs in extension, pelvic tilt is often greater than in the standing position, with greater lordosis and even less anteversion. In a series of 328 THAs, mean anteversion was 31.7° standing, 38.8° sitting and 24.2° supine [19].

Overall, "classic" CT measurements tend to underestimate it in the sitting position. Some subjects have a completely stiff lumbar-sacral junction, which significantly diminishes acetabular anteversion variation between the two positions. Such pelvic stiffening, with the pelvic block positioned in relative anterior or posterior tilt, can result in a situation of reproducible impingement.

Schematically, increased "pelvic anteversion" (or anterior pelvic flexion, or anterior pelvic tilt) induces relative

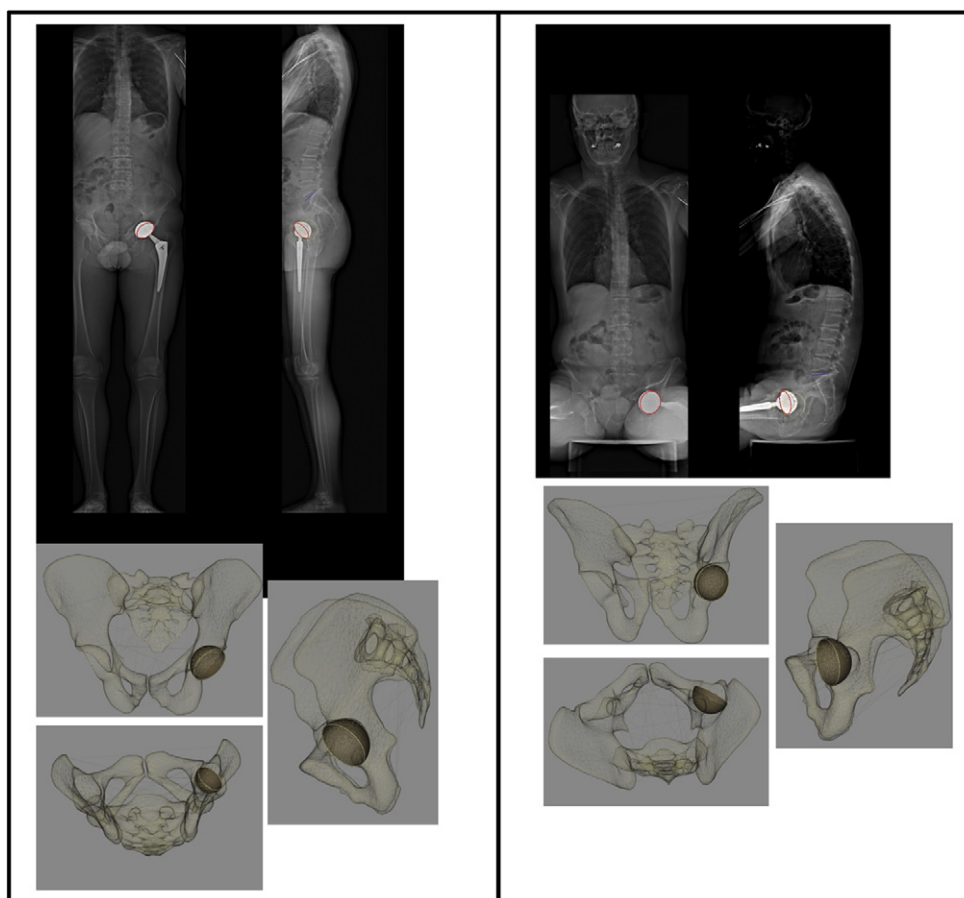


Figure 18 Changes in pelvic orientation with change in trunk posture significantly impact the native or prosthetic acetabulum (increased frontal and sagittal inclination visible on EOS® reconstructions). Anterior acetabular opening likewise increases in the sitting position.

acetabular retroversion. “Pelvic retroversion” (or pelvic extension or posterior pelvic tilt) increases acetabular anteversion. This phenomenon is documented in the literature for sagittal deformity in spondyloarthritis, maladjusted lumbar-sacral arthrodesis (flat back) and especially trunk aging [11,25,28,29] (Fig. 19).

Impact of pelvic and lumbar-pelvic block axial rotation

“Normal” pelvic posture is classically defined on AP images in a subject in a strictly anatomic posture, with both iliac wings projecting perfectly symmetrically with respect to the longitudinal axis of the trunk. The standard criteria of sagittal balance are described on lateral views with both femoral heads perfectly superimposed.

This ideal configuration is by no means systematically found in our experience of EOS® standing and sitting views of patients in their “normal position”: forward displacement of a semi-pelvis with corresponding backward displacement of the other half is frequent. On AP view, this is seen as an asymmetric projection of the iliac wings, with the

“anteriorized” wing appearing thinner than the other. On lateral view, the two femoral heads and two iliac wings are not superimposed. Such “twisting” is hard to quantify on plain radiograph due to the conical spread of the X-rays, giving a misleading aspect to the femoral head more remote from the source. It is, in contrast, well analyzed on EOS® imaging in the standing and sitting positions, with good 3D visualization of the position of the pelvis.

Spine surgeons are aware of the phenomena of vertebral rotation hampering analysis of lateral views. The “pelvic vertebra” concept suggests that pelvic rotation should be integrated in the analysis of trunk posture as a whole [30].

Pelvic rotation is extreme in scoliosis involving the pelvic vertebra (Fig. 20). The impact on acetabular orientation can be considerable, especially in case of THA, due to altered functional anteversion in both standing and sitting posture. 3D reconstruction clearly shows how the forward displacement of one half of the pelvis with respect to the other increases the “forward opening” of the hip joint (increased functional anteversion of the acetabulum). Conversely, the relative backward displacement of the other semi-pelvis induces acetabular functional retroversion on that side.

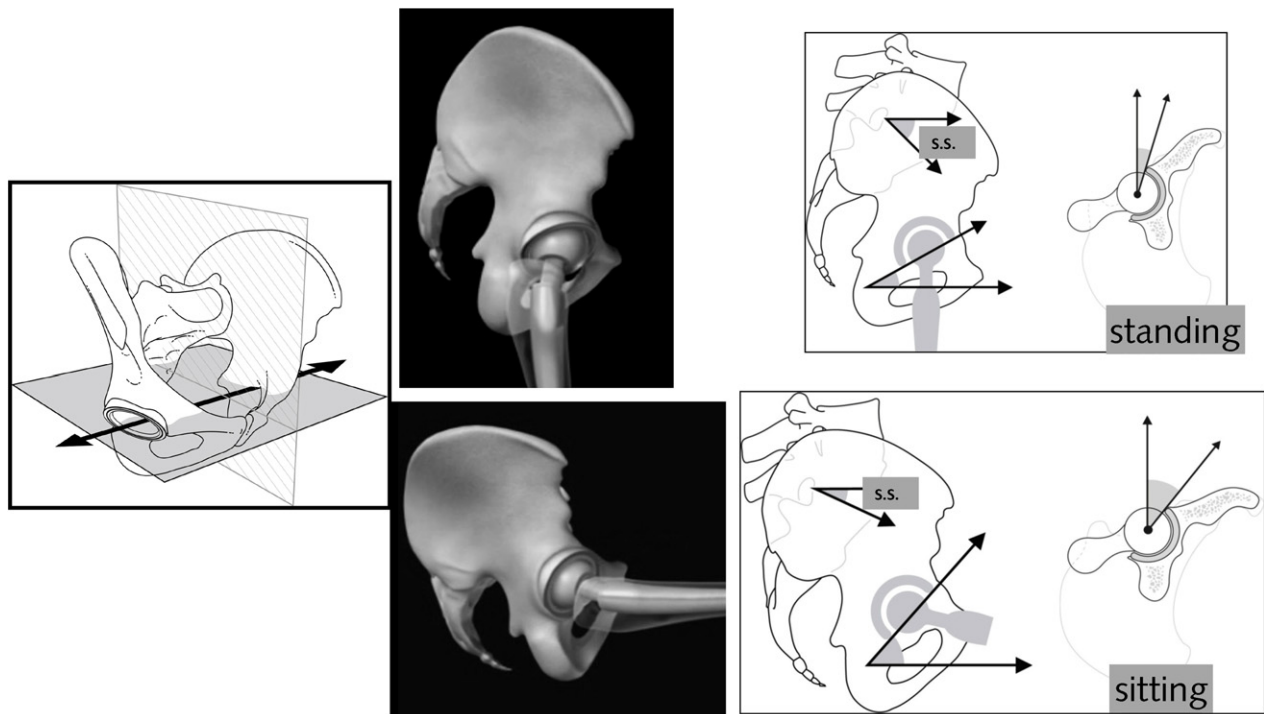


Figure 19 In the sitting position, acetabular sagittal inclination and functional anteversion are greater than in the standing position.

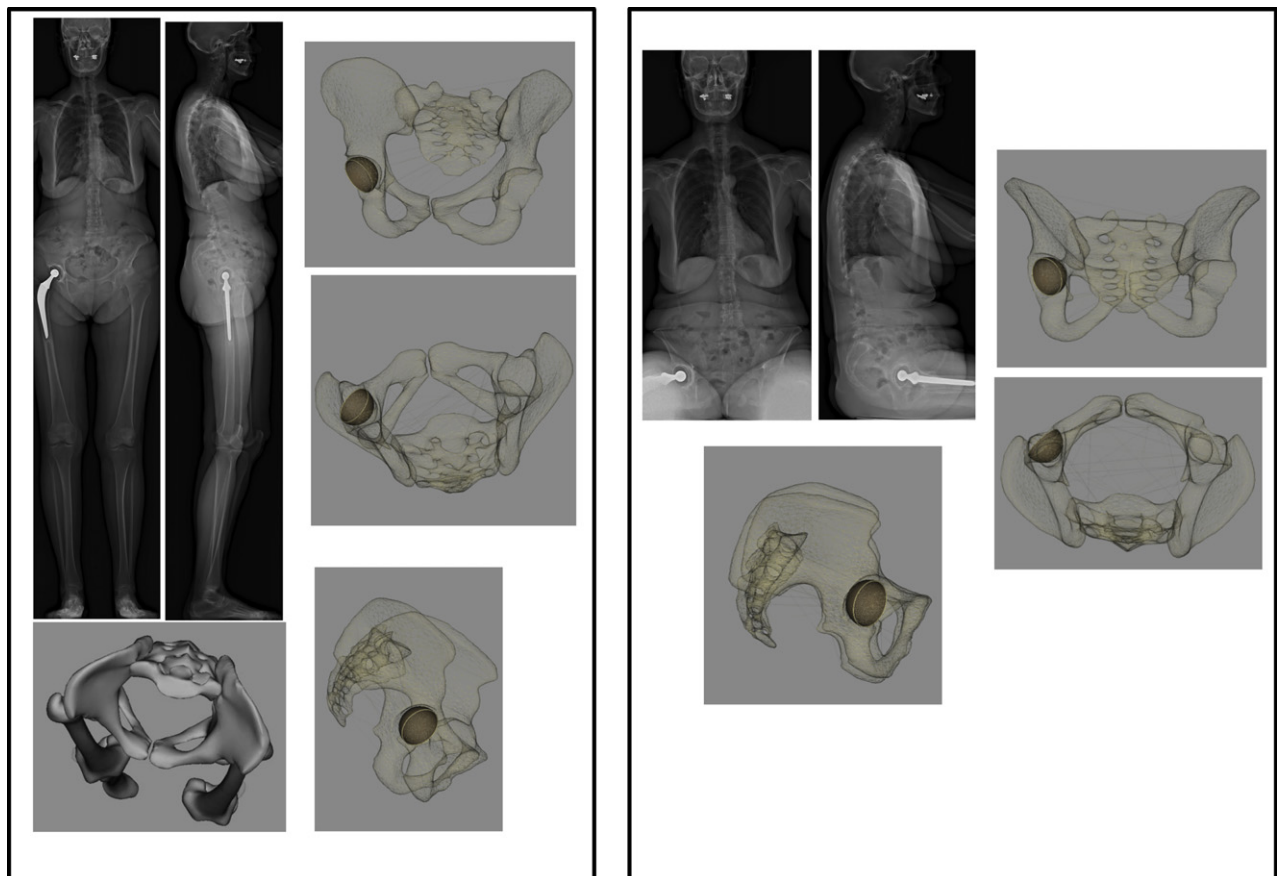


Figure 20 Strong pelvic rotation in standing position (left anterior iliac appearing thinner than the other), reduced in sitting position. Native EOS® images and 3D reconstructions show changed acetabular orientation on THA.

Conclusion

Global analysis of the pelvic and subpelvic regions in sagittal trunk balance sheds new light on the individual's adaptations to the imbalances induced by spinal or lower-limb pathology. Hip position is essential, and the interpretation of flexion contracture should take account of available extension. Views taken in the sitting position show wide variations in balance, and impose the concept of available flexion, which is essential to hip surgery and instability management.

A global view of the patient and of the spinal-pelvic-femoral complex in particular is essential both for spinal surgery specialists and for surgeons performing THA in elderly patients or patients with abnormal sagittal posture and/or severely impaired functional range of motion.

References

- [1] Lazennec J.Y, A. Brusson, M.A. Rousseau. Hip-Spine Relations: an innovative paradigm in THR Surgery. InTech 2012. Samo K. Fokter (Ed.), ISBN: 978-953-307-990-5(Recent Advances in Arthroplasty): p. Available from: <http://www.intechopen.com/articles/show/title/hip-spine-relations-an-innovative-paradigm-in-thr-surgery>
- [2] Kobayashi T, et al. A longitudinal study of congruent sagittal spinal alignment in an adult cohort. *Spine. Phila Pa 1976* 2004;29(6):671–6.
- [3] Chanplakorn P, et al. Lumbopelvic alignment on standing lateral radiograph of adult volunteers and the classification in the sagittal alignment of lumbar spine. *Eur Spine J* 2011;20(5):706–12.
- [4] Vialle R, et al. Radiographic analysis of the sagittal alignment and balance of the spine in asymptomatic subjects. *J Bone Joint Surg Am* 2005;87(2):260–7.
- [5] Jackson RP, McManus AC. Radiographic analysis of sagittal plane alignment and balance in standing volunteers and patients with low back pain matched for age, sex, and size. A prospective controlled clinical study. *Spine (Phila Pa 1976)* 1994;19(14):1611–8.
- [6] Murray DW. The definition and measurement of acetabular orientation. *J Bone Joint Surg Br* 1993;75(2):228–32.
- [7] Barrey C, et al. Sagittal balance disorders in severe degenerative spine. Can we identify the compensatory mechanisms? *Eur Spine J* 2011;20(Suppl. 5):626–33.
- [8] Jackson RP, Hales C. Congruent spinopelvic alignment on standing lateral radiographs of adult volunteers. *Spine (Phila Pa 1976)* 2000;25(21):2808–15.
- [9] Vaz G, et al. Sagittal morphology and equilibrium of pelvis and spine. *Eur Spine J* 2002;11(1):80–7.
- [10] Jackson RP, et al. Compensatory spinopelvic balance over the hip axis and better reliability in measuring lordosis to the pelvic radius on standing lateral radiographs of adult volunteers and patients. *Spine (Phila Pa 1976)* 1998;23(16):1750–67.
- [11] During J, et al. Toward standards for posture. Postural characteristics of the lower back system in normal and pathologic conditions. *Spine (Phila Pa 1976)* 1985;10(1):83–7.
- [12] Gelb DE, et al. An analysis of sagittal spinal alignment in 100 asymptomatic middle and older aged volunteers. *Spine (Phila Pa 1976)* 1995;20(12):1351–8.
- [13] Legaye J, et al. Pelvic incidence: a fundamental pelvic parameter for three-dimensional regulation of spinal sagittal curves. *Eur Spine J* 1998;7(2):99–103.
- [14] Guigui P, et al. Physiological value of pelvic and spinal parameters of sagittal balance: analysis of 250 healthy volunteers. *Rev Chir Orthop Reparatrice Appar Mot* 2003;89(6):496–506.
- [15] Duval-Beaupere G, Schmidt C, Cosson P. A barycentremetric study of the sagittal shape of spine and pelvis: the conditions required for an economic standing position. *Ann Biomed Eng* 1992;20(4):451–62.
- [16] Roussouly P, et al. Classification of the normal variation in the sagittal alignment of the human lumbar spine and pelvis in the standing position. *Spine (Phila Pa 1976)* 2005;30(3):346–53.
- [17] Lazennec JY, et al. Pelvis and total hip arthroplasty acetabular component orientations in sitting and standing positions: measurements reproducibility with EOS imaging system versus conventional radiographies. *Orthop Traumatol Surg Res* 2011;97(4):373–80.
- [18] Lazennec JY, et al. Sagittal alignment in lumbosacral fusion: relations between radiological parameters and pain. *Eur Spine J* 2000;9(1):47–55.
- [19] Lazennec JY, et al. Acetabular anteversion with CT in supine, simulated standing, and sitting positions in a THA patient population. *Clin Orthop Relat Res* 2011;469(4):1103–9.
- [20] Rousseau MA, et al. Optimization of total hip arthroplasty implantation: is the anterior pelvic plane concept valid? *J Arthroplasty* 2009;24(1):22–6.
- [21] Philippot R, et al. Pelvic balance in sagittal and Lewinnek reference planes in the standing, supine and sitting positions. *Orthop Traumatol Surg Res* 2009;95(1):70–6.
- [22] Lazennec JY, et al. Hip-spine relationship: a radio-anatomical study for optimization in acetabular cup positioning. *Surg Radiol Anat* 2004;26(2):136–44.
- [23] Lazennec JY, et al. Hip spine relationships: application to total hip arthroplasty. *Hip Int* 2007;17(Suppl. 5):S91–104.
- [24] Barrey C, et al. Sagittal balance of the pelvis-spine complex and lumbar degenerative diseases. A comparative study about 85 cases. *Eur Spine J* 2007;16(9):1459–67.
- [25] Itoi E. Roentgenographic analysis of posture in spinal osteoporotics. *Spine (Phila Pa 1976)* 1991;16(7):750–6.
- [26] Lafage V, et al. Pelvic tilt and truncal inclination: two key radiographic parameters in the setting of adults with spinal deformity. *Spine (Phila Pa 1976)* 2009;34(17):E599–606.
- [27] Lembeck B, et al. Pelvic tilt makes acetabular cup navigation inaccurate. *Acta Orthop* 2005;76(4):517–23.
- [28] Hammerberg EM, Wood KB. Sagittal profile of the elderly. *J Spinal Disord Tech* 2003;16(1):44–50.
- [29] Lazennec JY, et al. Surgery of the deformities in ankylosing spondylitis: our experience of lumbar osteotomies in 31 patients. *Eur Spine J* 1997;6(4):222–32.
- [30] Dubousset J, et al. EOS stereo-radiography system: whole-body simultaneous anteroposterior and lateral radiographs with very low radiation dose. *Rev Chir Orthop Reparatrice Appar Mot* 2007;93(6 Suppl.):141–3.