

—

Neodent® NeoArch®
Immediate Fixed
Full-Arch Solution
MANUAL

GRAND MORSE®

An elderly couple is shown in a close-up, smiling warmly. The man, on the left, has a full white beard and is wearing a blue button-down shirt over a white t-shirt. He is holding a black camera. The woman, on the right, has short, wavy grey hair and is wearing a light-colored blouse. They are outdoors, with a blurred background of green trees and a white railing. The overall mood is joyful and intimate.

*A SMILE FOR EVERYONE
NEODENT® NEOARCH® IMMEDIATE
FIXED FULL-ARCH SOLUTION.*

CONTENTS

INTRODUCTION	4
Treatment for full-arch rehabilitation with implants	4
NEOARCH® DESCRIPTION	6
The next level of Immediate fixed full-arch	6
Immediate solution in severe atrophic maxilla	8
PRE-OPERATIVE PLANNING	10
Anatomical Considerations	10
Digital 3D Planning	14
Implant Distribution and Prosthesis Definition	14
NEOARCH®	16
4 TO 8 REGULAR IMPLANTS	17
Helix GM® implants - design to achieve immediacy	17
Surgical procedures and implant placement	19
Bone Profile Use	21
Prosthetic options and procedures	22
LONG IMPLANTS	29
Helix GM® Long implants - solution for bicorticalization	29
Surgical procedures and implant placement	30
Prosthetic options and procedures	32
ZYGOMATIC IMPLANTS	33
Zygoma GM™ - implant for zygomatic anchorage	34
Surgical procedures and implant placement	35
Prosthetic options and procedures	37
COMPREHENSIVE RESTORATIVE SOLUTIONS: DESIGNED TO MEET THE PATIENTS' EXPECTATIONS	38
ZYGOMA GM™ AND HELIX GM® LONG IMPLANT PACKAGING	39
FOLLOW-UP	40
Cleaning and Care	40
REFERENCES	41

INTRODUCTION

Treatment for full-arch rehabilitation with implants

The complete loss of natural teeth affects the elderly in particular and is a globally prevalent tissue. Around the world, about 30% of people aged 65–74 have none of their natural teeth⁽¹⁾. Thus, regardless of any critical anatomical situation, patients expect for a proper functional and esthetical rehabilitation with a high level of comfort.

In order to address the requirements and expectations of patients seeking fast, convenient, and reliable solutions for a full dental replacement, Neodent® NeoArch® are fixed full-arch prosthetic and surgical solutions designed to implants installation according to the remain atrophic alveolar bone structure.

In order to provide proper implant distribution according to different residual bone heights, techniques can be used supporting a fixed full-arch rehabilitation. This manual outlines the Neodent® products for full-arch rehabilitations from 4 to 8 implants, long implants, or even zygomatic implants used in different clinical approaches.

Fixed Full-Arch Solutions

According to residual alveolar bone



4 to 8 regular implants

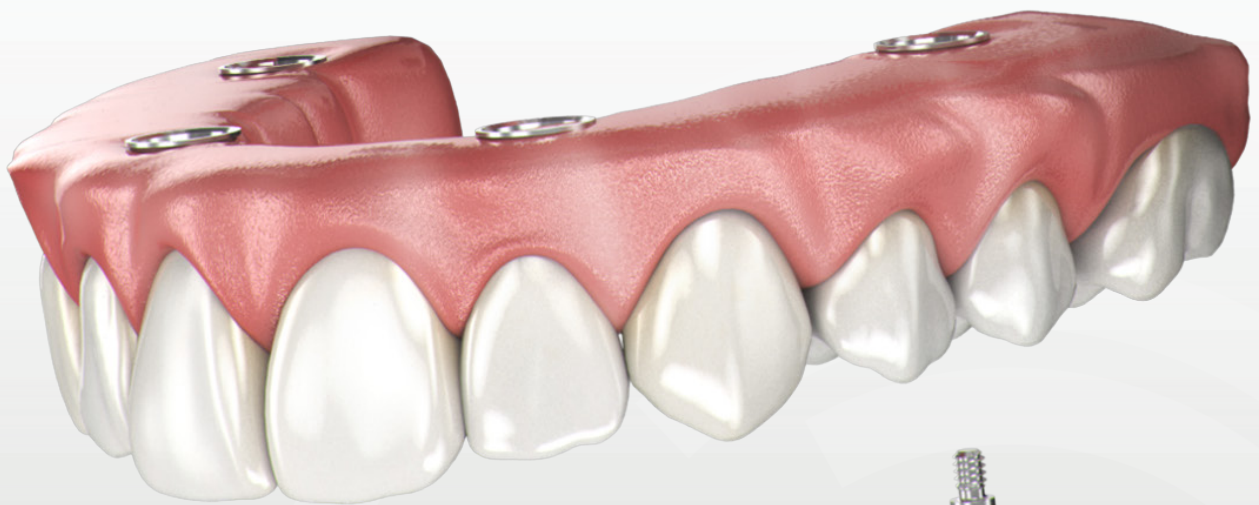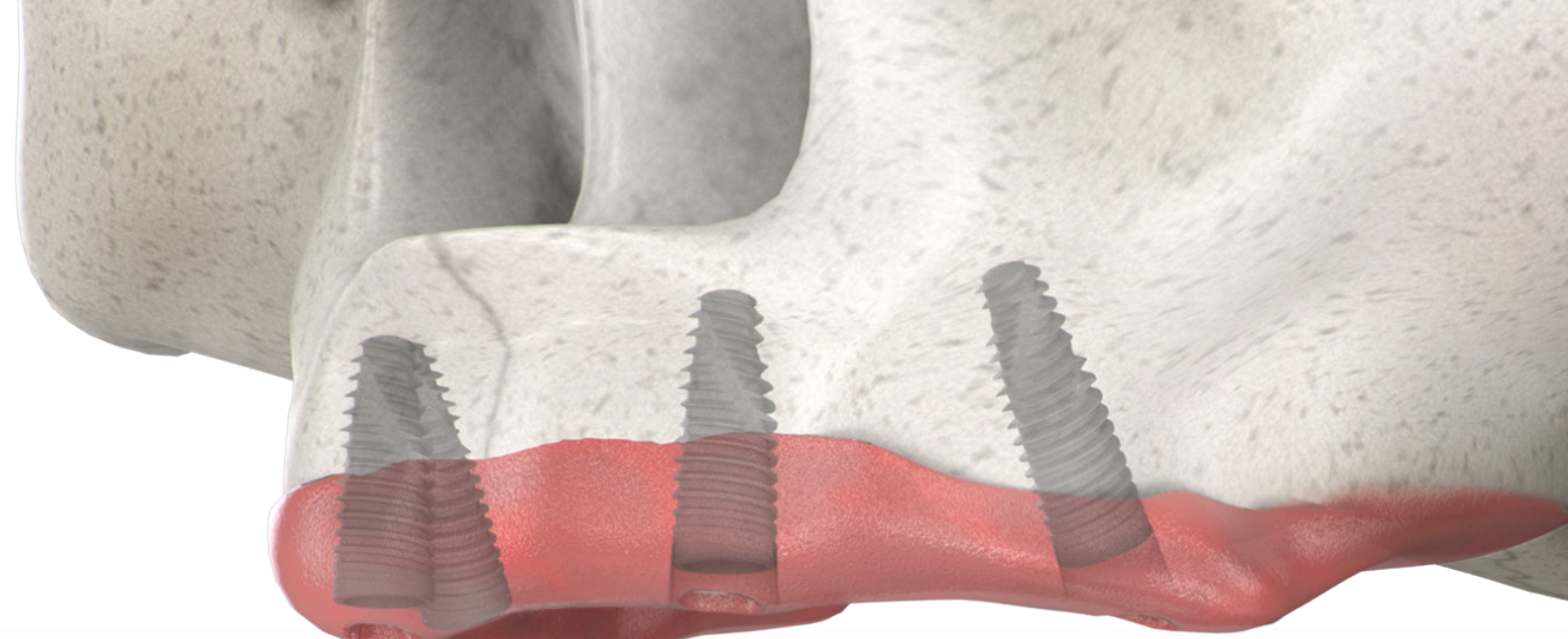


Long implants



Zygomatic implants

Fig 1. Different residual bone heights *versus* implant techniques.




NEOARCH® DESCRIPTION

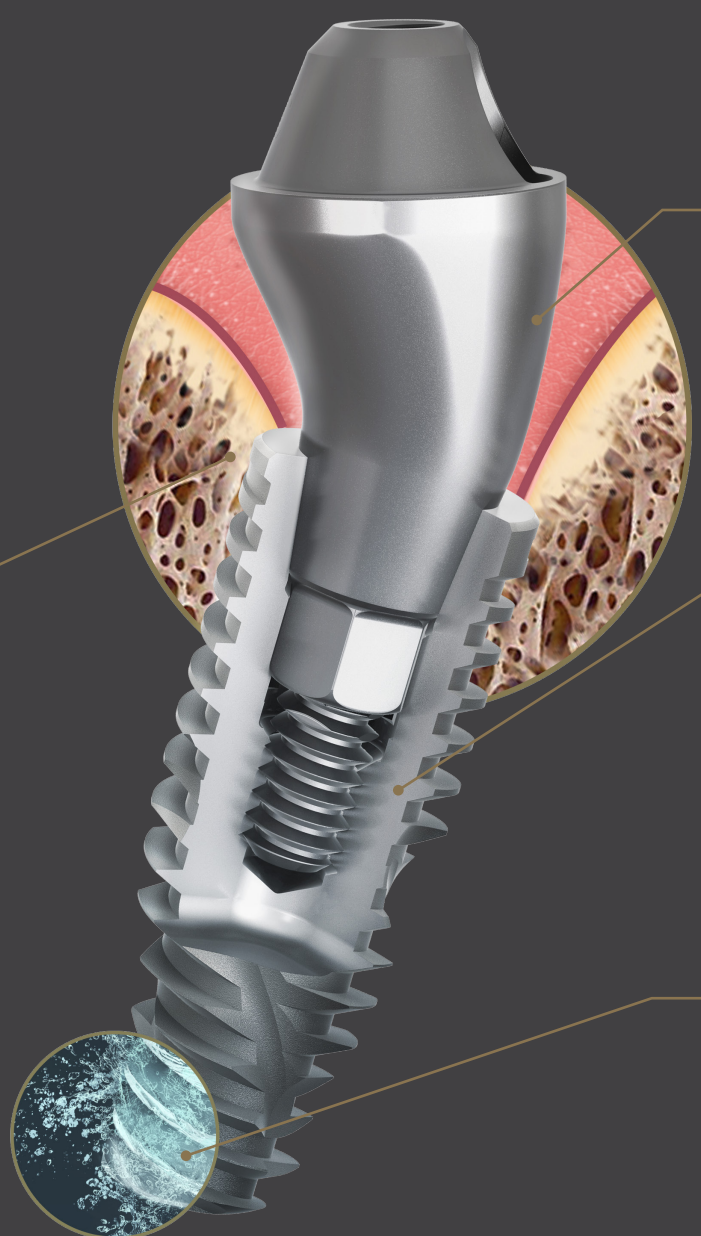
— The next level of Immediate fixed full-arch

The NeoArch® Grand Morse® combines Neodent's® technologies designed to enhance immediate full-arch rehabilitation. The Grand Morse® stability, the Helix® versatility, the Acqua surface predictability, and optimized Mini Conical abutment shape all combined, maximize NeoArch® efficiency: one implant, one connection, one abutment.

GRAND MORSE® CONNECTION: A STABLE AND STRONG FOUNDATION DESIGNED FOR LONG TERM SUCCESS.

- One prosthetic connection for all Grand Morse® Implants: ease of use.
- 16° Morse Taper connection: designed to ensure a tight fit for an optimal connection seal.
- Platform switching morse taper connection: fulfils the platform switching concept.
- Deep Morse taper connection: designed for optimal load distribution.
- Internal Indexation: precise abutment positioning, protection against rotation and easy handling.





**MINI CONICAL ABUTMENT:
IMMEDIATE NATURAL-LOOKING ESTHETICS.**

- Optimized emergence profile: reducing the need of bone profiling.
- Several gingival height options: adapting to tissues availability.
- Optimal angulation of 17° and 30°: fitting to patient anatomy.
- Short cone, wide angle: maximizing passive fit and angulation compensation.

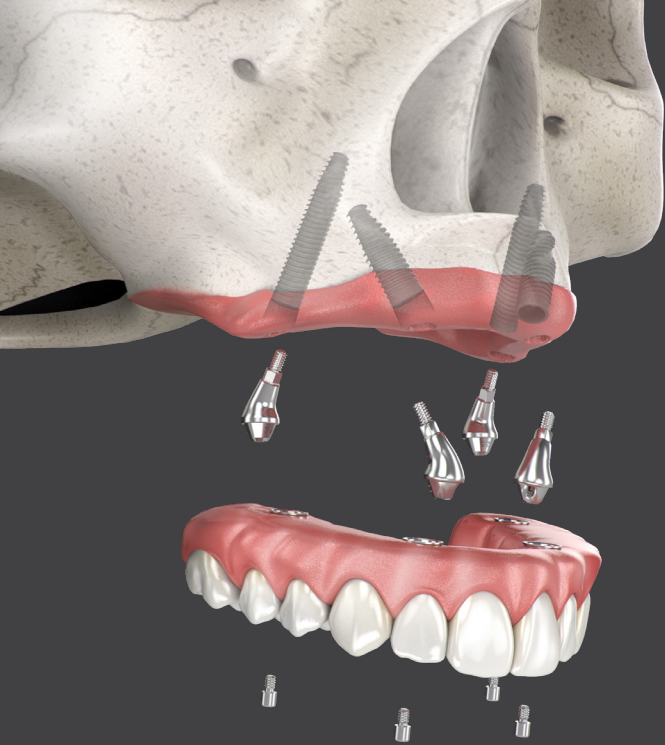**HELIX® GRAND MORSE®:
UNBEATABLE VERSATILITY.**

- Fully tapered body design: allows for under prepping of the osteotomy.
- Hybrid contour: enabling stability with vertical placement flexibility.
- Dynamic progressive thread design: designed to achieve high primary stability in all bone types.
- Active apex: self-tapping.

**ACQUA SURFACE:
HIGH TREATMENT PREDICTABILITY.**




- Sand-blasted Large grit and Acid etched surface: NeoPoros highly successful surface.
- Hydrophilic surface: immediate greater surface accessibility. ⁽⁷⁾



— Immediate solution in severe atrophic maxilla

The Neodent® Helix GM® Long and Zygoma GM™ complement the standard implant system for achieving immediate loading protocol in fixed full-arch restoration. They are specifically designed to bring surgical predictability to atrophic maxilla cases, as an alternative to grafting procedures.

Helix GM® Long *Solution for bicorticalization*



1. GRAND MORSE® CONNECTION

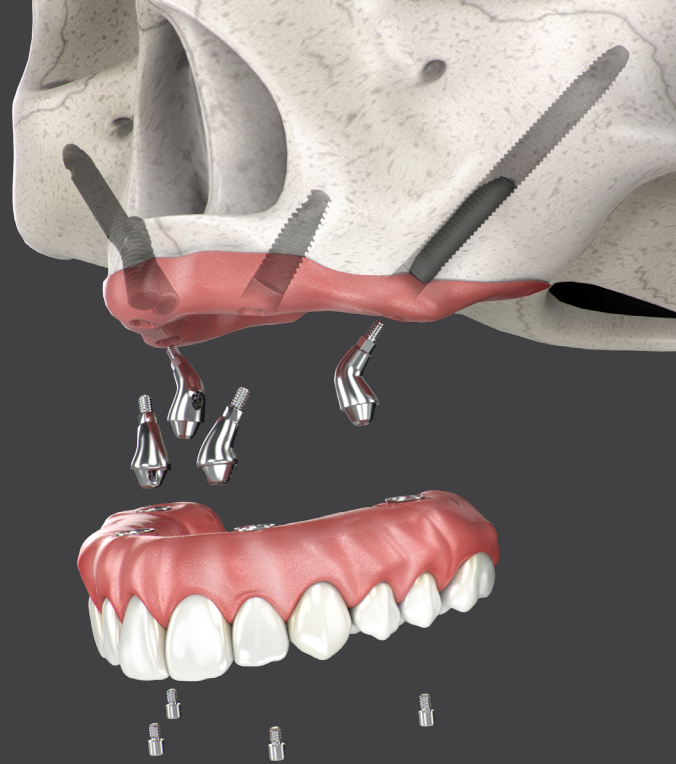
- All benefits of the original 16° Morse taper GM connection designed to ensure a tight fit for an optimal connection seal.
- One connection regardless of the diameter.

2. IMPLANT DESIGN

- Helix® hybrid implant body to maximize treatment options and efficiency.
- Dynamic progressive threads, designed to achieve high primary stability.

3. COMPREHENSIVE PORTFOLIO

- 3.75 and 4.0 mm diameters for more treatment versatility.
- 20, 22.5 and 25 mm lengths designed to achieve bicorticalization.



Zygoma GM™ *Implant for zygomatic anchorage*

1. GRAND MORSE® CONNECTION


- All benefits of the original 16° Morse taper GM connection designed to ensure a tight fit for an optimal connection seal.
- Straight head designed to bring flexibility to the implant positioning.

2. IMPLANT DESIGN

- Tissue protect portion without threads for a friendly contact with the mucosa.
- Progressive increase of the thread depth at the apical area.

3. COMPREHENSIVE PORTFOLIO

- 4.0 mm of diameter.
- Ten different lengths: 30 / 35 / 37.5 / 40 / 42.5 / 45 / 47.5 / 50 / 52.5 / 55 mm.



NeoPoros

PRE-OPERATIVE PLANNING

1. Anatomical Considerations

High success rates have in recent years been reported with the use of four implants in the rehabilitation of edentulous patients^(2-4,6). However, certain technical aspects have to be considered before surgery in order to help ensure treatment success^(7,8). All full-arch reconstruction starts with a clear and previously-defined prosthetic plan, developed according to the patient's remaining structures, including residual alveolar bone and smile line.

Residual Alveolar Bone

The residual alveolar ridge undergoes physiological resorption after complete tooth loss (Fig 2). This resorption can be located in different zones in the arch. Patients presenting atrophic conditions are indicated to receive fixed full-arch rehabilitations. Therefore, the use of implants became important to retention and stability of the entire system.

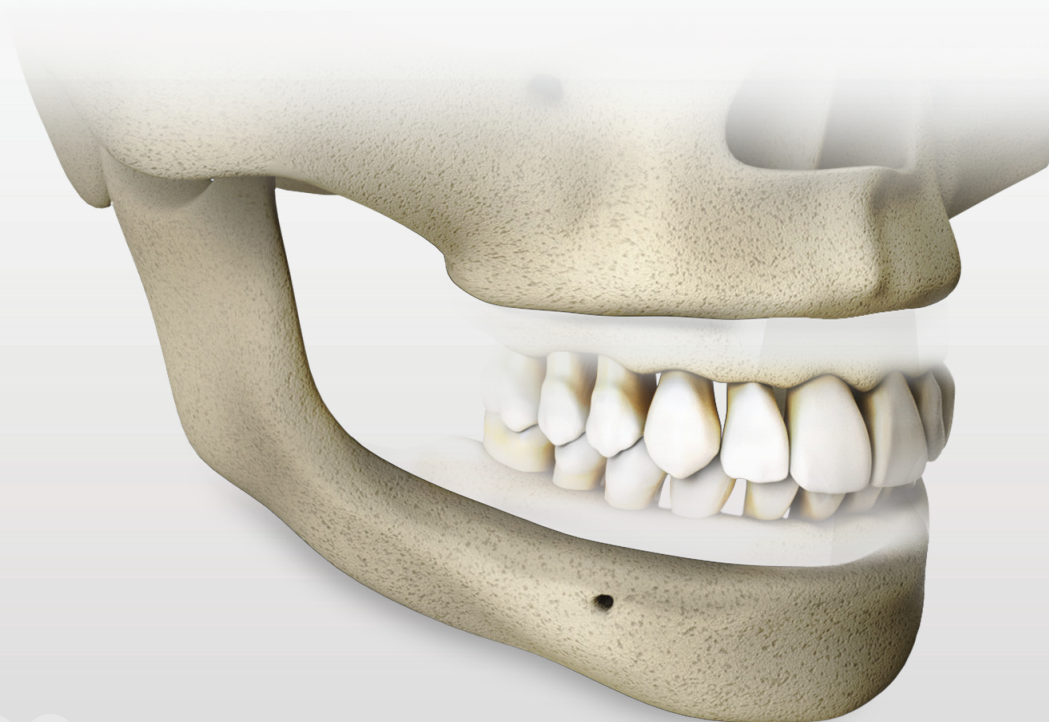
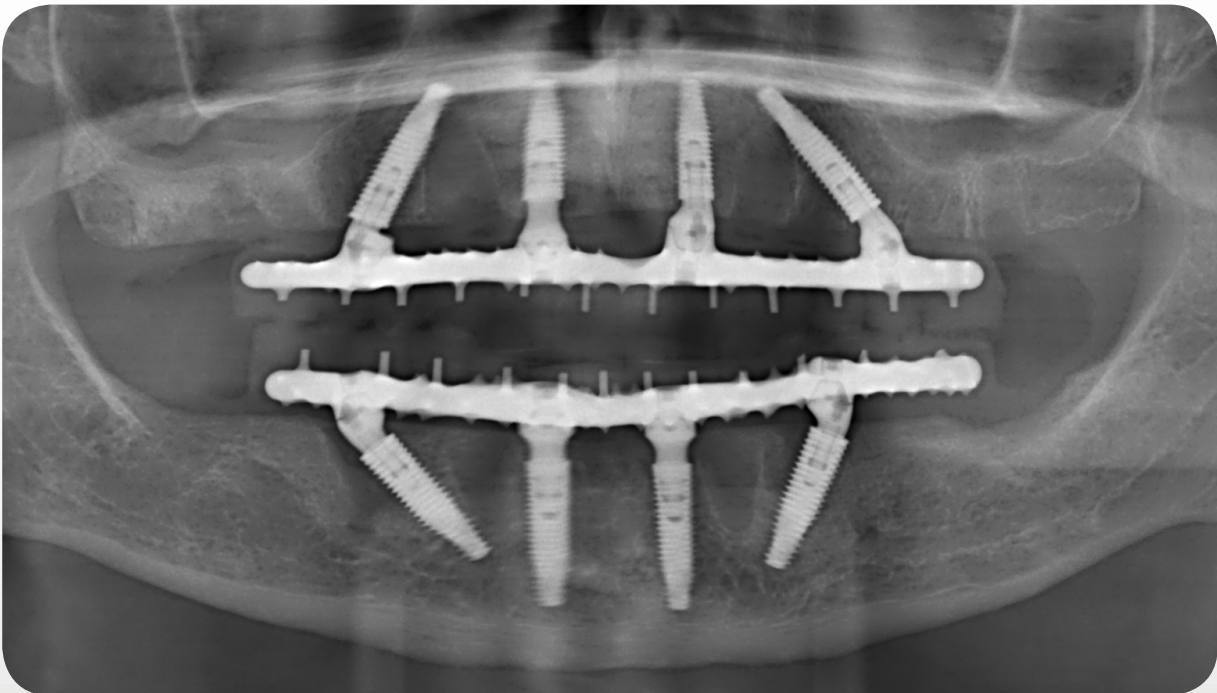


Fig 2. Mandible and maxilla bone resorption after complete tooth loss.

The maxilla has a lower bone density than the mandible, especially when compared at the anterior mandible region between the mental foramen region. Therefore, bicorticalization is a good method for achieve high primary stability of implants in maxilla. In addition, tilted distal implants, zygomatic, or long implants are an effective strategy to enhance contact area with remaining bone avoiding anatomical challenging structures and allowing bicorticalization (Fig 3). At the same time, anterior implants are limited by the nasal cavity and sometimes can be placed in a tilted fashion, also with the apex distally angled, which results in the same benefits, and is known as the M-4 treatment⁽⁹⁾. Thus, if there is sufficient residual bone structure at the anterior region, it may be used long implants to achieve bicorticalization further then the alveolar ridge.



* Patient treatment data authorized for publish.

Fig 3. Higher bone density for positioning implants on sinus and nasal cavity walls.

Smile Line

The patient's smile line determines the esthetic challenges that will drive important surgical and prosthetic procedures when the aim is a natural looking solution. Both characteristics, the smile line combined with the residual alveolar ridge height, (Fig 4) dictate bone horizontal osteotomy, implant positioning and prosthetic extension (with or without "pink esthetic") based on esthetics space for the restoration, and hygiene of the final prosthesis.

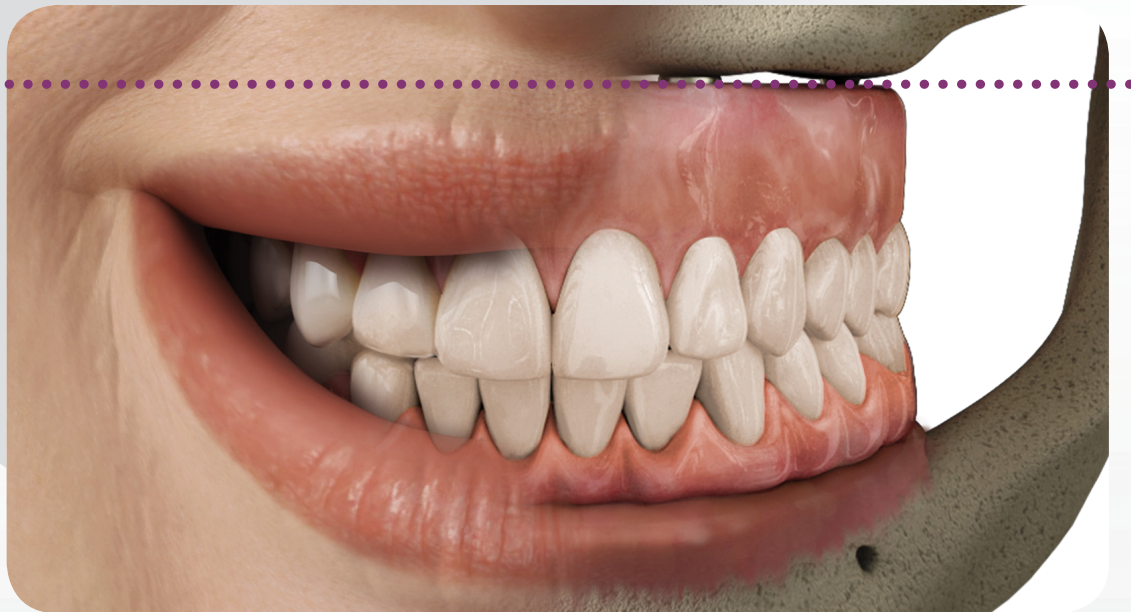


Fig 4. Rehabilitation extension according to patient's structures.

The upper lip defines the patient's smile line and the contact between bridge and remaining mucosa should never be exposed, otherwise there will be esthetical problems in the final restoration. The upper lip must cover the transition line between bridge and remaining mucosa independent of the residual bone structure.

During the planning stage, it is important to evaluate the volume of patient's residual alveolar bone.

VOLUME OF RESIDUAL ALVEOLAR BONE







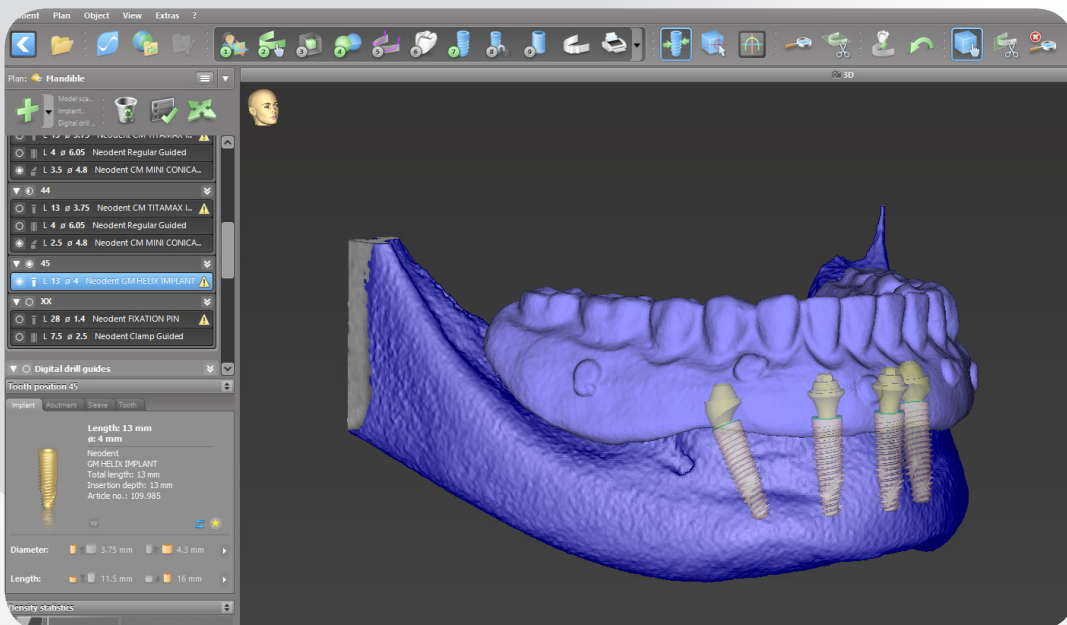
	small	mid	high
BEFORE			
Indication for horizontal osteotomy	Not indicated if the bone is in harmony with the upper lip and even.	Indicated to flat the bone to avoid esthetics and functional problems.	Not indicated if the bone is in harmony with the upper lip and there is prosthetic space for the restoration (see also smile line).
Smile Line High	No osteotomy if the remaining bone is parallel to the upper lip, even and covered by the upper lip.	No osteotomy if the remaining bone is parallel to the upper lip, even and covered by the upper lip.	No osteotomy if the remaining bone is parallel to the upper lip and even. Osteotomy is only indicated if the remaining bone isn't in harmony with the upper lip.
Smile Line Low	No osteotomy if the remaining bone is even.	No osteotomy if the remaining bone is even.	No osteotomy if the remaining bone is covered under the upper lip, even and there is space for the prosthesis.
AFTER			
Type of restoration	Large amount of pink esthetic in the restoration.	Small amount of pink esthetic in the restoration.	No pink esthetic.

Table 1. Previously uneven smile line between crowns and mucosa due to bone extrusion and smile line after osteotomy for fixed full-arch rehabilitation.

2. Digital 3D Planning

For a successful full-arch rehabilitation, the initial prosthetic planning constructed with the aid of a tomography guide according to proper occlusion using Cone Beam Computed Tomography (CBCT) images will define the proper position of implants, and takes into consideration anatomical structures, especially for complex rehabilitation (Fig 5). If the patient presents a well-established conventional complete denture, it also can be used as a guide and as an immediate provisional implant-supported prosthesis. In addition, specific planning software can be used to determine implant positions.



*Data extracted from coDiagnostiX® software.

*Patient treatment data authorized for publish.

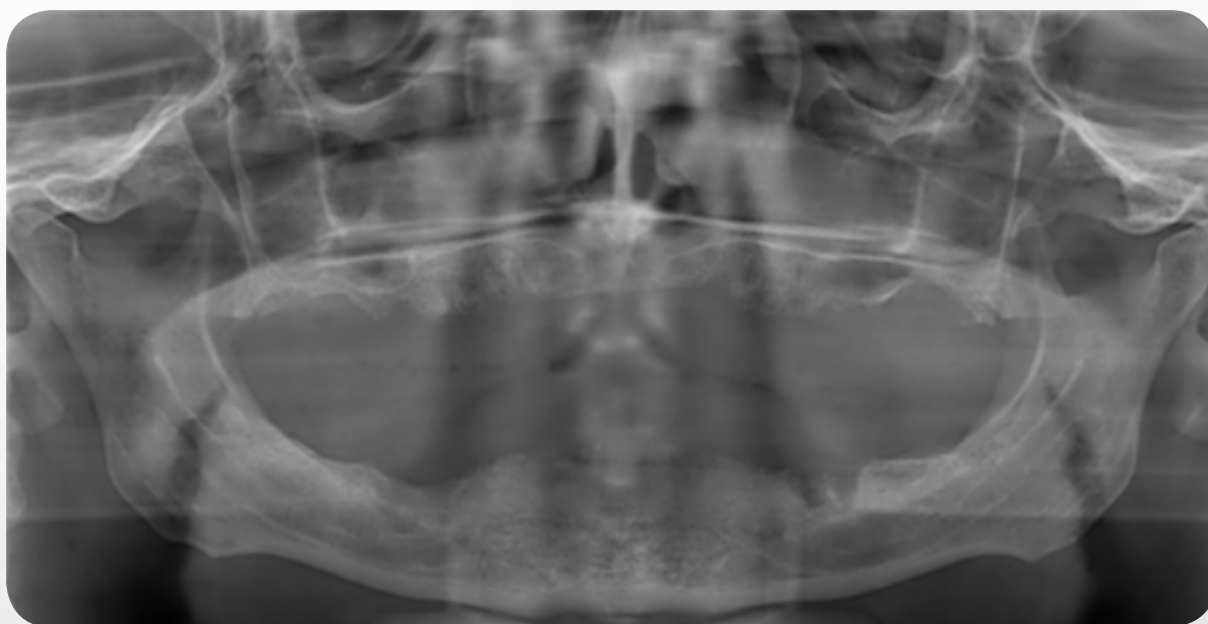
Fig 5. Implant distribution according to bone availability and prosthetic planning.

3. Implant Distribution and Prosthesis Definition

Implant distribution is an important factor to be considered in full-arch bridges as it supplies mechanical result on the system. Anteroposterior implants placement and occlusion should be balanced to avoid stress concentrations^(9,10). Bone condition, such as density, thickness, and anatomical structures are responsible for the implant distribution planning. Therefore, the posterior maxilla is considered the most difficult and problematic intraoral area for treatment with osseointegrated implants, presenting deficient bone quality and quantity, surgical access, and biomechanics (greater masticatory forces)^(11,12).

There are many options for rehabilitating a fixed full-arch, and according to remaining structures and the professional preferences, from 4 to 8 regular straight or tilted implants, long implants, or the addition of zygomatic implants can be used to provide a fixed solution and enhance patient masticatory performance and quality of life. The use of only four regular implants with the distals tilted allows more options for the final position and anteroposterior distribution when planning the rehabilitation^(9,10) and is normally used when facing a high residual alveolar ridge. For extremely atrophic ridges in maxillary bone, implant placement on denser cortical bone such as pterigomaxillary and zygomatic regions can provide adequate implant support and eliminate procedures such as sinus augmentation, supplementals bone block grafts, and the use of a large number of implants^(13,14).

Clinicians can define implant distribution based on the size of the cantilever where distal implants are initially determined. The medial implants can then be placed as far anterior as possible to spread the implants along the arch and distribute forces equally across the entire arch and implants (Fig 6). The use of only four implants allows more options for the final position and anteroposterior distribution when planning the rehabilitation^(9,10) and is normally used when facing a high residual alveolar ridge.



*Patient treatment data authorized for publish.

Fig 6. Panoramic radiography of an edentulous patient.

Note: Anterior/posterior implant distribution on the arch should be carefully evaluated because this determines stress distribution of the system (Fig 35 - 36).

Distal implants should be placed before anterior implants as they determine the posterior limits of implant distribution and are closer to key anatomical structures that must be avoided, such as the mental foramen in the mandible, nasal cavity and sinus for the maxilla. Because the posterior tilted implants installation occurs around the 1st and 2nd pre-molar region, a short cantilever is indicated to extend until the 1st molar, which decreases stress on the peri-implant cortical bone and increases the rehabilitation's longevity. Therefore, the prosthesis should extend to a maximum of 12 teeth.

NEOARCH®

NeoArch® fixed full-arch solutions brings from planning phase through final restoration a clear and complete portfolio workflow to aid the clinician in different bone availability and surgical techniques. Find a proposition of workflow for all treatments options:

1 4 TO 8 REGULAR IMPLANTS

- *Helix GM® implants - designed to achieve immediacy*
- *Surgical procedures and implant placement*
- *Prosthetic options and procedures*

2 LONG IMPLANTS

- *Helix GM® Long implants*
- *Surgical procedures and implant placement*
- *Prosthetic options and procedures*

3 ZYGOMATIC IMPLANTS

- *Zygoma GM™ Implants*
- *Surgical procedures and implant placement*
- *Prosthetic options and procedures*

1 4 TO 8 REGULAR IMPLANTS

— Helix GM® implants - design to achieve immediacy

Ideally, a full arch procedure should optimize an immediate loading with a minimum torque implant placement⁽¹⁵⁻¹⁹⁾, and a final prosthesis with proper occlusion. Helix GM® implants have a dual tapered outer shape with compressive threads in the coronal area and cutting threads at the apex designed to achieve high stability even in areas of poor bone density.

Additionally, implant selection based on the principle of bicorticalization can achieve a higher torque^(20,21), and therefore, more options of lengths and diameters are available for surgeons using this technique.

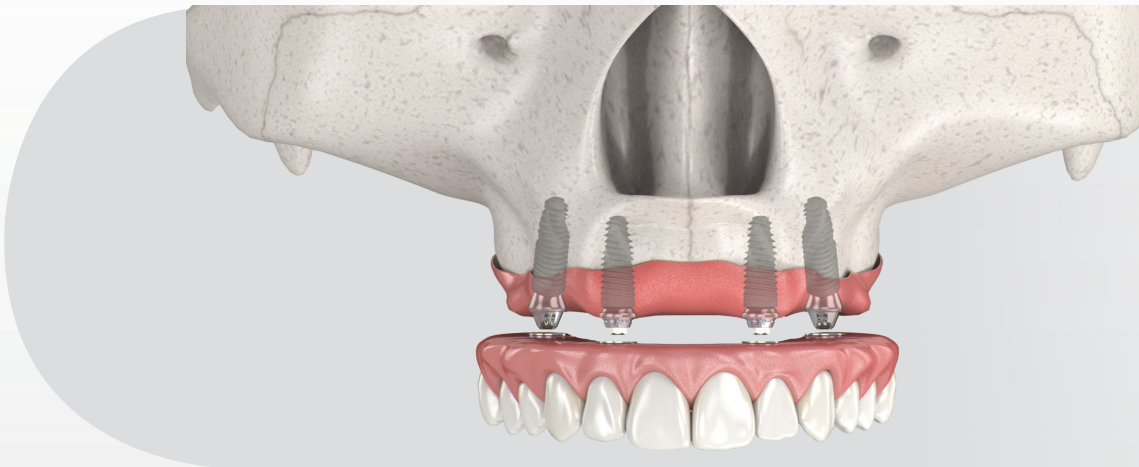



Fig 7. Implant positioning on a full-arch rehabilitation with 4 regular implants.

- GM prosthetic connection;
- Diameters from Ø3.5 to Ø6.0;
- Lengths from 8.0 to 18.0 mm
- Dynamic progressive thread design: designed to achieve high primary stability in all bone types.
- Neoporos and Acqua surface.



		8.0mm	10.0mm	11.5mm	13.0mm	16.0mm	18.0mm
Ø 3.5	Acqua	140.943	140.944	140.945	140.946	140.947	140.988
	NeoPoros	109.943	109.944	109.945	109.946	109.947	109.988
Ø 3.75	Acqua	140.976	140.977	140.978	140.979	140.980	140.981
	NeoPoros	109.976	109.977	109.978	109.979	109.980	109.981
Ø 4.0	Acqua	140.982	140.983	140.984	140.985	140.986	140.987
	NeoPoros	109.982	109.983	109.984	109.985	109.986	109.987
Ø 4.3	Acqua	140.948	140.949	140.950	140.951	140.952	140.989
	NeoPoros	109.948	109.949	109.950	109.951	109.952	109.989
Ø 5.0	Acqua	140.953	140.954	140.955	140.956	140.957	140.990
	NeoPoros	109.953	109.954	109.955	109.956	109.957	109.990
Ø 6.0	Acqua	140.1009	140.1010	140.1011	140.1012		
	NeoPoros	109.1009	109.1010	109.1011	109.1012		

Table 2. Helix GM® implant lengths and diameters.



	Initial	Ø 2.0	Ø 3.5	Ø 3.5+	Ø 2.8/3.5	Ø 3.75	Ø 3.75+	Ø 3.0/3.75	Ø 4.0	Ø 4.0+	Ø 3.3/4.0	Ø 4.3	Ø 4.3+	Ø 3.6/4.3	Ø 5.0	Ø 5.0+	Ø 4.3/5.0	Ø 6.0
	103.170	103.425	103.389	103.419	103.414	103.402	103.420	103.415	103.405	103.421	103.416	103.408	103.422	103.417	103.411	103.423	103.418	103.427
Ø 3.5	Optional	✓		✓	✓													
Ø 3.75	Optional	✓	✓				✓	✓										
Ø 4.0	Optional	✓	✓			✓				✓	✓							
Ø 4.3	Optional	✓	✓			✓			✓				✓	✓				
Ø 5.0	Optional	✓	✓			✓			Optional			✓		✓		✓	✓	

Bone types I and II

Ø 3.5	Optional	✓	✓															
Ø 3.75	Optional	✓	✓			Optional												
Ø 4.0	Optional	✓	✓					Optional										
Ø 4.3	Optional	✓	✓			✓						Optional						
Ø 5.0	Optional	✓	✓									✓			Optional			
Ø 6.0	Optional	✓	✓			✓						✓			✓			✓

Bone types III and IV

Table 3. Helix GM® drill sequence.

Surgical procedures and implant placement

Once the prosthetic and surgical planning are both completed, a flap technique can be used after osteotomy, if necessary for implant placement. According to bone availability, the surgeon can use the quantity of implants that proper will fit for the rehabilitation stress distribution. The following steps are indicated for 4 implants placement:

Maxilla instrumentation

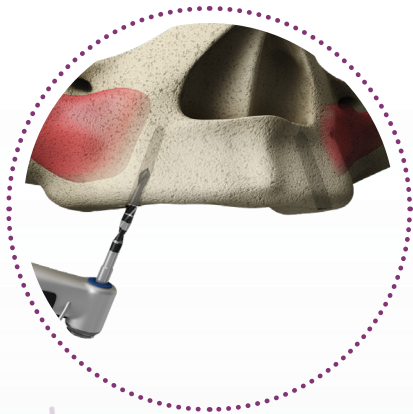


Fig 8.

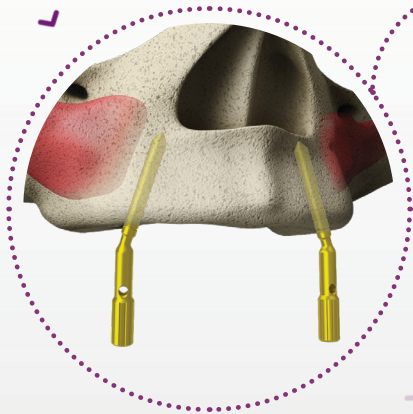


Fig 9.

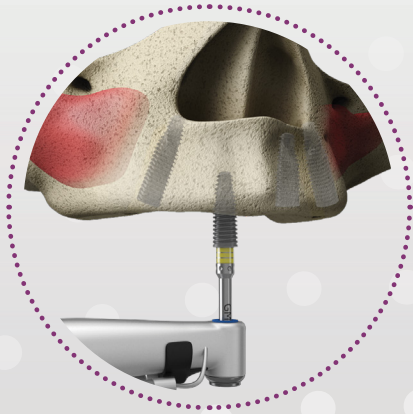


Fig 11.



Fig 10. GM Angle Measurers for Drill 2.0

1. Locate important anatomical structures such as maxillary sinus and nasal cavity to place properly tilted implants (Fig 8). Distal implants are placed in the 2nd premolar or 1st molar region and anterior implants in the lateral incisors region. Implant site is prepared by drilling to the appropriate depth and diameter according to previous planning and the instructions for use (www.ifu.neodent.com.br).

2. After 2.0 drilling, position the GM Angle Measurer for Drill 17° or 30° to analyze if tilted preparation is in accordance with the patient residual ridge arch line and the future prosthetic alignment (Fig 9 and 10).

3. Place distal tilted implants first, and then the straight anterior implants in the prepared bone site beginning with handpiece at a rotational speed of 30 rpm and a torque of 32 N.cm (Fig 11). The handpiece driver has metal tweezers in the active apex to keep the implant stable during transport. Finalize implant placement with the torque wrench connection by positioning the implant with the Exact dimple facing to the mesial site and according to the patient residual ridge arch line for tilted implants, and buccal site for straight anterior implants placement, providing prosthetic orientation.

Note: the line markings on torque wrench connections are designed to set the bone level implant positioning. To install anterior implants, prepare anterior sites as far apart from each other as possible and with a safety distance from tilted posterior implants.

Mandible instrumentation

1. Locate important anatomical structures such as the inferior alveolar nerve and place tilted implant avoiding such structures (Fig 12). Distal implants should be positioned in the 1st premolar region and anterior implants in the lateral incisors region.

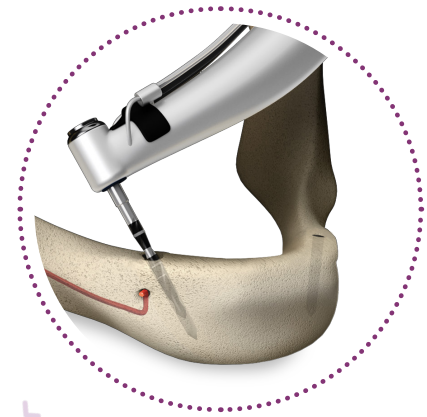


Fig 12.

2. Implant site is prepared by drilling to the appropriate depth and diameter according to previous planning and the instructions for use (www.ifu.neodent.com.br). After 2.0 drilling, position the GM Angle Measurer for Drill 17° or 30° to analyze if tilted preparation is in accordance to the patient residual ridge arch line and the future prosthetic alignment (Fig 13). Continue the drilling sequence until reach the proper alveolar site diameter.

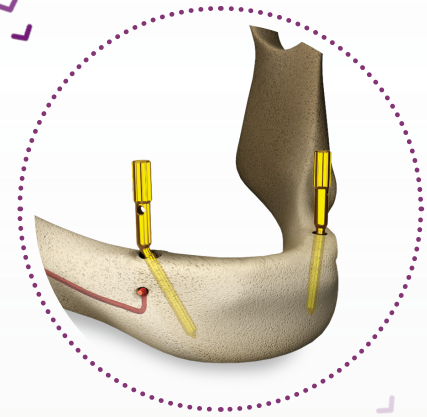


Fig 13.

3. Place distal tilted implants first, and then the straight anterior implants in the prepared bone site beginning with handpiece speed of 30 rpm and a torque of 32 N.cm (Fig 14). The handpiece driver has metal tweezers in the active apex to keep the implant stable during transport. Finalize installation with the torque wrench connection by positioning the implant with the Exact dimple facing to the mesial site and according to the patient residual ridge arch line for tilted implants, and buccal site for straight anterior implants placement, to provide prosthetic orientation.

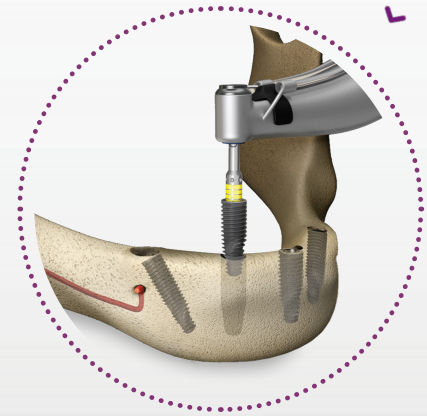


Fig 14.

Note: the line markings on torque wrench connections are designed to set the bone level implant positioning. To place anterior implants, prepare anterior sites as far apart from each other as possible and with a safety distance from tilted posterior implants.



Fig 15. GM Angle Measurers




Fig 16. After implant placement make sure that the angle measurer is aligned with the patient residual ridge arch line.

Bone Profile Use

Bone Profile Drill is used to remove bone, if necessary, around the implant platform in the following situations:

- Tilted implants for abutment emergence profile;
- Subcrestal implants positioning;
- Uneven residual alveolar ridge.

The following sequence is indicated:

1. Install the Bone Profile Drill Guide into the implant with the Manual Neo Screwdriver.
2. Fit the Bone Profile Drill into the handpiece and place it over the Guide.
3. Drill into the coronal bone around the implant in cases where the bone interferes with the abutment's emergence profile. Use an intermittent drilling technique with abundant irrigation.

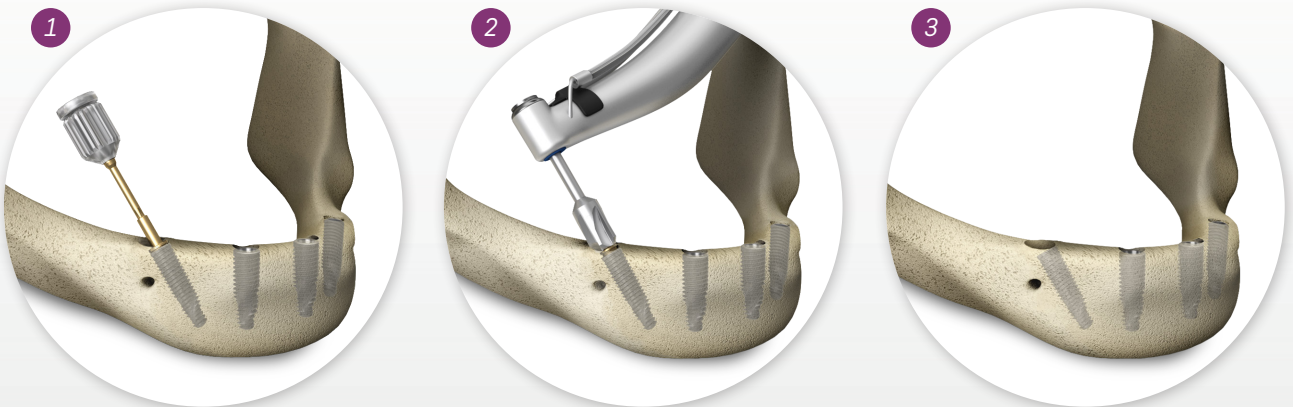

Fig 17. Drilling sequence when using Bone Profile.

Note: When drilling, keep the bone profile and the guide aligned. Do not apply bending forces and be aware that abundant irrigation is necessary.

Prosthetic options and procedures

Abutment Selection

After the implants placement, the following steps for abutment installation are indicated:

1. For tilted posterior implants, the use of angled abutments is recommended. For abutment selection use the GM Angle Measurer intraorally to determine the final angulation and positioning of Abutment and gingiva height (Fig 18). If the angle measurer is not pointing to the patient residual ridge arch line, the implant still can be rotated for a proper prosthetic future alignment (Fig 16).

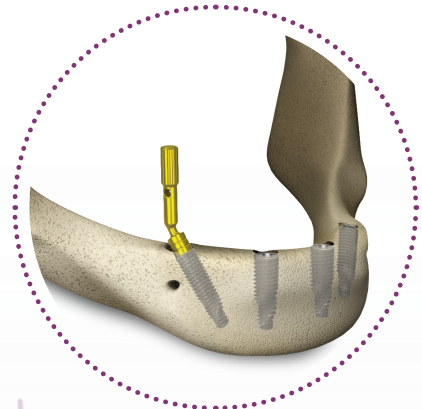


Fig 18.

2. Install the angled GM Exact Mini Conical Abutment 17°/30° with Neo Screwdriver at a torque of 20 N.cm (Fig 19).

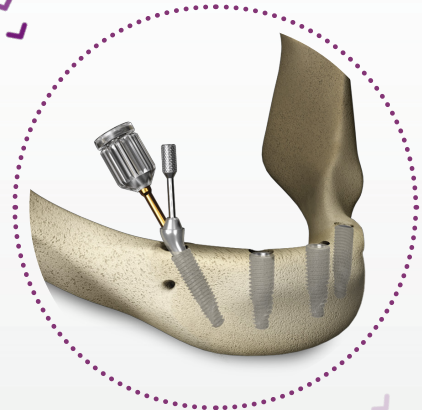


Fig 19.

3. There are two options for anterior straight abutments: Micro or Mini Conical Abutment. The difference is that the Micro Conical abutment is recommended for patients that present reduced interocclusal space, providing wider space for a bar construction and/or prosthetic material. For both abutments, use the hexagonal driver with a torque of 32 N.cm. Install the final abutments (Fig 20).

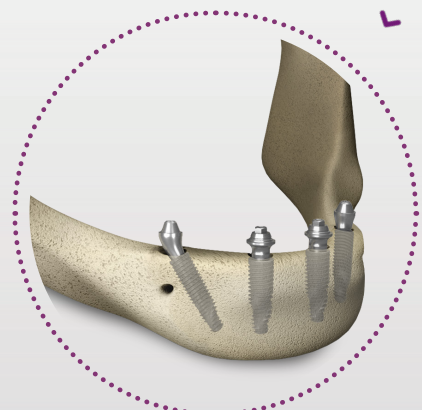


Fig 20.

Note: Angled abutments are delivered pre-assembled, which simplifies abutment placement in the posterior region (Fig 19). Furthermore, the pre-assembled driver indicates the orientation of the occlusal screw channel. Additionally, angled abutments are presented in 17° or 30° degrees and 1.5, 2.5, or 3.5 mm gingiva height.

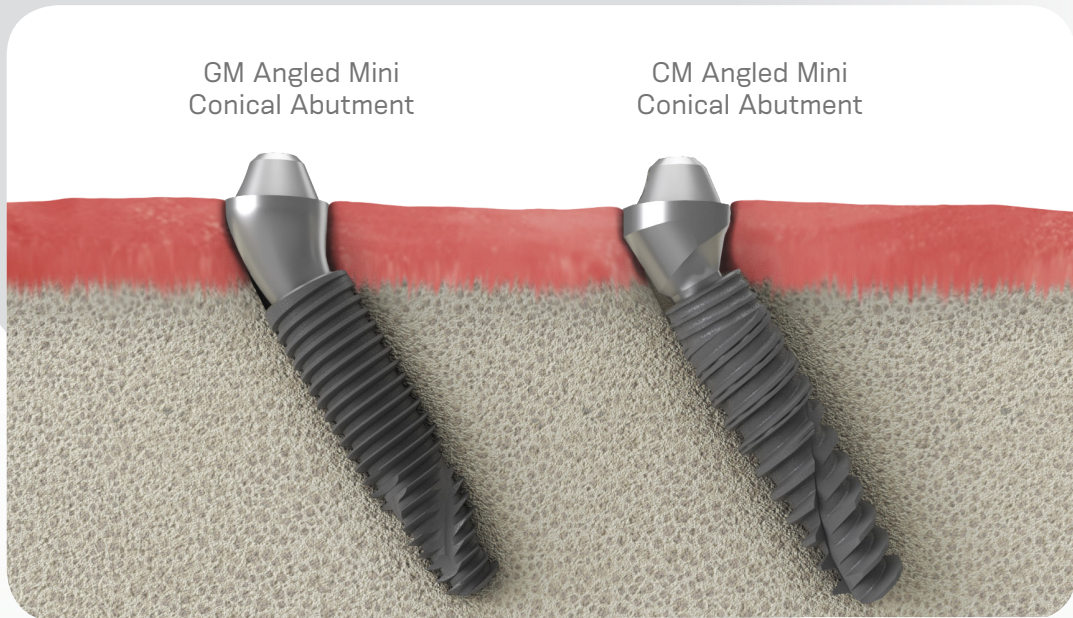

Figure 21 shows the optimized emergence profile that the new GM Mini Conical Abutment can produce, since is anatomically curved shape. This feature is also designed to facilitate patient daily cleaning procedures.

Impression taking on abutment level

Once the surgical procedures and abutment placement are completed, an impression is taken to cast the final abutment positions in the plaster model. The following steps for an OPEN TRAY IMPRESSION are indicated:

1. Place the Slim Mini Conical Abutment Open Tray Impression Coping accurately into the abutment and only rotate the screw, manually or with the aid of Neo torque Connection (Fig 22). Make perforations in the custommade impression tray (light-cured resin) according to the individual situation and check if the Screw of Impression Coping protrudes visibly.

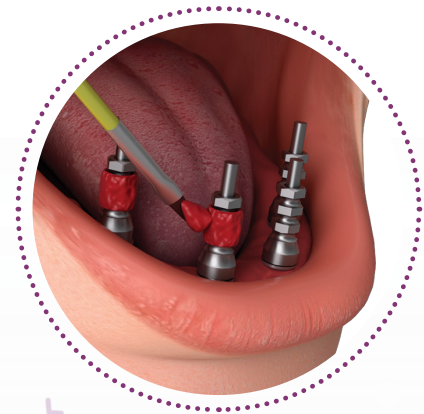

Fig 22.

2. Splint the Impression Copings using a low shrinkage polymerization acrylic resin according to manufacturer recommendation. It is recommended to take the impression using a standard elastomeric impression material (e.g. polyvinyl siloxane). Uncover the screws before the material is set. Once the material is set, loosen the Copings Screws with the Neo Torque Connection and remove the tray. For easy abutment identification, include the analogs when you send the dental impression to your dental lab partner (Fig 23).

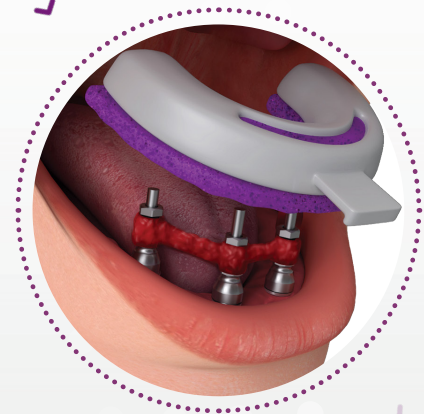


Fig 23.

3. Fabricate the master cast with stone type IV (Fig 24) or proceed with a digital scanning process creating a 3D printed model. For conventional workflow, a gingival mask should always be used to ensure that the emergence profile is optimally contoured. This final plaster model will be used in the next steps of restoration process.

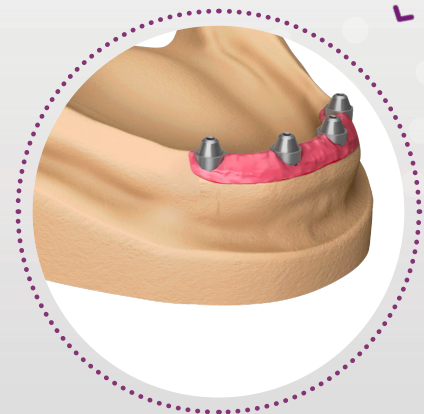


Fig 24.

Immediate provisionalization

In the 48 hours after the surgical procedure, clinicians can provisionally restore the patient's oral function and aesthetics. The restorative portfolio contains the Neo Distal Bar to strengthen the provisional transition from complete denture to fixed full-arch. The following steps for an IMMEDIATE TEMPORALIZATION are indicated:

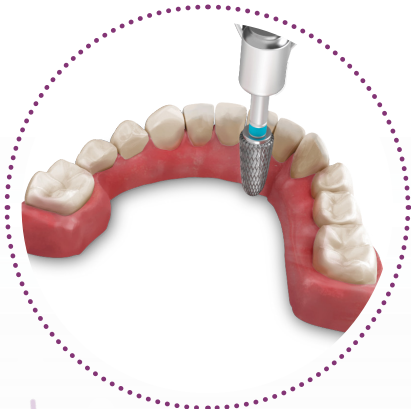

Fig 25.

1. Promote lingual wear on the conventional complete denture preserving the buccal and posterior region integrity (Fig 25).

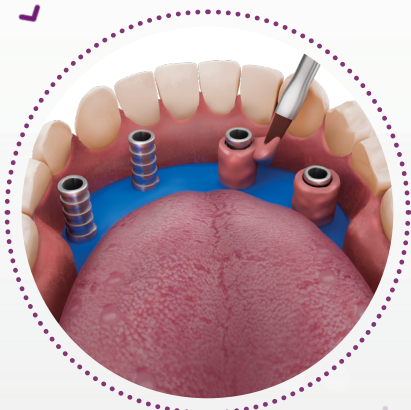


Fig 26.

2. Place non-engaging Titanium Copings on the anterior and posterior abutments. Proof the alignment and relation between implant components and prosthesis. Once the position is ensured, make sure the occlusal set up fits with the prepared prosthesis and place a rubber sheet over the copings to protect and avoid acrylic resin contact with soft tissue (Fig 26). Apply pink acrylic resin around the copings. Patient should be in occlusion to establish a proper central relation between arches until resin polymer.

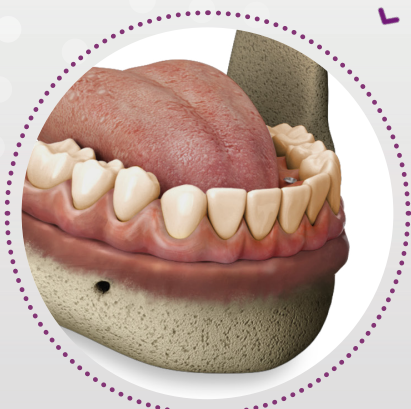

Fig 27.

3. Finalize and polish the temporary restoration. Place the temporary restoration in the patient's mouth and tighten the occlusal screws to 10 N.cm using the Neo Screwdriver (Fig 27).

After the final plaster model is produced, the bar can be made at the laboratory center by conventional cast.

1. Place the castable copings (One step hybrid set or conventional copings) on the top of the analogs with a 10 N.cm torque (Fig 28). Wax-up the bar-framework according to the availability of patient interocclusal space.

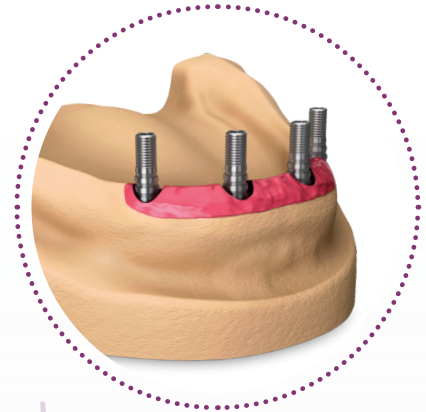


Fig 28.

2. Cast the bar and check its alignment over the model (Fig 29). For conventional casting, a clinical section is required to ensure passive fit of the bar. If not, perform a cross-section on the bar and reconnect intraorally with low shrinkage polymerization acrylic resin, reestablishing the bar fit. For One step hybrid technique, cement the structure over titanium copings.

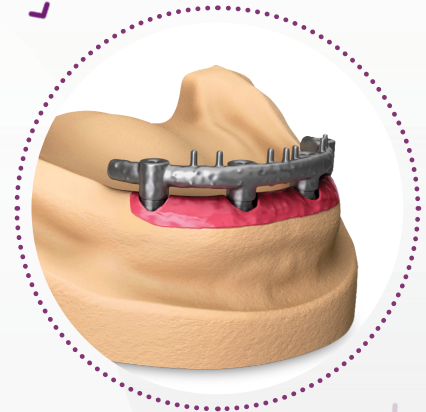

Fig 29.

3. Produce the final restoration based on the custom-milled framework. Install final complete fixed restoration on the patient's mouth (Fig 30).

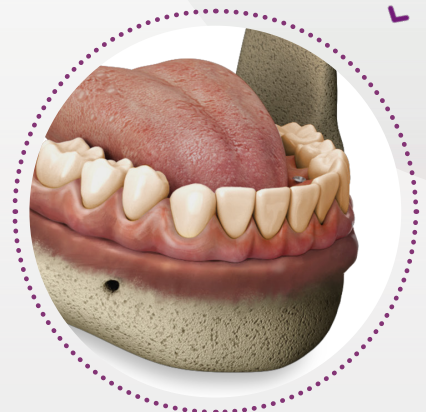

Fig 30.

If you decide to work with a custom-milled digital framework, please proceed as follows:

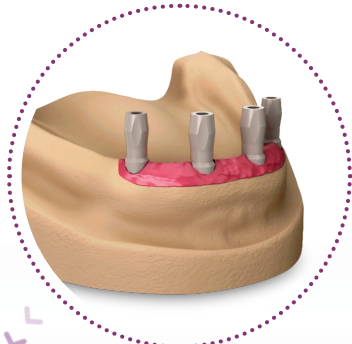

Fig 31.

1. Fabricate a master cast based on a dental impression or proceed with digital scanning process to create a 3D printed model. Place the Mini Conical Abutment Scanbodies onto the analogs on the dental model using the 1.2 Manual Screwdriver (Fig 31).



Fig 32.

2. Scan the plaster model set with the help of a scanner and design the framework in CAD software (Fig 32).

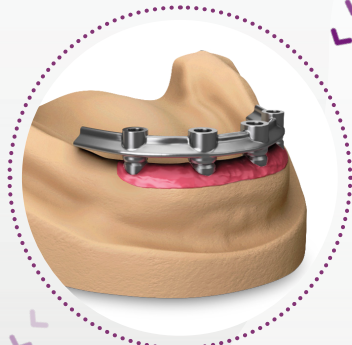


Fig 33.

3. Produce the final restoration based on the custom-milled framework (Fig 33).

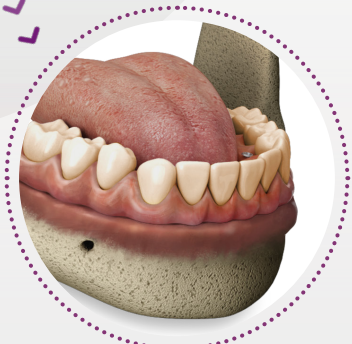

Fig 34.

4. In the dental office, place the final restoration into the patient's mouth (Fig 34).

For mandible rehabilitations, cantilever size is indicated up to 2 teeth (2nd pre molar and 1st molar) and anterior implants are ideally placed in the lateral incisor region^(9,10) (Fig 35).

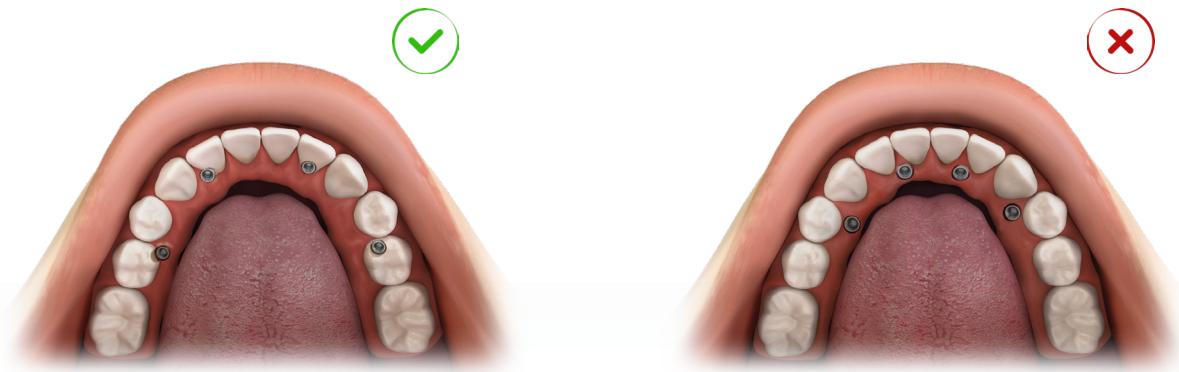


Fig 35. Force distribution and resistance proportions on full-arch rehabilitations with four implants.

In maxilla planning, the cantilever should extend only for the 1st molar. Anterior implants can be located at the lateral incisor or canine region^(9,10) (Fig 36).

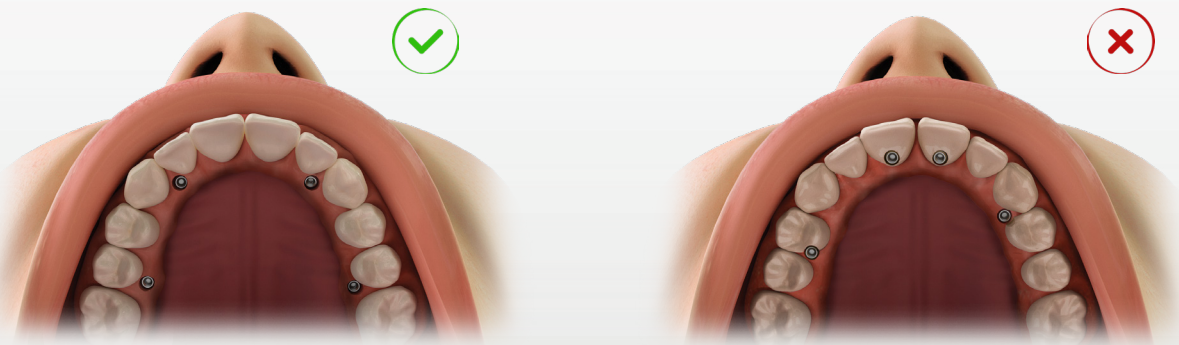


Fig 36. Proportion and relation of implants positioning and size of cantilever.

For a better stress distribution, the outlined shape between the implants should be the biggest square format as possible.

2 LONG IMPLANTS

The Neodent® Long implants are intended to be surgically placed in the maxilla bone providing support for prosthetic rehabilitations, restoring patient chewing function. They may be used with single-stage or two-stage procedures, for multiple unit restorations, and may be loaded immediately when proper primary stability is achieved and with appropriate occlusal loading. They are indicated for rehabilitation of patients with atrophic maxilla.

— Helix GM® Long implants - solution for bicorticalization

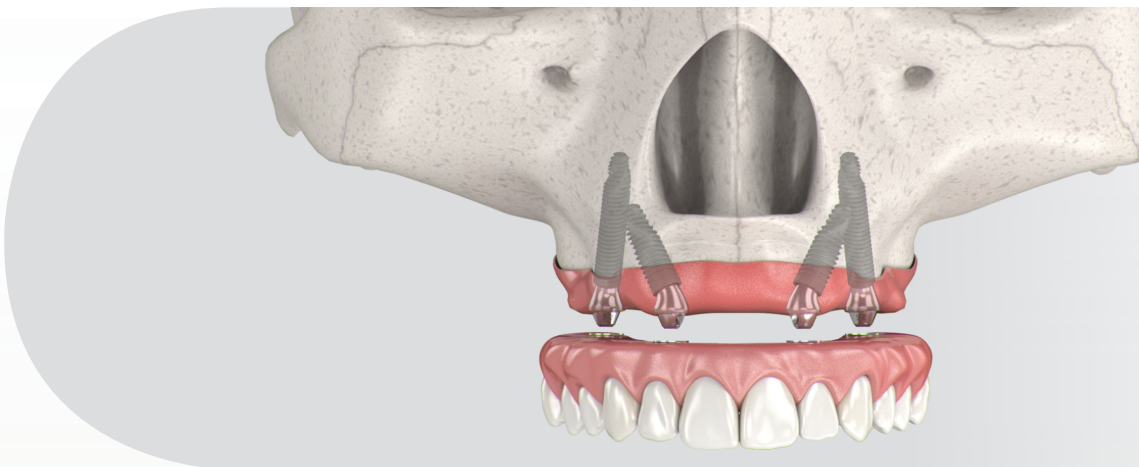


Fig 37. Implant positioning on a full-arch rehabilitation with 2 long implants and 2 regular implants.

- GM prosthetic connection;
- Diameters of 3.75 and 4.0 mm;
- Lengths of 20.0; 22.5 and 25 mm;
- Interface aligned to the implant longitudinal axis;
- Neoporos surface.




Ø 3.75	109.1043	109.1044	109.1045
Ø 4.0	109.1046	109.1047	109.1048

Table 4. Helix GM® Long implant lengths and diameters.


Surgical procedures and implant placement

The technical approach for long implants placement is similar to regular sizes implants. The awareness of anatomical structures and corticalization of such implants, on lateral bone tables of nasal cavity, maxillary sinus, or pterygomaxillary plates region turn to be extremely important, once the extension of such implants is higher. Additionally, the use of longer drills and instruments is required.

The drills of Helix GM® Long are used surgically in the perforation of bone tissue during bed preparation in cases of atrophic maxilla. The set for implant placement is formed by seven drills. Among them, there are three for guided surgical procedure and four for the conventional procedure.



	Initial	Ø 2.35*	Ø 3.75*	Ø 4.0*
	103.453	103.462	103.463	103.464
Ø 3.75 mm	Optional	✓	✓	
Ø 4.0 mm	Optional	✓	✓	✓

 For bone types III and IV

* Drills available for both conventional and Guided Surgery procedures.

Table 5. Helix GM® Long drill sequence.

M Technique

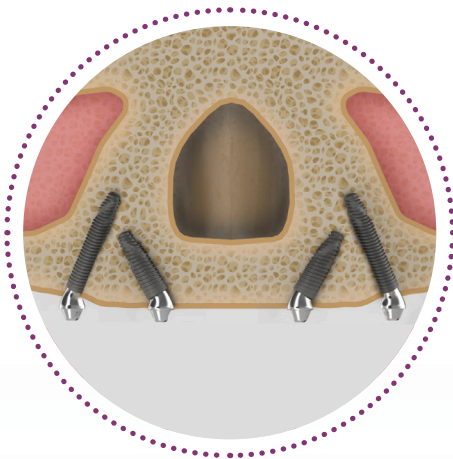


Fig 38.

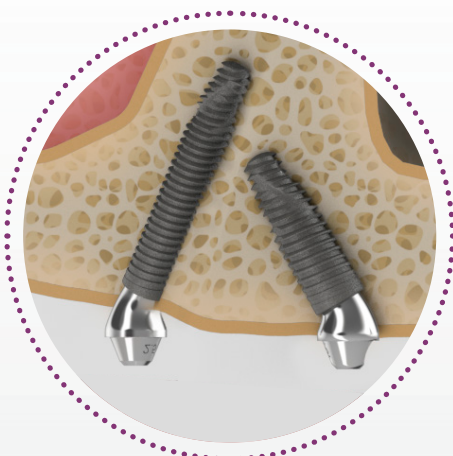

Fig 39.

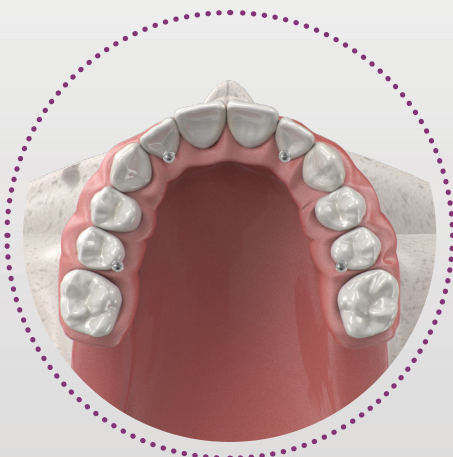


Fig 40.

Four implants are used, two posteriors and two anteriors (Fig 38). The two posteriors are installed in the pre-molar position, in a direction that is inclined up to 45° in a mesial direction tangent to the anterior wall of the maxillary sinus, with the prosthetic platform appearing at the position of the 2nd premolar or 1st molar. The two anteriors implants are tilted posteriorly to also cover the lateral border of the pyriform^(9,23).

M Point is the maximum bone mass at the lateral pyriform rim above the nasal fossa, where the implant apices can engage cortical bone for primary stability^(9,23) (Fig 39). Usually an area that does not suffer with the maxilla bone resorption on the long run.

According to Jensen et al. (2014) the most favorable implant angulation, surgically and prosthetically, is 30 degrees, based on the following 3 points:

1. Length of the implant in bone increasing by 50%;
2. It increases occlusal load resistance form;
3. Leading to sub-osseous conformation is splinted configurations, increasing the resistance to shear force (Fig 40).

For extreme angled positions the 45° GM Mini Conical Abutment can be used. The use of angle measures helps to select the proper abutment angle according to the alveolar ridge conformity.

Prosthetic options and procedures

Abutment selection, provisional, and final restoration

After the Helix GM® Long implants placement, prosecuting abutment selection, provisional temporary prosthetic rehabilitation, and the final restoration confection, present similar steps for regular size implants technique.

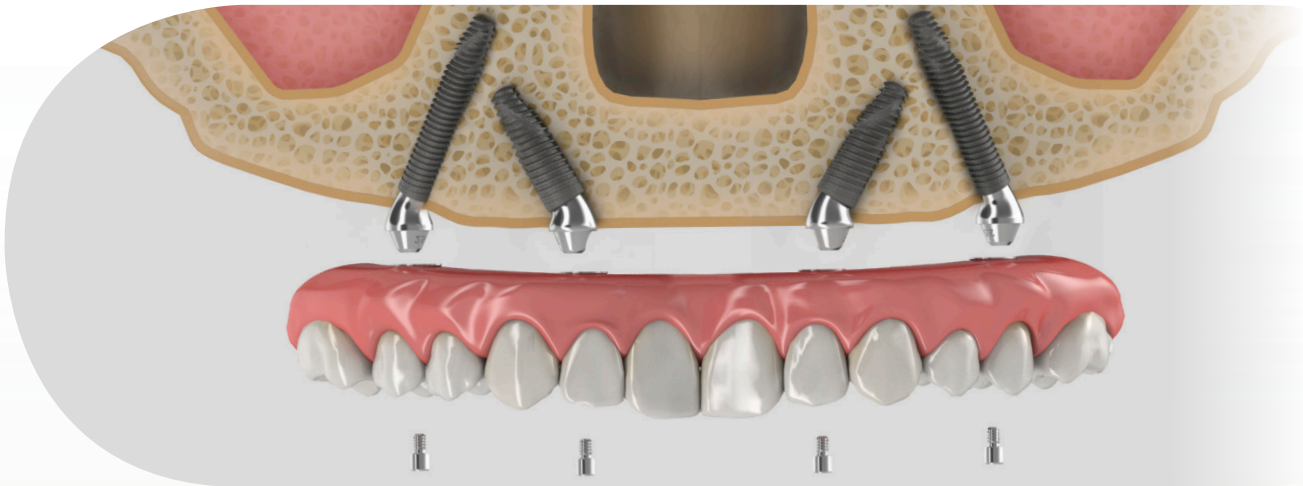


Fig 41. According to the implant placement position and the residual alveolar ridge arch, the straight or angled abutments are selected.

GM Exact Mini Conical Abutment



	17°	30°	45°*
1.5 mm	115.249	115.252	115.267
2.5 mm	115.250	115.253	115.268
3.5 mm	115.251	115.254	

*The 45° Mini Conical Abutment is indicated for use only with Helix GM® Long and Zygoma GM™.
Table 6. GM Angled Mini Conical Abutment.

GM Angle Measurer



17°	30°	45°
128.032	128.033	128.034

Table 7. GM Angle Measurers.

3 ZYGOMATIC IMPLANTS

In a clinical scenario of severe maxillary osteomalacia, atrophy, surgical resection, or trauma, conventional implant placement may require different approaches. The resorption of the maxilla in a posterior/superior direction results in a smaller osseous base that necessitates a larger volumetric replacement of the denoalveolar complex, added to the fact that the complications of sinus disease and enlarged pneumatized sinuses may create the need for multiple grafting procedures to develop suitable osseous tissue and may not present the most desirable pathway for patients.

The use of zygomatic implants avoid the need of bone block grafts, reducing healing period and consequently clinical time for final fixed restoration. The installation protocol implies in the placement of two zygomatic implants and additional regular or long implants in the anterior maxilla splinted together, to support a screw-retained fixed dental prosthesis.

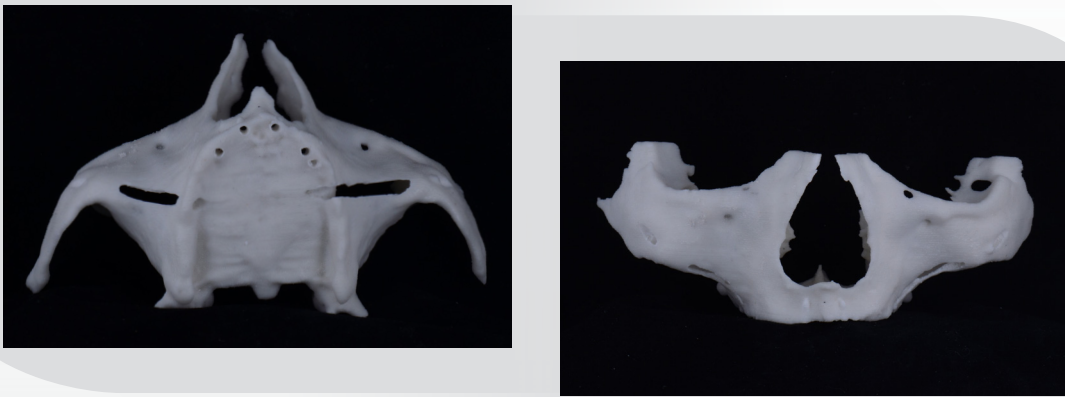


Fig 42. Illustration of anatomical structures.

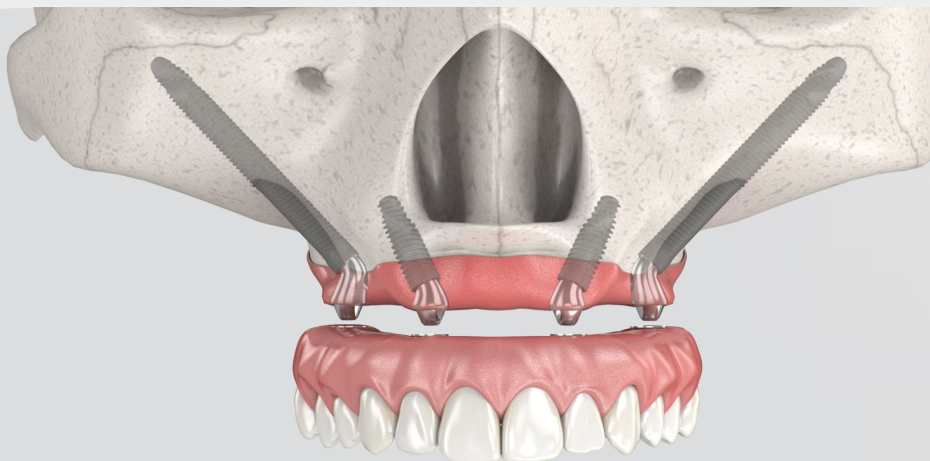


Fig 43. Implant positioning on a full-arch rehabilitation with 2 Zygoma GM™ implants and 2 regular implants.

Zygoma GM™ - implant for zygomatic anchorage

Indicated for surgical placement in the zygoma region, in cases of severe bone jaw resorption, in order to restore patient esthetics and chewing function. Zygomatic Implants are recommended for the posterior maxilla region. Neodent® Zygoma GM™ Implants may be loaded immediately when good primary stability is achieved and with appropriate occlusal loading.

- GM prosthetic connection;
- Diameter of 4.0 mm;
- Lengths from 30.0 to 55.0 mm;
- Tissue protect portion without threads near to the cervical region, for a friendly contact with the mucosa;
- Special Lateral direction drill designed to avoid soft tissue damaging;
- Neoporos Surface;

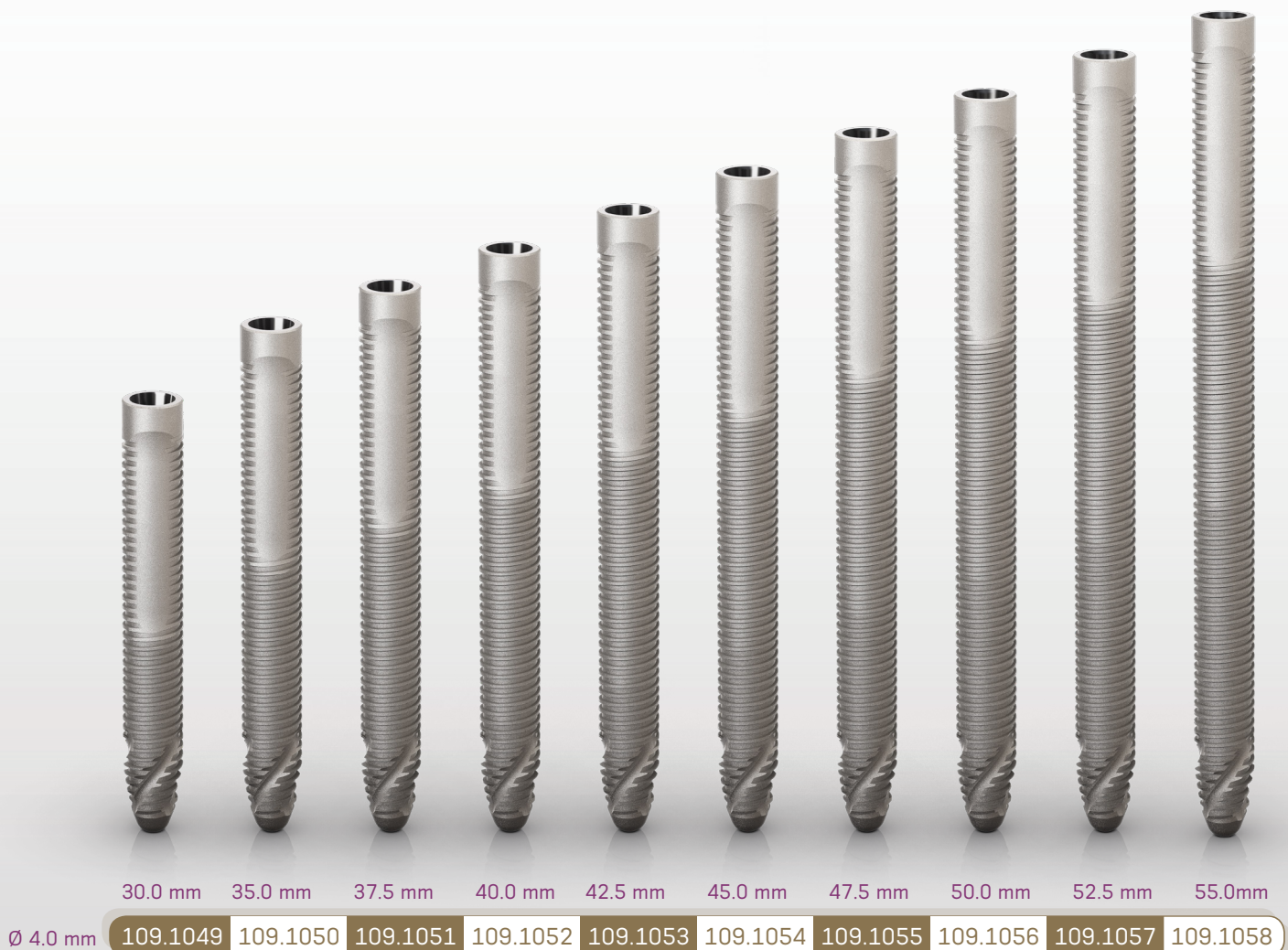



Table 8. Zygoma GM™ implant lengths.

Surgical procedures and implant placement

There are specific techniques used in order to promote zygomatic implants installations on the atrophic maxilla. From conventional through the full exterior implant position, or even Stella Sinus Slot technique⁽²²⁾, the surgical approach is considered advanced and requires a specific dental training program.

Due to the long drilling distance to the zygomatic bone and in order to protect critical adjacent anatomical structures, placement of zygomatic implants requires considerable surgical training and experience diagnostic planning. To receive an adequate overview over the anatomical structures, presurgical 3D planning with Cone Beam Computer Tomography scans and a biomodel is strongly recommended.

The drills have a longer lengths when compared to drills for conventional implants. The set of drills for implants placement is composed of six drills; one for guided surgical procedure, one for the exteriorized technique and the others to complete the procedure.



	Ø 2.35*	Lateral directional Ø 4.0	Pilot Ø 2.3/3.2	Ø 3.75	Ø 4.0
	103.455	103.458	103.465	103.456	103.457
Ø 4.0 mm	✓	Optional	Optional	✓	✓

* Drill available for both conventional and Guided Surgery procedures.

Table 9. Zygoma GM™ drill sequence.

Surgical technique

When performing the technique of implantation in the extra-sinus zygomatic⁽²⁴⁾ (Fig 44), the implant insertion should be guided by the local anatomical conditions, respecting the integrity of the infraorbital nerve, the orbit and the infraorbital fossa. The osteotomy should be performed as posteriorly as possible, maintaining a safe distance of 3 mm from the posterior vertical border of the zygomatic bone. When the trajectory of the zygomatic implant is visualized, surgical drills should be used to create a canal from the residual ridge and continue on the buccal surface of the maxillary body.

Once the sinus membrane is exposed, manual instruments should be used to push it inward in order to preserve its integrity and create space for the drills. Zygomatic implants should be placed in a space created between the membrane and the zygomatic bone, with its body located in the sinus cavity. Neodent® developed The Lateral Direction Drill specially to respect soft tissue, avoiding tissue damage (Fig 45).

The position of the platform regarding the residual ridge should be determined by the surgeon according to prosthetic needs. With this technique, posterior implants usually emerge at the level of the second premolar, while the anterior ones lie on the level of the lateral incisor (Fig 46).

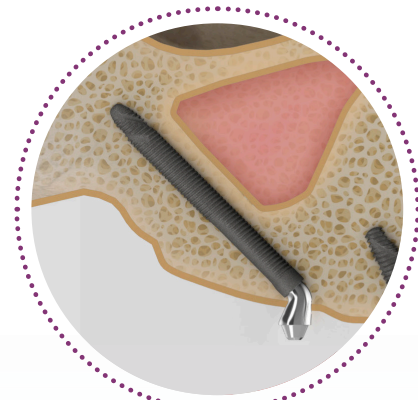


Fig 44.



Fig 45.

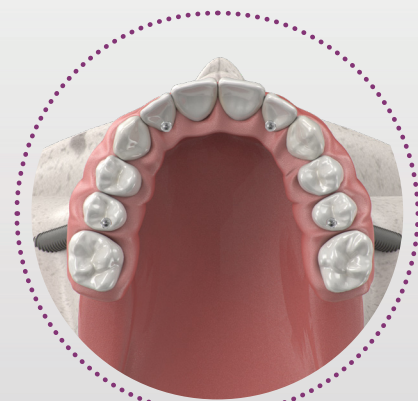


Fig 46.

Prosthetic options and procedures

Abutment selection, provisional, and final restoration

Zygomatic implants placement over the crest ridge allows traditional prosthetic reconstruction, in contrast to the challenge of palatally positioned implants. For extreme angled positions, the GM Mini Conical Abutment presents 45° of inclination. With the available gingival heights of 1.5 or 2.5 mm. Thus, the use of angle measures helps to select the proper abutment angle according to the alveolar ridge conformity (Fig 47).

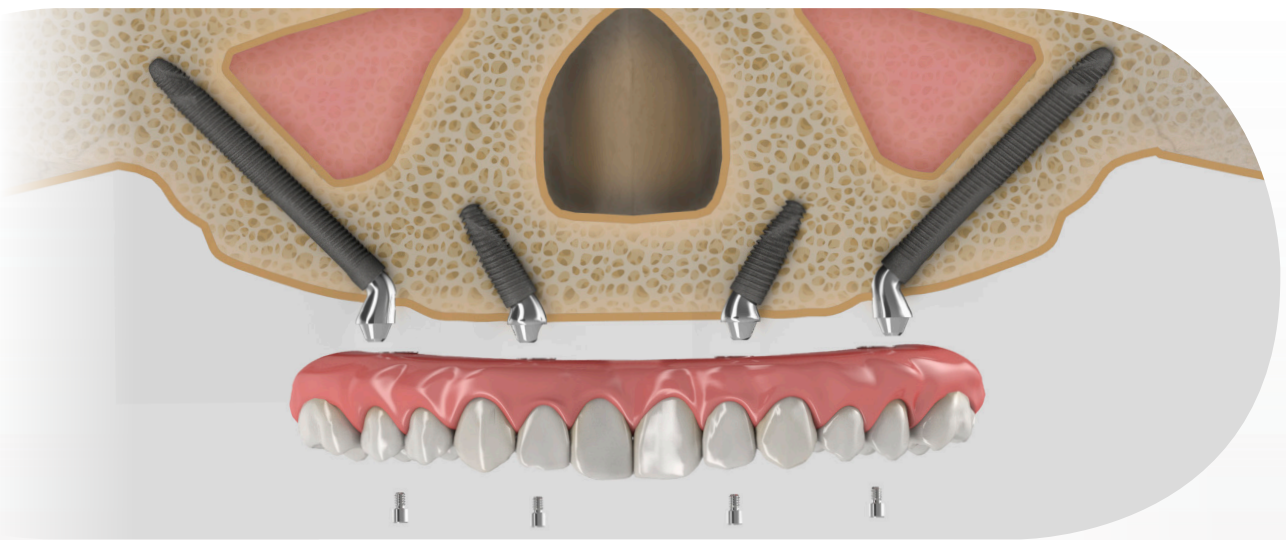


Fig 47.

GM Exact Mini Conical Abutment



	17°	30°	45°*
1.5 mm	115.249	115.252	115.267
2.5 mm	115.250	115.253	115.268
3.5 mm	115.251	115.254	

*The 45° Mini Conical Abutment is indicated for use only with Helix GM® Long and Zygoma GM™.
Table 10. GM Angled Mini Conical Abutment.

GM Angle Measurer



17°	30°	45°
128.032	128.033	128.034

Table 11. GM Angle Measurers.

COMPREHENSIVE RESTORATIVE SOLUTIONS: DESIGNED TO MEET THE PATIENTS' EXPECTATIONS

Meet patient stability and comfort expectations thanks to comprehensive custom made milled frameworks for provisional or final restoration at the abutment level using a broad range of material and any workflows.

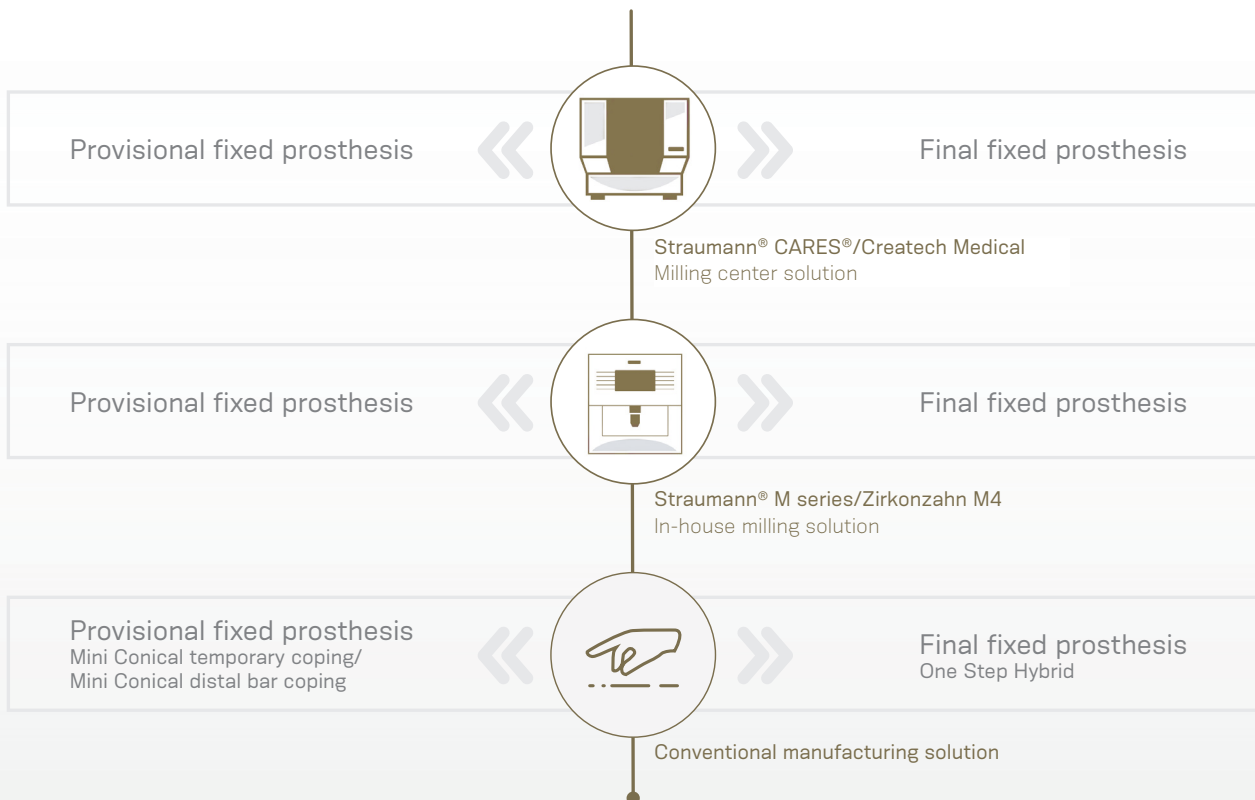


Table 12. Framework for provisional and final fixed prosthesis.

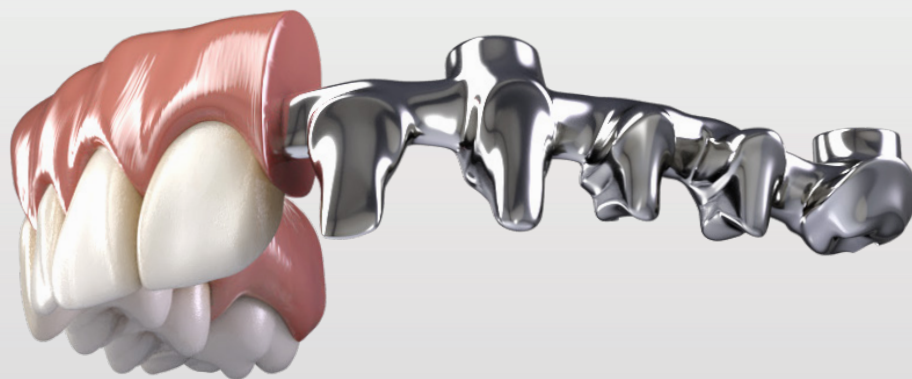

Fig 49. Illustration of final prosthesis on a milled bar.

ZYGOMA GM™ AND HELIX GM® LONG IMPLANT PACKAGING

Neodent® packaging has been specially updated for easy handling and safe surgical procedures, providing safety from implant stocking to the capture and transport to implant bed. The implant's features, such as type, diameter and length, are identifiable on the outside of the packaging.

Three self-adhesive labels are provided for recording in the patient's medical records and for reporting to the prosthesis team. They also allows traceability for all articles.

After opening the blister, note that the implant will remain attached at the lid. In order to break the base holder of the implant, hold the lid and apply a contra-torque with the GM Connection for contra-angle (a maximum torque of 20 N.cm). Or for manual installation, use the Zygoma GM™ Implant Driver with the Neo Screwdriver Torque Connection. Finish the implant placement with the aid of the Torque Wrench.



Fig 48. Instructions for opening and carrying the implant packaging.

Note: The holder is integrated to the implant body, but is designed to be removed from the blister without any apical burr.

FOLLOW-UP

Cleaning and Care

For long-term success and proper fit of the fixed bridge, comprehensive patient instruction and periodic check-ups (at least once a year) are recommended. During these visits, you should carefully examine the:

- 1. Condition of the peri-implant tissues with regard to oral diseases such as plaque and calculus, bleeding, recession, and bone loss, by taking regular periapical radiographs.*
- 2. Superstructure and prostheses occlusion, proper fit of the fixed bridge, wear of occlusal surface, retention, screw loosening, and abutment status.*
- 3. Function of the prostheses.*

Provide professional cleaning with the aid of ultrasonic or periodontal curettes, removing the prosthesis if necessary, and use cleaner prostheses agents. If a proper maintenance of the fixed restoration is provided, it is not necessary to exchange the occlusal screws at each check-up visit.

A full-arch prosthesis requires spaces for the framework and the esthetical veneering (can be either ceramic or acrylic). Also, from a functional point of view, full-arch bridges should allow for the patient's future hygiene and should never cover the remaining tissue, which will facilitate the patient's cleaning of the bridge.

For proper care at home, instruct the patient to clean the space between gingiva and fixed bridges, especially around the implants on a regular basis. Dental floss or interdental brushes are recommended.

REFERENCES

- [1] World Health Organization 2012: World Health Survey (WHS). Geneva: WHO - World Health Organization.
- [2] Agliardi E, Clericò M, Ciancio P, Massironi D. Immediate loading of full-arch fixed prostheses supported by axial and tilted implants for the treatment of edentulous atrophic mandibles. *Quintessence Int.* 2010;41(4):285-93.
- [3] Maló P, de Araújo Nobre M, Lopes A, Moss SM, Molina GJ. A longitudinal study of the survival of All-on-4 implants in the mandible with up to 10 years of follow-up. *J Am Dent Assoc.* 2011;142(3):310-20.
- [4] Babbush CA. Posttreatment quantification of patient experiences with full-arch implant treatment using a modification of the OHIP-14 questionnaire. *J Oral Implantol.* 2012;38(3):251-60.
- [5] Sartoretto SC, Alves ATNN, Zarranz L, Jorge MZ, Granjeiro JM, Calasans-Maia MD. Hydrophilic surface of Ti6Al4V-ELI alloy improves the early bone apposition of sheep tibia. *Clin Oral Implants Res.* 2017;28(8):893-901.
- [6] Maló P, de Araújo Nobre M, Lopes A, Ferro A, Gravito I. All-on-4® Treatment Concept for the Rehabilitation of the Completely Edentulous Mandible: A 7-Year Clinical and 5-Year Radiographic Retrospective Case Series with Risk Assessment for Implant Failure and Marginal Bone Level. *Clin Implant Dent Relat Res.* 2015;17(2):531-41.
- [7] Bedrossian E et al. Fixed-prosthetic Implant Restoration of the Edentulous Maxilla: A Systematic Pretreatment Evaluation Method. *J Oral Maxillofac Surg* 2008;66:112-22.
- [8] Maló P et al. The rehabilitation of completely edentulous maxillae with different degrees of resorption with four or more immediately loaded implants: a 5-year retrospective study and a new classification. *Eur J Oral Implantol* 2011;4(3):227-43.
- [9] Jensen OT, Adams MW. Secondary stabilization of maxillary m-4 treatment with unstable implants for immediate function: biomechanical considerations and report of 10 cases after 1 year in function. *Int J Oral Maxillofac Implants.* 2014;29(2):232-40.
- [10] Brunski JB. Biomechanical aspects of the optimal number of implants to carry a cross-arch full restoration. *Eur J Oral Implantol.* 2014;7(2):S111-31.
- [11] Zarb GA, Zarb FL, Schmitt A. Osseointegrated implants for partially edentulous patients. *Dent Clin North Am* 1987;31:457-472.
- [12] Balshi TJ. Single tuberosity osseointegrated implant support for a tissue integrated prosthesis. *Int J Periodontics Restorative Dent* 1992;12:345-357.
- [13] Reiger MR. Loading considerations for implants. *Oral Maxillofac Clin North Am* 1991;3:795-804.
- [14] Balshi TJ, Wolfinger GJ, Schlauch RW, Balshi SF. Brånemark system implant lengths in the pterygomaxillary region: a retrospective comparison. *Implant Dent.* 2013;22(6):610-2.
- [15] Takahashi T, Shimamura I, Sakurai K. Influence of number and inclination angle of implants on stress distribution in mandibular cortical bone with All-on-4 Concept. *J Prosthodont Res.* 2010;54(4):179-84.
- [16] Jensen OT, Cottam JR, Ringeman JL, Adams MW. Transsinus dental implants, bone morphogenetic protein 2, and immediate function for all on four treatment of severe maxillary atrophy. *J Oral Maxillofac Surg* 2012;70:141-148.
- [17] Graves S, Mahler BA, Javid B, Armellini D, Jensen OT. Maxillary all-on-four therapy using angled implants: a 16-month study of 1110 implants in 276 jaws. *Dent Clin North Am* 2011;55:779-794.
- [18] Romanos GE, Nentwig GH. Immediate functional loading in the maxilla using implants with platform switching: five-year results. *Int J Oral Maxillofac Implants* 2009;24:1106-1112.
- [19] Barewal RM, Stanford C, Weesner TC. A randomized controlled clinical trial comparing the effects of three loading protocols on dental implant stability. *J Oral Maxillofac Implants* 2012;27:945-956.
- [20] Jensen OT, Cottam JR, Ringeman JL, Adams MW. Angled dental implants placement into the vomer/nasal crest of atrophic maxillae for Allon-Four immediate function: a 2-year clinical study of 100 consecutive patients. *Oral Craniofac Tissue Eng* 2012;2:66-71.
- [21] Ivanoff CJ, Gröndahl K, Bergström C, Lekholm U, Brånemark PI. Influence of bicortical or monocortical anchorage on maxillary implant stability: a 15-year retrospective study of Brånemark System implants. *Int J Oral Maxillofac Implants.* 2000 Jan-Feb;15(1):103-10.
- [22] Stella JP, Warner MR. Sinus slot technique for simplification and improved orientation of zygomatic dental implants: a technical note. *Int J Oral Maxillofac Implants.* 2000;15(6):889-93.
- [23] Jensen OT, Adam MW, Smith E. Paranasal bone: the prime factor affecting the decision to use transsinus vs zygomatic implants for biomechanical support for immediate function in maxillary dental implant reconstruction. *The International Journal of Oral & Maxillofacial Implants.* 2014;29:e130-e138.
- [24] Agliardi, E. L., Romeo, D., Panigatti, S., de Araújo Nobre, M., & Maló, P. (2017). Immediate full-arch rehabilitation of the severely atrophic maxilla supported by zygomatic implants: a prospective clinical study with minimum follow-up of 6 years. *International journal of oral and maxillofacial surgery*, 46(12), 1592-1599.



© 2019 - JJGC Indústria e Comércio de Materiais Dentários S.A. All rights reserved.
Neodent®, Acqua®, NeoArch®, Helix®, Helix GM® Grand Morse®, Zygoma GM™, are trademarks or registered trademarks of JJGC Indústria e Comércio de Materiais Dentários S.A. Straumann®, CARES®, coDiagnostiX® are registered trademarks of Straumann Holding AG. Zirkonzahn is a trademark or registered trademark of Zirkonzahn GmbH. Createch Medical is a trademark or registered trademark of Createch Medical, S.L.
3Shape is a trademark or registered trademark of 3Shape A/S.
Dental Wings is a trademark or registered trademark of Dental Wings Inc.
Not all products could be available in all regions. Please contact your distributor for more information