

# Intraocular magnet of Parel

GERARD W CROCK, PATTABIRAMAN JANAKIRAMAN,  
AND PRADEEP REDDY

*From the Department of Ophthalmology, University of Melbourne*

**SUMMARY** The intraocular magnet (IOM) is a new device based on permanent magnetism providing controlled energy for removal of magnetic intraocular foreign bodies. Its use is reported in 11 cases.

Retained intraocular foreign bodies remain an important cause of ocular damage despite the protective counselling of medical societies, industrial unions, insurers, and manufacturers.

The surgical management of general ocular trauma entered a new era with the development of vitrectomy,<sup>1</sup> while instrumentation for the removal of non-magnetic foreign bodies progressed *pari passu*.<sup>2-4</sup> By contrast the electromagnet, which is the mainstay in removal of magnetic intraocular foreign bodies, had been little changed since the days of Herschberg.<sup>5</sup> The disadvantages of these instruments

are their bulk and clumsiness of handling, particularly if introduced within the globe<sup>6</sup> (Figs. 1 and 2).

This paper describes a new application of magnetism, as conceived by Parel, for intraocular use with or without vitrectomy techniques. Our first 11 cases of the successful removal of a foreign body by the intraocular magnet (IOM) are reported.

## Material and methods

### THE INTRAOCULAR MAGNET

The Parel magnet is composed of a rod 150 mm in length and 1.6 mm in diameter, set in a protective handle (Fig. 3). The magnetic rod is an aggregate of metallic elements, among which are rare earths. It is coated with gold, which is known to have little toxicity in the eye.<sup>7</sup>

Correspondence to Professor G W Crock, University of Melbourne, Department of Ophthalmology, Royal Victorian Eye and Ear Hospital, 32 Gisborne Street, East Melbourne, Victoria 3002, Australia.




Fig. 1 One of the authors (PR) standing beside the Haab giant electromagnet (1902) which is still to be found in the theatre suite at the Royal Victorian Eye and Ear Hospital, Melbourne. He is holding an IOM for comparison.

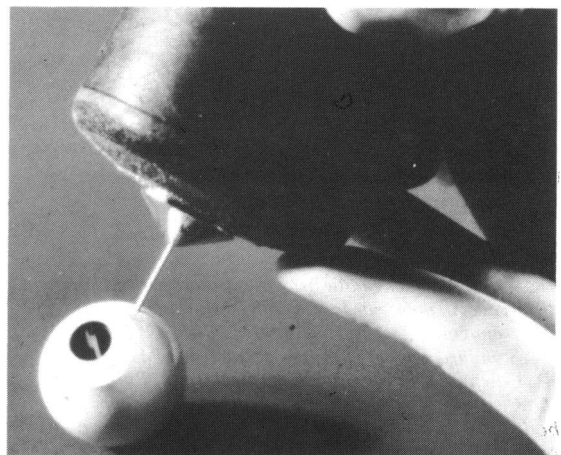


Fig. 2 Hand-held Bronson magnet with Coleman's pole tip inserted through pars plana region of a model eye.

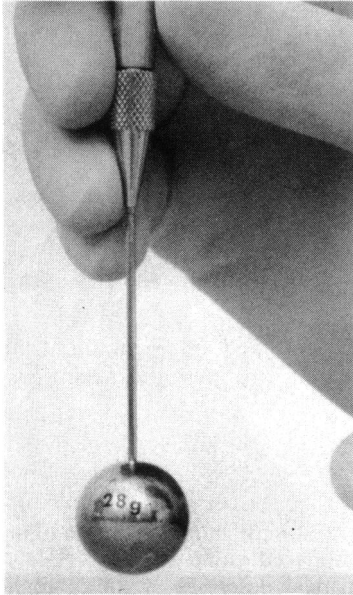


Fig. 3 The Parel intraocular Magnet (IOM) lifting a 28 g steel ball.

The surgical use of the older style electromagnets required a pole piece, usually cone shaped (Figs. 4A, B). Owing to the remoteness of its magnetic pole location (P) an electromagnet (EM) equipped either

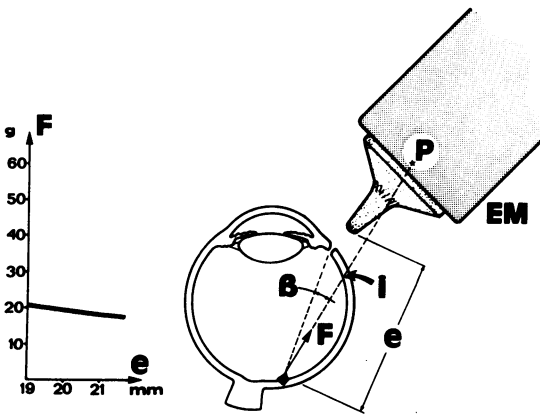


Fig. 4A

Fig. 4A, B, C Schematic drawings to compare the physical differences in magnetic forces of the traditional electromagnet (EM) and the Parel magnet (IOM). (A) Standard conical pole piece fitted to an EM. (B) Coleman's pole piece fitted to an EM. (C) Rare-earth IOM. (B) Misalignment angle resulting in secondary foreign body location at (i) (arrowed). (e) Distance between pole piece tip and foreign body. (F) Force vector applied to foreign body. (g) Grams. (i) Secondary location of foreign body. (mm) Millimetres. (P) Location of magnetic pole.

with a conical cone piece as in Fig. 4A, or with a cone extended and thinned to a 19 gauge intraocular probe (Fig. 4B), generates a feeble pull force at these tips relative to the magnetic force (F) of the main pole piece (P). Bronson went so far as to say that the pole tip has no application in foreign body surgery.<sup>5</sup>

The force-distance (F,e) graphs on the left of Figs. 4A and 4B, read in conjunction with schematic drawings, demonstrate how, in a quasi-uniform magnetic field, a non-encapsulated magnetic foreign body will accelerate rapidly. Angular misalignment (B) of these instruments by the operator can cause unintentional incarceration of the foreign body within the globe (i), with subsequent complications.

The situation of the magnetic pull force with the IOM is illustrated in Fig. 4C. As the IOM magnetic pole (P) is located at the instrument tip itself, the risk of accident from misalignment becomes insignificant. The pull force (F) varies rapidly as the distance (e)

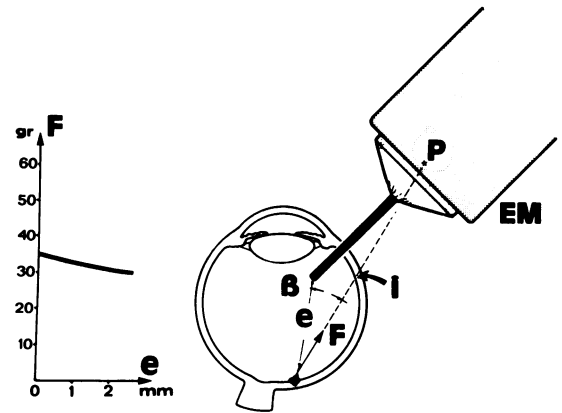


Fig. 4B

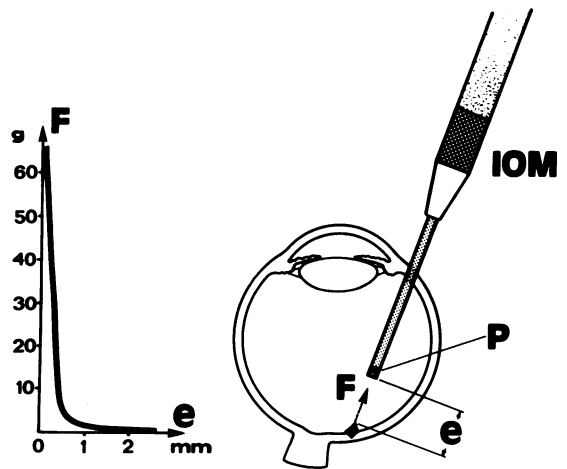


Fig. 4C

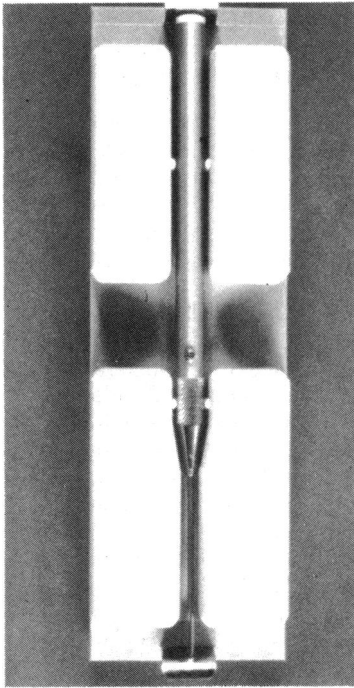


Fig. 5 The IOM in its autoclavable storage container, which slows decay of the permanent magnet.

from the magnetic object decreases. The graph on the left of the figure shows how a maximum force is obtained in contact with the foreign body. At a distance of 2 mm this force drops to zero, so that unwanted movements of intraocular magnetic foreign bodies are minimised with the IOM.

The IOM can be flash autoclaved in its storage container, which serves to slow down decay of the permanent magnet (Fig. 5). A bare IOM loses 10 to 15% of its pull force per year. When necessary, remagnetisation can be achieved readily by applying the rare earth IOM tip to the south pole of an electromagnet (EM) delivering at least 500 000 gauss. The IOM should be held to the EM central field axis with its tip touching the EM south pole piece. Remagnetisation takes less than one second.

Some of the giant EMs used in ophthalmology are capable of generating very strong magnetic fields. To utilise such ophthalmic EMs to recharge the IOM, care should be taken to: (1) Ascertain the accessible bare pole's polarity. Magnetic polarity reversal can be easily obtained by reversing the electrical current flow into the EM. The IOM will lose all its pull force if remagnetisation is attempted with an EM north pole piece. (2) Remove the usual conical pole piece and replace it with a flat one. The IOM should be held

perpendicularly and at the centre of the flat pole piece.

#### OPERATIVE TECHNIQUE

The instrument has been designed free of the encumbrances of standard electromagnets, as an adjunct to vitreoretinal microsurgery. Adequate vitrectomy should be performed before the IOM is inserted into the posterior segment of the globe. The present model has a tip diameter of 1.6 mm. Its introduction into the eye, therefore, requires some enlargement of one of the standard sized entry ports commonly used with three-port pars plana vitrectomy techniques. The port should be enlarged after the preliminary vitrectomy has been completed. When intraocular foreign bodies have a greater diameter than the IOM, the port, as in case 5, may need extensive enlargement. Under ideal circumstances the manipulation of the IOM within the eye is done through the operating microscope. When location of the foreign body precludes this, or when media opacity compromises visibility through the operating microscope, recourse may be had to binocular indirect ophthalmoscopy.

Jackson Coleman described an iron pole piece which could be inserted inside an eye (Fig. 4B).<sup>6</sup> Previously when a pole tip was applied to the eye, even through the sclerotomy site, the magnet remained external. However, with Parel's instrument it is the magnet itself which enters the eye (Fig. 4C).

The fundamental difference in clinical behaviour of these two magnetic sources lies in the fact that the magnetic pole of the IOM is located at its very tip (Fig. 4C). The magnetic field of pull is therefore virtually coaxial with the instrument probe. By contrast a powerful electromagnet, having its pole outside the eye, can exert its magnetic pull over a wide field and may impact a foreign body into the wall of the eye ([i] arrowed in Figs. 4A and 4B) at some distance from its intraocular probe, which has only a very weak magnetic pull force.

#### Case reports

*Case 1.* A 37-year-old sheet metal worker presented on 31 May 1982 one week after his left eye was injured while working with a sledge hammer. Visual acuity was 6/6. There was a scleral entry wound at 10.30 o'clock near the limbus. The lens was clear. A foreign body track was visible through the vitreous. Above the optic disc was an area of choroidal and retinal haemorrhages. Below the disc was an encapsulated metallic foreign body (Fig. 6).

A three-port vitrectomy was performed two days after admission. The vitreous track and the capsule

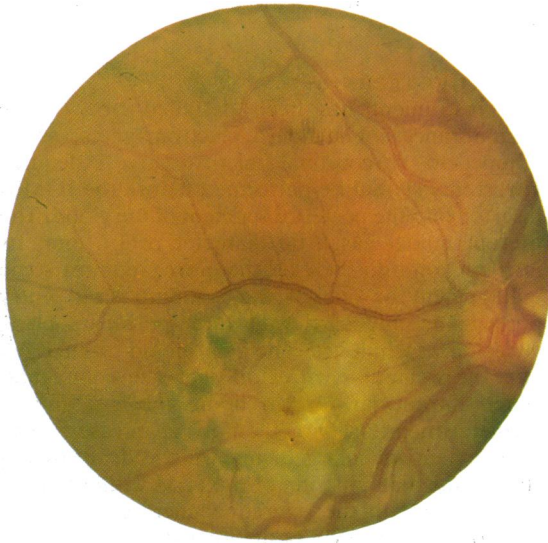

Fig. 6 The dark mass of the encapsulated intraocular foreign body is highlighted by a white rim, and lies in a circular field of retinal pigment epithelial disturbance below the optic disc. A large, circular choroidal haemorrhage is seen above and nasal to the disc, skirted by retinal haemorrhage.

overlying the foreign body were removed by the Intra Ocular Cutter (Micro-Fine Australia). The temporal port was enlarged to introduce the IOM. The foreign body was removed without incident. Postoperatively a vitreous haemorrhage developed centrally. This cleared spontaneously. When recorded on 14 June 1984, visual acuity was 6/18 and N 8, not improved with glasses, owing to posterior subcapsular lens opacity. This contrasted with a best acuity of 6/9 and N 4.5 in the early postoperative period.

*Case 2.* A 59-year-old male sheet metal worker sustained an injury to his left eye while grinding a gold-copper alloy. Fluctuating vision in this eye brought him to an ophthalmologist a year after the accident. Visual acuity was 6/6 uncorrected. There was a healed corneal scar superonasal to the visual axis and a localised traumatic cataract in the infero-temporal quadrant of the lens.

On fundus examination a foreign body could be seen in the superotemporal periphery attached to the retina by strands of vitreous, in which it lay just anterior to the retina. At operation on 25 June 1982 under binocular indirect ophthalmoscopic control the IOM was introduced through a superonasal sclerotomy 4 mm from the limbus and the tip approximated to the foreign body. Gentle manipulation freed the foreign body from the surrounding vitreous strands, and it was removed. Cryopexy was applied

to the site of vitreoretinal traction in the area of the foreign body. The postoperative course was uneventful. Pinhole visual acuity one month postoperatively was 6/5.

*Case 3.* A 29-year-old metal press worker was struck by a flying metallic particle while operating a press. A corneal entry wound was present near the lower nasal limbus. The lens was clear. The intraocular foreign body was located on the retinal surface nasal to the disc in the immediate postequatorial region. Visual acuity was 6/4. On 4 August 1982 an attempt to extract the foreign body through a lower nasal sclerotomy with an electromagnet was unsuccessful. The case was then referred.

A three-port vitrectomy was performed two days later. It was not possible to view the foreign body through the operating contact lens and microscope. Therefore the IOM was approximated to the foreign body under indirect ophthalmoscopic control. During this procedure the retina adjacent to the foreign body was accidentally struck by the IOM, resulting in a subhyaloid haemorrhage which, though limited in volume, tracked immediately into the macular area. The foreign body was removed and cryopexy was applied to the site of impaction. Postoperatively the subhyaloid haemorrhage tracked into the remaining vitreous body. Five days later total vitrectomy, fluid/gas exchange, and encircling buckle was performed. Final visual acuity on 13 June 1984 was 1/60 and N 36.

*Case 4.* A 15-year-old male was shot in the right eye by an air gun pellet of 4.6 mm diameter. Visual acuity was perception of light. Examination under anaesthesia on 23 September 1982 revealed a ragged entry wound 12 mm in anteroposterior extent beneath the insertion of the medial rectus muscle and just above the long ciliary system. The corneal epithelium was hazy. There was a microscopic hyphaema. The lens was subluxated, and there was a massive vitreous haemorrhage inferiorly. Superiorly, extensive commotio retinae was observed. A gleam from the intraocular pellet could be seen in the 7 o'clock meridian near the vitreous base.

The medial rectus was reflected from its insertion. Prolapsed uveal and retinal tissue were repositioned, and the large entry wound was closed with interrupted 8-0 nylon sutures. Then lensectomy and vitrectomy were performed through two horizontal ports. The temporal port was enlarged to introduce the IOM. The pellet was withdrawn to the pars plana after the temporal port had been further extended to deliver the foreign body through an incision, which was ultimately 6.5 mm in length circumferentially (Fig. 7). Partial fluid/gas exchange was performed after the foreign body was removed and cryopexy and buckling completed the surgery. The final visual



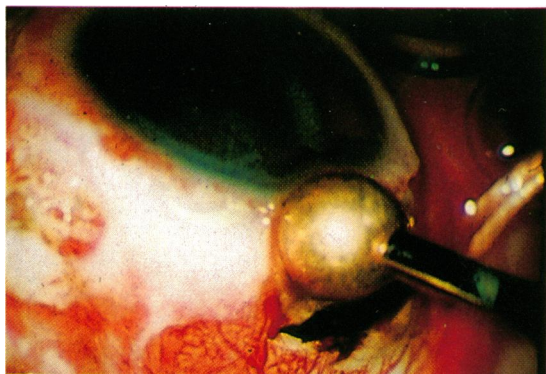


Fig. 7 Magnetic air gun pellet (4.6 mm diameter) being delivered through a 6.5 mm port in the pars plana.

acuity was hand movements. The retina was flat and the globe was hypotonic.

*Case 5.* A 22-year-old male carpenter was hammering a nail into timber. He was struck in the left eye by metallic foreign bodies, which lodged in the anterior chamber and in the vitreous base in the 6 o'clock meridian. There was a segmental traumatic cataract.

Both foreign bodies were removed by the IOM on 18 September 1982, one through the pars plana from a single port in the 2 o'clock meridian and the other through an inferior corneal section.

Two days later, because of progressive lens changes, lensectomy and vitrectomy were performed. Visual acuity on 14 June 1984 was 6/5 with a contact lens and N 5 with a +2.0 addition.

*Case 6.* A 27-year-old male sheet metal worker sustained a penetrating injury to his right eye when striking a stencil with a steel hammer. Visual acuity was 6/5. There was a corneal wound in the 3 o'clock meridian 2 mm inside the limbus. There was a hole in the underlying iris. The lens was clear. There was a patch of haemorrhage just nasal to the optic disc. X-ray localised the foreign body to be just in or behind the sclera. An attempt to remove the foreign body by electromagnet after disinsertion of the medial rectus was unsuccessful. The case was then referred on 7 December 1982.

Ultrasonography showed the foreign body to be intrascleral. One week after injury laser burns were applied around the site of the foreign body (Fig. 8). Two days later, after posterior vitreous detachment was observed, a three-port vitrectomy was performed. The temporal port was enlarged to introduce the IOM. The foreign body was removed without incident after contacting the retinal surface under operating microscope control. An encircling buckle was applied. Visual acuity was 6/4 and N 4.5 with a -4.0 sphere on 2 June 1984. The postoperative fundus appearance is shown in Fig. 9.

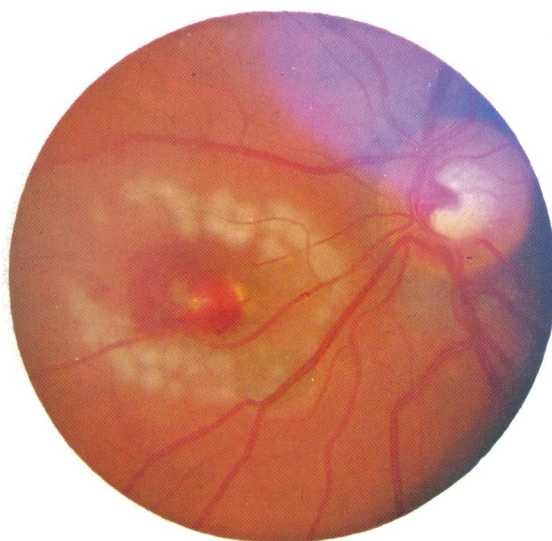


Fig. 8 Fundus photograph showing recent laser burns around a metallic foreign body embedded in retina above and nasal to the optic disc, and capped with blood.

*Case 7.* A 35-year-old male carpenter presented on 11 June 1983 with an intraocular foreign body below and nasal to the left optic disc following an injury while hammering a nail. Visual acuity was 6/12 with a pinhole. Attempted removal by hand magnet was unsuccessful. The case was then referred.

Four days later (15 June 1983) a three-port vitrectomy was performed, and the intraocular foreign body was removed through the upper temporal port with the IOM. Fluid/gas exchange, encircling buckle, and cryopexy of the foreign body impaction site completed the surgery. Visual acuity on 13 June 1984 was 6/6 with -3.0/-1.75 axis 90° and N 6 with a +1.5 sphere addition.

*Case 8.* On 1 October 1983 a 54-year-old male builder's labourer, dropped a length of steel rod and was struck in the left eye. Primary repair of a corneal laceration was carried out that day. The patient was referred on 5 October 1983 with a retained intraocular foreign body localised by radiography below the optic disc. A view of the fundus was precluded by lens opacity. A three-port lensectomy-vitrectomy was done on 6 October 1983 to reveal a small retinal tear below the disc and a larger one inferotemporally behind the equator. The intraocular foreign body was situated on the retinal surface adjacent to the large tear. The IOM was introduced through the upper nasal port and the foreign body removed. The retinal tears were frozen after fluid/gas exchange, and an encircling buckle was applied. Visual acuity recorded on 12 June 1984 had fallen from 6/6 in the early

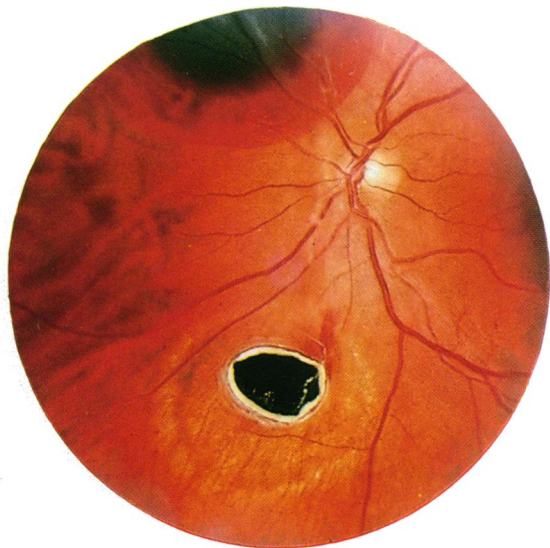


Fig. 9 Postoperative fundus photograph showing foreign body site after removal by the IOM.

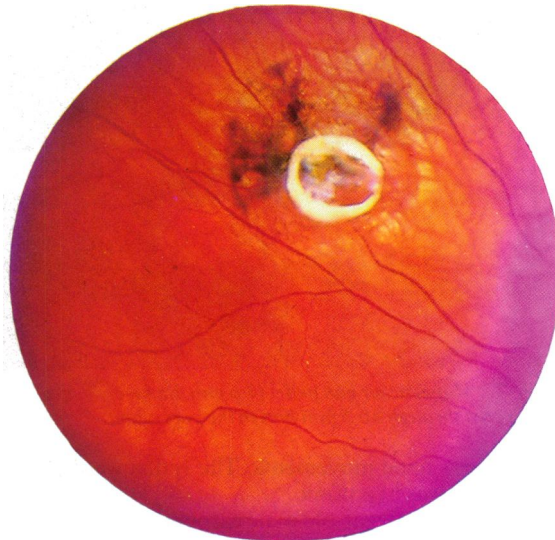


Fig. 10 Foreign body capsule remnants following uncapping and removal by the IOM of an embedded metallic fragment.

postoperative period to 6/60 due to cellophane maculopathy.

*Case 9.* On 22 October 1983 a 36-year-old housewife was hammering an iron bar. She presented on 25 October 1983 with a corneal wound, underlying lens opacity, and a foreign body which could be seen through the cloudy lens, encapsulated and lying on the retina inferonasal to the right optic disc. Visual acuity was hand movements. A three-port lensectomy-vitreotomy and foreign body removal by the IOM was performed on 28 October 1983. The capsule overlying the foreign body was nibbled away by the IOC before the IOM was inserted into the eye (Fig. 10). At review on 4 June 1984 vision was 6/9 with a contact lens and N 6 with a +3.0 addition.

*Case 10.* A 23-year-old male motor mechanic was striking a bearing with a chisel when he was hit in the right eye by a foreign body on 29 October 1983. Presenting visual acuity was 1/60. The fundus view was obscured by a shelving corneal wound and lens opacity. A foreign body was located in the mid vitreous cavity by x-ray.

On 30 October 1983 a three-port lensectomy-vitreotomy was performed, and the intraocular foreign body was removed via the upper temporal port. Fluid/gas exchange was performed without cryopexy or buckling. Vision corrected to 6/5 and N 4.5 with a contact lens in the immediate postoperative period.

He was readmitted on 17 May 1984 with an upper temporal balloon detachment and retinal dialysis.

This was treated by external drainage, cryopexy, and encirclage. Seen on 15 June 1984, his vision had corrected to 6/9 with a +11.0 dioptre sphere and N 8 with a +3.0 addition.

*Case 11.* A 21-year-old male sheet metal worker was hammering a pin when he was struck in the left eye by a foreign body, which lodged in the mid vitreous. The anterior chamber was reformed with sodium hyaluronate, then the corneal laceration was repaired with 10-0 nylon. A three-port vitrectomy was made and the foreign body removed via the upper temporal port on 13 April 1984. Six days later lensectomy, fluid/gas exchange, and encirclage were performed. On 4 June 1984 pinhole vision was 6/24. There was irregular corneal astigmatism.

## Discussion

The major application of the IOM lies in the removal of magnetic foreign bodies from the postequatorial segment of the phakic eye and from anywhere in the aphakic globe. It can be just as useful in the anterior segment, where it may be favourably combined with viscosurgery to minimise or avoid lens damage.

Eleven cases of retained magnetic intraocular foreign body have been reviewed with follow-up periods ranging from eight weeks to 23 months. All but one were in males.

Accurate localisation and adequate intraocular visibility are cardinal prerequisites to successful intervention with the IOM. If the foreign body is

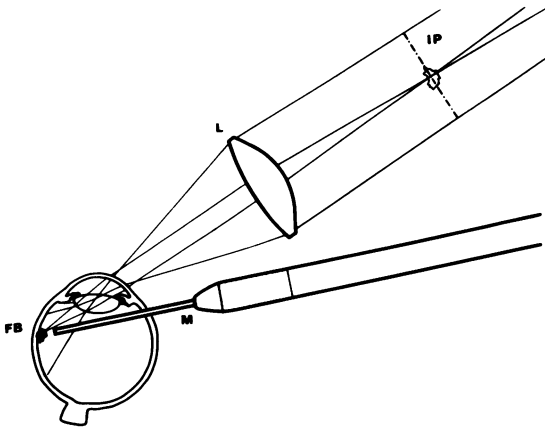


Fig. 11 Shows indirect ophthalmoscopic viewing for control of the IOM. A small (34 mm) diameter condensing lens is essential. L=lens. FB=foreign body. M=magnet. IP=image plane.

lodged outside the field of view of the operating microscope, or if haziness of the media precludes a clear view through the operating microscope, then the binocular indirect ophthalmoscope should be used. The latter method of visual control is hazardous and demands a high degree of skill. The operator must have a binocular view along the IOM so that the probe tip and the intraocular foreign body are virtually paraxial. To achieve this a small diameter (34 mm) condensing lens (Fig. 11) is mandatory.

In case 3 intraoperative concussion of the retina led to a limited preretinal haemorrhage, which tracked from its point of origin, superonasally, to the perimacular zone, with disastrous visual outcome (Fig. 12). Failure to appreciate the importance of the diameter of the condensing lens during paraxial viewing of the magnet rod against the fundus, through the binocular indirect ophthalmoscope, was responsible for this chain of events. The lens in question was of 20 dioptres with a diameter of 53 mm.

Size of intraocular foreign body has been correlated with final visual outcome.<sup>8</sup> Cases 4 and 8 bear out these statistics. The foreign body in case 4 was 4.6 mm in diameter. The massive impact resulted in phthisis bulbi. Case 8, with two retinal tears, one of which was quite large, had its final visual acuity compromised by premacular fibrosis.

Case 10 developed a retinal detachment due to dialysis within six months of removal of the intraocular foreign body. It must be assumed that the dialysis, which was found near the site of IOM introduction, had been induced by operative manipulation. We believe that limited vitrectomy and scleral buckling are desirable adjuncts to the successful removal of foreign bodies by the IOM.

The flying foreign body effect of electromagnets,

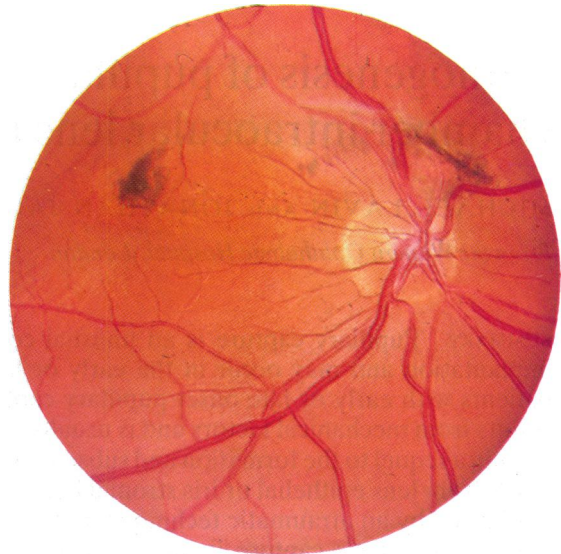


Fig. 12 Postoperative fundus photograph from case 3. The pigmented macular scar was caused by a haemorrhage which migrated from a point of retinal concussion inadvertently made with the IOM. Operator error was occasioned by use of a 53 mm diameter indirect ophthalmoscopic condensing lens.

applied at a distance from an intraocular foreign body, often resulted in further disruption of intraocular structures during surgical removal and accounted in no small part for some of the disheartening statistics reported.<sup>8</sup> Parel's application of permanent magnetism represents a significant step towards the controlled use of magnetic force in closed eye microsurgery. Further miniaturisation of intraocular magnets has already been achieved (Parel J M, personal communication).

The authors are grateful to Drs J Heinze, J Yeung, and J Reich for cases 1, 2, and 5.

Jean-Marie Parel, Director of the Ophthalmic Biophysics Center of the Bascom Palmer Eye Institute, University of Miami, invented the IOM. We are extremely grateful to him for the opportunity to have been among the first to use this instrument.

#### References

- 1 Machermer R. *Vitrectomy: a pars plana approach*. New York: Grune and Stratton, 1975: 82-5.
- 2 Neubauer H. Intra ocular foreign bodies. *Trans Ophthalmol Soc UK* 1975; **95**: 496-501.
- 3 Neubauer H. Non magnetic intraocular foreign bodies. *Bibl Ophthalmol* 1969; **80**: 1-41.
- 4 Sutherland G. Instruments for intraocular microsurgery. *Adv Ophthalmol* 1978; **37**: 39-44.
- 5 Bronson NR. Practical characteristics of ophthalmic magnets. *Arch Ophthalmol* 1968; **79**: 22-7.
- 6 Coleman DJ. A magnetic tip for controlled removal of magnetic foreign bodies. *Am J Ophthalmol* 1978; **85**: 256-8.
- 7 Sen SC, Ghosh A. Gold as an intraocular foreign body. *Br J Ophthalmol* 1983; **67**: 398-9.
- 8 Duke-Elder S. *Textbook of ophthalmology*. London: Kimpton, 1954: **6**: 6152-6.

Accepted for publication 20 February 1986.