

**Clinical Overview
and Pathogenesis
of the Fibromyalgia
Syndrome,
Myofascial Pain Syndrome,
and Other Pain Syndromes**

**I. Jon Russell, MD, PhD
Editor**



**The Haworth Medical Press
An Imprint of
The Haworth Press, Inc.,
New York • London**

Published by

The Haworth Medical Press, 10 Alice Street, Binghamton, NY 13904-1580 USA

The Haworth Medical Press is an imprint of The Haworth Press, Inc., 10 Alice Street, Binghamton, NY 13904-1580 USA.

Clinical Overview and Pathogenesis of the Fibromyalgia Syndrome, Myofascial Pain Syndrome, and Other Pain Syndromes has also been published as *Journal of Musculoskeletal Pain*, Volume 4, Numbers 1/2 1996.

© 1996 by The Haworth Press, Inc. All rights reserved. No part of this work may be reproduced or utilized in any form or by any means, electronic or mechanical, including photocopying, microfilm and recording, or by any information storage and retrieval system, without permission in writing from the publisher. Printed in the United States of America.

The development, preparation, and publication of this work has been undertaken with great care. However, the publisher, employees, editors, and agents of The Haworth Press and all imprints of The Haworth Press, Inc., including The Haworth Medical Press and Pharmaceutical Products Press, are not responsible for any errors contained herein or for consequences that may ensue from use of materials or information contained in this work. Opinions expressed by the author[s] are not necessarily those of The Haworth Press, Inc.

Library of Congress Cataloging-in-Publication Data

Clinical overview and pathogenesis of the fibromyalgia syndrome, myofascial pain syndrome, and other pain syndromes / I. Jon Russell, editor.

p. cm.—(Journal of musculoskeletal pain ; v. 4, no. 1/2)

Includes bibliographical references and index.

ISBN 1-56024-833-5

1. Fibromyalgia. 2. Myofascial pain. I. Russell, I. Jon. II. Series.

[DNLM: 1. Fibromyalgia. 2. Myofascial Pain Syndromes. 3. Pain. 4. Chronic Disease.

W1 JO775RK v.4, no. 1/2 1996 / WE 544 C6408 1996]

RC927.3.C56 1996

616.7'4-dc20

DNLM/DLC

for Library of Congress

96-7347

CIP

Chronic and Recurrent Muscle Pain: Pathophysiology and Treatment, and Review of Pharmacologic Studies

David R. Hubbard, Jr.

SUMMARY. Objectives: To review pharmacologic studies using needle electromyographically [EMG]-guided injection of trigger points [TrPs] in patients with myofascial pain syndromes.

Results: The alpha-adrenergic antagonists phentolamine and phenoxybenzamine eliminate EMG spike activity recorded by needle EMG in the nidus of TrPs and significantly reduce subjective report of pain arising in TrPs.

Conclusion: A specific pathophysiological abnormality has been identified by two-channel needle EMG in patients with chronic and recurrent muscle pain associated with TrPs. An objective diagnostic

David R. Hubbard, Jr., MD, is Associate Clinical Professor of Neurology, University of California, San Diego, and Medical Director, Pain Rehabilitation Services, Sharp HealthCare, San Diego, CA.

Address correspondence to: David Hubbard, MD, Sharp Pain Rehabilitation, 2999 Health Center Drive, San Diego, CA 92123.

The valuable help of Gregory Berkoff, DC, Richard Gevirtz, PhD, Roger Marchand, PhD, and many graduate and medical students, especially Dawn Bravata, MD, Walt McNulty, PhD, Carol Lewis, PhD, and Karen Schoenfeld-Smith, PhD, is gratefully acknowledged. Parenteral phenoxybenzamine was provided for this research by SmithKline Beecham under Dr. Hubbard's investigator-sponsor IND. Intramuscular phenoxybenzamine is now under commercial development by Myo Tech, Inc., of which Dr. Hubbard is scientific officer.

[Haworth co-indexing entry note]: "Chronic and Recurrent Muscle Pain: Pathophysiology and Treatment, and Review of Pharmacologic Studies." Hubbard, David R., Jr. Co-published simultaneously in *Journal of Musculoskeletal Pain* (The Haworth Medical Press, an imprint of The Haworth Press, Inc.) Vol. 4, No. 1/2, 1996, pp. 123-143; and: *Clinical Overview and Pathogenesis of the Fibromyalgia Syndrome, Myofascial Pain Syndrome, and Other Pain Syndromes* (ed. I. Jon Russell) The Haworth Medical Press, an imprint of The Haworth Press, Inc., 1996, pp. 123-143. Single or multiple copies of this article are available from The Haworth Document Delivery Service [1-800-342-9678, 9:00 a.m. - 5:00 p.m. (EST)].

test has been developed which distinguishes these patients from normal subjects. Electromyographically-guided TrP phenoxybenzamine injection promises lasting treatment for this common but misunderstood condition. [Article copies available from The Haworth Document Delivery Service: 1-800-342-9678.]

KEYWORDS. Trigger points [TrPs], sympathetic antagonists

INTRODUCTION

Chronic and recurrent muscle pain is the second most common medical condition after upper respiratory illness. Ten to twenty percent of the American population, over 44 million persons 18 years of age and older, are affected (1,2). Patients with these conditions make 70 million visits to physicians (3,4) and 425 million visits to chiropractors and other alternative health care providers each year (5) at an annual cost of \$47 billion (1). It is the single largest diagnostic group in chronic pain clinics, accounting for 85% of pain clinic populations (6).

Patients with muscle pain carry many different diagnostic labels, including muscle strain, whiplash, repetitive overuse syndrome, fibromyalgia, myofascial trigger point pain syndrome, tension headache, and low back syndrome. Many patients with pain of muscular origin are misdiagnosed with other conditions including degenerative spine disease, degenerative disc disease, tendonitis, arthritis, bursitis, carpal tunnel syndrome, and temporomandibular joint syndrome [TMJ]. Not surprisingly these patients utilize many invasive procedures, especially nerve blocks, back surgeries, and implantable devices. Fifteen to 30% of back surgeries have a poor outcome, primarily due to misdiagnosis of muscle pain as disc disease (7,8).

The reason for misdiagnosis and often ineffective treatment has been the absence of an objective method of diagnosis or proven pathophysiology. Laboratory studies such as x-ray, computerized tomography [CT], magnetic resonance imaging [MRI], and blood tests are normal. Routine clinical electromyography [EMG] and nerve conduction studies are also normal (9). Needle EMG studies of patients with chronic muscle pain have yielded negative or

equivocal results (10,11,12). Histological and biochemical examination of painful muscles including trigger points [TrPs] have shown no specific abnormalities (13,14).

The routine neurological examination of patients with chronic muscle pain is normal; their reflexes, classic sensory testing, and strength are normal. Muscle palpation, while not considered part of the routine neurologic exam, typically reveals the subjective complaint of tenderness, although neurologists have not traditionally considered this an objective sign. Nevertheless, careful examination of patients with true muscle pain typically reveals TrPs. This term was first popularized in the United States by Travell (15) and is now in common usage (16,17). While a detailed description of TrP examination can be found elsewhere (18), the essential phenomenon is muscle tenderness which is not diffuse throughout the muscle but rather is exquisitely localized to an area which has a firm consistency to deep palpation. Trigger point identification requires considerable training, inter-rater reliability has been problematic, and no objective pathophysiological abnormality has been identified (18).

Using a novel two-channel needle EMG method, it has been demonstrated that the 1-2 mm nidus of TrPs, identified according to Travell and Simons (18), contains actively-firing muscle fibers, while adjacent muscle fibers remain electrically silent. The active TrPs of patients with muscle tension headache and fibromyalgia showed significantly greater needle EMG activity than latent trigger points of normal controls (19). It was hypothesized that this localized needle EMG activity arises from sympathetically-mediated hyperactivity of the intrafusal muscle fibers of muscle spindles in the nidus of TrPs. Since then it has also been demonstrated that this trigger point needle EMG hyperactivity is significantly increased by laboratory stressors in both normal subjects (20), and patients with tension-type headache (21). Further pharmacological pilot studies are summarized here.

METHOD

Patients referred to the Pain Rehabilitation Services at the Sharp Rehabilitation Center or the Neurological Center for Headache and Pain in La Jolla were evaluated by the medical director, a board-cer-

tified neurologist. Histories and neurological examinations were done and all patients completed pain drawings. Informed consent was obtained and the studies were approved by the Institutional Review Board of the medical center.

Inclusion criteria:

1. The pain drawing showed a myofascial distribution as described by Travell and Simons (18).
2. Myofascial TrPs were identified according to the criteria of Travell and Simons (18). All patients had localized, 1-3 cm areas of firmness and tenderness to palpation with characteristic referral patterns of pain. Many, but not all, patients had localized twitch responses.

Patients with areas of tenderness meeting the criteria for fibromyalgia (22) were included only if they also had TrPs according to the Travell and Simons criteria. Patients were asked to take no analgesics, muscle relaxants, or anti-coagulants for 24 hours prior to injection.

3. Deep pressure on the TrP partially or completely reproduced the clinical pain complaint.

Exclusion criteria:

1. The pattern of pain was in a radicular or neuropathic distribution.
2. The pattern of pain was in a facet, shoulder, or sacroiliac joint distribution.
3. Examination demonstrated diffuse tenderness without palpable discrete TrPs.

Clinical diagnoses included myofascial pain syndrome, tension-type headache with pericranial muscle involvement, and fibromyalgia. Muscles studied included the trapezius, suboccipitalis, splenius capitis, supraspinatus, latissimus dorsi, quadratus lumborum, gluteus medius, sternocleidomastoid, and pectoralis.

Of note, patients who were narcotic dependent, in litigation, or on disability were not excluded.

The most tender TrPs were then identified, marked with silver nitrate sticks dipped in india ink, and photographed with a Polaroid

camera. No more than six TrPs were chosen at a time. Patients were then scheduled for the TrP procedure within two weeks.

For the procedure, each patient was positioned in a special chair used by massage therapists. The chair allows patients to rest comfortably while head, trunk, and leg supports facilitate mild stretch of the muscles to be injected. Using the Polaroid picture as a reference, a select TrP was re-identified by palpation and a TECA monopolar needle EMG was inserted through the skin. A second needle was inserted into adjacent non-tender muscle to monitor for voluntary motor unit contractions. A surface electrode was placed between the two needles to serve as reference for both. A ground electrode was also placed on the skin. Using either a Cadwell Quantum 84 [Kennewick, WA] or a specially modified PDS I-410 [I&J, Paulsbo, WA], two channels of needle EMG activity were recorded at gain 100, sweep 100 msec, low pass 30, high pass 1000 at 10,000 samples per second. The TrP needle was gradually advanced until the patient reported characteristic TrP pain and the screen showed the characteristic high-voltage EMG activity. If the second EMG channel indicated guarding or splinting [an interference pattern], the patient was encouraged to relax the muscle until the channel became quiet again.

The following criteria were used to determine when the trigger point nidus was contacted: Activity in the adjacent channel remained quiet [root mean square of needle EMG activity typically less than 10 microvolts], while the needle EMG activity of the TrP showed continuous high-voltage spike activity [root mean square typically greater than 20 microvolts]. The TrP needle EMG activity also needed to be sustained to distinguish it from "insertional activity," which is a brief burst of EMG activity whenever an EMG needle is moved through muscle tissue (9). Once the criteria were met, a 25-gauge hypodermic syringe was inserted beside the trigger point EMG needle, advanced to the same depth, and the pharmacological agent was slowly [over 1-2 seconds] injected. The injection of fluid was typically associated with the patient's report of increased pain. The procedure was repeated for up to six TrPs.

Using this two-channel TrP needle EMG method described above, different agents and routes of administration were studied.

RESULTS BY PROTOCOL

Study 1—Intramuscular Phentolamine

Subjects: Four normal subjects with latent TrPs and seven patients with tension headache associated with active TrPs in the trapezius were studied. The normal subjects included two men, ages 27 and 43, and two women, ages 24 and 40. The muscle tension headache patients were two women, ages 28 and 51, and one man, age 36. None of the subjects were taking preventive medications and none had taken any medication, including analgesics, within three days. In addition, none of the subjects had other medical problems.

Pharmacological agent: Ten mg of phentolamine in one cc of normal saline.

Route of administration: EMG-guided intramuscular TrP injection.

Results: Local injection produced a rapid reduction of TrP needle EMG activity. This reduction was maximal at 20-30 minutes. In three of the four studies, the EMG activity returned within 40 minutes. The reduction affected both amplitude and frequency of the trigger point EMG [TrP-EMG] activity. The EMG activity in the adjacent non-tender site did not change. Figure 1 shows the progressive reduction and return of TrP activity in a normal subject. The top tracing is prior to phentolamine injection and each subsequent tracing is at five-minute intervals after injection. Only the TrP-EMG tracings are presented since non-tender site tracings remained silent. Figure 2 shows the TrP-EMG changes in a normal subject. The left frame shows the TrP and non-tender EMG activity before phentolamine. At 20 minutes after sympathetic blockade [middle frame] the TrP-EMG activity is virtually indistinguishable from the adjacent non-tender site activity. At 40 minutes [right frame] the TrP activity has partially returned. Figure 3 presents the phentolamine responses from a chronic tension headache patient. Note that the gain in the patient tracings is half that of the normal subject tracings. At 30 minutes [middle frame] the activity is reduced but still present. At 50 minutes [right frame] the TrP activity has returned. The mean and standard deviation [SD] of mean EMG amplitude before and five minutes after the injections in all seven subjects were 27.71 [8.24] and 10.99 [3.67] respectively for the TrP, and 5.49 [1.32] and 3.84 [1.08] respectively for the adjacent normal muscle.

FIGURE 1. Trigger point electromyographic activity recorded from the latent trigger point in the trapezius muscle of a normal subject before [top tracing] and at five-minute intervals after [next seven tracings] local injection of phentolamine. [Note gain is twice that used to record active trigger points in patients.]

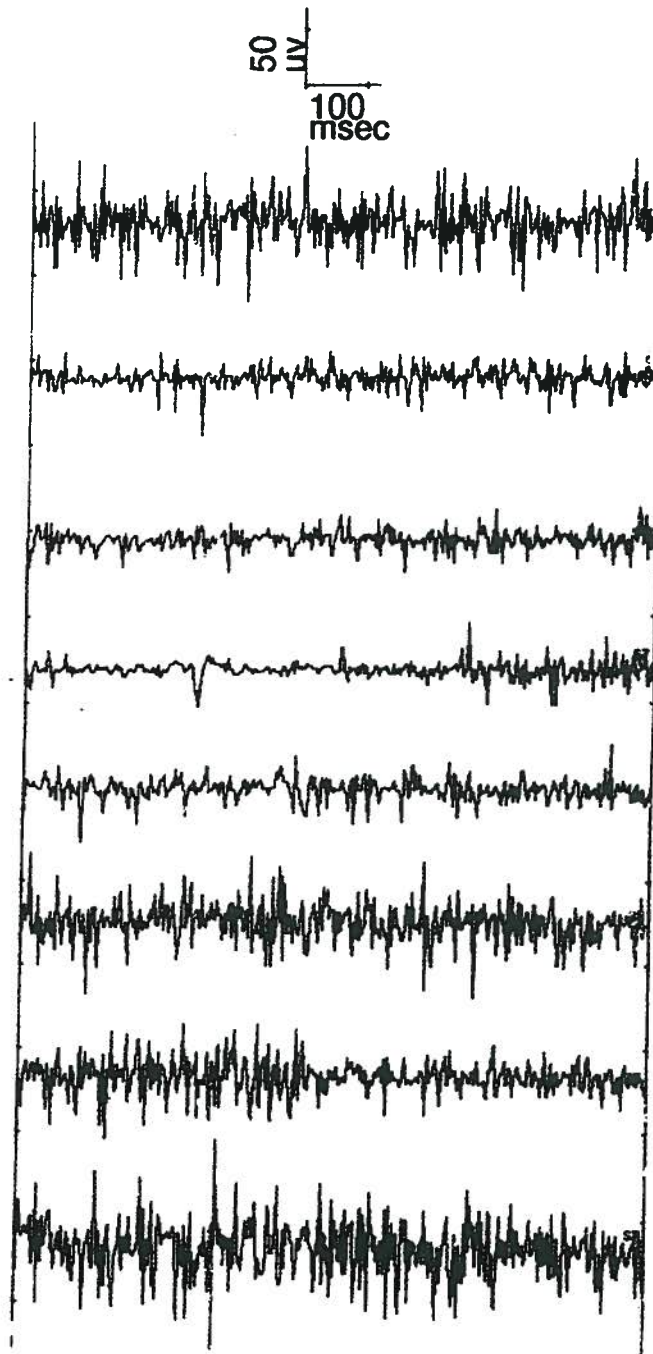



FIGURE 2. Needle electromyographic activity from the trigger point [upper tracing] and the adjacent non-tender muscle fibers [lower tracing] from a latent trigger point in the trapezius of a normal subject before [left frame], at 20 minutes after [middle frame], and at 40 minutes after [right frame] local injection of phentolamine. [Note gain is twice that used to record active trigger point in patients.]



Study 2—Intramuscular Curare

Subjects: Two subjects, a 43-year-old man and a 29-year-old woman, both with tension headache associated with myofascial TrPs in the trapezii were studied. Neither of the subjects was on medication or had other medical problems.

Pharmacological agent: Tubocurarine [Lilly] 0.6 mg in 1.0 cc of 0.9% saline.

Route of administration: EMG-guided intramuscular TrP injection.

Results: In these two subjects, the curare had no effect on either amplitude or frequency of the TrP-EMG activity or the adjacent non-tender muscle fibers. The response in one of the subjects before injection [left frame], and at five minutes [middle frame], and 12 minutes [right frame] after injection is shown in Figure 4.

Study 3—Intravenous Phentolamine

Subjects: Two subjects, a 36-year-old man and a 31-year-old woman, with myofascial TrP pain syndromes. The man had an active TrP in the right brachioradialis muscle, while the woman had an active TrP in the left trapezius.

Pharmacological agent: Phentolamine 10 mg in normal saline.

Route of administration: Intravenous infusion over 12 minutes by indwelling intravenous line in a single-blinded manner.

FIGURE 3. Needle electromyographic activity from the trigger point [upper tracing] and the adjacent non-tender muscle fibers [lower tracing] from an active trigger point in the trapezius of a muscle tension headache patient before [left frame], at 20 minutes after [middle frame], and at 40 minutes after [right frame] local injection of phentolamine.

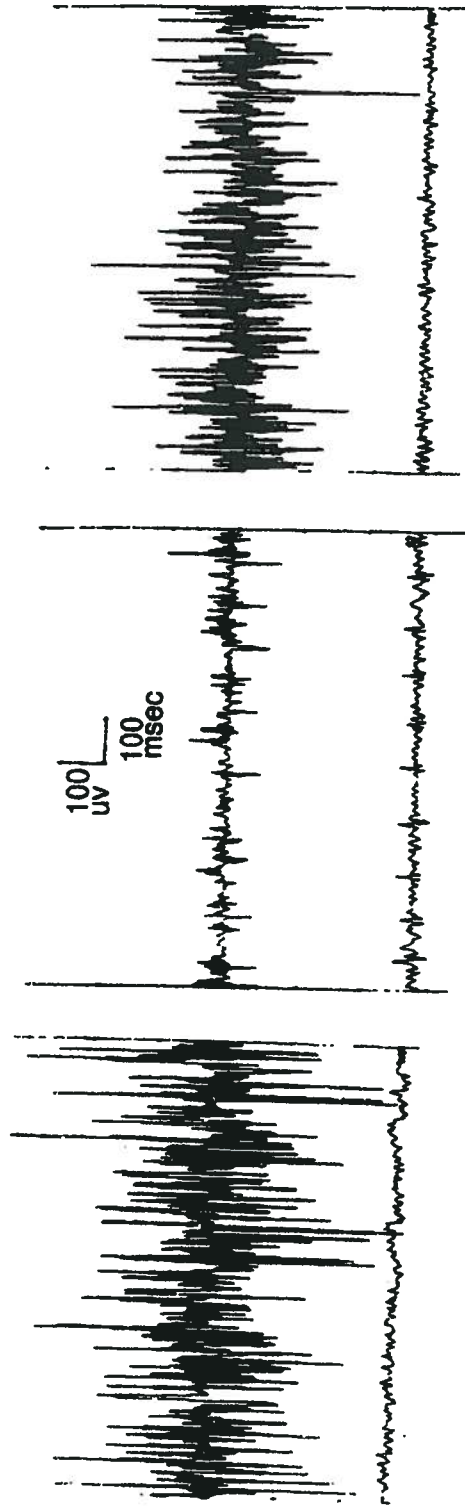
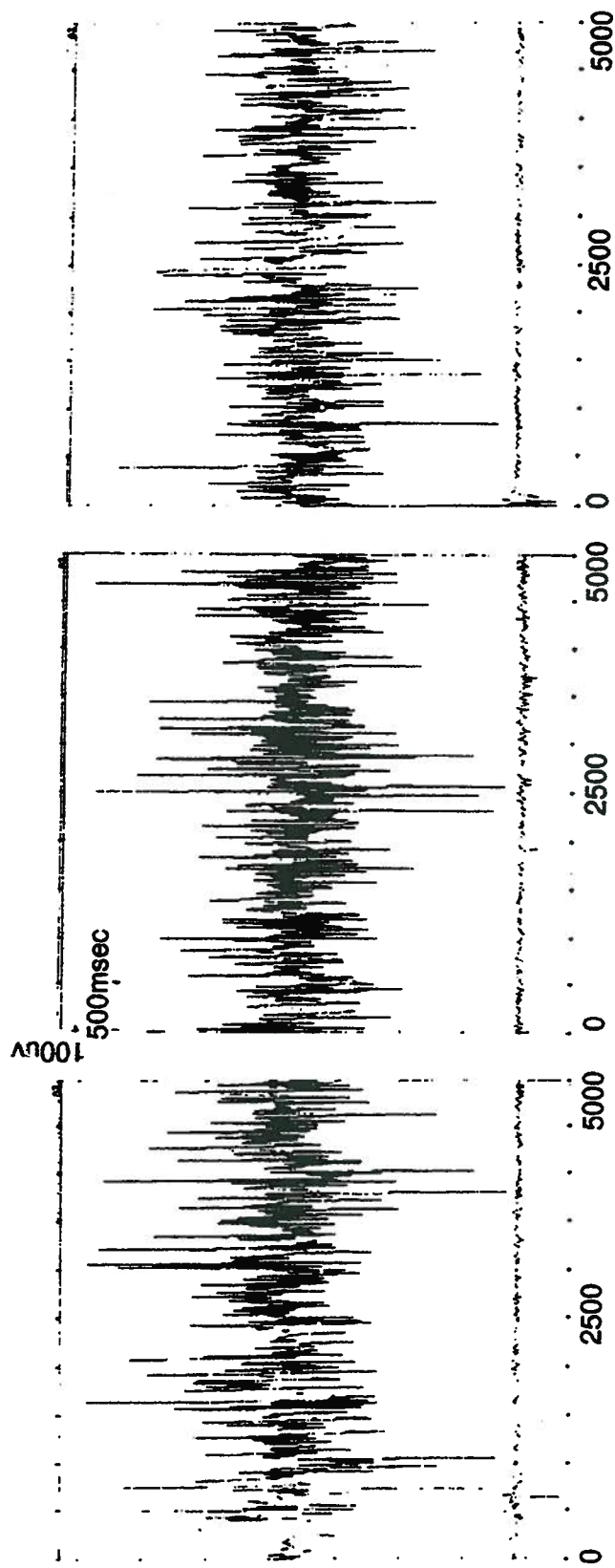


FIGURE 4. Needle electromyographic activity from the trigger point [upper tracing] and the adjacent non-tender muscle fibers [lower tracing] from an active trigger point in the trapezius of a muscle tension headache patient before [left frame], at five minutes after [middle frame], and at 12 minutes after [right frame] local injection of curare.



Results: In both subjects, the TrP-EMG activity was eliminated during the infusion. The response in one of the subjects before [left frame], during saline infusion [middle frame], and during the phentolamine infusion [right frame] is shown in Figure 5. As can be seen, saline infusion had no effect on TrP-EMG activity, whereas phentolamine infusion caused complete blockade.

Study 4—Phenoxybenzamine, Single Injection, 25 mg

Subjects: Sixteen patients with myofascial pain were treated with a single injection of phenoxybenzamine in an active TrP. The mean age was 51, with a range between 33 and 72 years of age. Four of the patients were male and 12 were female. Half of the patients received their injection in the right side and half received their injection in the left side.

Pharmacological agent: Phenoxybenzamine 25 mg in 2 cc of normal saline.

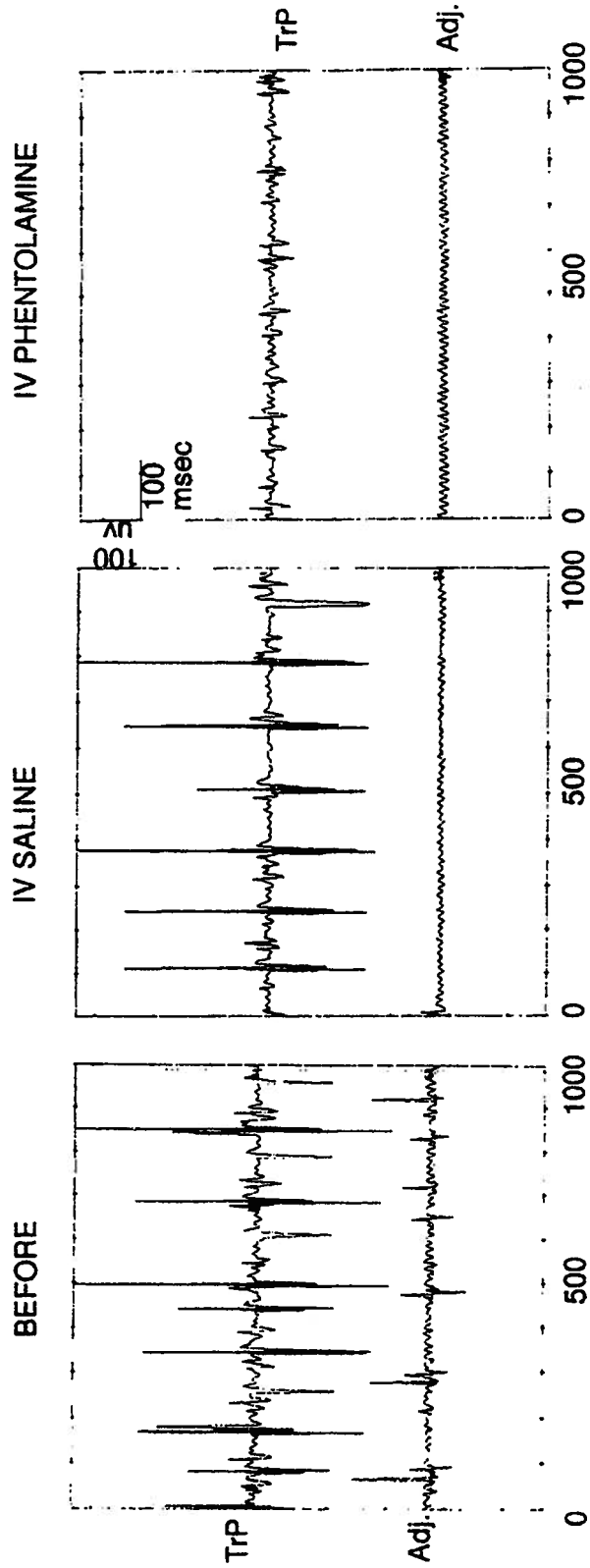
Route of administration: EMG-guided intramuscular TrP injection.

Pain rating: Patients were asked to keep visual analog daily diaries of pain severity for one week prior and for one week per month for four months after treatment. Percent improvement was calculated by subtracting the mean post-injection VAS scores from the mean pre-injection VAS scores and dividing by the mean of the pre-injection score. Each patient's improvement score was then categorized into 75 to 100% improved, 50 to 74% improved, 25 to 49% improved, unchanged, or worsened. Patients were also asked to keep track of adverse events.

Results: Three patients failed to complete their pain diaries over the four-month follow-up period. Percent of patients whose visual analog scale [VAS] ratings showed 25-100% lessening of pain is as follows: at one week 40%, at one month 57%, at two months 66%, at four months 53%.

The dose of phenoxybenzamine used caused significant local tissue irritation and swelling which, although self-limited, was quite painful. Seven of 16 patients reported 12 injection site soreness with a median onset of 12 hours post-injection and a median duration of 39.5 days.

FIGURE 5. Needle electromyographic activity from the trigger point [upper tracing] and the adjacent non-tender muscle fibers [lower tracing] from an active trigger point in the trapezius of a muscle tension headache patient before [left frame], during intravenous infusion of saline [middle frame], and during intravenous infusion of phentolamine [right frame].



Study 5—Phenoxybenzamine, Single Injection, 10-12.5 mg

Subjects: Eight patients with myofascial pain were treated using a single injection of phenoxybenzamine in an active TrP. The mean age of the patients was 44.8, with a range between 29 and 71 years of age. Two males and six females were treated. Two patients were treated on the left side and six treated on the right. There were two dropouts at follow-up month 2, and four dropouts at follow-up month 4.

Pharmacological agent: Phenoxybenzamine 10-12.5 mg in 0.5 cc normal saline.

Route of administration: EMG-guided intramuscular TrP injection.

Pain rating: Same as Study 4.

Results: Percent of patients whose VAS diary ratings showed 25-100% improvement was 50%, 83%, and 100% at 1, 2, and 4 months respectively.

Two patients reported injection site irritation with a median onset of 4.3 days post-injection lasting a median of 13 days.

Study 6—Phenoxybenzamine, Multiple Injections

Subjects: Eighty-four myofascial pain patients received up to six Trp injections of phenoxybenzamine in a single treatment session. The mean age of the patients was 52.2 years, with a range between 24 and 80 years of age. Fifty-nine patients were female and 25 were male. Eighty-four percent of the patients had head and neck TrPs; nine percent had head, neck, and arm TrPs; and seven percent had lower back TrPs. Forty-four percent of the patients had the left side treated and 56% had the right side treated.

Pharmacological agent: Phenoxybenzamine 10-12.5 mg in 0.5 cc normal saline.

Route of administration: EMG-guided intramuscular TrP injection in up to six TrPs in one treatment session.

Pain rating: Same as studies 4 and 5.

Results: The percent of patients whose VAS diary ratings showed 25-100% improvement was 52%, 68%, 66%, and 63% at 1, 2, 3, and 4 months respectively.

Thirty-four patients [51%] reported injection site irritation with a median onset of 24 hours post-injection lasting a median of 15.5

days. In two of these patients the injection site swelling persisted for three months, at which time they were biopsied and found to contain subcutaneous fat necrosis. Another patient had transient bleeding from the injection site and several days later developed a localized skin infection requiring a course of oral antibiotics.

Study 7—EMG-Guided Biopsy of a TrP

Subject: A 35-year-old woman who was scheduled for a cervical rib resection for thoracic outlet syndrome agreed to participate. She had previously been examined and diagnosed with myofascial pain affecting her cervical and shoulder girdle muscles in addition to the thoracic outlet syndrome. A right cervical rib was present on x-ray. Informed consent was obtained. Prior to surgery, a myofascial TrP in the right trapezius was localized by the TrP needle EMG procedure. While the electrodes remained in place, the TrP electrode was disconnected from the preamplifier and attached to an 18-volt direct current source through which 60 microamps of current were passed for 35 seconds [approximately 0.0021 Coulombs]. The goal was to deposit ferric ions in the tissue to mark the position of the needle tip. Following this, a 21-gauge, two-inch hypodermic syringe was inserted beside the probe needle, advanced to the same depth, and 0.25 cc of clinical grade methylene blue was injected to mark the EMG recording site.

Ninety minutes later the patient underwent surgical resection of the right cervical rib. The skin incision was made from the mid-clavicle to within one cm of the probe needle skin penetration site. The neurosurgeon dissected into the trapezius and identified the methylene blue-stained muscle tissue. The ends of the stained tissue were clamped, the tissue excised, and immersed in Bouin's fixative. Following fixation the tissue was dehydrated and prepared for paraffin sectioning. Seven micrometer serial sections were cut and every seventh section was mounted on a glass slide for staining. Two sets of slides were prepared. One set was subjected to routine hematoxylin and eosin staining. The second set was first immersed in a 10% aqueous solution of potassium ferrocyanide and then incubated at 37 degrees centigrade in a solution made up of equal parts of 20% hydrochloric acid and 20% potassium ferrocyanide.

After incubation, the slides were counterstained using a modified Van Gieson connective tissue stain (23,24).

Results: The two-channel needle EMG demonstrated sustained 300-500 microvolt activity from the biopsy site and simultaneous electrical silence from the adjacent muscle fibers of the trapezius muscle [Figure 6], consistent with previous studies. The methylene blue-stained muscle fibers were found in the right upper trapezius, approximately halfway between the C7 spinous process and acromion process, and 2.5 cm below the skin surface. The biopsy specimen measured 5 mm in length and 3 mm in diameter [0.035 cubic millimeters]. The specimen contained a single muscle spindle with two nuclear bag fibers and four nuclear chain fibers [Figure 7]. There was no evidence of inflammation or other histopathology. No ferric ion deposit was found.

Study 8—Phenoxybenzamine, Multi-Injection, 38 mg

Subjects: Twenty patients with myofascial pain received up to six TrP injections of phenoxybenzamine in one or two sessions, average of four. Ages ranged from 22 to 70; 65% were women.

Pharmacologic agent: Phenoxybenzamine, 3 mg in 0.3 cc.

Route of administration: EMG-guided intramuscular TrP injection.

Pain rating: Experience with the visual analog rating system showed that patients had difficulty understanding it, and applied it in variable ways both between subjects and over time, especially at intervals greater than one week. For this study, patients were asked to rate "percent change," worse or better, of 1. the injected TrPs, 2. the quadrant of the body. For example, a typical patient rated the change in the three or four TrPs injected in the right trapezius and sternocleidomastoid and then the change of the entire right upper back and head.

The mean improvement for the injected TrPs was 78%, median 88%, and the mean improvement for the quadrant treated was 71%, median 80%, at two and four months follow-up for the 20 patients studied.

Adverse events were limited to brief pre-syncopal symptoms at the moment of injection in 15% and to injection site soreness in 85%, which lasted an average of eight days and was disabling [e.g., stayed home from work] in two patients [20%].

DISCUSSION

Using a two-channel needle EMG method, high-voltage [100-900 microvolt], short-duration [1-3 msec] spike activity has been identified within the 1-2 mm nidus of muscle TrPs, while adjacent non-

FIGURE 6. Two-channel monopolar needle electromyographic recording contrasting electrical activity between the trapezius muscle biopsy site [upper tracing] and adjacent muscle fibers of the same muscle [lower tracing].

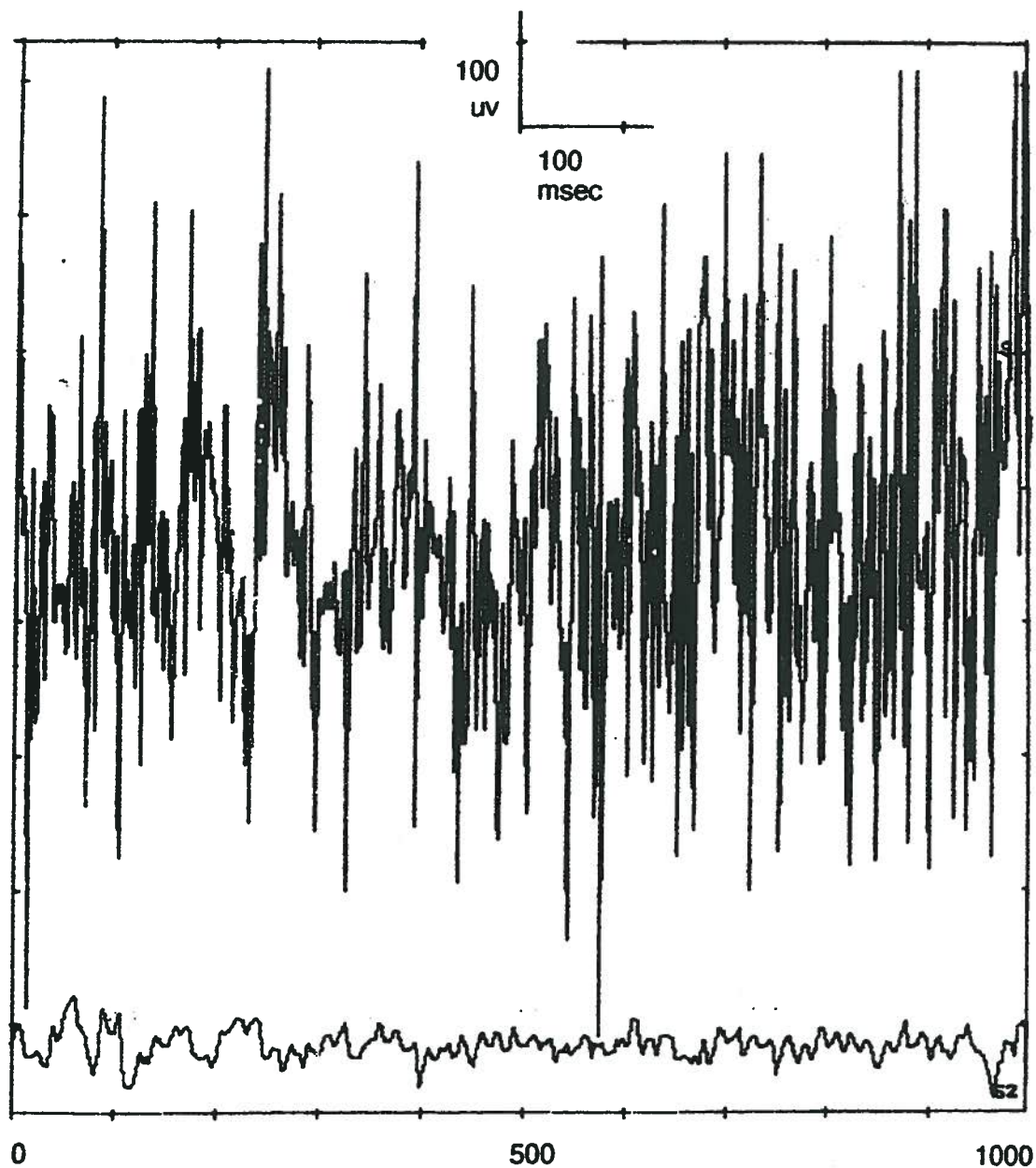
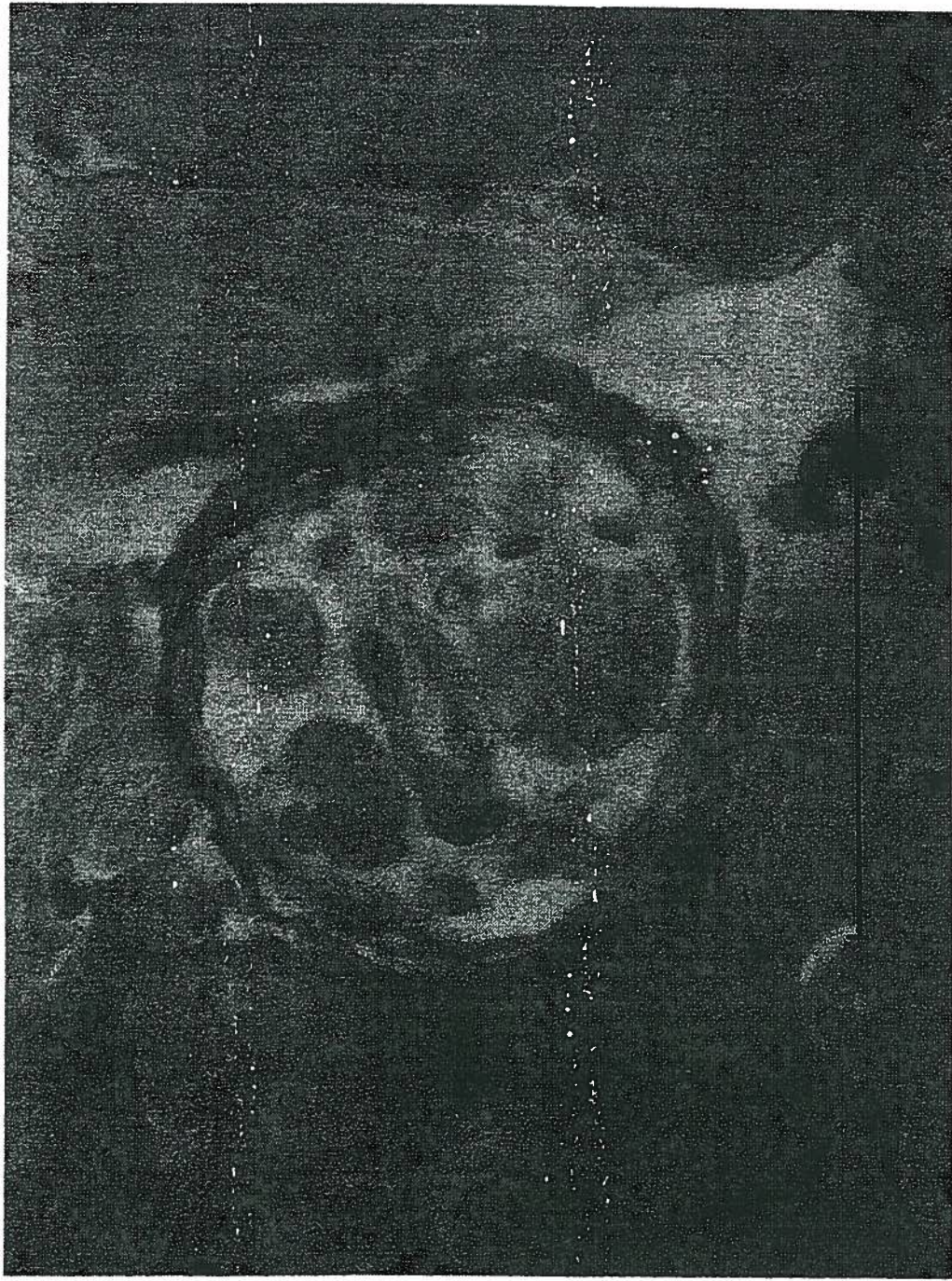


FIGURE 7. Photomicrograph of a cross section of the muscle spindle found in the electromyographically-guided trapezius biopsy specimen. Van Gieson stain. Bar represents 50 micrometers.



tender fibers of the same muscle remain electrically quiet without evidence of motor-unit or fibrillation potentials. This localized needle EMG [TrP-EMG] activity is sustained for as long as we have recorded, up to 60 minutes (17). The TrP-EMG activity is increased by laboratory stressors in both normal subjects (McNulty) (20) and patients with tension-type headache (21). In a series of pharmacologic studies it was demonstrated that the TrP-EMG activity is not eliminated by cholinergic blockade, but is eliminated by alpha-adrenergic blockade both intravenously and directly injected into TrPs. The competitive alpha-blocker phentolamine eliminated the EMG abnormality transiently, while the non-competitive alpha-blocker phenoxybenzamine appears to eliminate it indefinitely with significant TrP pain reduction for up to 24 months as observed to date. At the current dosage regimen of 3 mg in 0.3 cc of normal saline, an average pain improvement of 78% has been achieved with adverse effects limited to short-lived injection site soreness. Nevertheless, these pharmacologic studies are unblinded and preliminary.

A TrP nidus identified by this two-channel needle EMG technique and biopsied during surgery was found to contain a muscle spindle and no other pathology. Previous biopsy studies of the trapezius in patients with chronic pain did not determine tissue sample sites using a needle EMG technique, nor did these studies describe the presence of muscle spindles in their samples (13,14). This is consistent with the reported low distribution of spindles in the upper part of the trapezius (25). The specimen did not contain ferric reaction product, most likely because the electrode tip was not in the spindle but was close enough to record its electrical activity, or because the amount of current was too low. It is unlikely that the needle EMG and methylene blue localized biopsy specimen of only 0.035 cubic centimeters would contain a muscle spindle by chance. Nevertheless this procedure was done in only one subject and the evidence is not conclusive.

It has been proposed that chronic muscle pain associated with myofascial TrPs is related to sympathetically-mediated hyperactivity of muscle spindles (17). The TrP-EMG activity is recorded from contracting intrafusal muscle fibers which extend beyond the capsule sheath at both ends and which are being stimulated to contract,

not by cholinergic [gamma] activation but rather by alpha-adrenergic stimulation. Pain arises in the spindle capsule, which is under increased pressure. The condition is initiated by traumatic and/or repetitive hyperextension of the spindles, such as in strain injury, and is sustained by sympathetically-mediated factors, including emotional tension [stress].

Direct sympathetic innervation of intrafusal muscle fibers has been demonstrated (26,27) and sympathetic stimulation has been shown to activate 1A spindle afferents producing muscle tension in curarized and de-efferented animals (28). Spindles are both pain- and pressure-sensitive (29,30). The TrP needle EMG activity is consistent with spindle intrafusal muscle fiber action potentials (31). The localized distribution of the TrP EMG activity is also consistent with activity arising in muscle spindles which are 1-2 mm wide and 4-6 mm long (26) and which are scattered throughout muscle tissue with a particularly high distribution in cervical and axial muscles (25,32).

REFERENCES

1. Bonica J: The Management of Pain, Vol. I, Second edition. Lea & Febiger, Philadelphia, 1990, pp. 180-196.
2. Magni G: The epidemiology of musculoskeletal pain, Chapter 1. Progress in Fibromyalgia and Myofascial Pain. Edited by H. Voeroy and H. Merskey. Elsevier Science, Amsterdam, 1993, pp. 3-20.
3. Holdbrook TL: Frequency of occurrence, impact and cost of selected musculoskeletal conditions in the United States. American Academy of Orthopedic Surgeons, Chicago, 1984, pp. 1-13.
4. National Center for Health Statistics: Office Visits to Neurologists: 1985. Advance Data From Vital and Health Statistics, Washington, DC, 1988, 158: 1-3.
5. Eisenberg D: Unconventional medicine in the United States. New England Journal of Medicine 328: 246-252, 1993.
6. Fisbain DA, Goldberg M, Meagher BR, Steele R, Rosomoff H: Male and female chronic pain patients categorized by DSM-III psychiatric diagnostic criteria. Pain 26:181-197, 1986.
7. Cherkin D, Deyo R, Loeser J, Bush T, Waddell G: International comparison of back surgery rates. Spine 19,11: 1201-1206, 1994.
8. Pheasant HD, Dyck P: Failed lumbar disc surgery. Clinical Orthopedics 184: 93-97, 1982.
9. Kimura J: Electrodiagnosis in Diseases of Nerve and Muscle: Principles and Practice. F.A. Davis, Philadelphia, 1992, pp. 235-258.

10. Daube J: Chap. 34. Myology. Edited by A Engel, B Banker. McGraw-Hill, New York, 1986, pp. 1081-1120.
11. Durette M, Rodriguez A, Agre J, Silverman J: Needle EMG evaluation of patients with myofascial or fibromyalgia pain. *Am J Phys Med and Rehab* 70: 154-156, 1991.
12. Zidar J, Backman E, Bengtsson A, Henriksson K: Quantitative EMG and muscle tension in painful muscles in fibromyalgia. *Pain* 40: 249-54, 1990.
13. Henriksson K, Bengtsson A, Lindman R, Thornell L: Morphological changes in muscle in fibromyalgia and chronic shoulder myalgia. *Progress in Fibromyalgia and Myofascial Pain*. Edited by H Voeroy and H Merskey. Elsevier Science Publishers, Amersterdam, 1993, pp. 61-72.
14. Yunus M, Kalyan-Raman UP: Muscle biopsy findings in primary fibromyalgia and other forms of non-articular rheumatism. *Rheum Dis Clin North America* 15: 115-134, 1989.
15. Traveli J, Rinzler S, Herman M: Pain and disability of the shoulder and arm, treatment by intramuscular infiltration with procaine HCl. *JAMA* 120, 6: 417-22, 1942.
16. Rachlin E: *Myofascial Pain and Fibromyalgia, Trigger Point Management*. Mosby, St. Louis, 1994, pp. 3-29.
17. Sola A, Bonica J: Myofascial pain syndromes. *The Management of Pain, Second Edition*, Edited by J Bonica. Lea and Febiger, Philadelphia, 1990, pp. 352-367.
18. Travell J, Simons D: *Myofascial Pain and Dysfunction, the Trigger Point Manual*, Williams and Wilkins, New York, 1983, pp. 5-44.
19. Hubbard D, Berkoff, G: Myofascial trigger points show spontaneous needle EMG activity. *Spine* 18: 1803-1807, 1993.
20. McNulty W, Gevirtz R, Berkoff G, Hubbard D: Needle electromyographic evaluation of trigger point response to a psychological stressor. *Psychophysiology* 31: 313-316, 1994.
21. Lewis C, Gevirtz R, Hubbard D, Berkoff G: Needle trigger point and surface frontal EMG measurements of psychophysiological responses in tension-type headache patients. *Biofeedback & Self-Regulation* 19, 3: 274-275, 1994.
22. Wolfe F, Smythe HA, Yunus MB et al. The American college of Rheumatology 1990 Criteria for the Classification of Fibromyalgia: Report of the multicenter criteria committee. *Arthritis Rheum* 33: 160-172, 1990.
23. Gurr EA: *A practical Manual of Medical and Biological Staining Techniques*. Interscience Publishers, New York, 1953, pp. 1-320.
24. Humason, GL: *Animal tissue techniques*. W.H. Freeman, San Francisco, 1967, p. 171.
25. Voss VH: Zahl und anordnung der muskelsindelu in den oberen zungenbein muskeln, im m. trapezius und m. latissimus dorsi. *Anat Anzeiger* 103: 443-446, 1956.
26. Barker D, Banks R: The muscle spindle. *Myology*. Edited by A Engel, B Banker. McGraw-Hill, New York, 1986, pp. 309-341.
27. Santini M, Ibata Y: The fine structure of thin unmyelinated axons within muscle spindles. *Brain Res* 33: 289-302, 1971.